

Pediatric acute bilateral optic neuritis: A case report

YU CHENG and YUAN WU

Department of Ophthalmology, Peking University First Hospital, Beijing 100034, P.R. China

Received October 13, 2023; Accepted January 5, 2024

DOI: 10.3892/br.2024.1728

Abstract. With the improvement of diagnostic technology, the diagnosis of optic neuritis (ON) has become increasingly accurate. Due to the special characteristics of the pediatric population, there is currently a lack of large-scale studies and related guidelines on pediatric ON. This case report describes the complete diagnosis and treatment process of a 7-year-old male patient with bilateral acute ON, from onset to symptom relief. During the outpatient stage, the patient was suspected of having different types of ON by different departments, but the diagnosis was confirmed through antibody testing after hospitalization. The treatment plan for this case was based on the current plan for adults and the prognosis was better than that of adults with similar characteristics. This suggests that pediatric ON has its own features and requires more case reports and clinical research for further exploration and summary.

Introduction

The clinical diagnosis of optic neuritis (ON) can be achieved based on characteristic medical history, symptoms and signs. However, with more advanced methods such as specific antibody serology testing and magnetic resonance imaging (MRI) being used, a more accurate diagnosis of ON can be made (1). In the pediatric population, due to the difficulty in describing symptoms accurately (2), challenges in collecting physical signs and limited number of cases, there are currently no guidelines or results of large-scale studies specifically for pediatric ON.

It is necessary to explore and conduct in-depth studies on pediatric optic neuritis, as it presents characteristics distinct from optic neuritis in adults, such as a higher likelihood of bilateral onset (3), potentially better prognosis (4), lower recurrence rates (5) and increased susceptibility to medication side effects, as they are still in the developmental stage.

Therefore, pediatric optic neuritis has its own characteristics in terms of predicting risk factors, choosing and balancing long-term maintenance plans, monitoring complications and determining follow-up frequency. It requires separate research and evaluation.

The present case report aims to share experiences in the diagnosis and treatment of pediatric ON to limitedly contribute to future large-scale studies and relevant guidelines.

Case report

A male patient aged 7 years, came to the Department of Ophthalmology at Peking University First Hospital (Beijing, China) in April 2023 with the main complaint of 'sudden blurred vision in both eyes for about 2 days'. The patient had no obvious triggering factor for the blurred vision that started 2 days ago. The decrease in visual acuity was similar in both eyes. There were no accompanying symptoms such as fever, vomiting, headache, eye pain, redness or increased eye secretions. The patient had a normal mental state, appetite and sleep. There were no seizures or abnormal emotional behavior. Approximately 3 weeks prior, the patient had suffered a 'common cold' with symptoms of fever (102.7°F) and cough for ~1 week. The patient vomited 3 times during that period but experienced relief after taking medication (the guardian of the patient does not recall the specific medication, but it was described as a generic over-the-counter cold symptom relief medication). An ophthalmic examination conducted 1 month previously showed 20/20 vision in both eyes.

The following examinations were completed during the outpatient visit: Visual acuity was 20/400 in both eyes. Non-contact intraocular pressure was 18 mmHg in the right eye (OD) and 17 mmHg in the left eye (OS). There was no redness or swelling of the eyelids and no conjunctival edema or congestion, and eye movements were normal in all directions without any pain. The cornea was transparent, the anterior chamber depth was clear and both pupils were round with delayed light reflex. The lens was transparent. Fundus examination showed normal transparency of the vitreous cavity in both eyes, indistinct and elevated optic disc boundaries, redness and no obvious abnormalities in the retina and blood vessels (Fig. 1). Goldman visual field examination indicated a central scotoma in the OD and peripheral visual field defect in the upper half of the OS. OCT revealed normal morphology of the macular central fovea and significant optic disc elevation in both eyes (Fig. 2). The provisional diagnosis in the ophthalmology clinic was 'bilateral ON' and it was recommended

Correspondence to: Dr Yuan Wu, Department of Ophthalmology, Peking University First Hospital, 8 Xishiku Street, Xicheng, Beijing 100034, P.R. China
E-mail: wuyuanpk@hsc.pku.edu.cn

Key words: optic neuritis, ophthalmology, pediatrics, myelin oligodendrocyte glycoprotein, demyelinating disease of central nervous system

to complete visual evoked potential (VEP) and optic nerve MRI as soon as possible and to consult with the neurology department promptly.

VEP performed 2 days after the initial presentation revealed delayed latency of the P100 wave and decreased amplitudes of the P100 wave at various spatial frequencies, as well as decreased amplitudes of the P2 wave in both eyes. On the same day, enhanced MRI (Fig. 3) showed slight thickening of the posterior part of the intracranial segment of the right optic nerve, bilateral optic canal segment and intracranial segment, with significant enhancement visible. In addition, multiple patchy T2-weighted imaging (T2WI) hyperintensity lesions were observed in the bilateral frontal, temporal, occipital lobes, pons, medulla oblongata and the right cerebellar hemisphere, with multiple enhancements visible. Based on the above, the ophthalmology department considered a diagnosis of 'bilateral ON, multiple sclerosis (MS)?' and admitted the patient to the inpatient department for further evaluation. On the same day, a consultation was also carried out with the neurology department and a provisional diagnosis of 'acute disseminated encephalomyelitis (ADEM)' was made.

The patient was admitted to the ophthalmology ward 6 days after the initial presentation to receive comprehensive screening for infectious diseases, tuberculosis skin test and other systemic examinations. Pulse therapy of high-dose intravenous methylprednisolone (IVMP) sodium succinate was administered, along with a consultation with the pediatric neurology department. After the consultation, the patient was transferred to the pediatric neurology department for further diagnosis and treatment. Subsequently, the patient underwent lumbar puncture, cranial and spinal cord MRI and antibody testing for central nervous system demyelinating diseases (conducted by the Beijing branch of Hangzhou Oumengwei Medical Laboratory Co., Ltd.) [aquaporin (AQP)4, myelin oligodendrocyte glycoprotein (MOG) and myelin basic protein (MBP)]. The results showed negative immunoglobulin G (IgG) and oligoclonal bands in the cerebrospinal fluid, positive MOG-IgG in the serum (++ at 1:32) and negative AQP4 and MBP. The MRI showed bilateral occipital-temporal-parietal-occipital lobes, pons, medulla, bilateral cerebellar hemisphere, right hippocampus with multiple patchy T2WI hyperintensity, T2 fluid-attenuated inversion recovery hyperintensities and T1WI hypointensities, some of which showed ring-shaped diffusion-weighted imaging hyperintensities and decreased apparent diffusion coefficient signals. Patchy T2WI hyperintensities were also seen in C2, C5 and Th10. Therefore, the patient was diagnosed with 'MOG antibody-associated disease' and received three courses of high-dose methylprednisolone pulse therapy combined with intravenous immunoglobulin (IVIG) therapy (three days per course, a four-day IVIG therapy between the first and second courses, and a four-day break between the second and third courses), followed by oral prednisolone (initial dose of 40 mg/day, gradually tapered weekly). During the treatment process, the patient's visual acuity initially continued to decline to counting fingers at close range (7 days after initial presentation), but gradually recovered to OD 20/16, OS 20/20 (15 weeks after initial presentation). Optic disc edema (Fig. 1) and central nervous system lesions (Fig. 3) both improved. The patient experienced mild to moderate elevation of intraocular pressure

after steroid pulse therapy, but it was controlled with topical ocular hypotensive medications.

Discussion

Until now, the clinical diagnosis of ON has been based on characteristic medical history, symptoms and physical signs. The IVMP treatment for the acute phase of ON can be initiated only based on the clinical diagnosis. However, in the past decade, the understanding of ON has evolved and subtypes of central nervous system (CNS) demyelinating diseases and relative ON have expanded (6), emphasizing the increasing importance of etiological diagnosis for precise treatment, assessment of recurrence and prognosis and selection of long-term maintenance strategies.

MS, neuromyelitis optica spectrum disorders, ADEM and myelin oligodendrocyte glycoprotein antibody-associated disease (MOGAD) can all lead to demyelinating lesions and ON, resulting in significant clinical overlap (6). This poses challenges in the etiological diagnosis of ON, as the initial clinical diagnosis is often revised multiple times before arriving at a final diagnosis. Based on medical history, symptoms and signs, and MRI results, the patient of the current study was initially suspected of having MS and ADEM by the ophthalmology and neurology outpatient departments, respectively, before being admitted to the hospital. The diagnosis of MOGAD was ultimately confirmed based on immunological tests conducted after admission. The diagnostic process of this case suggests that the value of MRI and immunological tests is directly linked to the etiological diagnosis of ON, and the completion of these two examinations is important for evaluating the overall condition and establishing etiological diagnoses. It is worth noting that, since relevant immunological tests have only gradually matured in the past decade, the establishment of reference values may require further correction and improvement with a larger amount of data. For now, the reference values for immunological tests may vary significantly among institutions and it is recommended to refer to the normal value range within the respective institution.

Currently, there have been no prospective intervention studies specifically focusing on the pediatric population in terms of ON treatment strategies. Based on published cases and retrospective studies, the acute treatment of pediatric ON still largely follows the strategy recommended by the ON Treatment Trial (7), which involves the use of IVMP followed by oral steroids to expedite visual recovery. In severe cases or cases with suboptimal response to treatment, steroid therapy is often combined with IVIG or plasmapheresis (PLEX) (4), as in the case of the present study. Among the cases reported in the literature, a regimen of IVIG combined with PLEX without the use of steroids was only employed in one case (8). In contrast to acute treatment, the long-term maintenance treatment strategy for pediatric ON is more varied and controversial. Using MOGAD as an example, the incidence rate in children is higher than in adults (9), but existing studies have shown that the risk of relapse is lower in children (10). This raises the question of whether long-term maintenance therapy is necessary in the pediatric population as it is in adults. This is particularly important

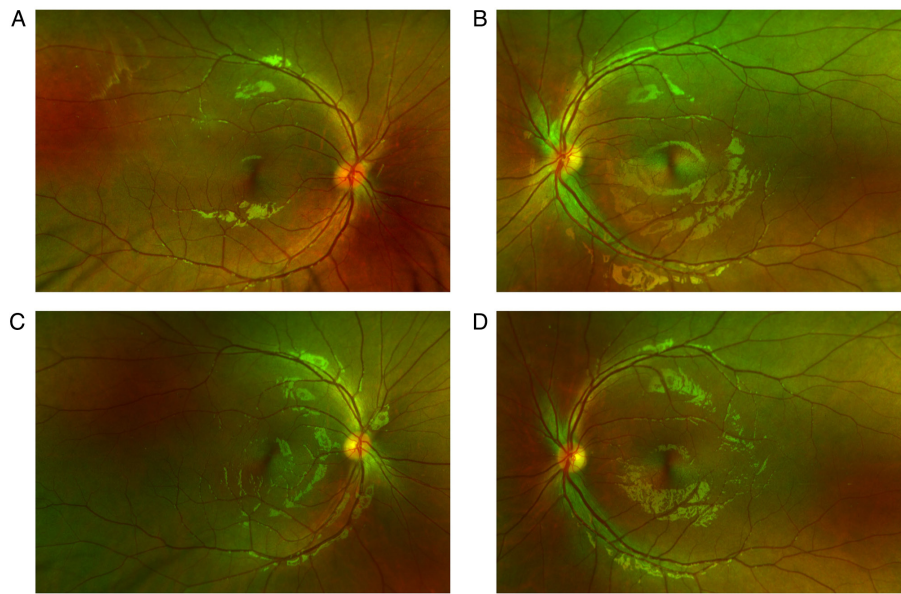


Figure 1. Fundus image before and after treatment. Images of the fundus of the (A) right and (B) left eye before treatment in April 2023. It can be observed that the optic disc borders are blurry in both eyes, with the right eye being more pronounced. In addition, there is significant congestion of the optic disc in the right eye. The fundus of (C) the right and (D) left eye after treatment (37 days after initial consultation). It can be observed that the optic disc borders are clear and the color is normal in both eyes.

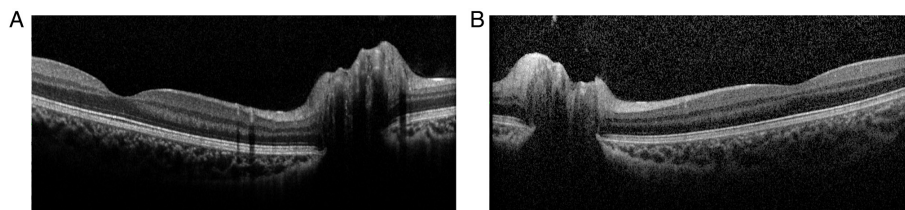


Figure 2. Optical coherence tomography images at the onset of the disease. (A) Right and (B) left eye. Both eyes exhibit optic disc edema, with the right eye being more severe. The macular region of both eyes appears normal.

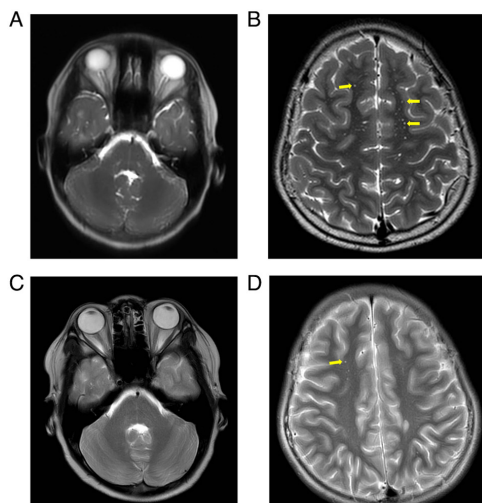


Figure 3. MRI features before and after treatment. The orbit MRI is shown in the left panel, while the cranial MRI is shown in the right panel. (A and B) Pre-treatment MRI. (A) Significant thickening of the optic nerve with enhanced visibility. (B) Multiple punctate T2-weighted imaging high-signal lesions (the yellow arrows indicate some of the lesions) in the intracranial white matter. (C and D) Post-treatment MRI; (C) the optic nerve appears slightly thinner compared to before and (D) there is a reduction in the extent of intracranial lesions (the yellow arrow indicates one of the remaining lesions). MRI, magnetic resonance imaging.

considering the potential side effects of medications such as hormones and immunosuppressants on children who are still in the developmental stage and have a longer life expectancy.

However, current statistics show that as many as 79% of pediatric cases receive maintenance treatment (7). Common maintenance therapies include oral corticosteroids for >4 weeks, oral immunosuppressive agents (such as azathioprine, mycophenolate mofetil), monthly IVIG therapy and monoclonal antibody-targeted therapy. Long-term maintenance therapy is often used for cases of relapse, continuous positivity for MOG-IgG and imaging findings suggesting new CNS lesions (7). In the present case, due to the typical CNS lesions during attacks, significant involvement of the optic nerve and severe visual impairment, oral steroid maintenance therapy was provided and gradually tapered off. At the time of conclusion of the present study (December 2023, >30 weeks after the initial consultation), there has been no relapse in this patient and vision has recovered to the pre-onset level. Currently, due to the limited number of cases with sufficient follow-up duration and clear etiological diagnosis, there is a lack of high-level evidence-based research on risk prediction factors for relapse of pediatric ON, the necessity of long-term maintenance drug therapy

and how to choose the appropriate treatment. Global collaboration among peers is urgently needed to further investigate these areas.

Going through the diagnostic process in the present case, various problems or areas of improvement were identified. First, although the diagnostic process was comprehensive, the workflow was somewhat inefficient. This was due to two reasons: i) The medical resources at the large medical center were crowded, resulting in a delay in the timely completion of the crucial CNS MRI examination, which delayed the subsequent diagnostic and treatment steps; ii) considering the financial burden on the patient, from the initial consultation in April 2023 to the completion of infection screening and immunological examinations related to CNS demyelinating diseases before IVMP therapy 6 days later, we did indeed spend several days waiting for the MRI results to confirm the next move. It may be more effective to conduct infection screening and immunological examinations at the initial consultation if the patient's financial condition allows, while waiting for the MRI to be completed at the same time. This would make the diagnosis and treatment process more compact and efficient. Secondly, regarding the treatment strategy, in the present case, the patient continued to take oral corticosteroids for >4 weeks after symptom relief, which led to complications of increased intraocular pressure, necessitating the addition of medications to control the intraocular pressure. In ophthalmic clinical practice, we have observed that children are highly sensitive to corticosteroids in terms of intraocular pressure and are prone to developing steroid-induced glaucoma. Therefore, when selecting a maintenance treatment regimen, the necessity of long-term corticosteroid treatment should have been questioned and the possibility of combining immunosuppressive agents to reduce the dosage and duration of corticosteroid use should have been explored.

It is esteemed that the complete diagnostic and therapeutic process, as well as the analysis, discussion and reflection on this case, may contribute to the optimization of the diagnosis and treatment of pediatric ON.

Acknowledgements

Not applicable.

Funding

No funding was received.

Availability of data and materials

The data generated in the present study may be requested from the corresponding author.

Authors' contributions

YC was a major contributor in writing the manuscript. YC and YW both participated in the diagnosis and treatment of this case. All authors have read and approved the final manuscript. YC and YW confirm the authenticity of all the raw data.

Ethics approval and consent to participate

Not applicable.

Patient consent for publication

This case report does not include any identifying information. Consent for publication of case data/description and images has been obtained from the patient's guardian.

Competing interests

The authors declare that they have no competing interests.

References

1. Petzold A, Fraser CL, Abegg M, Alroughani R, Alshowaeir D, Alvarenga R, Andris C, Asgari N, Barnett Y, Battistella R, *et al*: Diagnosis and classification of optic neuritis. *Lancet Neurol* 21: 1120-1134, 2022.
2. Lehman SS and Lavrich JB: Pediatric optic neuritis. *Curr Opin Ophthalmol* 29: 419-422, 2018.
3. Wilejto M, Shroff M, Buncic JR, Kennedy J, Goia C and Banwell B: The clinical features, MRI findings, and outcome of optic neuritis in children. *Neurology* 67: 258-262, 2006.
4. Wan MJ, Adebona O, Benson LA, Gorman MP and Heidary G: Visual outcomes in pediatric optic neuritis. *Am J Ophthalmol* 158: 503-507.e2, 2014.
5. Waters P, Fadda G, Woodhall M, O'Mahony J, Brown RA, Castro DA, Longoni G, Irani SR, Sun B, Yeh EA, *et al*: Serial anti-myelin oligodendrocyte glycoprotein antibody analyses and outcomes in children with demyelinating syndromes. *JAMA Neurol* 77: 82-93, 2020.
6. Gise RA and Heidary G: Update on pediatric optic neuritis. *Curr Neurol Neurosci Rep* 20: 4, 2020.
7. Klein da Costa B, Banwell BL and Sato DK: Treatment of MOG-IgG associated disease in paediatric patients: A systematic review. *Mult Scler Relat Disord* 56: 103216, 2021.
8. Baumann M, Hennes EM, Schanda K, Karenfort M, Kornek B, Seidl R, Diepold K, Lauffer H, Marquardt I, Strautmanis J, *et al*: Children with multiphasic disseminated encephalomyelitis and antibodies to the myelin oligodendrocyte glycoprotein (MOG): Extending the spectrum of MOG antibody positive diseases. *Mult Scler* 22: 1821-1829, 2016.
9. de Mol CL, Wong Y, van Pelt ED, Wokke B, Siepmann T, Neuteboom RF, Hamann D and Hintzen RQ: The clinical spectrum and incidence of anti-MOG-associated acquired demyelinating syndromes in children and adults. *Mult Scler* 26: 806-814, 2020.
10. Cobo-Calvo A, Ruiz A, Rollot F, Arrambide G, Deschamps R, Maillart E, Papeix C, Audoin B, Lépine AF, Maurey H, *et al*: Clinical features and risk of relapse in children and adults with myelin oligodendrocyte glycoprotein antibody-associated disease. *Ann Neurol* 89: 30-41, 2021.