

Therapeutic considerations for patients with chronic plantar fasciitis (Review)

DANIELA POENARU¹, SILVIU CONSTANTIN BADOIU² and ANCA MIRELA IONESCU¹

Departments of ¹Rehabilitation Medicine and ²Morphological Sciences,
'Carol Davila' University of Medicine, Bucharest 020021, Romania

Received May 1, 2021; Accepted July 14, 2021

DOI: 10.3892/mi.2021.9

Abstract. Heel pain is a common complaint in the population, leading to a limitation in daily activities and a poor quality of life. Chronic plantar fasciitis is the most common cause of heel pain. Despite its name, which suggests inflammation, the underlying process is rather a degenerative one. The clinical course is often chronic or relapsing, as a challenge to physicians to find the most effective therapeutically approach. First-line treatment consists of rest, shoe modification, orthosis and physiotherapy. Physical exercise is an important tool which can be combined with other therapeutic options. Medication is usually administered in acute cases, in the form of simple analgesics, non-steroidal anti-inflammatory drugs (NSAIDs) or opioids, in different regimens. For chronic evolution, the use of NSAIDs is controversial. Second-line treatment includes extracorporeal shock wave therapy and corticosteroid local injection. New therapies have emerged, as autologous blood derivatives and prolotherapy, with growing evidence, to be included in clinical practice. The present review article discusses the therapeutic options for patients with chronic plantar fasciitis, to with an aim to shed light on the treatment strategies for this condition.

Contents

1. Introduction
2. Treatments
3. Conclusions and future perspectives

Correspondence to: Dr Daniela Poenaru, Department of Rehabilitation Medicine, 'Carol Davila' University of Medicine, 37 Dionisie Lupu Street, Bucharest 020021, Romania
E-mail: poenarudana@yahoo.com

Key words: plantar fasciitis, shoe modification, physiotherapy, extracorporeal shock wave therapy, autologous blood derivatives, prolotherapy

1. Introduction

Plantar fascia, plantar aponeurosis or plantar ligament is a triangular structure covering the sole of the foot. It originates from the medial tubercle of the calcaneus and it spreads in five bands or processes for the five toes. The bands appear at the level of the metatarsal head and divide at the level of metatarsophalangeal joint into two fascicles, superficial and profound. The superficial fascicle attaches to the skin and the deep fascicle divides into two slips to fuse with the flexor tendons of the toes and with the transverse metatarsal ligament (1) (Fig. 1).

Plantar fasciitis is the most frequent cause of heel pain and it challenges the physician as it has a chronic or relapsing course, interferes with walking and running. It also requires a number of interventions and patient compliance may diminish over time.

Although the term 'fasciitis' is suggestive of inflammation, the main process is a degenerative one, with no inflammatory cells. The terminology may be in fact fasciosis or fasciopathy, in the same category with tendinosis or tendinopathy. The main alteration is fibroblastic hypertrophy, disorganized collagen and vascular hyperplasia with zones of avascularity. The structural modification is triggered by repetitive micro-trauma due to excessive stretching (2).

2. Treatments

Natural evolution indicates that plantar fasciitis is a self-limiting condition, and after 6 to 18 months, the pain and limitations disappear spontaneously. This long duration is, however, a burden and impediment to the quality of life of patients.

Complete rest may reduce pain; however, this is not always feasible, since walking is necessary for daily activities. Relative rest is recommended for athletes or active adults, in the form of changing the type of physical activity. A number of treatment strategies for plantar fasciitis are available, and a list of these is presented in Table I.

Shoe alteration and orthotics. Shoe alteration is an important issue to discuss with the patients. Evaluating and replacing worn-out shoes is the first step, particularly for athletes. Researchers have underlined that running shoes lose their shock absorption properties over time (3). Shoes with thick and

well-cushioned midsoles may offer pain relief for individuals which have to stand or walk for long periods of time. When overpronation is the cause of pain, shoes have to be modified to increase foot stability and to control motion through a number of characteristics: A semi-curved outer sole shape, slip last or combination last (a particular shape of the insole wider at the toe box than at the heel). The toe box should be sufficiently wide and the sole should provide forefoot flexibility. The amount of stability or motion control of a shoe depends on the pronation control required. For underpronation, shoes are designed to increase flexibility both in the rear foot and in the forefoot, with a curved outer sole shape and a slip last, cushion midsole and accommodative heel pad to enhance shock absorption (4).

Arch tapping provides initial short-term pain relief; it may be used prior to each sport session, as it loses its effect after 24 min. It is advised to be followed by other therapeutic interventions. Continuous taping can also lead to skin lesions. Tapping acts through mechanical support, which is disputable, and through proprioceptive mechanism acting on cutaneous, fascial and muscular receptors. It is most suitable for the underpronated foot, to improve flexibility (5).

Foot orthoses, prefabricated or customized, are prescribed for two reasons: Mechanical and proprioceptive corrections. Mechanistically, they assist in shock absorption, correct overpronation and increase the stability. The proprioceptive strategy is based on the stimulation of plantar receptors to modify the postural control (6).

Over-the-counter arch supports are used by patients with mild pes planus, as they offer highly variable support depending on the material used. They are preferred by adolescents whose feet grow rapidly (6).

Custom orthotics require a plaster cast of the foot in neutral, followed by modeling of an insert, with the aim of correcting the overpronation and the metatarsal head motion, particularly the first metatarsal head. Heel cups are used to decrease the impact on the calcaneus, elevating the heel on a soft cushion and reducing tension on the plantar fascia (6).

Researchers agree that foot orthoses provide pain relief for a period of 3 to 12 months. However, there is debate on which type works more efficiently, the prefabricated or custom-made insert (6). There is no modification of gait pattern or postural control, at least after 9 weeks of wearing (7). It is important to stress the necessity to wear foot orthoses both indoors and outdoors.

Night splints are designed to maintain the ankle in 90° of dorsiflexion, to passively stretch the fascia and triceps - Achilles complex and to counterbalance the naturally position of relaxed plantar flexion during night sleep. They promote the healing of the fascia in the elongated position, decreasing the tension during the first steps taken in the morning. There are a number of types of night splints, varying from a prefabricated support to a custom made one. For a better tolerance, anterior night splints have been designed for the purpose of covering a smaller skin surface than the posterior splints and to allow walking. They have been reported to relieve pain in a significant number of patients, although their side-effects may reduce the compliance: Skin pressure and mild nocturnal discomfort. Combining physical exercise with night splints leads to better results as regards pain and local function (8).

Table I. Treatment strategies for plantar fasciitis.

Treatment strategy	Comments
Rest	Complete/relative
Shoe alteration	Replacing old shoes Midsole features Foot stability control
Arch tapping	
Orthotics	Prefabricated/customized Night splints
Physiotherapy	Cryotherapy Iontophoresis (acetic acid, corticosteroids)
Physical exercise	Stretching Eccentric strengthening
Medication	Analgesics (acetaminophen, opioids) Non-steroidal anti-inflammatory drugs
ESWT	Radial/focused
Corticosteroids	Local injections
Autologous blood derivatives	Autologous blood injection Platelet rich plasma (PRP)
Prolotherapy	Hypertonic dextrose

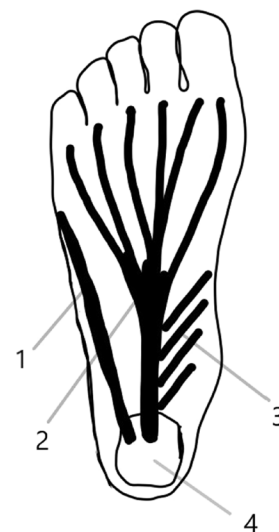


Figure 1. Anatomy of plantar fascia: 1, lateral band; 2, central band; 3, medial band of pantar fascia; 4, calcaneus, posterior tuberosity.

Physiotherapy. Ice or other cryotherapy procedures exert a marked analgesic effect, and are used for short periods of time (10 to 20 min).

Iontophoresis, a non-invasive method, uses a low-voltage galvanic current to introduce active agents through the skin, up to a depth of 20 mm, as corticosteroids or acetic acid. Some researchers have stressed the importance of acetic acid iontophoresis, as the local chronic process produces excessive calcium ions, which, as calcium carbonate, form spurs. Acetic acid iontophoresis delivers the negatively charged acetate ions

that combine with calcium positive ions from local processes, forming calcium acetate which dissolves into the local blood stream and is removed (9).

Treatment prescription consists of six alternate-day sessions, with a total daily dose of 40-mA/min, the intensity of the galvanic current up to 4 mA, according to skin sensitivity, using 4 ml acetic acid. Acetic acid (5%) is delivered under the negative electrode (cathode) placed on the plantar aspect of the calcaneus, on the most painful spot; the positive electrode is placed on the posterior aspect of the calf (9).

Corticosteroid iontophoresis (4% dexamethasone) exerts a less prominent pain-reducing effect on plantar fasciitis than acetic acid, although better than the placebo (10).

Physical exercise includes the stretching of the plantar fascia and triceps - Achilles complex. Usually, patients perform the stretching under medical surveillance, two or three times a week for 6 to 12 weeks. However, this may be associated with an economic burden and is a time-consuming activity. In addition, certain specific situations (as the actual pandemic) may reduce the mobility of individuals and, consequently, reduces treatment compliance and participation. Static and dynamic stretching may be adapted for home-based use and remote medical surveillance may be initiated (11).

Medication. Simple analgesics and non-steroidal anti-inflammatory drugs (NSAIDs) are efficient for short periods of time, particularly during the acute phase. In the chronic phase however, the use of NSAIDs is controversial. NSAIDs mainly function by inhibiting prostaglandin synthesis, whereas the production of other inflammatory mediators (leukotrienes, cytokines and platelet activating factor) remains unaltered. The addition of a simple analgesic drug (such as acetaminophen) may provide short-term relief. It has been demonstrated that primary care physicians prescribe NSAIDs more often, while pain specialists are more likely to recommend opioids. Combinations between acetaminophen and opioids (tramadol or codeine) are often prescribed (4,11,12).

NSAIDs should be used in combination with other conservative therapies (rest, physical agents, exercise, etc.), as isolated utilization has failed to reduce consistent pain and disability (13).

The side-effects of NSAIDs should also be taken into consideration, particularly during chronic administration. These side-effects include gastritis, peptic ulcers, esophagitis, gastrointestinal bleeding, interstitial nephritis, sodium and water retention, thrombocytopenia, as well as central nervous system and hepatic complications.

Extracorporeal shock wave therapy (ESWT). ESWT and corticosteroid injections are considered second-line therapies. ESWT is a non-invasive procedure using mechanical shock waves to alter pain receptors and to promote local healing through microtrauma. The use of ESWT in the treatment of musculoskeletal conditions has increased. According to the energy delivered, ESWT is defined as low energy or high energy, with a cut-off value of 0.12 mJ/mm² (14).

Two forms of therapy, radial shock wave (RSW) and focused shock therapy (FSW) have become available, with the radial form having a dispersing effect on a large area. Studies have evaluated both ESWT in general and the specific forms

of ESWT and have found these to be more effective than sham treatment on pain reduction. RSW seems to have a superior effect (9,13,15). Moreover, some researchers have integrated both forms of shock waves, focused and radial, each one with 2,000 pulses (0.2 mJ/mm²) in the same session, to achieve pain reduction (16,17).

The ideal candidate for this type of treatment is the patient with chronic or recalcitrant plantar fasciitis, with an evolution of at least 6 months and a lack of response to conservative modalities. There is no unique protocol as regards the energy level, number of impulses and sessions. Generally, there are 3 to 5 weekly sessions, each with 1,000-2,000 pulses, both on the maximum tenderness area and on the whole fascia. Researchers agree on pain reduction on the short- (3 weeks) and long-term (6 months) and an improvement on walking performance (gait speed, cadence and distance) (18). For acute cases, with an evolution of up to 1 month, no clinical improvement has been observed following ESWT (19).

The side-effects of this type of treatment are minor and transient and include: Post procedural pain, warm or burning sensations, numbness, tingling, petechiae and ecchymosis; these are intensity-related reactions. The risk of local bleeding is increased in patients with coagulopathies and on anticoagulant therapy (20).

Corticosteroids. Corticosteroids are beneficial in the early stages of the condition; however, they are associated with multiple risks. The injection is performed using the palpation method or ultrasound guidance, via the plantar, posterior or medial approach. Long-acting corticosteroids, i.e., dexamethasone and betamethasone, and intermediate-acting corticosteroids, i.e., methylprednisolone, prednisolone and triamcinolone are used in different regimens, with no evidence of the superiority of one substance over the other (21).

In chronic, recalcitrant cases, this therapy is effective in the reduction of heel pain and plantar fascia thickness, as proven by ultrasound evaluation (22,23). As the procedure is painful, some researchers have proposed a posterior tibial nerve block prior to corticosteroid injection, to reduce the level of pain experienced during the plantar injection (23).

The risks associated with corticosteroid use are fat pad atrophy, rupture of the plantar fascia, pain, local bleeding or bruising, infection, skin atrophy and osteomyelitis of the calcaneus (24).

Autologous blood derivatives. Autologous blood derivatives and prolotherapy may be considered third-line therapy. Autologous blood injection (ABI) and platelet rich plasma (PRP) are novel therapeutic procedures in muscle, tendon and ligament pathology, with wide-spread use, dedicated mainly to recalcitrant or chronic cases, with the failure of conservative treatments. ABI uses a small amount (2-4 ml) of patient blood to dispose it into the target tissue. PRP is a platelet concentrate obtained following the centrifugation of patient blood. There is no standardized method to obtain PRP; thus, the end-product may vary in platelet and leucocyte concentration between studies (25).

Both therapies create a local inflammatory condition, supply the tissue with growth factors and promote healing. Some researchers use one single entry point to dispose the

product around the plantar fascia or after dry needling, e.g., multiple fascia penetration to produce small mechanical injuries. Other physicians use a number of entry points, according to the maximum tenderness sites (25).

One injection of ABI has been found to reduce heel pain between 40 and 84% in the first 2 months following the procedure, with a consistent result after 1 year. A transient pain following the procedure (2-3 days) has been reported in ~30% of cases, which subsides with the use of analgesics. No fascial rupture has been noted (26,27).

PRP administration may be unique or on a regimen of three weekly injections, with heel pain resolution at 12 months in 64% of patients. The main side-effect is post-procedural pain, reported by the majority of patients (79%), with an intensity of 8.1/10 on the visual analogue scale (VAS) scale and which subsides within 2 h (27).

Anesthesia may be provided locally, by means of a spray or as a regional posterior tibial nerve block. Post-injection care varies from total immobilization for a short period of time to relative rest, with avoiding running or jumping, with a gradual return to normal physical activity over a period of 3 weeks (27). Injections can be administered blindly, although a number of physicians prefer sonographic guidance.

Plantar fascia sonography is useful to document the structural changes following ABI or PRP treatments. As previously demonstrated, after 3 months, the echogenicity of the fascia normalizes in 88% of patients and the thickness decreases, without significant difference between the two. Sonographic and pain evolution are not associated with each other (28,29).

ABI has been found to be superior to conservative treatment and comparable with corticosteroid injection, while the pain resolution lasts longer (30). When comparing PRP to a saline injection, both therapies result in pain reduction, with a significantly better result for PRP. The fact that simple saline can lead to symptom reduction may be explained by the needling effect, another technique which deserves attention (31,32).

For plantar fasciitis, PRP was compared with corticosteroids and offered the comparable pain relief in the short- (2-4 weeks) and intermediate-term (4-8 weeks); however, better results were observed at long-term (over 24 weeks) (33).

Prolotherapy. Prolotherapy is receiving increasing attention in musculoskeletal conditions. Hypertonic glucose may contribute to local healing, through the osmotic rupture of local cells, with subsequent release of growth factors and healing (34).

Researchers use 2-4 ml dextrose, 15-20%, right into the fascia via a medial approach, preferably under ultrasound guidance. Lidocaine may be added for local anesthesia. The frequency of administration varies from three injections every 3 weeks to two weekly injections. With such a large variety of administration schedules, all studies have noted an improvement in pain and functionality in the short- (6 weeks) and long-term (12 months). The results were comparable with those of radial ESWT (32-35).

3. Conclusions and future perspectives

The chronic or relapsing clinical course of plantar fasciitis challenges physicians to study and standardize the therapeutic

approaches. The first-line of treatment should include rest, shoe modification, orthoses and physiotherapy. The addition of analgesic medication is a current practice. ESWT and corticosteroids are prescribed as a second-line therapy. New therapies have also emerged, as autologous blood derivatives and prolotherapy, with ongoing research stressing their benefits. Further studies are however required to determine the effectiveness and efficiency of these therapies.

Acknowledgements

Not applicable.

Funding

No funding was received.

Availability of data and materials

Not applicable.

Authors' contributions

The authors DP, SCB and AMI were all involved in the conception and documentation, and in the writing and reviewing of the present review article. The authors SCB and AMI confirm the authenticity of the all the raw data. All authors have read and approved the final manuscript.

Ethics approval and consent to participate

Not applicable.

Patient consent for publication

Not applicable.

Competing interests

The authors declare that they have no competing interests.

References

1. Draghi F, Gitto S, Bortolotto C, Draghi AG and Ori Belometti G: Imaging of plantar fascia disorders: Findings on plain radiography, ultrasound and magnetic resonance imaging. *Insights Imaging* 8: 69-78, 2017.
2. Monteagudo M, de Albornoz PM, Gutierrez B, Tabuenca J and Álvarez I: Plantar fasciopathy: A current concepts review. *EFORT Open Rev* 3: 485-493, 2018.
3. Cornwall MW and McPoil TG: Can runners perceive changes in heel cushioning as the shoe ages with increased mileage? *Int J Sports Phys Ther* 12: 616-624, 2017.
4. Lim AT, How CH and Tan B: Management of plantar fasciitis in the outpatient setting. *Singapore Med J* 57: 168-170, quiz 171, 2016.
5. Podolsky R and Kalichman L: Taping for plantar fasciitis. *J Back Musculoskeletal Rehabil* 28: 1-6, 2015.
6. Anderson J and Stanek J: Effect of foot orthoses as treatment for plantar fasciitis or heel pain. *J Sport Rehabil* 22: 130-136, 2013.
7. Moyne-Bressand S, Dhieux C, Dousset E and Decherchi P: Effectiveness of foot biomechanical orthoses to relieve patients suffering from plantar fasciitis: is the reduction of pain related to change in neural strategy? *BioMed Res Int* 2018: 3594150, 2018.

8. Wheeler PC: The addition of a tension night splint to a structured home rehabilitation programme in patients with chronic plantar fasciitis does not lead to significant additional benefits in either pain, function or flexibility: a single-blinded randomised controlled trial. *BMJ Open Sport Exerc Med* 3: e000234, 2017.
9. Costa IA and Dyson A: The integration of acetic acid iontophoresis, orthotic therapy and physical rehabilitation for chronic plantar fasciitis: A case study. *J Can Chiropr Assoc* 51: 166-174, 2007.
10. Osborne HR and Allison GT: Treatment of plantar fasciitis by LowDye taping and iontophoresis: Short term results of a double blinded, randomised, placebo controlled clinical trial of dexamethasone and acetic acid. *Br J Sports Med* 40: 545-549, discussion 549, 2006.
11. Nahin RL: Prevalence and pharmaceutical treatment of plantar fasciitis in United States adults. *J Pain* 19: 885-896, 2018.
12. Biswas C, Pal A and Acharya A: A comparative study of efficacy of oral nonsteroidal antiinflammatory agents and locally injectable steroid for the treatment of plantar fasciitis. *Anesth Essays Res* 5: 158-161, 2011.
13. Latt LD, Jaffe DE, Tang Y and Taljanovic MS: Evaluation and Treatment of Chronic Plantar Fasciitis. *Foot Ankle Orthop* 5: 1-11, 2020.
14. Cinar E, Saxena S, Akkurt HE and Uygur F: Extracorporeal shockwave therapy in the management of plantar fasciitis: A randomized controlled trial. *Foot* 44: 101679, 2020.
15. Vahdatpour B, Sajadieh S, Bateni V, Karami M and Sajjadieh H: Extracorporeal shock wave therapy in patients with plantar fasciitis. A randomized, placebo-controlled trial with ultrasonographic and subjective outcome assessments. *J Res Med Sci* 17: 834-838, 2012.
16. Leão RG, Azuma MM, Ambrosio GNC, Faloppa F, Takimoto ES and Tamaoki MJS: Effectiveness of shockwave therapy in the treatment of plantar fasciitis. *Acta Ortop Bras* 28: 7-11, 2020.
17. Sun J, Gao F, Wang Y, Sun W, Jiang B and Li Z: Extracorporeal shock wave therapy is effective in treating chronic plantar fasciitis: A meta-analysis of RCTs. *Medicine (Baltimore)* 96: e6621, 2017.
18. Roehrig GJ, Baumhauer J, DiGiovanni BF and Flemister AS: The role of extracorporeal shock wave on plantar fasciitis. *Foot Ankle Clin* 10: 699-712, ix, 2005.
19. Wheeler P: The role of autologous blood injections in the treatment for patients with chronic plantar fasciitis - A case series and longer-term follow-up. *Int Musculoskelet Med* 37: 47-53, 2013.
20. Roerdink RL, Dietvorst M, van der Zwaard B, van der Worp H and Zwerver J: Complications of extracorporeal shockwave therapy in plantar fasciitis: Systematic review. *Int J Surg* 46: 133-145, 2017.
21. Ang TW: The effectiveness of corticosteroid injection in the treatment of plantar fasciitis. *Singapore Med J* 56: 423-432, 2015.
22. Chen CM, Lee M, Lin CH, Chang CH and Lin CH: Comparative efficacy of corticosteroid injection and non-invasive treatments for plantar fasciitis: A systematic review and meta-analysis. *Sci Rep* 8: 4033, 2018.
23. McMillan AM, Landorf KB, Gilheany MF, Bird AR, Morrow AD and Menz HB: Ultrasound guided corticosteroid injection for plantar fasciitis: Randomised controlled trial. *BMJ* 344: e3260, 2012.
24. Tatli YZ and Kapasi S: The real risks of steroid injection for plantar fasciitis, with a review of conservative therapies. *Curr Rev Musculoskelet Med* 2: 3-9, 2009.
25. Vahdatpour B, Kianimehr L and Ahrar MH: Autologous platelet-rich plasma compared with whole blood for the treatment of chronic plantar fasciitis; a comparative clinical trial. *Adv Biomed Res* 5: 84, 2016.
26. Kirmani TT, Gul IA, Manzoor QW and Kangoo KA: Autologous whole blood injection in chronic plantar fasciitis: A prospective clinical study. *Int J Res Orthop* 4: 634-637, 2018.
27. Martinelli N, Marinozzi A, Carni S, Trovato U, Bianchi A and Denaro V: Platelet-rich plasma injections for chronic plantar fasciitis. *Int Orthop* 37: 839-842, 2013.
28. Scioli MW: Platelet-rich plasma injection for proximal plantar fasciitis. *Tech Foot Ankle Surg* 10: 7-10, 2011.
29. Tabrizi A, Dindarian S and Mohammadi S: The Effect of corticosteroid local injection versus platelet-rich plasma for the treatment of plantar fasciitis in obese patients: a single-blind, randomized clinical trial. *J Foot Ankle Surg* 59: 64-68, 2020.
30. Karimzadeh A, Raeissadat SA, Erfani Fam S, Sedighipour L and Babaei-Ghazani A: Autologous whole blood versus corticosteroid local injection in treatment of plantar fasciitis: A randomized, controlled multicenter clinical trial. *Clin Rheumatol* 36: 661-669, 2017.
31. Deghady AAM, Hamid MMA, Helal AMH, El-Sherif SM and Latief HSA: Platelet-rich plasma in treatment of plantar fasciitis: randomized double-blinded placebo controlled study. *J Appl Clin Pathol* 2: 1, 2019.
32. Yang WY, Han YH, Cao XW, Pan JK, Zeng LF, Lin JT and Liu J: Platelet-rich plasma as a treatment for plantar fasciitis: A meta-analysis of randomized controlled trials. *Medicine (Baltimore)* 96: e8475, 2017.
33. Jain K, Murphy PN and Clough TM: Platelet rich plasma versus corticosteroid injection for plantar fasciitis: A comparative study. *Foot* 25: 235-237, 2015.
34. Ersen Ö, Koca K, Akpınar S, Seven MM, Akyıldız F, Yıldız Y and Özkan H: A randomized-controlled trial of prolotherapy injections in the treatment of plantar fasciitis. *Turk J Phys Med Rehabil* 64: 59-65, 2017.
35. Asheghan M, Hashemi SE, Hollisaz MT, Roumizade P, Hosseini SM and Ghanjal A: Dextrose prolotherapy versus radial extracorporeal shock wave therapy in the treatment of chronic plantar fasciitis: A randomized, controlled clinical trial. *Foot Ankle Surg*: Aug 25, 2020 (Epub ahead of print).



This work is licensed under a Creative Commons Attribution-NonCommercial-NoDerivatives 4.0 International (CC BY-NC-ND 4.0) License.