

Figure S1. TET insertion images. A TET tube was inserted via the anus into the cecum, as far as the terminus of the ileum, using an endoscope, and while the head of the TET tube was kept stable, the endoscope was carefully removed. (A) The endoscope was reinserted and the head of the TET was fixed with a clamp that was attached to the intestinal wall. (B and C) A further two loops of the TET were fixed with clamps to the intestinal wall while removing the endoscope. (D) The end of the TET tube was fixed with tape to the outside of the skin at the lower back. TET, transendoscopic enteral tubing.

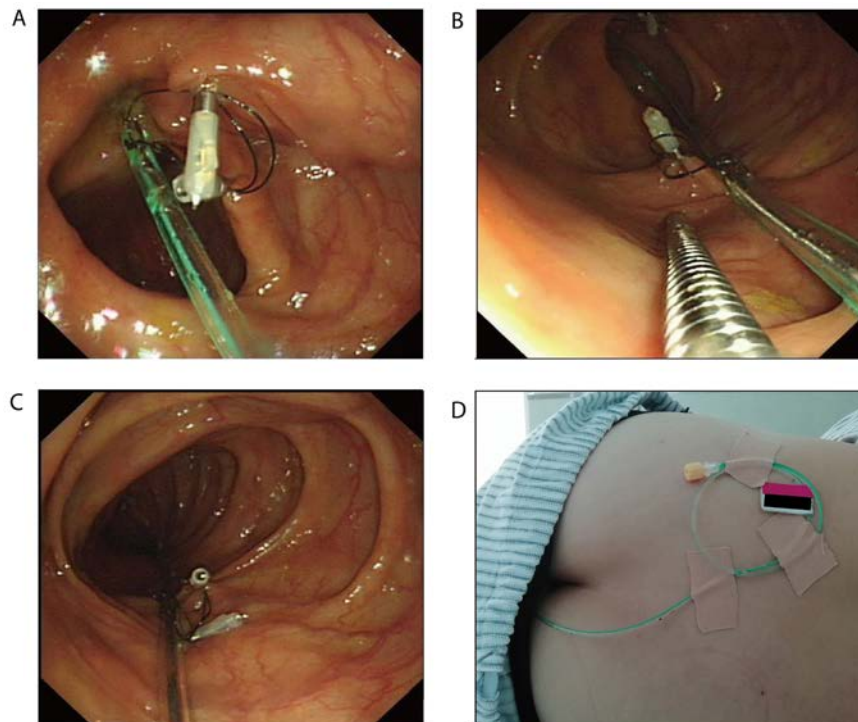


Figure S2. Transendoscopic enteral tubing tube.

