

REGULAR ARTICLE

# High-risk human papilloma viruses (HPVs) were not detected in the benign skin lesions of a small number of children

I Mammás<sup>1</sup>, G Sourvinos<sup>1</sup>, C Michael<sup>2</sup>, DA Spandidos (spandidos@spandidos.gr)<sup>1</sup>

1.Department of Virology, School of Medicine, University of Crete, Crete, Greece  
2.Department of Pathology, 'Agliaia Kyriakou' Children's Hospital, Athens, Greece

## Keywords

Children, 'High-risk' HPVs, HPV 16, HPV 18, Human papilloma virus (HPV), Skin

## Correspondence

D. A. Spandidos, Laboratory of Virology, School of Medicine, University of Crete, Crete, Greece.  
Tel: +30-210-7227809 |  
Fax: +30-210-7252922 |  
Email: spandidos@spandidos.gr

## Received

14 May 2008; revised 23 July 2008;  
accepted 29 July 2008.

DOI:10.1111/j.1651-2227.2008.01004.x

## Abstract

**Aim:** Human papilloma virus (HPV) can be transmitted via sexual as well as nonsexual routes. Recently, 'high-risk' HPVs were detected in the oral mucosa of children in whose cases there was no suspicion of sexual abuse. This implies that HPV 16 and 18 have additional nonsexual modes of transmission in childhood, such as vertical transmission and autoinoculation.  
**Methods:** Using polymerase chain reaction (PCR) assays, we examined the skin tissues of 12 children with benign skin lesions, aged between 6 and 13 years, for the presence of HPV.  
**Results:** Among 12 biopsy skin specimens, no 'high-risk' HPV DNA was detected. Specific PCRs for HPV DNA 16 and 18 were also negative.

**Conclusion:** This preliminary case-control study indicates the absence of mucosal 'high-risk' HPV types in the benign skin lesions of children.

## INTRODUCTION

Vaccines against human papilloma virus (HPV) have recently been introduced to the national vaccination programmes of several countries (1). HPV is considered to be the principal cause of cervical cancer in adulthood (2–4). In childhood, it causes a wide range of epithelial infections including different types of skin warts, anogenital warts and recurrent respiratory papillomatosis, which is a life-threatening condition in children (2–4). To date, over 130 different types of HPV have been identified, each type having less than 90% of its nucleotide sequence in common with the others (5).

HPVs can be classified into cutaneous and mucosal types. Cutaneous types infect the squamous epithelium of the skin and produce common warts, plantar warts and flat warts, which commonly occur on the hands, face and feet. Specific cutaneous types are also detected in epidermodysplasia verruciformis (EV) (6), a rare familial disorder related to the development of large cutaneous warts that can progress to skin cancer.

Mucosal HPVs infect the mucous membranes and can cause cervical neoplasia in adults as well as anogenital warts in both children and adults. 'High-risk' mucosal types HPV 16 and 18 are detected in over 70% of women with cervical carcinoma and represent the 'high-risk' types most frequently detected in the female anogenital system (7). 'High-risk' and 'low-risk' mucosal HPVs have also been involved in the development of squamous intraepithelial lesions (SILs) (4).

In the anogenital warts of children, both cutaneous and mucosal HPVs can be present; of the mucosal type, HPVs 11 and 6 are the most frequently detected (2,8–10). Among nonsexually abused children with anogenital warts, cutaneous types are more common in older children above the

age of 4 years, in children with a relative affected by skin warts and in children with skin warts elsewhere (9). In contrast, mucosal types are more common in girls, in children under 3 years of age, in children with relatives with genital warts and in children without warts elsewhere. Mucosal types 11 and 6 have also been implicated in the pathogenesis of recurrent respiratory papillomatosis (RRP) in children (11,12). Patients with RRP infected with HPV 11 are prone to developing more aggressive disease, and more frequently require surgical intervention.

The aim of this study was to evaluate the presence of mucosal HPVs in the skin lesions of children. To date, data on the presence of HPV in the healthy skin or skin with benign lesions of children are limited. In this study, we sought to provide further confirmation of possible nonsexual modes of mucosal HPV transmission by examining the presence of mucosal types of HPV in the skin lesions of children.

## SUBJECTS AND METHODS

Paraffin-embedded skin biopsy tissues from 12 children with benign skin lesions treated at the 'Agliaia Kyriakou' Children's Hospital in Athens, Greece, between 1995 and 2002 were examined. Histological analysis of the material was performed at the Department of Pathology of the same hospital.

DNA was extracted and stored at  $-20^{\circ}\text{C}$  (13). DNA purity was assessed by a UV/VIS spectrophotometer estimating the  $A_{260}/A_{280}$  ratio and titrated to  $200\ \mu\text{g}/\text{mL}$ . The presence of amplifiable DNA was verified by polymerase chain reaction (PCR) using primers specific for b2-microglobulin. HPV DNA was detected using PCR with the general primers GP5+ and GP6+ (14). The extracted DNA ( $1\ \mu\text{L}$ ) of each sample was amplified in a total volume of  $30\ \mu\text{L}$  containing  $5\ \mu\text{M}$  of  $10\times$  PCR reaction buffer ( $200\ \text{Mm}$  Tris-HCl pH

8.4, 500 mM KCl), 1.5 mM MgCl<sub>2</sub>, 200 μM of each dNTP, 0.5 μM of each primer and 0.6 U of recombinant Taq DNA polymerase (Invitrogen Ltd., Carlsbad, CA, USA). As a positive control, we used DNA extracted from a human biopsy HPV-positive sample from a patient with cervical cancer.

In order to distinguish the different HPV types, we used separate specific pairs of primers for HPV virus types 16 and 18, resulting in different lengths of amplified DNA. The extracted DNA (1 μL) of each sample was amplified in a total volume of 20 μL containing 10× PCR reaction buffer, 1.5 mM MgCl<sub>2</sub>, 200 μM of each dNTP, 0.5 μM of each primer (sense and antisense) and 0.8 U of recombinant Taq DNA polymerase (Invitrogen Ltd.). All PCR products were analysed on 2% agarose gel and photographed on a UV light transilluminator. PCR assay was carried out using a PTC-200 programmable thermal controller (MJ Research Inc., Waltham, MA, USA). All PCR reactions included appropriate negative controls. DNA extracted from HeLa cells and the plasmid DNA of HPV 16 and 18 were used as positive controls. The amplification conditions and primers used have been previously described (14).

## RESULTS

We studied skin biopsy specimens from 12 children including 3 girls and 9 boys (Table 1). The mean age of our study population was 8.2 years (SD 2.6 years), ranging between 6 and 13 years. Five of the 12 specimens were diagnosed as warts, while in 7 the histological analysis proved normal. Skin specimens originated from the face in 3 children, the trunk in 2, the hands in 2 and the feet in 5 children. Table 1 presents the clinicopathological characteristics of the samples as well as the results of HPV detection and typing. No mucosal HPV DNA was detected in any of the specimens studied (Fig. 1). Specific PCRs for 'high-risk' HPV DNA 16 and 18 were also negative.

## DISCUSSION

To our knowledge, this is the first study to evaluate the presence of 'high-risk' mucosal HPVs in biopsies of the skin lesions of Greek children. Of the 12 skin specimens analysed, no 'high-risk' HPV DNA was detected. Specific PCRs for HPV DNA 16 and 18 were also negative. Our findings indicate the absence of mucosal 'high-risk' HPV types in the benign skin lesions of children.

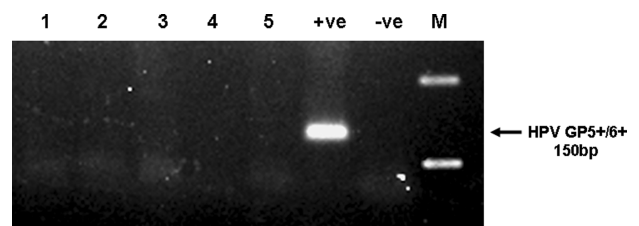
In healthy skin, cutaneous HPV types are frequently found and can commonly persist over several years (15). Specific cutaneous EV-HPV types are present in epidermodysplasia verruciformis, a skin lesion associated with an increased risk of nonmelanoma skin cancer (16). Though cutaneous HPVs are predominantly detected in patients with warts, the presence of mucosal HPVs has also been reported (17,18). Chen et al. studied 61 specimens of skin warts, detecting cutaneous HPV1, 2, 3 and 4 most frequently (17). In a study by Porro et al., cutaneous HPV 2, 27 and 57 were predominately detected in the skin warts of HIV-infected and immunocompetent individuals (18). In the same study, mucosal HPV 6 was detected in two of 25 warts from HIV-infected patients,

**Table 1** Clinicopathological characteristics of the samples and the results of HPV detection and typing

Patient	Anatomical site	Histology	Age	'High-risk' HPV	HPV 16	HPV 18
1	Foot	Normal skin	11	0	0	0
2	Hand	Wart	8	0	0	0
3	Foot	Wart	9	0	0	0
4	Trunk	Normal skin	10	0	0	0
5	Face	Normal skin	7	0	0	0
6	Face	Wart	6	0	0	0
7	Foot	Wart	13	0	0	0
8	Trunk	Normal skin	11	0	0	0
9	Foot	Normal skin	12	0	0	0
10	Foot	Normal skin	9	0	0	0
11	Face	Wart	12	0	0	0
12	Hand	Normal skin	8	0	0	0

Groups	Categories	Rate (%)
Patients	Boys	9/12 (75)
	Girls	3/12 (25)
Age	6–10 years	6/12 (50)
	11–14 years	6/12 (50)
Anatomical site	Face	3/12 (25)
	Trunk	2/12 (16.7)
	Hand	2/12 (16.7)
	Foot	5/12 (41.7)
Histology	Normal skin	7/12 (58.3)
	Wart	4/12 (33.3)
	Other	1/12 (8.3)
HPV status	'High-risk' HPV	0/12 (0)
	HPV 16	0/12 (0)
	HPV 18	0/12 (0)



**Figure 1** Representative examples of HPV-negative samples tested by PCR using general primers (GP5 ± 6 +). +ve = HPV-positive control from cervical cancer; -ve = HPV-negative control; M = 100 bp DNA ladder.

and in one lesion of 14 obtained from immunocompetent patients. Interestingly, in the study by Chen et al., 'high-risk' mucosal HPVs 16 and 18 were detected in 2% and 8% of the studied skin warts, while HPV 11 was detected in 5% (17).

Modes of HPV transmission in childhood remain controversial. Although sexual contact is a possible cause, other

pathways seem to be more likely, including perinatal transmission, autoinoculation and heteroinoculation, and possibly indirect transmission via fomites (2–4,8). In our study, there was no evidence of the presence of 'high-risk' mucosal HPVs in the skin lesions examined. This finding is of great significance, as the presence of 'high-risk' mucosal HPVs in skin samples from children would implicate autoinoculation or heteroinoculation as possible modes of HPV transmission in children.

Recent studies have shown that 'high-risk' mucosal HPVs are detected in 4–15% of genital scrape samples and in 12–21% of oral scrape samples obtained from infants (19). The rates of carriage decrease during the first year of life, though HPV DNA is still detectable in 10% of mucosal samples and in 1.5% of genital samples at 3 years of age. 'High-risk' mucosal HPV 16 seroprevalence in children has been found to range between 0% and 7.6% (20,21). Age over 7 years has been associated with a significantly higher prevalence of antibodies to HPV 16 (20). Infants born to women positive for antibodies to HPV 16 were not at a significantly higher risk of HPV 16 infection than those born to women negative for the antibodies (21). These findings suggest that exposure to 'high-risk' mucosal HPVs increases with increasing age.

Recently, mucosal HPVs 16 and 11 were detected in the oral cavities of children who had undergone a tonsillectomy or adenoidectomy (14,22,23). Detection of mucosal HPV infection in the buccal cavity of healthy children has raised further questions concerning modes of HPV transmission in the oral cavity of children. It has been proposed that the presence of HPV DNA in the oral cavity of children is a transitory event, with reinfection occurring via their peers (22). 'High-risk' mucosal HPVs are not detected in children's skin lesions, implicating the mucosa of the oral cavity as a unique reservoir of 'high-risk' mucosal HPV infection in childhood (14,23). The exact natural history of HPV and its possible modes of transmission remain to be clarified. Doing so will help to answer questions that have recently been raised regarding the age at which HPV vaccination should be initiated in childhood, as well as the necessity of vaccinating both boys and girls.

## References

- Raffle A. Challenges of implementing human papillomavirus (HPV) vaccination policy. *BMJ* 2007; 335: 375–7.
- Armstrong DK, Handley JM. Anogenital warts in prepubertal children: pathogenesis, HPV typing and management. *Int J STD AIDS* 1997; 8: 78–81.
- Syrjanen S, Pyranen M. Human papillomavirus infections in children: the potential role of maternal transmission. *Crit Rev Oral Biol Med* 2000; 11: 259–74.
- Zur Hausen H. Papillomaviruses and cancer: from basic studies to clinical application. *Nat Rev Cancer* 2002; 2: 342–50.
- Chan SY, Delius H, Halpern L, Bernard HU. Analysis of genomic sequences of 95 papillomavirus types: uniting typing, phylogeny, and taxonomy. *J Virol* 1995; 69: 3074–83.
- Majewski S, Jablonska S. Epidermodysplasia verruciformis as a model of human papillomavirus induced genetic cancer of the skin. *Arch Dermatol* 1995; 131: 1312–8.
- Clifford GM, Smith JS, Plummer M, Munoz N, Franceschi S. Human papillomavirus types in invasive cervical cancer worldwide: a meta-analysis. *Br J Cancer* 2003; 88: 63–73.
- Myhre AK, Dalen A, Berntzen K, Bratlid D. Anogenital human papillomavirus in non-abused preschool children. *Acta Paediatr* 2003; 92: 1445–52.
- Padel AF, Venning VA, Evans MF, Quantrill AM, Fleming KA. Human papillomaviruses in anogenital warts in children: typing by in situ hybridisation. *BMJ* 1990; 300: 1491–4.
- Obalek S, Misiewicz J, Jablonska S, Favre M, Orth G. Childhood condyloma acuminatum: association with genital and cutaneous human papillomaviruses. *Pediatr Dermatol* 1993; 10: 101–6.
- Rimell FL, Shoemaker DL, Pou AM, Jordan JA, Post JC, Ehrlich GD. Pediatric respiratory papillomatosis: prognostic role of viral typing and cofactors. *Laryngoscope* 1997; 107: 915–8.
- Rabah R, Lancaster WD, Thomas R, Gregoire L. Human papillomavirus-11-associated recurrent respiratory papillomatosis is more aggressive than human papillomavirus-6-associated disease. *Pediatr Dev Pathol* 2001; 4: 68–72.
- Noutsou A, Koffa M, Ergazaki M, Sifakas N, Spandidos D. Detection of human papilloma virus (HPV) and K-ras mutations in human lung carcinomas. *Int J Oncol* 1996; 8: 1089–93.
- Mammas I, Sourvinos G, Michael C, Spandidos D. Human papilloma virus in hyperplastic tonsillar and adenoid tissues in children. *Pediatr Infect Dis J* 2006; 25: 1158–62.
- Hazard K, Karlsson A, Andersson K, Ekberg H, Dillner J, Forslund O. Cutaneous human papillomaviruses persist on healthy skin. *J Invest Dermatol* 2007; 127: 116–9.
- Harwood CA, Suretheran T, Sasieni P, Proby CM, Bordea C, Leigh IM, et al. Increased risk of skin cancer associated with the presence of epidermodysplasia verruciformis human papillomavirus types in normal skin. *Br J Dermatol* 2004; 150: 949–57.
- Chen SL, Tsao YP, Lee JW, Sheu WC, Liu YT. Characterization and analysis of human papillomaviruses of skin warts. *Arch Dermatol Res* 1993; 285: 460–5.
- Porro AM, Alchorne MM, Mota GR, Michalany N, Pignatary AC, Souza IE. Detection and typing of human papillomavirus in cutaneous warts of patients infected with human immunodeficiency virus type 1. *Br J Dermatol* 2003; 149: 1192–9.
- Rintana M, Grenman S, Jarvenkyla ME, Syrjanen KJ, Syrjanen SM. High-risk types of human papillomavirus (HPV) DNA in oral and genital mucosa of infants during their first 3 years of life: experience from the Finnish HPV Family Study. *Clin Infect Dis* 2005; 41: 1728–33.
- Dunne E, Karem K, Sternberg M, Stone K, Unger E, Reeves W, et al. Seroprevalence of human papillomavirus type 16 in children. *J Infect Dis* 2005; 191: 1817–9.
- Manns A, Strickler HD, Wiiktor SZ, Pate EJ, Gray R, Waters D. Low incidence of human papillomavirus type 16 antibody seroconversion in young children. *Pediatr Infect Dis J* 1999; 18: 833–5.
- Mant C, Kell B, Rice P, Best JM, Bible JM, Cason J. Buccal exposure to human papillomavirus type 16 is a common yet transitory event of childhood. *J Med Virology* 2003; 71: 593–8.
- Smith EM, Swarnavel S, Ritchie JM, Wang D, Haugen TH, Turek LP. Prevalence of human papillomavirus in the oral cavity/oropharynx in a large population of children and adolescents. *Pediatr Infect Dis J* 2007; 26: 836–40.