SPANDIDOS PUBLICATIONS

BIOMEDICAL REPORTS 20: 17, 2024

Granulomatous mastitis masking ductal carcinoma *in situ*: A case report with literature review

ABDULWAHID M. SALIH[1,2], LANA R.A. PSHTIWAN[2], ARI M. ABDULLAH[2,3], HARDI M. DHAHIR[2], HALKAWT OMER ALI[2], ASO S. MUHIALDEEN[2,4], BUSHRA O. HUSSEIN[2], SHKO H. HASSAN[2] and FAHMI H. KAKAMAD[1,2,4]

[1]College of Medicine, University of Sulaymaniyah; [2]Smart Health Tower, Scientific Affairs Department; [3]Department of Pathology, Sulaymaniyah Teaching Hospital; [4]Kscien Organization for Scientific Research, Sulaymaniyah, Kurdistan 46001, Republic of Iraq

Received September 3, 2023; Accepted November 2, 2023

DOI: 10.3892/br.2023.1705

Abstract. Granulomatous mastitis (GM) is a rare inflammatory disorder that infrequently occurs with synchronous breast carcinoma. The present study reports the case of a patient who was initially diagnosed with recurrent GM, which eventually proved to be masking an underlying ductal carcinoma *in situ* (DCIS). A 30-year-old female presented with left breast pain. On clinical examination, there was a large, palpable and painful lump in the left breast, with axillary lymphadenopathy. Initially, the diagnosis was GM and conservative treatment was applied. Surgical resection was decided upon for the condition after it became recurrent, and the histopathological examination revealed extensive DCIS with GM. Later on, the patient underwent a mastectomy with an axillary sentinel lymph node biopsy. The postoperative follow-up was uneventful. In conclusion, tissue diagnosis has a key role in detecting DCIS masked by GM, especially in young females who are not undergoing regular mammogram screening. The present study shows the challenge that the specialists in this field may face when dealing with recurrent GM of the breast, and warns them to search for a second pathology such as the DCIS presented in the current case.

Introduction

Breast diseases encompass a wide spectrum of inflammatory, benign and malignant conditions. However, sometimes malignant lesions may arise from benign ones, or these conditions may mimic or mask one another, presenting clinicians with intricate diagnostic and management challenges (1). Granulomatous mastitis (GM) is a rare inflammatory condition of the breasts with an unknown etiology, with an estimated incidence of 2.4 per 100,000 women (2). This infrequent non-malignant disease typically impacts women during their childbearing years, with a higher incidence in some Middle Eastern countries such as Iran and Turkey (3). The primary feature of the condition is non-caseous granulomatous inflammation located near the ducts and lobules of the breast (4,5). Ductal carcinoma *in situ* (DCIS) is the pre-cancerous stage of breast cancer, and it refers to an abnormal growth of luminal cells restricted to the ductal-lobular system of the breast (6,7). Before the development of breast screening, DCIS was rarely diagnosed (7); it used to account for only 1-2% of newly diagnosed breast cancer cases, but more recently, the rate has markedly increased to 20-30% (8-10). Through penetration of the ductal basement membrane and invasion of the surrounding tissues, DCIS can transform into invasive breast cancer (7). Synchronous presentation of carcinoma *in situ* with GM is an extremely rare phenomenon, with only a few cases being reported in the literature (11-13).

The present study reports an intriguing case of a 30-year-old lactating woman who was initially diagnosed with recurrent GM, which eventually proved to be masking an underlying DCIS.

Case report

Patient information. A 30-year-old woman presented to the Breast Clinic at Smart Health Tower (Sulaymaniyah, Iraq) on December 2022 with left breast pain that had persisted for 7 days. The patient had three children and had experienced one miscarriage. The patient was currently lactating due to a newborn child and had lactated from the right breast for a total of 4 years and 3 months. A paternal aunt had been diagnosed with breast cancer when in her forties and was still alive. The patient stated that she had undergone an operation for resection of a left axillary mass in 2013 and that the histopathological examination (HPE) was benign. Other than a history of using anti-inflammatory medication, the patient had no other notable medical history, no oral contraceptive use and no history of smoking.

Correspondence to: Dr Fahmi H. Kakamad, College of Medicine, University of Sulaymaniyah, Doctor City, Building 11, Apartment 50, Shorsh Street, Sulaymaniyah, Kurdistan 46001, Republic of Iraq
E-mail: fahmi.hussein@univsul.edu.iq

Key words: idiopathic granulomatous mastitis, breast cancer, synchronous, concurrent, carcinoma *in situ*

The first presentation to the same breast clinic mentioned with lumps and swelling at the same site dates back to December 2020. Investigations such as breast ultrasound (US) examination were performed. The patient had a painful lump, swelling and axillary lymphadenopathy, and the US finding showed a large collection of unknown fluid with surrounding inflammation, and an inverted nipple with associated axillary nodal enlargement. The patient was clinically diagnosed with GM and underwent conservative management with antibiotics, steroids and methotrexate as follows: 500 mg ciprofloxacin twice per day orally for 5 days, 20 mg prednisolone daily orally for 7 days and 2.5 mg methotrexate twice per day orally for 7 days. On December 2020 (7 days post presentation), the patient returned to the clinic. The antibiotic was stopped, the methotrexate dose was tapered (2.5 mg daily for 30 days) and the prednisolone was continued at the same dose. On January 2021, a new US examination showed multiple collections on the skin and decrease of the inflamed tissue next to the skin surface, showing regression of the disease; therefore, drainage was performed for the breast collection under local anesthesia, with a prescription of prednisolone (20 mg daily for 20 days). After ~20 days, in January 2021, the disease responded to the medications and an almost total response was achieved. Tapering of the prednisolone was started (10 mg daily for 1 week, 5 mg daily for 1 week and then 5 mg on alternative days for 1 week) and a 3-month follow-up was advised. The patient returned in June 2021 and US results showed only marks of old mastitis; therefore, a 1-year follow-up was advised. In June 2022, when the patient came back in the first trimester of pregnancy, a breast US examination showed the same result as that on the last visit, hence the patient was advised to come back after delivery, which is when presentations of the disease were once again apparent.

Clinical findings. On clinical examination, there was a large, palpable and painful lump in the left breast with axillary lymphadenopathy associated with localized swelling of the lower part of the breast.

Diagnostic assessment. Breast US showed a full-length ectatic duct from the nipple root toward the 5-7 o'clock position, with a heterogenous internal echo associated with mild surrounding edema and reactive axillary lymph nodes. This was suggestive of the recurrence of GM.

Therapeutic intervention. Surgical resection was decided upon due to the recurrence of GM at the same site that was refractory to therapy. Following a preoperative assessment, under general anesthesia, excision of the left breast lump was performed using a 10-cm radial elliptical incision, a corrugate drain was put in and the wound was closed in layers. The surgical specimen was marked with stitches and sent for HPE (Data S1). The HPE revealed extensive DCIS with apocrine features without invasion (Fig. 1), while other pathological findings included lactational changes, acute suppurative GM with abscess formation and fat necrosis (Fig. 2). The pathological staging from the Tumor-Node-Metastasis staging system was pTisNx (14).

Following breast multidisciplinary team (MDT) recommendations, additional investigations such as mammography (MMG) and magnetic resonance imaging (MRI) were performed. The MMG of the right breast showed only a solitary benign-looking calcification, while that of the upper outer quadrant of the left breast showed an operative bed deformity with trabecular thickening, associated with regional skin thickening. Additionally, in the central part of the left breast, at mid-depth, below the scar line, there were two rounded scattered faint micro-calcifications; the breast imaging-reporting and data system (BI-RADS) score (15) was M2 bilaterally. Breast MRI revealed a clumped focal non-mass-like enhancement measuring 20x6 mm within a focally ecstatic duct in the left breast and other smaller borderline foci measuring 4-5 m. The collective measurements were 60x50 mm, with a BI-RADS score of MR-4. In addition, in the surgical bed, there was a focal heterogenous non-mass-like enhancement measuring 19x13 mm and ending 12 mm from the pectoralis major muscle. Both axillae were clear and no suspicious lymph nodes were apparent radiologically.

The investigation results were presented again in another MDT session, and the decision was made to perform a revision of the left breast surgical bed in the form of a simple mastectomy, with axillary sentinel lymph node biopsy (SLNB) and right breast-wide local excision (WLE) of the non-mass-like enhancement after marking on the skin. A left-sided mastectomy was performed by Stewart incision with axillary SLNB after methyline blue dye injection. The right breast WLE of the marked area on the skin was performed using a crescent incision; both wounds were closed in layers, and the sample was again sent for HPE. For the left breast, the HPE report showed no residual invasive tumor, no carcinoma *in situ*, tumor-free excised axillary lymph nodes and N0 pathological staging. The report of the right breast showed only benign non-proliferative fibrocystic changes, duct ectasia with stromal fibrosis and no malignancy. The immunohistochemical (IHC) study of estrogen receptor expression showed positive staining with a score of 8 in the Allred scoring system (16), supporting the DCIS component (Fig. 3) (Data S1).

Follow-up. The postoperative period was uneventful after both surgical sessions. The patient was referred to an oncologist for further management. Adjuvant hormone therapy using tamoxifen (20 mg, 1*1) was initiated for 5 years, and after 6 months, follow-up by breast US was performed, with an annual MMG and MRI recommended if indicated. Genetic testing was offered by the oncologist but the patient refused it due to the cost. The patient remained free of disease for 6 months after the surgical procedure and the last follow-up was in September 2023.

Discussion

DCIS is an unusual proliferation of the epithelial cells of the mammary ducts without movement into other parts of the breast parenchyma (17). DCIS is surrounded by an intact basement membrane and bordered by a layer of semi-continuous myoepithelial cells (18). Among the benign chronic inflammatory breast diseases, such as periductal mastitis and lactational mastitis (19), GM is the least common and has an unclear etiology; it is characterized by the formation of a non-caseating granuloma, with an abscess and the presence of lymphocytes, multi-nucleated giant cells, plasma cells and epithelioid histiocytes (17,20).

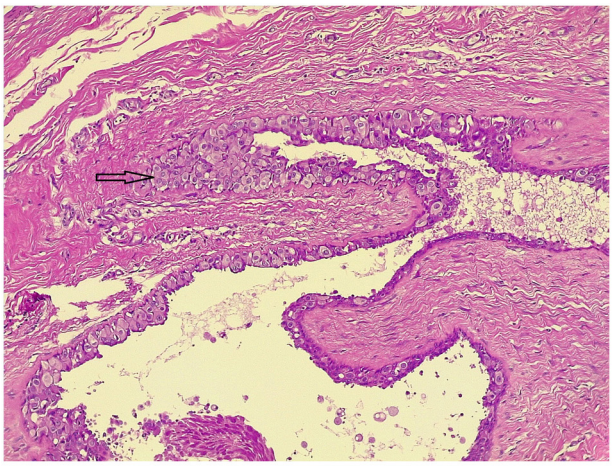

Figure 1. High grade ductal carcinoma *in situ* (black arrow) (hematoxylin and eosin staining; magnification, x40).

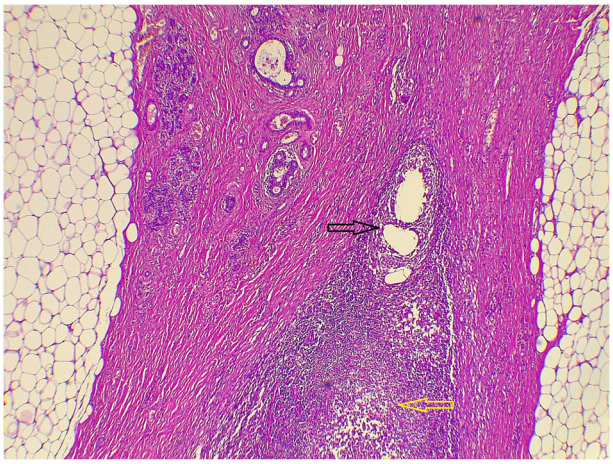

Figure 2. Well-formed epithelioid granuloma (black arrow) with an area of suppurative necrosis (yellow arrow) (hematoxylin and eosin staining; magnification, x40).

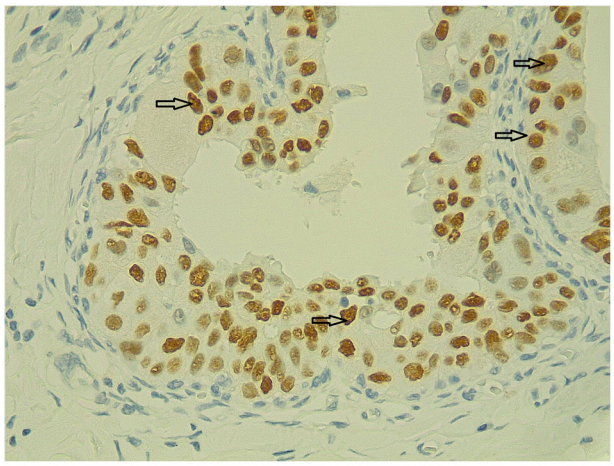

Figure 3. Strong and diffuse nuclear staining pattern for estrogen receptor (black arrows).

In 1972, Kessler and Wolloch (18) reported the first case of GM and stated that it can be confused with breast cancer, since the diseases share similarities in clinical signs and presentations, such as lumps, pain, swelling, skin changes, abscesses, ulcerations, sinus tracts and fistulas, in severe or chronic patients, and are sometimes associated with axillary lymphadenopathy. By contrast, DCIS is rarely symptomatic or palpable clinically (21). In some instances, patients have been clinically diasgnosed with breast cancer, leading to a complete mastectomy and lymph node removal, only to later discover through pathological analysis that they actually had GM (18). Furthermore, there have been uncommon cases of individuals first diagnosed with GM and managed non-invasively, who were then discovered to have breast cancer after surgical intervention due to no significant improvement in their condition (22). Only in rare instances, has the literature reported concurrent GM and carcinoma in the same breast (11-13).

The reason behind the development of DCIS from normal breast tissue is unknown; genetic predisposition plays a role, not in all, but in some patients who have BRCA1 DNA repair associated (BRCA1) and BRCA2 mutations (23). Some studies have shown that there are other risk factors, such as being 35 years of age or older, ethnicity, nulliparity or pregnancy at an older age, dense breasts and a family history of breast cancer, especially in first-degree relations. Other studies have investigated the relationship between the incidence of DCIS and behavioral risk factors, such as the use of nonsteroidal anti-inflammatory medications, aspirin, alcohol, smoking, physical activity and the intake of dietary β-carotene (24-26). Moreover, the pathogenesis of GM has also not been determined and scholars have different hypotheses regarding the mechanisms involved, for instance: i) Autoimmunity, since GM has a significant response to immunosuppressants such as steroids and methotrexate; ii) infections, even though the exact pathogenic bacteria have not been discovered yet; and iii) hormonal disorders, where hyperprolactinemia seems to act as a triggering factor (23). Inflammation has been linked to increased cancer risk and death (27,28). In cohort studies with a large population size, Lambe *et al* (29) and Chen *et al* (30) reported that women with a history of mastitis had a significantly higher risk of developing breast cancer ($P<0.001$). In an analysis of genetic polymorphisms in breast cancer and GM, gene mutations in the methylenetetrahydrofolate reductase C677T variant, plasminogen activator inhibitor 1 and angiotensin I converting enzyme were discovered (31). In another study of series of three GM cases in 2021, 12,115 mRNAs were analyzed from GM and normal tissues, and GM was found to be enriched in genes that were significantly highly expressed in breast cancer tissues (32). After a review of the literature, no association was found between BRCA1 or BRCA2 gene mutation and GM.

The current study presents the case of a patient with a synchronous diagnosis of GM and DCIS. The patient had a second-degree family history of breast cancer and a history of using anti-inflammatory medication. Similar to the patients in most of the concurrent GM and breast cancer cases, the current patient was also of reproductive age. In a study by Özşen *et al* (11), a similar 35-year-old woman presented with swelling in the right breast. Via core needle biopsy, the patient was initially diagnosed with GM; however, a later excisional surgery was performed, as the patient lacked a proper response

to treatment, which resulted in a diagnosis of DCIS after a second HPE and IHC examination. Oddó *et al* (12) presented the case of another 44-year-old woman with painful swelling in the left breast. The patient was diagnosed with GM, but did not respond to any of the provided antibiotics. A biopsy was performed, which again showed GM with DCIS. The study by Tavakol *et al* (13), which is the last concurrent case report at the time of the present study, reported the case of a 35-year-old female presenting with pain and a lump in the right breast. A core needle biopsy showed lobular carcinoma *in situ* and GM, and the patient was treated (prednisolone, nonsteroidal anti-inflammatory drugs and hydroxychloroquine) and kept on follow-up (13). In the present study, as well as the aforementioned studies, both GM and breast carcinoma were found in the same breast. However, it is still feasible to have GM present in one breast and carcinoma in the other breast (33).

The only approach for a definite diagnosis of GM is tissue diagnosis to exclude other pathologies, such as breast carcinoma (34). DCIS can be easily detected by MMG since ~75% of DCIS lesions contain calcifications, but the other 25% can be underestimated by MMG, so the procedure should be followed by a tissue biopsy for a definite diagnosis (7). For the current case, a tissue biopsy was obtained after the first presentation in 2020, and the HPE result was GM. As the site was the same as the previous pathology, a tissue biopsy was not taken again after the last presentation, with the assumption of reccurrence.

Scientists and clinicians have always been intrigued by the connection between inflammation and cancer. Inflammation may be a result of infection or autoimmune diseases, but the precise biological link between GM and malignant lesions remains unclear due to the limited number of case studies. Long-term inflammation causing DNA damage is one of the key causes of malignancy. Other possible causes include DNA methylation, abnormal regulation of microRNA, and the presence of common genes involved in both autoimmunity and cancer development (13,35).

Treatment options for GM vary due to a vague etiology, including surgical management (drainage, excision and mastectomy), close observation, antibiotics, immunosuppressants and anti-inflammatory medications (20). For patients diagnosed with DCIS, a combination of surgery, radiation and endocrine therapy is used accordingly (36). Multiple treatment plans, including antibiotics, anti-inflammatory drugs, immunosuppressants, drainage and surgical excision, were used for the current case during chronic presentations on follow-up examination. The final decision after full investigations and confirmation of both diseases was to perform a mastectomy with axillary SLNB.

In conclusion, the present case demonstrates the challenges associated with identifying and diagnosing breast cancer in a patient with recurrent GM or a previous history of GM, making the presence of GM a key alert for surgeons to search for secondary pathologies. The question of whether GM can lead to the development of cancer remains debatable unless even more cases are encountered and further research establishes a connection between breast cancer and GM.

Acknowledgements

Not applicable.

Funding

No funding was received.

Availability of data and materials

Not applicable.

Authors' contributions

SHH was responsible for the data collection, follow up of the patient and final approval of the manuscript. AMS was a major contributor to the conception of the study, as well as in the literature search for related studies. LRAP was the radiologist who performed the assessment of the GM. AMA was the pathologist who perfomed the histopathological diagnosis. HMD and HOA were involved in the literature review, the design of the study and the critical revision of the manuscript. FHK, BOH and ASM were involved in the literature review, the writing of the manuscript, and the data analysis and interpretation. BOH and FHK confirm the authenticity of all the raw data. All authors have read and approved the final manuscript.

Ethics approval and consent to participate

Written informed consent was obtained from the patient for participation in the present study.

Patient consent for publication

Written informed consent was obtained from the patient for the publication of the present case report and any accompanying images.

Competing interests

The authors declare that they have no competing interests.

References

1. Salih AM, Pshtiwan LR, Abdullah AM, Qaradakhy AJ, Kakamad FH, Ali HO, Salih KM, Rahim HM, Abdalla BA, Hassan MN and Mohammed SH: Carcinoma arising from fibroadenoma; presentation and management; a case series. Barw Med J 1: 1-28, 2023.
2. Bacon DR, Ngeve SM and Jordan SG: Granulomatous mastitis: An underdiagnosed inflammatory disease afflicting minority women. Radiol Case Rep 16: 3990-3994, 2021.
3. Martinez-Ramos D, Simon-Monterde L, Suelves-Piqueres C, Queralt-Martin R, Granel-Villach L, Laguna-Sastre JM, Nicolau MJ and Escrig-Sos J: Idiopathic granulomatous mastitis: A systematic review of 3060 patients. Breast J 25: 1245-1250, 2019.
4. Esmaeil NK, Salih AM, Hammood ZD, Pshtiwan LR, Abdullah AM, Kakamad FH, Abdullah HO, Ahmed GS, Abdalla BA and Salih RQ: Clinical, microbiological, immunological and hormonal profiles of patients with granulomatous mastitis. Biomed Rep 18: 41, 2023.
5. Esmaeil NK, Salih AM, Pshtiwan LR, Muhialdeen AS, Abdullah AM, Hama JI, Hammood ZD, Kakamad FH, Tahir SH, Abdalla BA, *et al*: Management of idiopathic granulomatous mastitis: A single institution experience. Breast Care (Basel) 18: 231-238, 2023.
6. Mahmood ZH, Mohemed FM, Fatih BN, Qadir AA and Abdalla SH: Cancer publications in one year (2022); a cross-sectional study. Barw Med J 1, 2023.

7. Van Seijen M, Lips EH, Thompson AM, Nik-Zainal S, Futreal A, Hwang ES, Verschuur E, Lane J, Jonkers J, Rea DW, *et al*: Ductal carcinoma in situ: To treat or not to treat, that is the question. Br J Cancer 121: 285-292, 2019.
8. Allred DC: Ductal carcinoma in situ: Terminology, classification, and natural history. J Natl Cancer Inst Monogr 2010: 134-138, 2010.
9. Ward EM, DeSantis CE, Lin CC, Kramer JL, Jemal A, Kohler B, Brawley OW and Gansler T: Cancer statistics: Breast cancer in situ. CA Cancer J Clin 65: 481-495, 2015.
10. Ryser MD, Hendrix LH, Worni M, Liu Y, Hyslop T and Hwang ES: Incidence of ductal carcinoma in situ in the United States, 2000-2014. Cancer Epidemiol Biomarkers Prev 28: 1316-1323, 2019.
11. Özşen M, Tolunay Ş and Gökgöz MŞ: Case report: Ductal carcinoma in situ within a granulomatous mastitis. Eur J Breast Health 14: 186-188, 2018.
12. Oddó D, Domínguez F, Gómez N, Méndez GP and Navarro ME: Granulomatous lobular mastitis associated with ductal carcinoma in situ of the breast. SAGE Open Med Case Rep 7: 2050313X19836583, 2019.
13. Tavakol M, Alvand S, Azmoudeh Ardalan F and Assarian A: Idiopathic granulomatous mastitis with incidental lobular carcinoma in situ: A case report. Arch Breast Cancer 9: 315-319, 2022.
14. Rami-Porta R, Bolejack V and Goldstraw P: The new tumor, node, and metastasis staging system. Semin Respir Crit Care Med 32: 44-51, 2011.
15. Balleyguier C, Ayadi S, Van Nguyen K, Vanel D, Dromain C and Sigal R: BIRADS classification in mammography. Eur J Radiol 61: 192-194, 2007.
16. Hammond ME, Hayes DF, Dowsett M, Allred DC, Hagerty KL, Badve S, Fitzgibbons PL, Francis G, Goldstein NS, Hayes M, *et al*: American society of clinical oncology/college of American pathologists guideline recommendations for immunohistochemical testing of estrogen and progesterone receptors in breast cancer (unabridged version). Arch Pathol Lab Med 134: e48-e72, 2010.
17. Benson JR and Dumitru D: Idiopathic granulomatous mastitis: Presentation, investigation and management. Future Oncol 12: 1381-1394, 2016.
18. Kessler E and Wolloch Y: Granulomatous mastitis: A lesion clinically simulating carcinoma. Am J Clin Pathol 58: 642-646, 1972.
19. Scott DM: Inflammatory diseases of the breast. Best Pract Res Clin Obstet Gynaecol 83: 72-87, 2022.
20. Wolfrum A, Kümmel S, Theuerkauf I, Pelz E and Reinisch M: Granulomatous mastitis: A therapeutic and diagnostic challenge. Breast Care (Basel) 13: 413-418, 2018.
21. Kerlikowske K: Epidemiology of ductal carcinoma in situ. J Natl Cancer Inst Monogr 2010: 139-141, 2010.
22. Sakurai T, Oura S, Tanino H, Yoshimasu T, Kokawa Y, Kinoshita T and Okamura Y: A case of granulomatous mastitis mimicking breast carcinoma. Breast Cancer 9: 265-268, 2002.
23. Yin Y, Liu X, Meng Q, Han X, Zhang H and Lv Y: Idiopathic granulomatous mastitis: Etiology, clinical manifestation, diagnosis and treatment. J Invest Surg 35: 709-720, 2022.
24. Virnig BA, Wang SY, Shamilyan T, Kane RL and Tuttle TM: Ductal carcinoma in situ: Risk factors and impact of screening. J Natl Cancer Inst Monogr 2010: 113-116, 2010.
25. Trentham-Dietz A, Newcomb PA, Storer BE and Remington PL: Risk factors for carcinoma in situ of the breast. Cancer Epidemiol Biomarkers Prev 9: 697-703, 2000.
26. Wohlfahrt J, Rank F, Kroman N and Melbye M: A comparison of reproductive risk factors for CIS lesions and invasive breast cancer. Int J Cancer 108: 750-753, 2004.
27. Moore MM, Chua W, Charles KA and Clarke SJ: Inflammation and cancer: Causes and consequences. Clin Pharmacol Ther 87: 504-508, 2010.
28. Morrison L, Laukkanen JA, Ronkainen K, Kurl S, Kauhanen J and Toriola AT: Inflammatory biomarker score and cancer: A population-based prospective cohort study. BMC Cancer 16: 80, 2016.
29. Lambe M, Johansson ALV, Altman D and Eloranta S: Mastitis and the risk of breast cancer. Epidemiology 20: 747-751, 2009.
30. Chen YC, Chan CH, Lim YB, Yang SF, Yeh LT, Wang YH, Chou MC and Yeh CB: Risk of breast cancer in women with mastitis: A retrospective population-based cohort study. Medicina (Kaunas) 56: 372, 2020.
31. Destek S, Gul VO and Ahioglu S: A variety of gene polymorphisms associated with idiopathic granulomatous mastitis. J Surg Case Rep 2016: rjw156, 2016.
32. Zhu Q, Wang L and Wang P: The identification of gene expression profiles associated with granulomatous mastitis. Breast Care (Basel) 16: 319-327, 2021.
33. Kaviani A, Zand S, Karbaksh M and Ardalan FA: Synchronous idiopathic granulomatosis mastitis and breast cancer: A case report and review of literature. Arch Breast Cancer 4: 32-36, 2017.
34. Kiyak G, Dumlu EG, Kilinc I, Tokaç M, Akbaba S, Gurer A, Ozkardes AB and Kilic M: Management of idiopathic granulomatous mastitis: Dilemmas in diagnosis and treatment. BMC Surg 14: 66, 2014.
35. Cappelli LC and Shah AA: The relationships between cancer and autoimmune rheumatic diseases. Best Pract Res Clin Rheumatol 34: 101472, 2020.
36. Mitchell KB and Kuerer H: Ductal carcinoma in situ: Treatment update and current trends. Curr Oncol Rep 17: 48, 2015.