SPANDIDOS PUBLICATIONS

BIOMEDICAL REPORTS 20: 61, 2024

Metastatic gallbladder cancer presenting as numb chin syndrome: A case report and literature review

MAKOTO MURAHASHI[1,2], EDWARD HOSEA NTEGE[1,3], KENTARO IDE[1], NOBUYUKI MARUYAMA[1], JUMPEI SHIRAKAWA[1,4], HIROKI KOYAMA[1], TOSHIHIRO KAWANO[1], TAKAHIRO GOTO[2], YUSUKE SHIMIZU[3], KAZUHIDE NISHIHARA[2] and HIROYUKI NAKAMURA[1]

[1]Department of Oral and Maxillofacial Functional Rehabilitation, Graduate School of Medicine, University of The Ryukyus, Nishihara, Okinawa 903-0215; [2]Department of Oral and Maxillofacial Surgery, Okinawa Red Cross Hospital, Naha, Okinawa 902-8588; [3]Department of Plastic and Reconstructive Surgery, Graduate School of Medicine, University of the Ryukyus, Nishihara, Okinawa 903-0215; [4]Department of Oral and Maxillofacial Surgery, Faculty of Medicine, University of Miyazaki, Kiyotake, Miyazaki 889-1692, Japan

Received August 16, 2023; Accepted December 4, 2023

DOI: 10.3892/br.2024.1749

Abstract. Gallbladder cancer (GBC) is an uncommon malignancy that is highly aggressive in the advanced stages. However, it rarely metastasizes to the mandible. Numb chin syndrome (NCS) is a rare neurological manifestation associated with various underlying causes, including occult primary cancers and distant metastases. It is often considered to be a significant indicator of malignancy, and thorough investigation is essential in the presence of unclear etiology. The current study reported on the case of a 69-year-old Japanese woman who presented with numbness and mild pain in the lower lip and chin area for three months. No other systemic symptoms were observed. Immunocytochemical examination revealed the presence of an adenocarcinoma and TNM staging as per the Union for International Cancer Control and the American Joint Committee on Cancer guidelines confirmed stage IVb GBC. Comprehensive full-body positron emission tomography-computed tomography examination using ^{18}F-fluoro-2-deoxy-D-glucose revealed additional bone and soft-tissue metastases. Palliative chemotherapy and radiation treatment were initiated based on the advanced stage of disease at the time of diagnosis. However, the patient succumbed to multiple organ failure six months later. The simultaneous occurrence of GBC, mandibular metastasis and NCS is rare and associated with poor prognosis. Despite the widespread nature of the disease, it can often manifest as non-specific oral symptoms without any systemic indications. The current study emphasizes the critical importance of timely confirmatory testing for accurate diagnosis and initiation of appropriate management for such complex conditions.

Correspondence to: Dr Edward Hosea Ntege, Department of Plastic and Reconstructive Surgery, Graduate School of Medicine, University of the Ryukyus, 207 Uehara, Nakagami, Nishihara, Okinawa 903-0215, Japan
E-mail: ehntege@gmail.com

Abbreviations: CA19-9, carbohydrate antigen 19-9; CEA, carcinoembryonic antigen; CK, cytokeratin; CRP, C-reactive protein; CT, computerized tomography; GBC, gallbladder cancer; MRI, magnetic resonance imaging; NCS, numb chin syndrome; PET-CT, positron emission tomography-computed tomography; STIR, short-tau inversion recovery

Key words: numb chin syndrome, metastatic gallbladder cancer, mandibular osteomyelitis, oral metastases, pathological fracture, case report

Introduction

In 2020, ~115,949 new cases of gallbladder cancer (GBC) were reported globally (1). GBC is a rare, aggressive and complex disease that mostly originates from the organ's epithelial cells (2,3). The highest incidence rates were observed among indigenous populations in South America, northern India and East Asia, as well as individuals aged 70-74 years (1-3). GBC, while uncommon overall, ranks as the 23rd most prevalent cancer globally. Among men, it holds the same position, while among women, it occupies the 20th space (2). Matsuda and Saika (4) report that in Japan, the incidence of GBC and biliary tract cancers (classified under the International Classification of Diseases version 10 category C23-C24) is 11,641 cases in males and 10,699 in females. The age-standardized incidence rates for these cancers are 5.9 per 100,000 male and 3.6 per 100,000 female individuals. Furthermore, these rates vary with age and geographical region, with the highest incidence being observed in individuals in the seventh and eighth decades of life, as well as those living in the northern regions of the country (5).

The etiology of GBC involves a complex interplay of numerous genetic, epigenetic and environmental risk factors, including gallstones, chronic inflammation, congenital anomalies, obesity and genetic/molecular alterations (6).

Comprehensive diagnosis and management of GBC includes thorough clinical evaluation, imaging, histopathological examination, staging and development of individualized treatment strategies that adopt a multidisciplinary approach (7). Despite significant advancements in treatment, the overall survival rates of GBC remain relatively low, predominantly due to delayed diagnosis, as early-stage lesions that are confined to the gall bladder and have not invaded adjacent structures or metastasized are typically associated with better prognosis (8).

Metastatic tumors in the oral region account for ~1% of all oral malignancies (9). However, while several studies have reported metastasis of primary breast, lung and kidney tumors to this region, there is limited evidence of the spread of GBC (10). Metastasis typically involves a complex series of steps wherein the cancer cells first invade the blood and/or lymphatic vessels before spreading to distant sites, such as the mandible (11).

Numb chin syndrome (NCS) is a rare, sensory neuropathy that affects the mental nerve, leading to unilateral or bilateral altered sensations, decreased sensitivity or absence of pain in the chin and surrounding regions. Perez *et al* (12) recently reported that NCS was associated with various local and systemic etiological factors (summarized in Table I), including primary mandibular tumors or distant metastases of other cancers (13-33). It is commonly observed in association with metastasized breast cancer (32%), lymphoma and leukemia (24%), or prostate cancer (9%), and less frequently observed in association with lung cancer, myeloma, bone cancer, soft-tissue cancer, colon cancer, kidney cancer, adenoid cystic carcinoma, melanoma, skin cancer and digestive cancers such as GBC (13-19). The exact mechanisms underlying NCS remain unclear, although certain studies hypothesized nerve compression or damage as a consequence of tumor infiltration and invasion into the mandibular canal and bone (13,34). Accurate diagnosis of the cause of NCS can be challenging, highlighting the importance of prompt confirmatory testing and timely treatment.

The current study focuses on a rare case of GBC metastasis to the mandible accompanied by NCS. This combination posed significant diagnostic challenges due to its similarity with other mandibular pathologies, and the current case report aims to emphasize the critical significance of timely confirmatory testing to ensure accurate diagnosis and effective management of this complex condition.

Materials and methods

Literature search strategy. Multiple databases, including PubMed (https://pubmed.ncbi.nlm.nih.gov/), Embase (https://www.embase.com/) and Web of Science (https://www.webofscience.com/), were extensively searched for studies examining patients with metastatic GBC or extra biliary tract cancer. The search terms used included 'gallbladder cancer', 'carcinoma of the gallbladder', 'metastatic gallbladder cancer', 'carcinoma to the mandible', 'metastatic gallbladder cancer to the oral and maxillofacial region', 'head and neck metastatic gallbladder cancer' and 'numb chin syndrome'. The subsequent literature review primarily focused on studies published in English, although those published in other languages were also evaluated for relevance and new information. No restrictions regarding the publication date were applied, with the earliest study being published in 1961, and the findings of the literature search were summarized in Table II (35-43).

Case report. In April 2015, a 69-year-old Japanese female patient presented at the Oral and Maxillofacial Surgery Department of the Red Cross Hospital (Naha, Japan) with the chief complaint of a tingling (numbness) sensation on the right side of the chin and lower lip and mild pain during molar occlusion since February 2015. The patient had been referred by a dentist for further investigation and management of suspected periodontitis in the right mandibular second premolar region and/or right mandibular osteomyelitis. The patient had previously undergone dental prosthetic treatment, including a partial denture for a missing right mandibular first molar. In addition, the patient had a history of chronic, well-controlled hypertension and type 2 diabetes mellitus and an unremarkable family history.

Upon examination, the patient was indicated to be well-nourished and in good condition, and exhibited no signs of pallor, jaundice, cyanosis, clubbing or localized/generalized lymphadenopathy. Although systemic examination yielded inconclusive results, the patient declined further exploration due to a lack of clear indications. Local examination revealed normal facial symmetry and a lack of sensation on the right side of the mandible extending from the labial commissure of the mouth to the midline of the inferior labium, including the vermilion and anterior chin. This area is innervated by the mental nerve (Fig. 1). Intraoral examination showed mild gingival erythema extending from the right mandibular second premolar to the right mandibular second molar. No obvious abnormalities were observed in the right mandibular first molar region.

Further investigation included orthopantomogram (OPG), contrast-enhanced computed tomography (CT), contrast-enhanced magnetic resonance imaging (MRI) using the short-tau inversion recovery (STIR)-PROPELLER technique, as well as hematological, cytology and histopathological examinations. OPG and MRI T2-weighted/STIR imaging showed alveolar bone resorption and high signal intensity between the right mandibular second premolar and second molar, indicating aggressive inflammation (Figs. 2 and 3). CT imaging showed mild osteolytic changes around the root of the right mandibular second premolar (Fig. 4), while hematological examination showed normal complete blood count levels. However, the C-reactive protein (CRP) and carbohydrate antigen 19-9 (CA 19-9; sialyl-Lewis^{A}) levels were elevated at 2.71 (reference value: 0-0.5) mg/dl and 1161.99 (reference value: 0-37) U/ml, respectively. Although non-specific, the erythrocyte sedimentation rate test was an unremarkable at 28 mm/h (local reference range for the 60-69-year age category, 2-40 mm/h; Westergren method). The patient's electrolyte levels, liver and renal function, complement titer, thyroid function, autoantibody levels, cytomegalovirus antibody levels and Epstein-Barr virus antibody levels were all normal. Core needle cytology examination indicated an inflammatory process (data not shown), prompting an initial diagnosis of right mandibular osteomyelitis with a strong suspicion of cancer. As the patient's medical history included tooth extraction, prosthetic treatment and absence of a prior diagnosis of

Table I. Etiological factors of numb chin syndrome.

Category	Condition	(Refs.)
Malignancy	Common: Breast cancer, lymphoma and leukemia, prostate cancer Uncommon: Lung cancer, myeloma, bone cancer, soft-tissue cancer, colon cancer, kidney cancer, adenoid cystic carcinoma, melanoma and other skin cancers, other digestive tract cancers (e.g.,gall bladder carcinoma)	(13-19)
Non-malignancy	Iatrogenic injuries during dental extractions, orthognathic surgery, trauma involving mandibular fractures, radicular dentigerous cysts, infections (e.g., chronic apical periodontitis, dental abscess), osteomyelitis of the jaw, medication-related osteonecrosis of the jaw, cysts and other benign tumors of dental origin, dental anesthetic administration, dental implants	(13,20-26)
Systemic	Syphilis arachnoiditis, connective tissue diseases, acromegaly, Paget's disease, van Buchem syndrome, diabetes mellitus, systemic lupus erythematosus, multiple myeloma, sickle cell disease, amyloidosis and sarcoidosis, brain stem infarcts, carotid aneurysms, temporal arteritis, multiple sclerosis, Sjögren's syndrome, infections (e.g., herpes and the human immunodeficiency virus)	(13,27-32)
Ageing	Mandibular atrophy	(33)

Table II. Previous reports of metastasis of gall bladder carcinoma to the mandible.

Case no.	Author, year of publication	Gender	Age, years	Diagnosis	TNM stage	Presence of NCS	Treatment	Prognosis/survival status	(Refs.)
1	Rominger, 1961	Female	68	GBC	NI	Not clear	Radiation/ chemotherapy	Deceased	(35)
2	Kim, 1990	Female	38	GBC	NI	Not clear	Chemotherapy	Poor prognosis/ unknown survival status	(36)
3	Suzuki, 1995	Female	61	GBC	IV	Hypoaesthesia of lower lip	Surgery	Deceased	(37)
4	Chang, 2002	Female	62	GBC	IV	Not clear	Chemotherapy	Deceased	(38)
5	Tanaka, 2010	Male	78	GBC	IV	Not clear	Palliative care	Deceased	(39)
6	Chen, 2010	Female	63	GBC	IV	Not clear	Palliative care	Deceased	(40)
7	Marin, 2013	Female	66	GBC	NI	Not clear	Aesthetic surgery	Poor prognosis/ 5 months' survival after diagnosis	(41)
8	Savithri, 2018	Female	64	GBC?	IV	Paresthesia of the lower lip and chin	Palliative radiotherapy	Poor prognosis/ survived for over 10 months after diagnosis	(42)
9	Dall'Magro, 2022	Female	33	EBC	IV	Not clear	Palliative radiotherapy/ chemotherapy and care	Deceased	(43)

EBC, extrahepatic biliary carcinoma; GBC, gall bladder carcinoma; NI, not indicated.

cancer, the possibility of tumorous lesions could not be ruled out based on CT and MRI images of the head and neck only. However, the patient declined additional comprehensive investigations including histopathology and a full-body evaluation using positron emission tomography (PET)-CT. The right mandibular second premolar was subsequently extracted, and

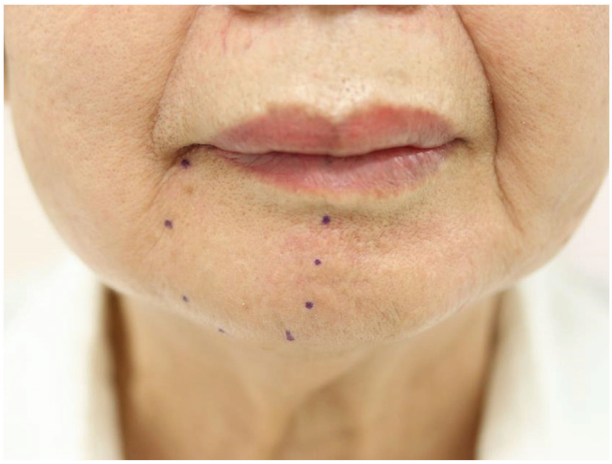

Figure 1. Photograph of the lower face of the 69-year-old female Japanese patient. The blue dotted area is innervated by the mental nerve and exhibited poor sensory perception.

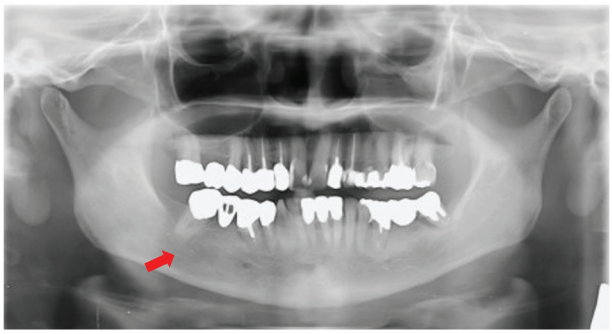

Figure 2. Orthopantomograph. The red arrow indicates mild resorption of the periapical alveolar bone extending from the right mandibular second premolar to the right mandibular second molar.

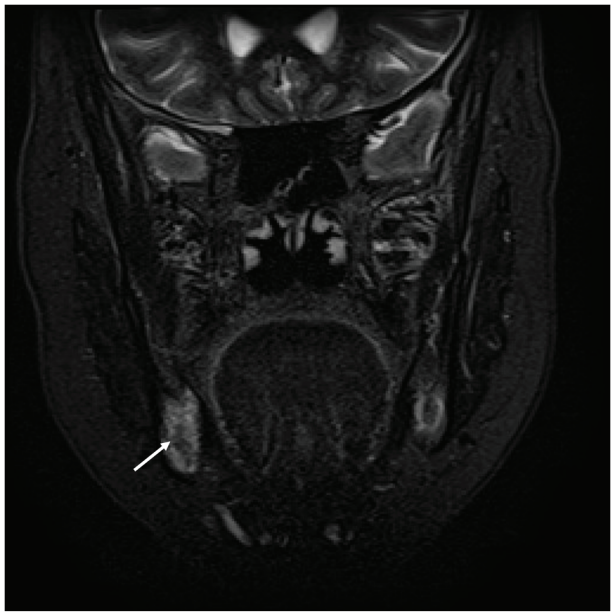

Figure 3. CT scan. Minor resorptive bone changes observed around the root of the right mandibular second premolar (arrow).

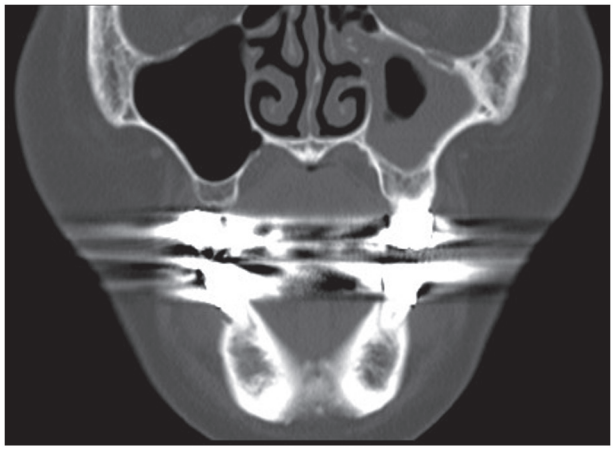

Figure 4. MRI coronal T2-weighted/short-tau inversion recovery-PROPELLER technique image showing a high signal intensity area between the right mandibular premolar and molar, suggesting aggressive inflammation and osteomyelitis of the right mandible.

mandible biopsy cytology examination suggested osteomyelitis (Fig. S1). Treatment with broad-spectrum antibiotics alleviated the numbness. However, an immediate evaluation for extraoral cancer was strongly recommended. The patient returned with a chief complaint of swelling and pain in the right mandible two months later and underwent extraction of the right mandibular second molar. Biopsy cytology examination suggested mandibular osteomyelitis again and the patient was advised to continue with anti-inflammatory and antibacterial treatment. However, the patient's symptoms persisted despite ongoing treatment, and she developed difficulty in mouth opening and further lip paresthesia 1 month later. At this point, the patient also developed severe pain in the right upper arm, and an orthopedic surgeon was consulted. Radiographic examination showed a pathological fracture (Fig. 5) due to suspected bone metastasis. Consequently, the patient was referred to the Department of Internal Medicine of the University of the Ryukyus Hospital (Nishihara, Japan) for extended investigation of the primary tumor. Contrast-enhanced CT imaging of the thorax and abdomen and full-body PET-CT imaging showed features suggestive of GBC with lymph node, bone, lung and liver metastasis (Fig. 6A and B). The lung and liver lesions were strongly suspected to be metastatic tumors based on CT imaging and the absence of any evidence of viral hepatitis.

Intraoral biopsy of the jaw tumor was repeated and histopathological analysis including hematoxylin and eosin (HE) staining and immunohistochemical (IHC) examination was carried out by at least two pathologists at the pathology department of the University of the Ryukyus Hospital (Nishihara, Japan). The specimens were cut into 4-μm-thick sections, fixed with 96% ethanol and immersed in a 10% formalin solution at 4°C for 24 h. Thereafter, hematoxylin staining was performed for 30 sec and the samples were rinsed with water at 4°C for 5 min and then counterstained with eosin Y at 4°C for 15 sec. The samples then underwent dehydration with 96 and 99.8% ethanol and xylene fixation, before being sealed with coverslips using mounting medium. Diagnostic images were captured using a Nikon Eclipse Ci microscope equipped with a Nikon DS-Fi3 camera with a x4 objective (Nikon Corporation). IHC examination was

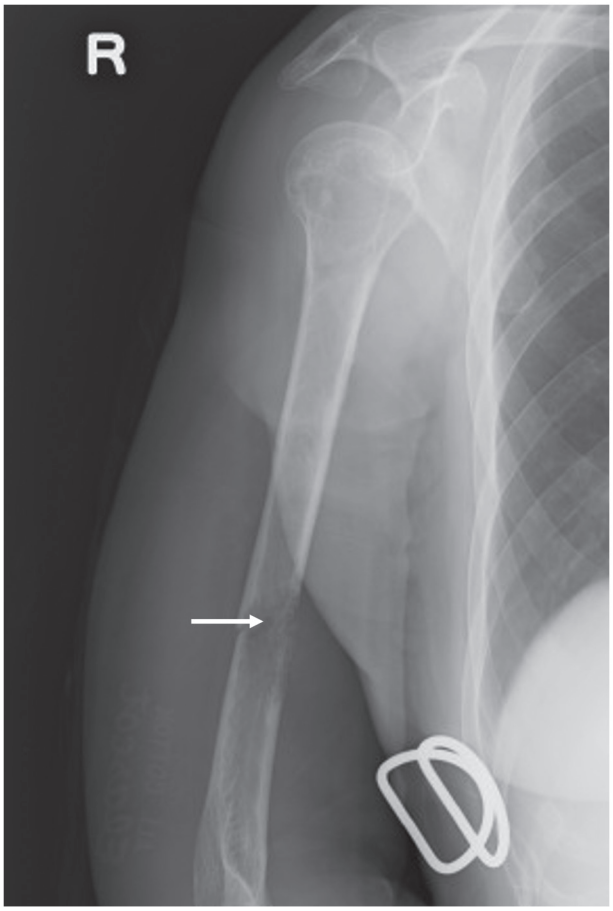

Figure 5. Radiographic examination of the right upper arm showing a pathological fracture caused by bone infiltration of the tumor.

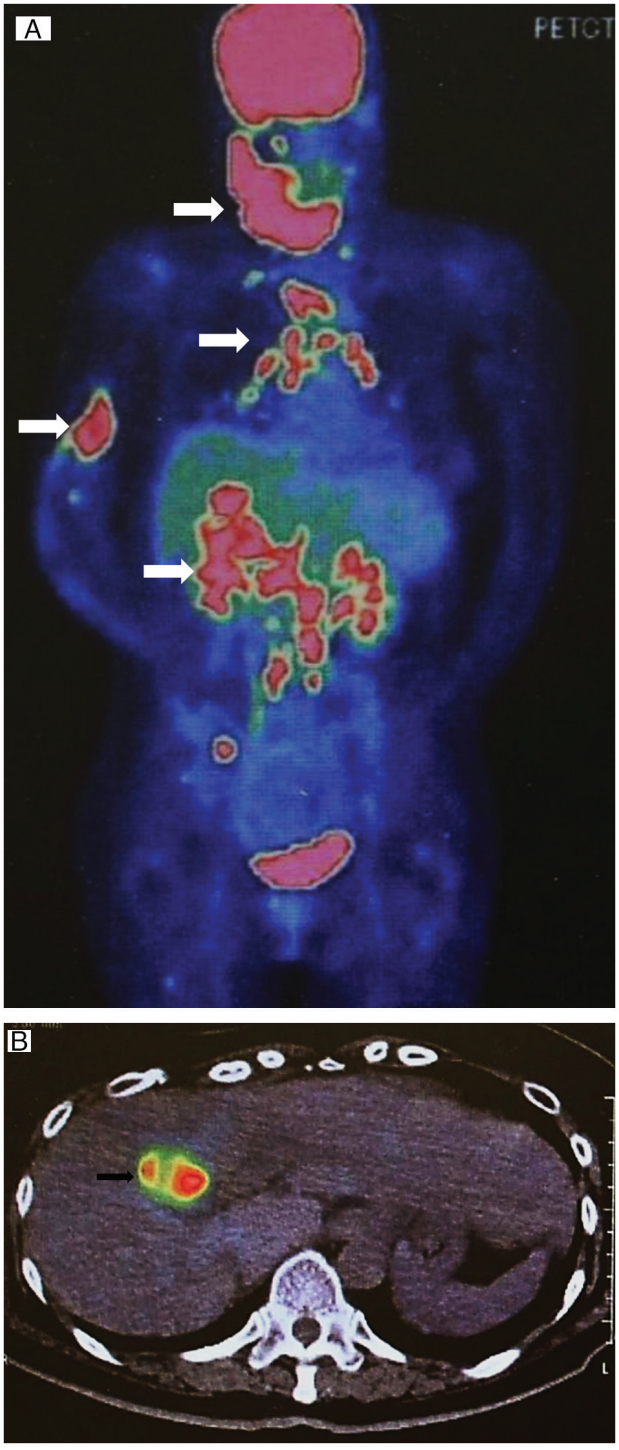

Figure 6. PET-CT imaging. A) Coronal fused image of ^{18}F-FDG PET/CT showing extensive hepatic, lung, humerus (right side) and mandibular (right side) metastasis (white arrows); B) fused images of ^{18}F-fluoro-2-deoxy-D-glucose PET/CT showing the primary tumor in the fundus and body of the gallbladder (black arrow). PET/CT, positron emission tomography-computed tomography.

conducted using the streptavidin-peroxidase technique at room temperature. The 4-μm-thick sections were rinsed with PBS before being subjected to 10 min of pepsase (1:1,000 dilution; Sigma-Aldrich; Merck KGaA) processing for antigen retrieval. They were then incubated in methanol and 3% hydrogen peroxide to deactivate endogenous peroxidases, blocked with PBS containing 0.5% Tween-20 (Sigma-Aldrich; Merck KGaA) and 3% bovine serum albumin (Sigma-Aldrich; Merck KGaA) for 1 h at room temperature, and then incubated with primary antibodies, including rabbit anti-cytokeratin (CK)7 (1:1,600 dilution; cat. no. ab199718; Abcam) and rabbit anti-CK20 (1:200; cat. no. ab64090; Abcam), overnight at 4°C. After three washes with PBS, a secondary antibody, goat anti-rabbit IgG H&L (HRP; 1:500 dilution; cat. no. ab97051; Abcam) was introduced along with fresh diaminobenzidine as the substrate for 1 h at room temperature. Negative controls were prepared using PBS instead of the primary antibody, and the Philips IntelliSite Pathology Solution (Philips Medical Systems) was used for image acquisition (data not shown). The histopathological analysis showed the presence of tumor cells with strongly atypical nuclei of unequal size, eosinophilic sporangia and an indistinct cord-like structure (Fig. 7) in the mandibular gingiva. Immunostaining revealed diffuse positivity for CK7 (Fig. 8A), partial positivity for CK20 (Fig. 8B) and negativity for hepatocyte-specific antigen and p40 (results not shown). The staining pattern was negative for hepatocellular and squamous cell carcinomas, indicating GBC metastasis (Fig. 8).

A diagnosis of stage IVb (T4N3M1) GBC, as per the American Joint Committee on Cancer classification (44), was made and the patient was admitted to the Red Cross Hospital (Naha, Japan) in October 2015 for palliative treatment due to the advanced stage of cancer and presence of multiple

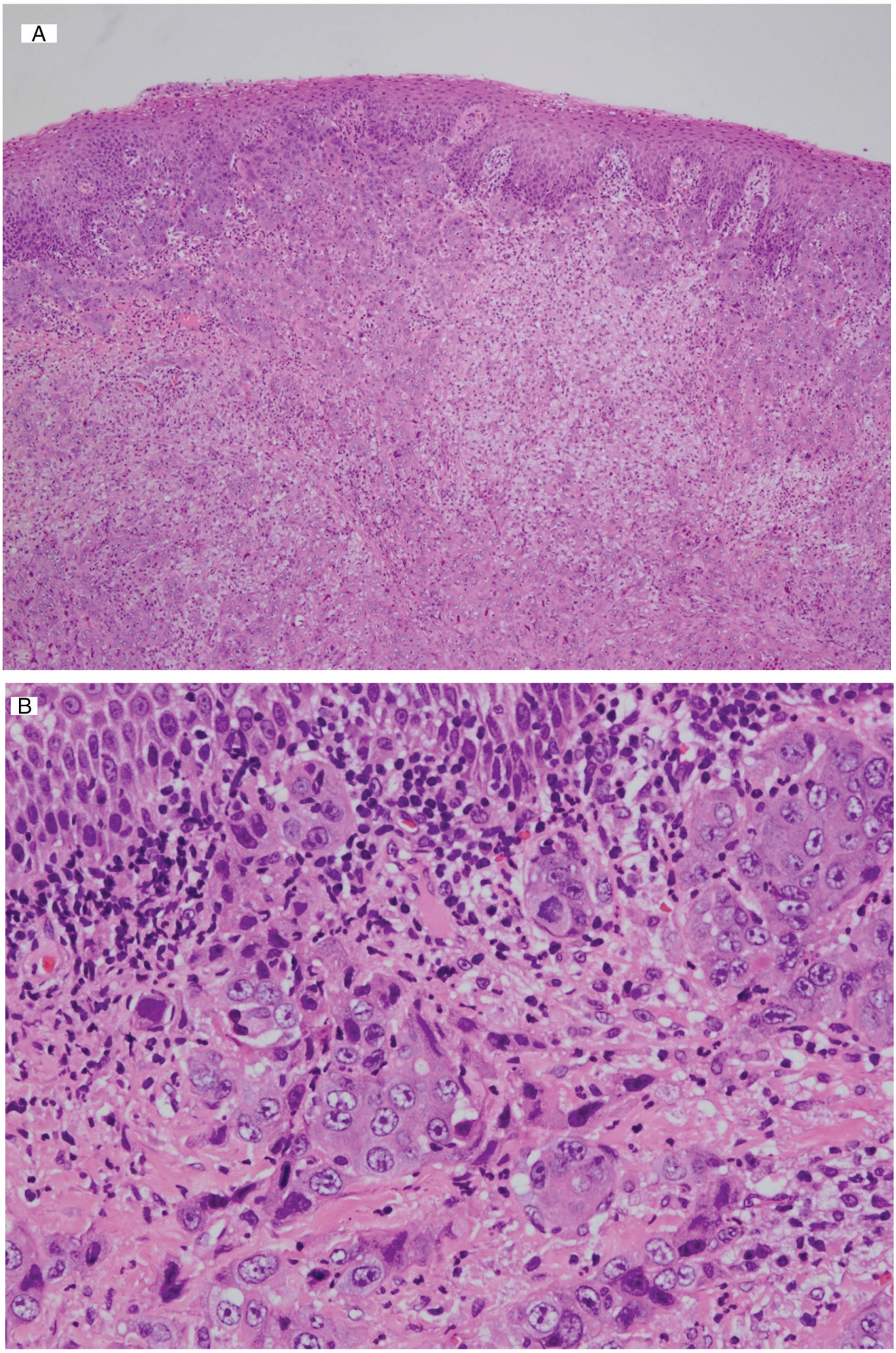

Figure 7. Histopathological images of the mandibular gingiva. HE staining with magnifications of (A) x10 and B) x40. Tumor cells exhibit strongly atypical nuclei of unequal size, eosinophilic sporangia and indistinct cord-like structures.

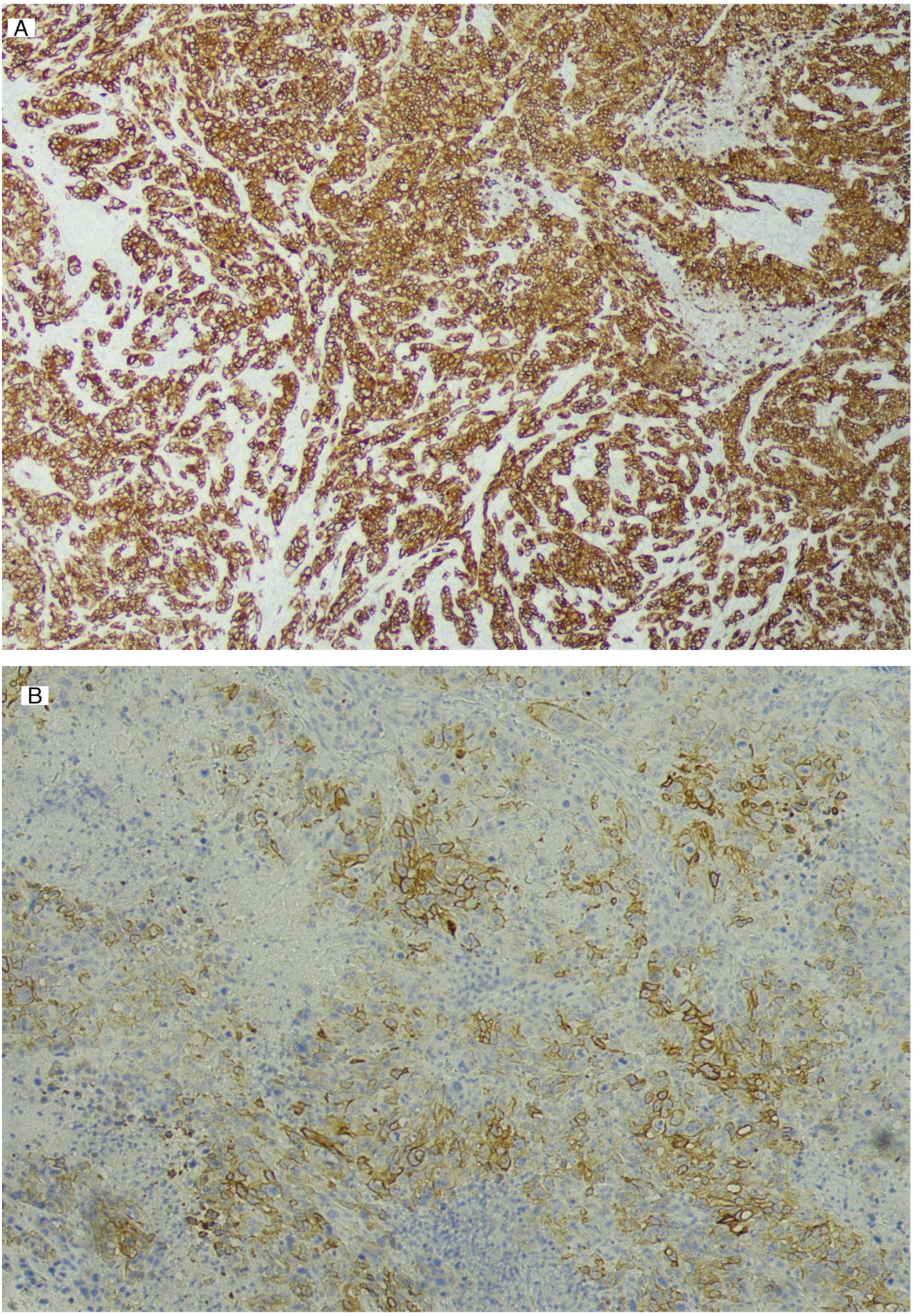

Figure 8. Immunohistochemical examination of the mandibular gingiva. A) CK7 and B) CK20 (magnification, x40). Tumor cells were diffusely positive for CK7 and partially positive for CK20. CK, cytokeratin.

metastases. Combination intravenous chemotherapy with 1,000 mg gemcitabine (Eli Lilly and Co.) and 32.5 mg cisplatin (Teva Pharmaceutical Industries Ltd.) was administered along with a pain control regimen consisting of a subcutaneous injection of 12 mg denosumab (Amgen Inc.) and a combination of narcotic drugs. Furthermore, 27 Gy irradiation was applied to the right upper arm. Despite treatment, the patient's symptoms did not improve significantly and she succumbed to multiple organ failure in November 2015.

Discussion

Extraoral metastatic tumors are an exceptionally rare occurrence, accounting for only 1% of all oral malignancies (9,45). Primary lesions that may metastasize to the oral cavity include lung, kidney, liver and prostate neoplasms in men and breast, genital, kidney and colorectal neoplasms in women (10). GBC typically spreads through direct extension to the liver and adjacent organs within the gastrointestinal tract before involving the regional lymph nodes. Instances of metastatic GBC in distant organs have been documented, but its spread to the oral cavity remains conspicuously rare, with only a small number of cases observed to date (Table II).

The determinants of oral cavity metastasis include the nature of the primary tumor, lesion stage, presence of lymphatic and vascular channel invasion, regional lymph node involvement, tumor size, histological characteristics of the lesion, patient's immune status, genetic factors and the micro-environments of the tumor and distant site. Delay in diagnosis and treatment of the primary tumor may substantially increase the risk of metastasis, with the mandible being particularly vulnerable in the oral region due to its rich blood supply (46). Metastasis of GBC to the mandible involves a complex interplay of molecular mechanisms, such as epithelial-mesenchymal transition, angiogenesis, lymphatic and hematogenous dissemination, extracellular matrix remodeling, evasion of immune surveillance, adaptation to the distinct mandibular microenvironment and concurrent genetic mutations and alterations that may potentially influence lesion aggressiveness and its capacity to infiltrate adjacent tissues and spread to distant sites (47-51).

Oral cavity metastasis typically has a poor prognosis, with most patients dying within one year of diagnosis (35-43). The prognosis depends on the treatment of the oral cavity lesion, as well as adequate control of the primary tumor and metastasis (advanced disease) (35-43,52). In the present case, the patient was diagnosed with extensive GBC metastasis throughout the body, and the patient's condition had deteriorated significantly by the time of admission to the Department of Internal Medicine of the University of the Ryukyus Hospital (Nishihara, Japan). Consequently, the patient succumbed to the disease 7 months after the initial diagnosis.

The present study was limited by the absence of initial intraoral photographs and images documenting the oral treatment process. These images could have provided additional insight into the progression and response of the oral metastasis to treatment, thereby enriching the visual documentation of this rare case. However, it should be emphasized that their absence does not diminish the clinical and diagnostic relevance of the findings presented. The absence of negative control IHC images, excluded from the analysis, could have potentially aided in the validation of the staining specificity and enhanced the interpretive accuracy for the reader. However, this potential limitation is mitigated by the comprehensive diagnostic approach employed in the present retrospective case report. To further uphold and enhance the scientific integrity of the reported findings, improved access to and inclusion of relevant investigation control data/images will be a key focus in our future studies.

A diagnosis of metastatic tumors in the oral and maxillofacial region may be made if the presence of a primary tumor located outside this region has been histologically and clinically confirmed, a clear distinction and absence of invasion between the primary tumor and metastases is observed and the patient has no history of a previous primary lesion in the same region (9,52). In the present study, the patient met all of these criteria, leading to the diagnosis of a metastatic tumor originating from GBC. GBC is a highly aggressive cancer that often spreads to nearby organs. Distant metastasis to the lungs, chest cavity (9.4%), skeletal system (2.4%) and the brain has been reported, although there is limited evidence of metastasis to the oral region (37,53-56).

NCS, first described by Calverley in 1963 and characterized by hypoesthesia limited to the lower lip and mental region due to mental nerve palsy (34), is often observed in association with metastatic malignancies of the mandible or infiltration of hematopoietic tumors such as lymphomas (13). While malignant lymphomas commonly present with NCS as the first symptom, followed by leukemia, gastric cancer, lung cancer and others, metastatic GBC with NCS as the initial symptom is a rare occurrence (34). In the current study, OPG showed no significant abnormalities, and a definitive diagnosis was made after histopathological confirmation. OPG alone may be insufficient during the early stages of invasion. CT and MRI scans may be used for lesion identification, although differentiation from mandibular osteomyelitis may be challenging. The patient's lack of relevant surgical and/or cancer history and initial failure to fully explore the condition due to personal reasons may have contributed to delays in diagnosis. As the majority of patients exhibiting malignancies with NCS as the initial symptom have a poor prognosis, it is presumed that the cancer had already progressed significantly at the time of onset of symptoms (10).

Distinguishing metastatic malignant tumors arising in the jawbone from mandibular osteomyelitis may be challenging due to the similarities in their clinical and radiological features, with both conditions presenting with lower lip hypoesthesia and mandibular bone resorption (57,58). Hariya *et al* (57) categorized the morphology of bone resorption into point, mass and infiltrative fractures, and found that both malignant tumors of the jawbone and mandibular osteomyelitis were associated with a higher degree of bone resorption. Intra-mandibular malignant tumors with infiltrative bone resorption typically present as a worm-eaten pattern, while mandibular osteomyelitis presents as point-like and massive resorption of cortical bone without infiltrative bone resorption on CT images. Cortical bone swelling is typically observed in intra-mandibular malignancies and is absent in patients with mandibular osteomyelitis. Furthermore, although periosteal reactions and osteosclerotic features are frequently seen in patients with mandibular osteomyelitis, they

have also been reported in association with intra-mandibular malignant tumors (57,58). In the present study, initial CT images revealed no resorption or mass formation in the lateral cortical bone of the mandible. However, elevated levels of CRP, CA19-9 and ESR were observed, and a history of tooth extraction with subsequent denture placement, coupled with pain in the region of the right mandibular second premolar, suggested potential mandibular osteomyelitis or malignancy. Consequently, biopsy cytology was undertaken following the premolar extraction, leading to a diagnosis of mandibular osteomyelitis. Diagnosis was delayed due to several factors, including the absence of a significant surgical or cancer history of the patient and the typically occult presentation of GBC (1,2). Although core needle biopsy provides a valuable tool for preliminary assessment of tumorous lesions and treatment guidance, its limitations, particularly regarding the potential for inadequate tissue sampling and preservation, as well as the ability to accurately assess certain biomarkers by IHC testing, should be recognized to avoid negatively impacting the diagnostic process (59).

Omics analyses, including metabolomics, transcriptomics and proteomics studies, were not conducted in this study due to the rapid deterioration of the patient's condition and her reluctance to undergo comprehensive assessments. Furthermore, attempts to conduct posthumous analyses were hindered by the absence of stored blood samples from the patient. Omics analyses, employing liquid biopsies, chromatographic separation, mass spectrometry and molecular biology techniques, show great promise for cancer diagnosis and prognosis (60). However, challenges persist, as identified by Wang *et al* (60), including variability in quantification and detection depending on the metabolomics approach-targeted or untargeted- and the choice of instruments. In addition, the considerable heterogeneity of metabolites among different cancer types, influenced by numerous factors, adds to these challenges (60). Therefore, while these analyses could have provided deeper insight into the molecular underpinnings of the metastatic process, their absence does not detract from the clinical and histopathological findings that form the basis of the present case report. This highlights the importance of considering the preservation of biological samples in future cases for advanced molecular studies.

The current study emphasizes the critical need for timely diagnosis and multimodal therapy in patients presenting with initial vague symptoms to improve outcomes in aggressive metastatic malignancies such as GBC.

In conclusion, the present case report underscores the rarity of GBC metastasizing to the oral region and presenting as NCS. It highlights the critical need for prompt, thorough evaluation of neurological symptoms to detect hidden malignancies and the importance of differentiating bony metastases from conditions such as osteomyelitis through comprehensive diagnostic methods. The study also emphasizes the value of multidisciplinary collaboration for the timely diagnosis and treatment of complex metastatic diseases. In addition, it points to the potential of emerging technologies such as metabolomics in cancer research, underscoring the necessity for swift confirmatory tests and accurate diagnoses in managing metastatic cancers.

Acknowledgements

Not applicable.

Funding

No funding was received.

Availability of data and materials

The datasets used and/or analyzed in the current study are available from the corresponding author upon reasonable request.

Authors' contributions

MM and EHN: Study conception and design; MM, EHN, HK, TG, KI, JS, NM, TK, KN, YS and HN: Data acquisition, analysis and interpretation; MM, EHN, KN, YS and HN: Preparation of manuscript draft and revision. MM and HN confirm the authenticity of all the raw data. All authors have read and approved the final version of the manuscript prior to submission.

Ethical approval and consent to participate

Not applicable.

Patient consent for publication

Written informed consent was obtained from the patient's next-of-kin prior to publication of their clinical information and images.

Competing interests

The authors declare that they have no competing interests.

References

1. Gallbladder Cancer Statistics. World Cancer Research Fund International n.d. Available from: https://www.wcrf.org/cancer-trends/gallbladder-cancer-statistics/(accessed May 24, 2023).
2. Bray F, Ferlay J, Soerjomataram I, Siegel RL, Torre LA and Jemal A: Global cancer statistics 2018: GLOBOCAN estimates of incidence and mortality worldwide for 36 cancers in 185 countries. CA Cancer J Clin 68: 394-424, 2018.
3. Roa JC, García P, Kapoor VK, Maithel SK, Javle M and Koshiol J: Gallbladder cancer. Nat Rev Dis Primers 8: 69, 2022.
4. Matsuda T and Saika K: Cancer burden in Japan based on the latest cancer statistics: Need for evidence-based cancer control programs. Ann Cancer Epidemiol 2: 2, 2018.
5. Hariharan D, Saied A and Kocher HM: Analysis of mortality rates for gallbladder cancer across the world. HPB (Oxford) 10: 327-331, 2008.
6. Rawla P, Sunkara T, Thandra KC and Barsouk A: Epidemiology of gallbladder cancer. Clin Exp Hepatol 5: 93-102, 2019.
7. Hundal R and Shaffer EA: Gallbladder cancer: Epidemiology and outcome. Clin Epidemiol 6: 99-109, 2014.
8. Lamarca A, Barriuso J, McNamara MG and Valle JW: Molecular targeted therapies: Ready for 'prime time' in biliary tract cancer. J Hepatol 73: 170-185, 2020.
9. Meyer I and Shklar G: Malignant tumors metastatic to mouth and jaws. Oral Surg Oral Med Oral Pathol 20: 350-362, 1965.
10. Hirshberg A, Shnaiderman-Shapiro A, Kaplan I and Berger R: Metastatic tumours to the oral cavity-pathogenesis and analysis of 673 cases. Oral Oncol 44: 743-752, 2008.
11. Pisani P, Airoldi M, Allais A, Aluffi Valletti P, Battista M, Benazzo M, Briatore R, Cacciola S, Cocuzza S, Colombo A, *et al*: Metastatic disease in head & neck oncology. Acta Otorhinolaryngol Ital 40 (Suppl 1): S1-S86, 2020.

12. Perez C, de Leeuw R, Escala PF, Fuentealba R and Klasser GD: Numb chin syndrome: What all Oral Health care professionals should know. J Am Dent Assoc 154: 79-93, 2023.
13. Baskaran RK, Krishnamoorthy SM and Smith M: Numb chin syndrome-a reflection of systemic malignancy. World J Surg Oncol 4: 52, 2006.
14. Maeda K, Taniguchi JI and Matsui K: Two cases of numb chin syndrome diagnosed as malignant disease. Oxf Med Case Reports 2018: omy097, 2018.
15. Sanchis JM, Bagán JV, Murillo J, Díaz JM, Poveda R and Jiménez Y: Mental neuropathy as a manifestation associated with malignant processes: Its significance in relation to patient survival. J Oral Maxillofac Surg 66: 995-998, 2008.
16. Evans RW, Kirby S and Purdy RA: Numb chin syndrome. Headache 48: 1520-1524, 2008.
17. Lu SY, Huang SH and Chen YH: Numb chin with mandibular pain or masticatory weakness as indicator for systemic malignancy-A case series study. J Formos Med Assoc 116: 897-906, 2017.
18. Smith SF, Blackman G and Hopper C: Numb chin syndrome: A nonmetastatic neurological manifestation of malignancy. Oral Surg Oral Med Oral Pathol Oral Radiol Endod 105: e53-e56, 2008.
19. Tejani N, Cooper A, Rezo A, Pranavan G and Yip D: Numb chin syndrome: A case series of a clinical syndrome associated with malignancy. J Med Imaging Radiat Oncol 58: 700-705, 2014.
20. Divya KS, Moran NA and Atkin PA: Numb chin syndrome: A case series and discussion. Br Dent J 208: 157-160, 2010.
21. Kalladka M, Proter N, Benoliel R, Czerninski R and Eliav E: Mental nerve neuropathy: Patient characteristics and neurosensory changes. Oral Surg Oral Med Oral Pathol Oral Radiol Endod 106: 364-370, 2008.
22. Shah D, Shetty S, MacBean AD and Olley SF: Numb chin syndrome: A metastatic deposit in the mandible. Dent Update 37: 244-246, 2010.
23. Hirshberg A, Leibovich P and Buchner A: Metastatic tumors to the jawbones: Analysis of 390 cases. J Oral Pathol Med 23: 337-341, 1994.
24. Maillefert JF, Gazet-Maillefert MP, Tavernier C and Farge P: Numb chin syndrome. Joint Bone Spine 67: 86-93, 2000.
25. Neal CE and Kiyak HA: Patient perceptions of pain, paresthesia, and swelling after orthognathic surgery. Int J Adult Orthodon Orthognath Surg 6: 169-181, 1991.
26. Worthington P: Injury to the inferior alveolar nerve during implant placement: A formula for protection of the patient and clinician. Int J Oral Maxillofac Implants 19: 731-734, 2004.
27. Hogan MC, Lee A, Solberg LA and Thomé SD: Unusual presentation of multiple myeloma with unilateral visual loss and numb chin syndrome in a young adult. Am J Hematol 70: 55-59, 2002.
28. Mestoudjian P, Steichen O, Stankovic K, Lecomte I and Lionnet F: Sickle cell disease, a benign cause of numb chin syndrome. Am J Med 121: e1, 2008.
29. da Silva CJ, da Rocha AJ, Mendes MF, Maia AC Jr, Braga FT and Tilbery CP: Trigeminal involvement in multiple sclerosis: Magnetic resonance imaging findings with clinical correlation in a series of patients. Mult Scler 11: 282-285, 2005.
30. Mori K, Iijima M, Koike H, Hattori N, Tanaka F, Watanabe H, Katsuno M, Fujita A, Aiba I, Ogata A, *et al*: The wide spectrum of clinical manifestations in Sjögren's syndrome-associated neuropathy. Brain 128: 2518-2534, 2005.
31. Abilleira S and Bowler JV: The numb chin syndrome as an early manifestation of giant-cell (temporal) arteritis: A case report. Headache 45: 1411-1413, 2005.
32. Yura Y, Kusaka J, Yamakawa R, Bando T, Yoshida H and Sato M: Mental nerve neuropathy as a result of primary herpes simplex virus infection in the oral cavity. A case report. Oral Surg Oral Med Oral Pathol Oral Radiol Endod 90: 306-309, 2000.
33. Furukawa T: Numb chin syndrome in the elderly. J Neurol Neurosurg Psychiatry 53: 173, 1990.
34. Smith RM, Hassan A and Robertson CE: Numb chin syndrome. Curr Pain Headache Rep 19: 44, 2015.
35. Rominger CJ, Lockwood DW and Canino CW: Carcinoma of the gallbladder with mandibular metastasis: Report of case. J Oral Surg Anesth Hosp Dent Serv 19: 425-427, 1961.
36. Kim CS, Lee JH, Ann HY, Chung SC and Choi HS: Metastatic carcinoma of oral cavity. Maxillofac Plast Reconstr Surg 12: 142-147, 1990.
37. Suzuki K, Onizawa K, Yoshida H and Fukuda H: A case of metastatic gallbladder adenocarcinoma of the mandible. Jpn J Oral Maxillofac Surg 41: 154-156, 1995.
38. Chang TS, Liaw CC, Lee KF and Wu CS: Gingival metastasis from gallbladder cancer. Chang Gung Med J 25: 553-556, 2002.
39. Tanaka A, Shigematsu H, Kikuchi K, Inoue K, Ide F, Hasegawa A, Kusama K and Sakashita H: Metastatic tumor of the mandible from occult gallbladder cancer: A case report. Asian J Oral Maxillofac Surg 22: 168-171, 2010.
40. Chen YS, Hsu YH, Lee CF and Chou YF: Metastatic gallbladder cancer presenting as a gingival tumor and deep neck infection. Kaohsiung J Med Sci 26: 558-561, 2010.
41. Marin H, Bouras AF, Patenôtre P, Boleslawski E, Zerbib P, Pruvot FR and Truant S: Cheek metastasis from gallbladder adenocarcinoma. J Visc Surg 150: 225-226, 2013.
42. Savithri V, Suresh R, Janardhanan M and Aravind T: Metastatic adenocarcinoma of mandible: In search of the primary. BMJ Case Rep 11: e227862, 2018.
43. Dall'Magro AK, Dogenski LC, Bade P, Cé LC, Dall'Magro E and De Carli JP: Mandibular metastasis of primary extrahepatic biliary carcinoma: Case report. Int J Surg Case Rep 98: 107498, 2022.
44. Amin MB: AJCC Cancer Staging Manual. 8th edition. Springer, Heidelberg, 2017.
45. Adewale AO, Mofoluwake LA, Olamide OT and Yussuf SA: Two case reports on mandibular metastases. Ghana Med J 52: 168-172, 2018.
46. Hirshberg A, Berger R, Allon I and Kaplan I: Metastatic tumors to the jaws and mouth. Head Neck Pathol 8: 463-474, 2014.
47. Xu S, Zhan M and Wang J: Epithelial-to-mesenchymal transition in gallbladder cancer: From clinical evidence to cellular regulatory networks. Cell Death Discov 3: 17069, 2017.
48. Leong SP, Naxerova K, Keller L, Pantel K and Witte M: Molecular mechanisms of cancer metastasis via the lymphatic versus the blood vessels. Clin Exp Metastasis 39: 159-179, 2022.
49. Fares J, Fares MY, Khachfe HH, Salhab HA and Fares Y: Molecular principles of metastasis: A hallmark of cancer revisited. Signal Transduct Target Ther 5: 28, 2020.
50. Andrén-Sandberg A: Molecular biology of gallbladder cancer: Potential clinical implications. N Am J Med Sci 4: 435-441, 2012.
51. Kang M, Na HY, Ahn S, Kim JW, Lee S, Ahn S, Lee JH, Youk J, Kim HT, Kim KJ, *et al*: Gallbladder adenocarcinomas undergo subclonal diversification and selection from precancerous lesions to metastatic tumors. Elife 11: e78636, 2022.
52. Clausen F and Poulsen H: Metastatic carcinoma of the jaws. Acta Pathol Microbiol Scand 57: 361-374, 1963.
53. Arnaud JP, Graf P, Gramfort JL and Adloff M: Primary carcinoma of the gallbladder: Review of 25 cases. Am J Surg 138: 403-406, 1979.
54. Sons HU, Borchard F and Joel BS: Carcinoma of the gallbladder: Autopsy findings in 287 cases and review of the literature. J Surg Oncol 28: 199-206, 1985.
55. Bosset JF, Mantion G, Gillet M, Pelissier E, Boulenger M, Maingon P, Corbion O and Schraub S: Primary carcinoma of the gallbladder. Adjuvant postoperative external irradiation. Cancer 64: 1843-1847, 1989.
56. Zachariades N: Neoplasms metastatic to the mouth, jaws and surrounding tissues. J Craniomaxillofac Surg 17: 283-290, 1989.
57. Hariya Y, Yuasa K, Nakayama E, Kawazu T, Okamura K and Kanda S: Value of computed tomography findings in differentiating between intraosseous malignant tumors and osteomyelitis of the mandible affecting the masticator space. Oral Surg Oral Med Oral Pathol Oral Radiol Endod 95: 503-509, 2003.
58. Tanaka R and Hayashi T: Computed tomography findings of chronic osteomyelitis involving the mandible: Correlation to histopathological findings. Dentomaxillofac Radiol 37: 94-103, 2008.
59. Sun C, Lu Q, Zhang X, Zhang Y, Jia S, Wang J, Zhu H, He W and Zhang Z: Comparison between core needle biopsy and excisional biopsy for breast neoplasm. Medicine (Baltimore) 100: e26970, 2021.
60. Wang W, Rong Z, Wang G, Hou Y, Yang F and Qiu M: Cancer metabolites: Promising biomarkers for cancer liquid biopsy. Biomark Res 11: 66, 2023.