Granulomatous mastitis in accessory breast tissue: A rare presentation and surgical management

ABDULWAHID M. SALIH[1,2], LANA RA. PSHTIWAN[1], SHABAN LATIF[1], HALKAWT O. ALI[1], ARI M. ABDULLAH[1,3], HIWA O. BABA[1,4], JIHAD IBRAHIM HAMA[5], SHKO H. HASSAN[1], MARWAN N. HASSAN[1,4], SHVAN H. MOHAMMED[4], MOHAMMED L. AHMED[1] and FAHMI H. KAKAMAD[1,2,4]

[1]Scientific Affairs Department, Smart Health Tower; [2]College of Medicine, University of Sulaimani; [3]Department of Pathology, Sulaimani Surgical Teaching Hospital; [4]Kscien Organization for Scientific Research, Sulaimani, Kurdistan 46001; [5]Research Center, University of Halabja, Halabja, Kurdistan 46018, Republic of Iraq

Received November 5, 2023; Accepted January 19, 2024

DOI: 10.3892/br.2024.1750

Abstract. Granulomatous mastitis (GM) in accessory breast tissue is rare. The present study aimed to report a rare case of GM in accessory breast tissue. A 39-year-old female patient presented with right axillary discomfort and swelling for ~5 days. On clinical examination, a tender, firm lump was detected in the right axillary region. The ultrasound showed diffuse parenchymal heterogeneity and surrounding edema in the right accessory breast associated with reactive axillary lymph nodes. Following unresponsiveness to conservative treatment, a surgical procedure was performed in the form of an excisional biopsy and the lesion was diagnosed as GM. During the six-month follow-up, there were no recurrences. The exact cause of GM remains uncertain and the etiology within accessory breast tissue is even less understood. Proposed mechanisms suggest that it may result from an exaggerated immune response triggered by various factors, such as infection, autoimmunity or hormonal fluctuations. GM in accessory breast tissue is a rare and challenging clinical condition to be diagnosed. Due to the rarity of this condition, it highlights the importance of including GM in the differential diagnosis of axillary masses.

Introduction

Granulomatous mastitis (GM) is a rare inflammatory disorder of the breast, which typically develops in women of childbearing age who have a history of breastfeeding (1). GM is classified into two types: Idiopathic GM or primary GM, as well as secondary GM. Infections such as histoplasmosis and actinomycosis, along with autoimmune conditions such as granulomatosis with polyangiitis, IgG4-related diseases like mastitis, sarcoidosis, fat necrosis and foreign body reactions, are all potential triggers for secondary GM (2). In 1972, Kessler and Wolloch (3) initially documented GM, but it was Cohen (4) who provided a more comprehensive description of the condition in 1977. Despite being a benign disease, it is frequently difficult to detect, and its locally aggressive character causes long-term discomfort and distress for affected patients (5). It is a serious condition, since it clinically mimics cancer (6). Ethnic diversity has a role in the distribution of this condition, as GM occurrences are more prevalent in Middle Eastern nations compared to Western countries (7). GM in accessory breast tissue is rare. There have been only a small number of cases of GM identified in axillary accessory breast tissue that have been documented in the medical literature (2,8-10), excluding those published in predatory journals.

The present case report reports on a rare clinical presentation of GM in accessory breast tissue, providing information on the diagnosis and therapeutic challenges of this unusual disease.

Case report

Patient information. A 39-year-old female patient presented with right axillary discomfort and swelling for ~5 days, associated with redness, fever and chills. The patient had three children and she had breastfed two of them for ~17 months each; the last child was breastfed only three months intermittently from the right breast. The last time the patient lactated was approximately two years prior to the current presentation. She was non-diabetic with a past medical history of left breast GM in November 2018. The patient was a nonsmoker and her other medical history was unremarkable. Her diet consisted of eating daily meals of low-fat and low-salted food with high amounts of vegetables. She ate less fruit and fried food, and a lot of sweet or sweetened food.

Clinical findings. During the clinical examination, a tender, firm lump was detected in the right axillary region. The lump displayed signs of inflammation, including redness and

Correspondence to: Dr Fahmi H. Kakamad, College of Medicine, University of Sulaimani, HC8V+JFG, Madam Mitterrand Street, Sulaimani, Kurdistan 46001, Republic of Iraq
E-mail: fahmi.hussein@univsul.edu.iq

Key words: axillary breast, breast, cancer, granulomatous mastitis, inflammation

warmth, and there were also palpable lymph nodes in the axilla (Fig. 1).

Diagnostic approach. The breast ultrasound (US) was performed externally at Breast Center on Malik Mahmud Ring Road (HCMR+46H; Sulaymaniyah, Iraq). Unfortunately, the US image is not available. It revealed bilateral normal breasts with normal left accessory breast. The right accessory breast showed diffuse parenchymal heterogeneity and surrounding edema associated with reactive axillary lymph nodes. There was no evidence of fluid accumulation, implying a diagnosis of mastitis. The complete blood count results fell within the normal range.

Therapeutic interventions. Initially, conservative treatment commenced with a five-day course of antibiotics, specifically oral amoxicillin and clavulanic acid. However, during the follow-up, the patient did not show any improvement with the medication. Consequently, surgical excision was proposed as an alternative, considering the patient's history of successfully treating left breast GM through surgical intervention when medication proved ineffective. After obtaining informed consent, the surgical procedure was performed in the form of an excisional biopsy. This procedure was conducted under general anesthesia and involved a seven-centimeter elliptical incision with no drain placed.

The excised tissue was sent for histopathological examination (HPE). The examined tissue underwent a pathological staining process according to standard procedures (Data S1).

The HPE indicated the presence of breast tissue with duct ectasia and suppurative granulomatous inflammation leading to abscess formation (Figs. 2 and 3). Importantly, no malignancy was detected in the histopathological findings.

Follow-up. The postoperative course was uneventful. In zero-day postoperative care, nearly 12 h after surgery, the patient was discharged home without any complications. During the six-month follow-up, the breast US showed no signs of recurrence, and the patient was not symptomatic; therefore, she was kept on one-year follow up.

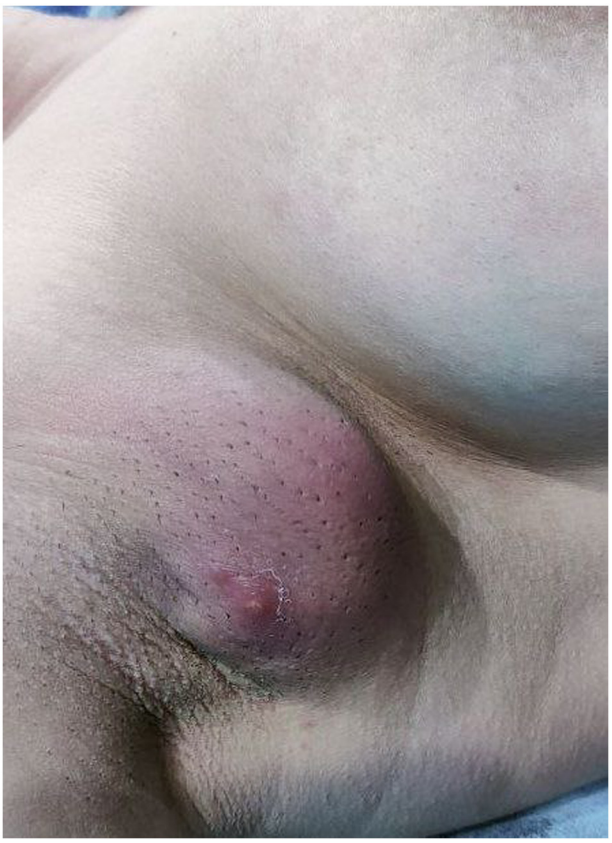

Figure 1. Right axillary erythematous swelling.

Discussion

GM is a rare and clinically challenging inflammatory breast disorder characterized by the formation of granulomas within the breast tissue. It predominantly affects the mammary gland but may, in rare cases, occur within accessory breast tissue (8). Accessory breast tissues can be seen along the embryonic mammary ridge, which runs from the axilla to the pubic region. The disease processes affecting axillary breast tissue are the same as those affecting the tissue of the main breast (9). While GM is most frequently observed in women who are in their third and fourth decades of life, it is often identified within a few years after childbirth, and most individuals affected by this condition have experienced at least one live birth and have breastfed (11).

The exact cause of GM remains uncertain and the etiology within accessory breast tissue is even less understood. Proposed mechanisms suggest that it may result from an exaggerated immune response triggered by various factors, such as infection, autoimmunity or hormonal fluctuations. However, no single etiological factor has been consistently identified (1). Only a few cases of GM in accessory breast tissue have been documented in the English literature. Two of these occurred in women of childbearing age after giving birth and one during pregnancy (2,8,9). The patient of the present case study had three children and breastfed for a total of three years. She had a history of GM of the contralateral breast in 2018.

GM is often unilateral, with few reports of bilateral involvement. A large, tender lump, frequently several centimeters in diameter, is the most common presenting symptom. This is usually associated with skin abnormalities such as erythema and ulceration. Sinuses can occur, with discharge from the lesions. Multiple lumps and ulcers in one or more quadrants of the breast are common. Systemic features such as fever are uncommon (5,11). The current patient presented with right axillary pain and swelling for ~5 days, associated with fever and chills. On examination, there was a hard, palpable lump in the right axilla; it was tender and exhibited evidence of inflammation, such as redness and pain, as well as palpable axillary lymph nodes.

Diagnosing GM is often challenging due to its rarity and the absence of specific clinical or radiological features. Mammography often shows nonspecific features that do not provide a definitive diagnosis, such as asymmetric density (12). In cases where an abscess is present, US can be a valuable diagnostic tool. It is able to display an irregular mass with mixed heterogeneity. However, these findings are non-specific and may overlap with other breast pathologies (5). In the current case, the US revealed the normal

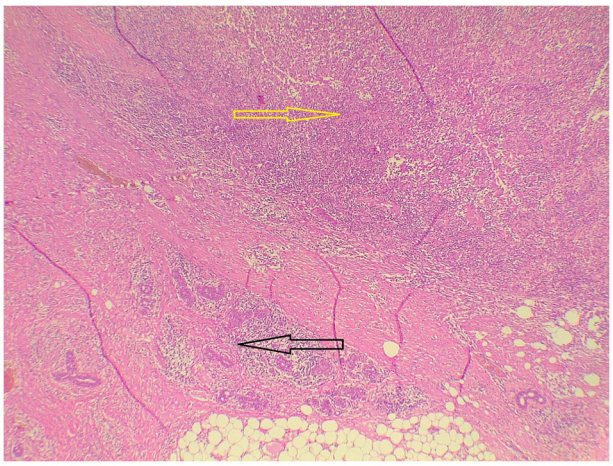

Figure 2. Histology of excisional biopsy indicated benign axillary breast tissue (black arrow) with heavy mixed inflammatory cell infiltration (yellow arrow) (hematoxylin and eosin staining; magnification, x20).

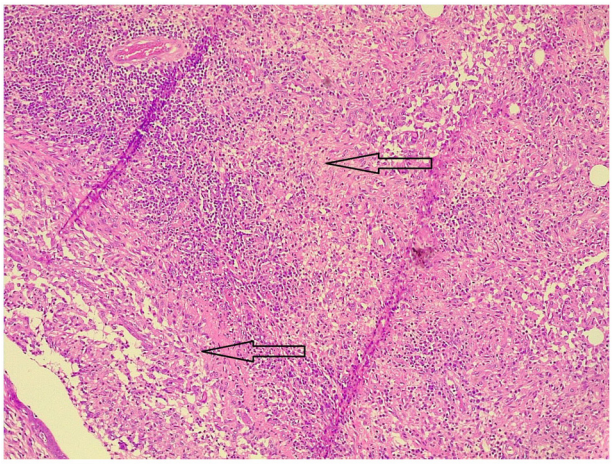

Figure 3. Histology on magnification revealed multiple different-sized, ill-defined epithelioid granulomas (black arrows) with severe inflammation in the background (hematoxylin and eosin staining; magnification, x40).

features of both the main breasts and the left accessory breast. However, there were notable irregularities in the tissue of the right accessory breast, parenchymal heterogeneity with preserved architecture without associated mass or ductal distortion, marked by significant variation in density, along with edema in the surrounding area, which was more evident than in malignancy. Importantly, there was no sign of fluid accumulation, which typically suggests mastitis. In addition, reactive lymph nodes were observed in the adjacent axillary region. The axillary lymph nodes showed concentric regular outline cortical thickening and the vascularity was going from the hilum towards the cortices, not vice versa as it occurs in malignancy.

Definitive diagnosis often relies on histopathological examination, typically obtained through fine-needle aspiration cytology (FNAC) or core needle biopsy (CNB). Although FNAC may aid in a quicker diagnosis, it is not as specific as CNB. As a result, in the literature, CNB is regarded as the gold standard preoperative diagnostic modality (1,5,13). The condition is distinguished by the formation of granulomas in conjunction with localized infiltration of multi-nucleated giant cells, lymphocytes, epithelioid histiocytes and plasma cells (1).

Regarding the management, there is no agreement on the optimum treatment for GM; however, medical therapy, surgical excision, abscess drainage or only close observation are now the most popular choices. Antibiotics, systemic steroids, nonsteroidal anti-inflammatory drugs and immunosuppressive medicines, such as methotrexate and azathioprine, have been documented as medical therapies (14). Corticosteroids, while commonly employed by numerous clinicians and yielding positive results, have a restricted role primarily due to the absence of consensus regarding their optimal timing, duration and dosage. Commencing steroid therapy can be complicated by concerns about the presence of an infectious cause (15). Furthermore, the use of corticosteroids may lead to potential adverse effects, including Cushing syndrome, hyperglycemia, weight gain and susceptibility to opportunistic infections (8). The period required for complete remission typically spans from six weeks to eleven months, necessitating prolonged patient follow-up, which may pose challenges when patients are non-compliant with follow-up appointments (16).

In the present case, surgical excision was performed and no signs of recurrence were observed during a six-month follow-up period. Surgery was chosen for this patient due to her previous successful surgery on the contralateral breast, the favorable cosmetic outcomes associated with surgery in this region, the potential for a precise diagnosis and the prospect of faster recovery. After surgery, recurrence rates of 5.5-50% have been reported (17).

Healthcare providers should be aware of the possibility of GM occurring in accessory breast tissue, particularly when evaluating patients with axillary masses. Prompt diagnosis is crucial to avoiding delays in appropriate treatment and minimizing patient discomfort. Given the rarity of this condition, a high index of suspicion is essential. Treatment options should be individualized, taking into account the patient's symptoms and the extent of the disease. In cases of GM in accessory breast tissue, surgical excision may be a suitable option, considering the potential for favorable cosmetic outcomes and a definitive diagnosis. Long-term follow-up is vital to monitor for disease recurrence, complications and treatment efficacy.

In conclusion, GM in accessory breast tissue is a rare and challenging clinical condition to diagnose. Due to the rarity of this condition, it highlights the importance of including GM in the differential diagnosis of axillary masses, particularly when clinical and radiological characteristics are abnormal. Further research is warranted to better understand the pathogenesis and optimal treatment strategies. Increased awareness among healthcare providers, along with collaborative efforts in research and clinical care, will ultimately enhance the ability to diagnose and manage this noteworthy and rare manifestation of GM.

Acknowledgements

Not applicable.

Funding

No funding was received.

Availability of data and materials

The data generated in the present study may be requested from the corresponding author.

Authors' contributions

AMS and HOA were major contributors to the conception of the study, as well as the literature search for related studies. FHK, SHH, SHM and MNH were involved in the literature review, study design and in writing the manuscript. LRAP, SL, JIH, MLA and HOB were involved in the literature review, the design of the study, critical revision of the manuscript and processing of the figures. FHK and SHH confirm the authenticity of all the raw data. AMA was the pathologist who performed the histopathological diagnosis. All authors have read and approved the final manuscript.

Ethics approval and consent to participate

Written informed consent was obtained from the patient for participation in the present study.

Patient consent for publication

Written informed consent was obtained from the patient for the publication of the present case report and any accompanying images.

Competing interests

The authors declare that they have no competing interests.

References

1. Wolfrum A, Kümmel S, Theuerkauf I, Pelz E and Reinisch M: Granulomatous mastitis: A therapeutic and diagnostic challenge. Breast Care (Basel) 13: 413-418, 2018.
2. Alvand S, Hessami A, Makhmalbaf AO and Elahi A: Uncommon location of idiopathic granulomatous mastitis: A case report. Arch Breast Cancer 9 (3-SI): 320-324, 2022.
3. Kessler E and Wolloch Y: Granulomatous mastitis: A lesion clinically simulating carcinoma. Am J Clin Pathol 58: 642-646, 1972.
4. Cohen C: Granulomatous mastitis-a review of 5 cases. S Afr Med J 52: 14-16, 1977.
5. Brennan ME, Morgan M, Heilat GB and Kanesalingam K: Granulomatous lobular mastitis: Clinical update and case study. Aust J Gen Pract 49: 44-47, 2020.
6. Carmalt HL and Ramsey-Stewart G: Granulomatous mastitis. Med J Aust 1: 356-359, 1981.
7. Deng Y, Xiong Y, Ning P, Wang X, Han XR, Tu GF and He PY: A case management model for patients with granulomatous mastitis: A prospective study. BMC Womens Health 22: 143, 2022.
8. Nakamura J, Tanaka F, Ohtaka K, Sato K and Iyama A: A rare case of granulomatous mastitis in the accessory axillary breast of a pregnant woman successfully treated by surgery. Eur J Breast Health 18: 195-198, 2022.
9. Yılmaz MA, Kaya TI, Demirel M and Yuyucu Karabulut Y: Pregnancy-associated granulomatous mastitis of accessory breast: A novel clinical presentation. Dermatol Ther 34: e14729, 2021.
10. Muhialdeen AS, Ahmed JO, Baba HO, Abdullah IY, Hassan HA, Najar KA, Mikael TM, Mustafa MQ, Mohammed DA, Omer DA, *et al*: Kscien's list; a new strategy to discourage predatory journals and publishers (second version). Barw Med J 1: 30-32, 2023.
11. Altintoprak F, Kivilcim T and Ozkan OV: Aetiology of idiopathic granulomatous mastitis. World J Clin Cases 2: 852-858, 2014.
12. Camargo MD PhD A, F B, B DF, L S, J M, Ramilo MD T and Balcarce MD TG: Is it possible to avoid the late diagnosis of idiopathic granulomatous mastitis? Obstet Gynecol Int J 12: 408-413, 2021.
13. Kumar MA, Pankaja S, Kumar NG and Sunayana K: Varied clinical presentation of granulomatous mastitis-a retrospective cohort study. Int J Anat Radiol Surg 11: SO19-SO24, 2022.
14. Chirappapha P, Thaweepworadej P, Supsamutchai C, Biadul N and Lertsithichai P: Idiopathic granulomatous mastitis: A retrospective cohort study between 44 patients with different treatment modalities. Ann Med Surg (Lond) 36: 162-167, 2018.
15. Bani-Hani KE, Yaghan RJ, Matalka II and Shatnawi NJ: Idiopathic granulomatous mastitis: Time to avoid unnecessary mastectomies. Breast J 10: 318-322, 2004.
16. Diesing D, Axt-Fliedner R, Hornung D, Weiss JM, Diedrich K and Friedrich M: Granulomatous mastitis. Arch Gynecol Obstet 269: 233-236, 2004.
17. Kiyak G, Dumlu EG, Kilinc I, Tokaç M, Akbaba S, Gurer A, Ozkardes AB and Kilic M: Management of idiopathic granulomatous mastitis: Dilemmas in diagnosis and treatment. BMC Surg 14: 66, 2014.

Copyright © 2024 Salih et al. This work is licensed under a Creative Commons Attribution-NonCommercial-NoDerivatives 4.0 International (CC BY-NC-ND 4.0) License.