SPANDIDOS PUBLICATIONS

EXPERIMENTAL AND THERAPEUTIC MEDICINE 3: 865-868, 2012

Development of a new auxiliary heterotopic partial liver transplantation technique using a liver cirrhosis model in minipigs: Preliminary report of eight transplants

JUN-JING ZHANG[1,2], JIAN-XIANG NIU[2], GEN-QUAN YUE[2], HAI-YAN ZHONG[3] and XING-KAI MENG[1,2]

[1]Department of General Surgery, XuanWu Hospital, Capital Medical University, Peking 100053; Departments of [2]General Surgery, and [3]Anaesthesia, The Affiliated Hospital of Inner Mongolia Medical College, Hohhot 010050, P.R. China

Received January 11, 2012; Accepted February 10, 2012

DOI: 10.3892/etm.2012.507

Abstract. This study aimed to develop a new auxiliary heterotopic partial liver transplantation (AHPLT) technique in minipigs using a model of liver cirrhosis. Based on our previous study, 14 minipigs were induced to cirrhosis by administration of carbon tetrachloride (CCl_4) through intraperitoneal injection. All of the cirrhotic animals were utilized as recipients. The donor's liver was placed on the recipient's splenic bed, and the anastomosis was performed as follows: end-to-end anastomosis between the donor's portal vein and the recipient's splenic vein, end-to-side anastomosis between the donor's suprahepatic vena cava and the recipient's suprahepatic vena cava, and end-to-end anastomosis between the donor's hepatic artery and the recipient's splenic artery. The common bile duct of the donor was intubated and bile was collected with an extracorporeal bag. Vital signs, portal vein pressure (PVP), hepatic venous pressure (HVP) and portal vein pressure gradient (PVPG) were monitored throughout the transplantation. All 8 minipigs that developed liver cirrhosis were utilized to establish the new AHPLT; 7 cases survived. Following the surgical intervention, the PVP and PVPG of the recipients were lower than those prior to the operation ($P<0.05$), whereas the PVP and PVPG of the donors increased significantly compared to those of the normal animals ($P<0.05$). A new operative technique for AHPLT has been successfully described herein using a model of liver cirrhosis.

Correspondence to: Dr Xing-Kai Meng, Department of General Surgery, XuanWu Hospital, Capital Medical University, Peking 100053, P.R. China
E-mail: mengxingkai6788@yahoo.com.cn

Abbreviations: AHPLT, auxiliary heterotopic partial liver transplantation; CVP, central venous pressure; HR, heart rate; HVP, hepatic venous pressure; MAP, mean arterial pressure; PVP, portal vein pressure; PVPG, portal vein pressure gradient; VG, Van Gieson's stain

Key words: auxiliary heterotopic partial liver transplantation, liver cirrhosis, splenectomy, minipigs

Introduction

Auxiliary heterotopic partial liver transplantation (AHPLT), which is an important branch of liver transplantation, has been considered as the best choice for the treatment of acute liver failure and liver metabolic diseases (1-4). However, its clinical application is unsatisfactory for the treatment of chronic end-stage liver failure, for which further investigation is required to solve issues, including the lack of ideal operative technique, the liver function competition between the transplanted and host livers, and other post-operative complications (5-8). Established AHPLT in the past mainly used small or normal large animals, and was unable to simulate the characteristics of auxiliary liver transplantation of end-stage liver failure (9,10). Thereby motivated to resolve these issues, our study herein aimed to establish a new operative technique for AHPLT in minipigs using a model of liver cirrhosis.

Materials and methods

Experimental animals. Twenty-two Chinese experimental minipigs (either gender) were purchased from the laboratory animal farm of the Inner Mongolia Medical College. Fourteen minipigs (weighing 21-25 kg) were used for the establishment of the cirrhosis model, and 8 minipigs (weighting 19-23 kg) were used as donors for the improved AHPLT. The experimental protocol was approved by the Laboratory Animal Ethics Committee of the Inner Mongolia Medical College and conformed to the NIH Guidelines for the Care and Use of Laboratory Animals.

Establishment of the cirrhosis model in minipigs. Our previous study successfully produced liver cirrhosis in minipigs (11). Liver cirrhosis was induced by the intraperitoneal injection of carbon tetrachloride (CCl_4) twice a week for 9 weeks. Maize flour was the only food and a 5% alcohol-water mixture was provided for the animals. A piece of liver tissue was obtained in the 9th week and was stained with H&E and Van Gieson's (VG) stain. Meanwhile, portal vein pressure (PVP) and hepatic venous pressure (HVP) were measured by direct puncture with a 27G needle and pressure tubing attached to the normal

central venous pressure monitoring transducer, and then the portal vein pressure gradient (PVPG) was directly calculated by PVP and HVP.

Establishment of the donor procedure model. Under general anaesthesia, the donor abdominal cavity was exposed via a midline incision. The donor liver was perfused with lactated Ringer's solution at 4°C via an abdominal aorta and portal vein. Once the perfusion was finished, the whole donor liver was resected. The right lobe was resected along the line connecting the front side of the median fissure of the liver with the right edge of the suprahepatic vena cava. The collateral aorta, porta and cava vessels were ligated. The left lobe was used for the transplantation. The 2.5-cm abdominal aorta of the donor was reserved.

Recipient procedure and testing index. The venous channel was established through the internal jugular vein, and then general anesthesia and assisted respiration were carried out. After opening the abdomen, the condition of the spleen was observed and splenectomy was performed. The reserved abdominal aorta was anastomosed end-to-side with the suprahepatic vena cava of the recipient. Latex drainage tube matching the diameter of the abdominal aorta was adopted. One end of the common latex drainage tube was inserted into the anastomosed abdominal aorta and sutured. The donor liver was placed on the splenic bed, then the portal vein of the transplanted liver was anastomosed end-to-end with the splenic vein of the recipient, while the other end of the latex drainage tube was secured with the suprahepatic vena cava of the transplanted liver. Blood flow to the portal vein was thus reestablished. The common hepatic artery of the transplanted liver was end-to-end anastomosed with the splenic artery of the recipient. The donor's common bile duct was intubated and bile was collected with an extracorporeal bag (Fig. 1). After the operation, fluid infusion was given for the symptomatic treatment, and anti-rejection drugs were not administered. Throughout the transplantation process, vital signs [including the heart rate (HR), mean arterial pressure (MAP) and central venous pressure (CVP)] of the recipient pigs were measured by a central venous catheter in the right internal jugular vein and a catheter in the right internal carotid artery that was connected to a cardiac output monitor (NPB4000, USA). The PVP, HVP and PVPG of the recipients were measured at different time intervals. Additionally, the PVP, HVP and PVPG of the donors were also measured after the operation. On the 3rd day after the operation, the blood flow of every anastomosis was examined with Doppler vascular ultrasound. After being anesthetized, 2 cases were randomly selected to perform laparotomy.

Statistical analysis. SPSS13.0 software was used for data analysis. Results are expressed as the means ± SEM, unless otherwise noted. All variables were analyzed by two-way ANOVA. $P \leq 0.05$ denoted statistical significance.

Results

Fourteen minipigs were utilized to establish the cirrhosis model through administration of CCl_4 by intraperitoneal injection. After administration for 9 weeks, cirrhosis developed in 8 pigs, and 4 cases of ascites were found. An increasing spleen volume was discerned by visual inspection. Before the establishment of the cirrhosis model, the PVP, HVP and PVPG of the experimental animals were 13.66±1.15, 6.73±1.00 and 6.92±1.42 cmH_2O, respectively. After 9 weeks, the PVP, HVP and PVPG of the cirrhotic pigs were 24.52±2.84, 6.81±1.05 and 17.70±2.71 cmH_2O, respectively. The normal liver and the cirrhotic liver stained by H&E and VG are shown in Fig. 2.

Eight cases were used to establish the novel AHPLT model, 7 of which survived on the 3rd day after the operation, whereas 1 case died of bleeding of the transplanted liver section and shock at 5 h after the operation; the surgical success rate was thus 87.5% (7/8). Changes in the vital signs of the surviving 7 recipients at different time periods during the operation are shown in Table I, and the PVP, HVP and PVPG of the recipients are shown in Table II. After the blood flow to the transplanted liver was regained for 15 min, the PVP, HVP and PVPG of the donor were 21.59±1.26, 6.08±0.66 and 15.51±1.35 cmH_2O, respectively. After the blood flow of the portal vein was regained for 0.5-3 h, all experimental pigs had

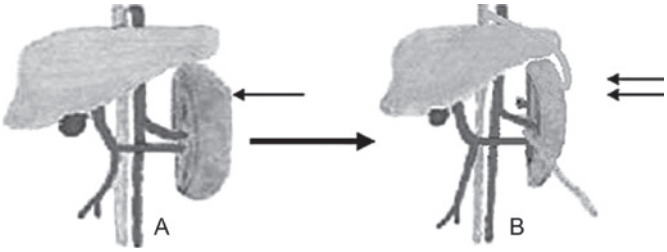

Figure 1. Diagram of the new auxiliary heterotopic partial liver transplantation. (A) The recipient spleen before transplantation (single arrow); (B) the transplanted liver after transplantation (double arrow).

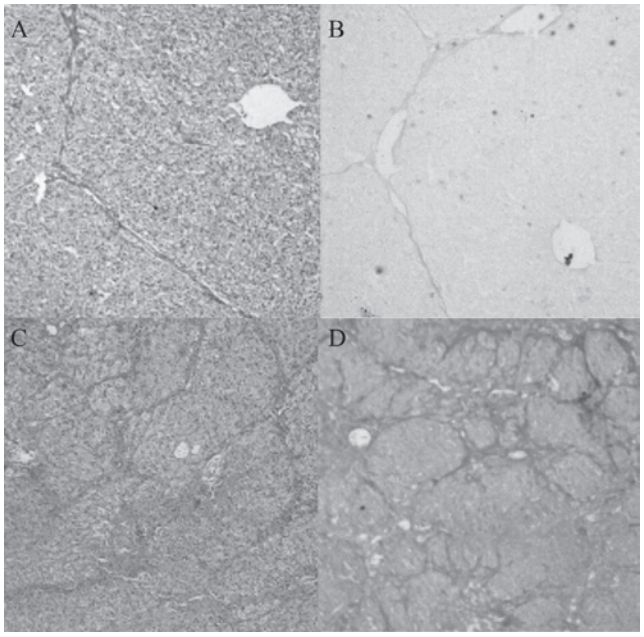

Figure 2. Normal liver and cirrhotic liver stained with H&E and VG. (A) Normal liver (H&E stain). (B) Normal liver (VG stain). (C) Formation of liver cirrhosis (H&E stain). (D) Formation of liver cirrhosis (VG stain). Magnification, x40.

Table I. Changes in the vital signs of the recipients during liver transplantation ($\bar{\chi} \pm s$, n=8).

Time	HR (/min)	MAP (mmHg)	CVP (cmH_2O)
A	130.75±6.11	120.88±4.91	5.33±0.37
B	127.87±4.29	119.13±6.10	5.31±0.43
C	136.87±5.89[a]	120.50±4.66[b]	5.20±0.40[c]

A, 5 min after opening of the abdomen of the recipient pigs. B, 10 min after the splenectomy. C, 15 min after regaining blood flow to the transplanted liver. [a]Compared to the HR of Group A and Group B, P<0.05. [b]Compared to the MAP of Group A and Group B, P>0.05. [c]Compared to the CVP of Group A and Group B, P>0.05. HR, heart rate; MAP, mean arterial pressure; CVP, central venous pressure.

Table II. Changes in PVP, HVP and PVPG of the recipients ($\bar{\chi} \pm s$; n=8).

Time	PVP (cmH_2O)	HVP (cmH_2O)	PVPG (cmH_2O)
A	24.01±2.57	6.41±0.97	17.60±2.52
B	23.10±1.78	6.18±0.93	16.93±1.68
C	21.59±1.26[a]	6.08±0.66[b]	15.51±1.35[c]

A, 5 min after opening of the abdomen of the recipient pigs. B, 10 min after the splenectomy. C, 15 min after regaining blood flow to the transplanted liver. [a]Compared to the PVP of Group A, P<0.05, and compared to the PVP of Group B, P>0.05. [b]Compared to the HVP of Group A and Group B, P>0.05. [c]Compared to the PVPG of Group A, P <0.05, and compared to the PVPG of Group B, P>0.05. PVP, portal vein pressure; HVP, hepatic venous pressure; PVPG, portal vein pressure gradient.

bile excretion. On the 3rd day after the operation, 1 case of abnormal blood flow between the suprahepatic vena cava of the transplanted liver and the latex drainage tube was discovered employing Doppler vascular ultrasound examination. Moreover, the laparotomy showed a distortion at the anastomosis, but no obvious abnormality in the blood flow of each anastomosis of the other animals was observed. Two pigs were vivisected, in which a small amount of thrombosis was found at the anastomosis between the vena cava of the transplanted liver and the latex drainage tube.

Discussion

Since Welch introduced the first case of auxiliary whole liver transplantation to dogs in 1955 (12), many improvements have been made in the urgical techniques. However, no satisfactory auxiliary heterotopic liver transplantation method has been reported hitherto. In the previous study concerning the auxiliary heterotopic liver transplantation, donor livers were mostly transplanted into the abdominal cavity, which led to an increase in abdominal pressure and circulatory disturbance. Recently, a liver was transplanted to the splenic bed of a normal animal to solve the shortage of space in the animal model (13). However, the method suffered from the limited availability of splenic vessels in the normal condition. In the present study, the auxiliary heterotopic liver transplantation model was established using a model of liver cirrhosis; the spleen of the recipient increased to further expand the transplantation space. Theoretically, cirrhosis and portal hypertension leads to hemangiectasis of the spleen, which favors the anastomosis of the blood vessels of the recipient spleen in the donor. However, no changes in the blood vessel diameter of the spleen were observed prior to and after establishment of the liver cirrhosis model, which is in need of further investigation in the future.

Moreover, in auxiliary heterotopic liver transplantation, the function competition between the recipient liver and the transplanted liver is a long-term complication, which is the most common problem requiring an urgent solution. Nevertheless, the underlying mechanism has not been completely clarified (6,10,14). Portal vein blood flow of the transplanted liver is inadequate, which is considered as an important manifestation that results from the function competition. Once the portal vein blood flowing to the transplanted liver was restored, the function competition was found to vanish (15). Portal vein blood flow is driven by the PVPG, i.e., by the pressure difference between the portal vein and the hepatic vein. Previous studies were carried out mostly using rat models of transplantation without arterial blood supply or the established normal large animal model of AHPLT, which differs greatly from the pathophysiological characteristics of clinical auxiliary heterotopic liver transplantation. The results of the present study (Table II) showed that the established minipig model of AHPLT on the basis of liver cirrhosis better simulated the characteristics of liver transplantation for human end-stage liver failure, which is therefore suitable for further exploration of the function competition mechanism. Due to the pressure gradient in the vena system, lower venous pressure occurs at the position closer to the heart. In our study, the end-to-side anastomosis of the donor vena cava and the recipient suprahepatic vena cava replaced the previous method of the donor vena cava and the recipient renal vein or the infrahepatic inferior vena cava above its level, which aimed to reduce the outflow tract pressure of the donor hepatic vein. The interaction of higher PVP and lower HVP results in a further increase in PVPG of the transplanted liver. However, in this study, 1 case of suprahepatic vena cava anastomotic distortion of the transplanted liver and the drainage tube was noted on the 3rd day after the operation. This may have resulted from the long outflow tract and the abnormal location of the liver transplantation, which is a shortcoming of this operation. Two pigs were vivisected, revealing a small amount of thrombosis at the anastomosis between the vena cava of the transplanted liver and the latex drainage tube, which may be avoided by adopting a man-made blood vessel instead of the common latex drainage tube in the living donor liver transplantation or donor conduit (donor aorta, donor vena cava and iliacs) in the cadaver liver transplantation.

Early studies have proven that AHPLT outweighs other techniques due to advantages, such as slight injury of the operation, short time of the operation, no anhepatic phase and stable hemodynamics (16,17). The results of this study also supported the above findings; the surgery success rate in the group was 87.5%, and changes in the vital signs of the recipients at different time periods were more stable.

In this study, although the observation time was short (only 3 days), a novel AHPLT technique was successfully established using a model of liver cirrhosis. In a future study, we will assess the comparison of the difference between a suprahepatic and infrahepatic venae cavae drainage model. In addition, post-transplant aspects will also be observed, including liver function of the transplanted liver compared to that of the cirrhotic liver on the long term, evolution of the blood flow and pressure over time, and the histologic analysis of both the transplanted and cirrhotic livers over time.

Acknowledgements

The authors are grateful to Jian-liang Qiao and Rui-Fang Zhang for the technical assistance. This study was supported by a research fund of the Inner Mongolia Medical College (no. Y2003ZD001), and the Natural Science Foundation of Inner Mongolia of China (no. 2010MS1126).

References

1. Jaeck D, Pessaux P and Wolf P: Which types of graft to use in patients with acute liver failure?: (A) Auxiliary liver transplant (B) Living donor liver transplantation (C) The whole liver. (A) I prefer auxiliary liver transplant. J Hepatol 4: 570-573, 2007.
2. Haberal M, Arda IS, Karakayali H, *et al*: Successful heterotopic segmental liver transplantation from a live donor to a patient with Alagille syndrome. J Pediatr Surg 4: 667-671, 2001.
3. Rela M, Battula N, Madanur M, *et al*: Auxiliary liver transplantation for propionic acidemia: a 10-year follow-up. Am J Transplant 9: 2200-2203, 2007.
4. O'Grady J: Modern management of acute liver failure. Clin Liver Dis 2: 291-303, 2007.
5. Fern RI, Palenciano CG, Ri A, *et al*: Hemodynamic assessment during auxiliary heterotopic liver transplantation with portal vein arterialization in a swine model: preliminary report of 10 transplants. Transplant Proc 8: 2603-2605, 2006.
6. Schleimer K, Stippel DL, Kasper H, *et al*: Competition between native liver and graft in auxiliary liver transplantation in a rat model. Transplant Proc 4: 967-970, 2008.
7. Willemse PJ, Ausema L, Terpstra OT, *et al*: Graft regeneration and host liver atrophy after auxiliary heterotopic liver transplantation for chronic liver failure. Hepatology 1: 54-57, 1992.
8. Tarhan NC, Firat A, Coskun M, *et al*: Diagnosis of complications in auxiliary heterotopic partial-liver transplant recipients: spiral CT findings. Turk J Gastroenterol 4: 192-197, 2002.
9. Hong IC, Mullen PM, Precht AF, *et al*: Non-viral human IL-10 gene expression reduces acute rejection in heterotopic auxiliary liver transplantation in rats. Microsurgery 5: 432-436, 2003.
10. Serrou B, Michel H and Gelis C: Study of the role of the splanchnic organs in hepatic atrophy for the purpose of auxiliary transplantation of the liver. Ann Surg 3: 274-278, 1974.
11. Zhang JJ, Meng XK, Dong C, *et a1*: Development of a new animal model of liver cirrhosis in swine. Eur Surg Res 1: 35-39, 2009 (In Chinese).
12. Welch CS: A note on transplantation of the whole liver in dogs. Transpl Bull 2: 54-55, 1955.
13. Kesen X, Nanhai S, Yuxin C, *et al*: Splenectomy and auxiliary liver transplantation. Transplant Proc 7: 2308-2309, 2000.
14. Lygidakis NJ: Segmental auxiliary liver transplantation: a new approach to an old problem. J Invest Surg 3: 246-251, 1985.
15. Kasahara M, Takada Y, Kozaki K, *et al*: Functional portal flow competition after auxiliary partial orthotopic living donor liver transplantation in noncirrhotic metabolic liver disease. J Pediatr Surg 39: 1138-1141, 2004.
16. Groenland TH, Visser L, Terpstra OT, *et al*: Stable hemodynamics during heterotopic auxiliary partial liver transplantation for end-stage liver cirrhosis. Transplant Proc 20: 538-540, 1988.
17. Terpstra OT, Schalm SW, Weimar W, *et al*: Auxiliary partial liver transplantation for end-stage chronic liver disease. N Engl J Med 23: 1507-1511, 1988.