

Successful treatment of EGFR-mutated non-small cell lung cancer with reduced-dose gefitinib: A case report

HIROKO WATANABE¹, TOMOHIRO TAMURA¹, KATSUNORI KAGOHASHI¹, NORIO TAKAYASHIKI²,
KOICHI KURISHIMA¹, HIROAKI SATOH¹ and NOBUYUKI HIZAWA³

Divisions of ¹Respiratory Medicine and ²Pathology, Department of Clinical Medicine, Mito Medical Center, University of Tsukuba, Mito, Ibaraki 310-0015; ³Division of Respiratory Medicine, Department of Clinical Medicine, Faculty of Medicine, University of Tsukuba, Tsukuba, Ibaraki 305-8575, Japan

Received August 10, 2014; Accepted May 1, 2015

DOI: 10.3892/etm.2015.2499

Abstract. Epidermal growth factor receptor (EGFR) mutation is a favorable prognostic factor of non-small cell lung cancer (NSCLC). In the majority of patients with EGFR mutations, clinical benefits of EGFR-tyrosine kinase inhibitors (TKIs) have been reported. One of the TKIs, gefitinib, appears to be less toxic to the skin than other TKIs. The present study reports a case of NSCLC with EGFR mutation (exon 19 deletion) in which dose-reduced gefitinib was effective against recurrence. Due to development of a grade 3 skin adverse event (AE) after 2 months of daily administration of gefitinib, the frequency of administration of gefitinib was reduced to every other day for 2 weeks. As the AE continued, the frequency of administration was reduced to once every 3 days. The patient has been in remission for 27 months since treatment with 250 mg gefitinib once every 3 days was initiated, which is the lowest dose to be reported in a successfully treated case of NSCLC with EGFR mutation. Dose reduction of gefitinib might be appropriate for patients with severe AEs and should be considered as a treatment option after 1 or 2 months of regular daily dosing of gefitinib if there is no other satisfactory treatment option.

Introduction

Non-small cell lung cancer (NSCLC) remains a refractory disease, even in the era of development of molecular-targeting agents. Mutated epidermal growth factor receptor (EGFR) is a favorable prognostic factor; it is observed in 20-30% of cases, and the incidence is high in the Asian population (1). EGFR-tyrosine kinase inhibitors (TKIs) have been recog-

nized as key drugs for NSCLC; the majority of studies have reported their effectiveness in the treatment of EGFR-mutated NSCLC (2). The present study reports a case of NSCLC with EGFR mutation in which the administration of gefitinib was reduced to once every 3 days.

Case report

A 65-year-old woman with no medical history presented with the incidental detection of a nodule 34 mm in diameter on chest radiography at the Mito Medical Center of the University of Tsukuba (Mito, Japan). The patient was asymptomatic and had been in good health. The physical examination was unremarkable. The chest computed tomography (CT) scan revealed a well-circumscribed mass in the middle lobe of the lung that measured 34x30x24 mm with specular appearance (Fig 1). The routine laboratory tests were normal, as were tumor markers including carcinoembryonic antigen. The patient was diagnosed with adenocarcinoma on the basis of cytological examination of transbronchial biopsy specimens. Distant metastasis was not detected. The patient underwent lobectomy of the middle of the lung and mediastinal lymph node dissection. The patient's pleural fluid was malignant and the final pathological diagnosis was lung adenocarcinoma staged as pT4bN2M1a, stage IV. An EGFR exon 19 deletion was identified. Soon after the surgical resection, the patient received five courses of chemotherapy with carboplatin and paclitaxel. In addition, the patient was treated with uracil and tegafur (UFT; Taiho Pharmaceutical Co., Ltd., Tokyo, Japan) for 6 months. However, 24 months after the surgery, four metastatic lesions ≤15 mm in diameter were identified in the right lung (Fig 2). A cerebellar metastasis with a diameter of 16 mm was also observed in brain magnetic resonance imaging (MRI) (Fig 3), which was treated with gamma knife radiotherapy. Thereafter, treatment with 250 mg gefitinib once daily was initiated. A chest CT scan after 1 month of gefitinib administration revealed that the pulmonary metastatic tumors in the right lower lobe of the lung had disappeared. A grade 3 skin adverse effect (AE) according to the National Cancer Institute Common Toxicity Criteria (version 4.0) was present. Due to the AE, the administration of gefitinib was changed to every other day following daily administration for 2 months.

Correspondence to: Professor Hiroaki Satoh, Division of Respiratory Medicine, Department of Clinical Medicine, Mito Medical Center, University of Tsukuba, Miya-machi 3-2-7, Mito, Ibaraki, 310-0015, Japan
E-mail: hiroasato@md.tsukuba.ac.jp

Key words: gefitinib, dose reduction, non-small cell lung cancer

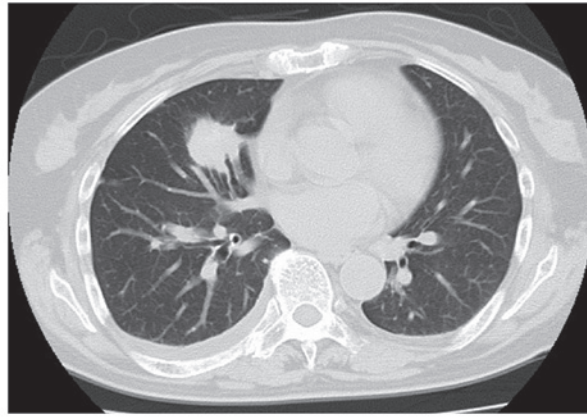


Figure 1. Chest computed tomography scan at the time of first presentation revealed a mass in the middle lobe of the lung.

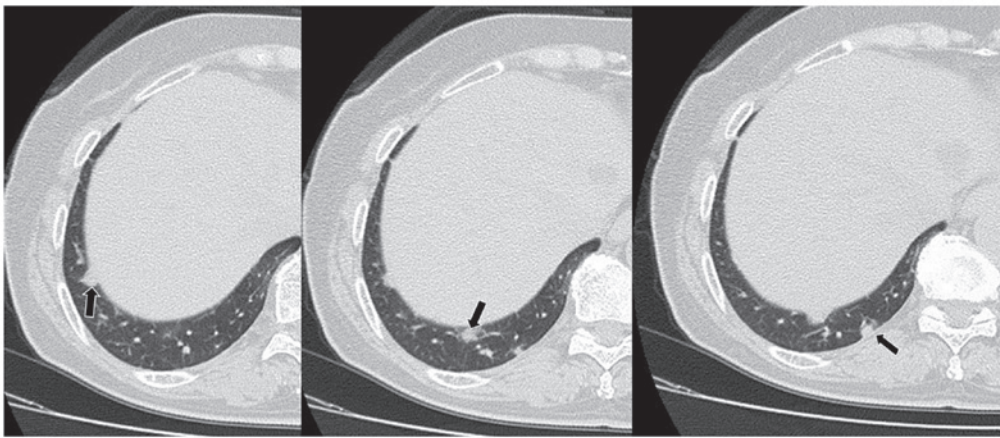


Figure 2. Follow-up chest computed tomography scan, performed 24 months after the surgery, detected pulmonary metastatic tumors ≤ 15 mm in the right lung (arrows).

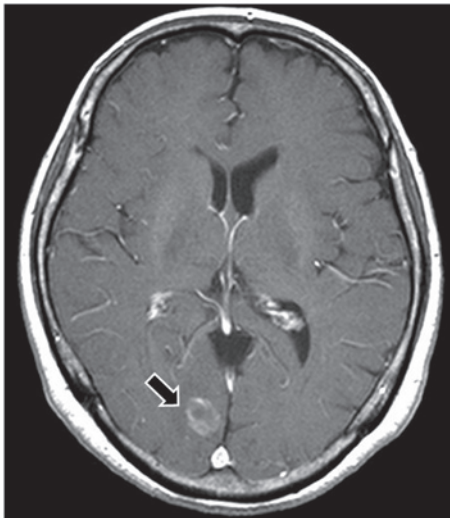


Figure 3. Follow-up brain magnetic resonance imaging, performed 24 months after the surgery, detected a cerebellar metastasis (arrow).

However, the skin AE continued and the patient requested further dose reduction. After discontinuation of gefitinib for 1 week, treatment was restored at a frequency of once every

3 days. Treatment with gefitinib was continued in the outpatient clinic without tumor recurrence, including in the lung as well as in the brain, for 27 months from the initiation of the reduction in frequency of gefitinib treatment to once every 3 days. Informed consent was obtained from the patient prior to treatment.

Discussion

Gefitinib has been reported to be the preferred choice of treatment for NSCLC with EGFR mutation (2). Three previous case reports of successful treatment with a low dose of gefitinib exist, and they are restricted to elderly patients and patients with severe AEs (3-5). Hanaoka *et al* reported a case of postoperative recurrent lung cancer in an octogenarian patient that responded to treatment with radiation and gefitinib. The authors considered that a useful treatment option for octogenarians with postoperative recurrent lung cancer could be the administration of gefitinib every other day following daily administration for two weeks (3). Tomisaki *et al* reported the successful treatment of a patient with advanced lung cancer and brain metastasis after gamma knife radiotherapy and chemotherapy, when gefitinib was administered every other day. The frequency of administration of gefitinib was reduced

to every other day because of grade 3 skin reaction and rash (4). The reduction was initiated following the discontinuation of treatment after 1 month of daily administration of gefitinib (4). Kitamura *et al* reported a case who remained in good condition over 5 years with the administration of gefitinib every other day (5). Very recently, we also evaluated the dose reduction of TKIs in the treatment of NSCLC (6). In the patients tested, not only patients with AEs but also elderly patients and patients with low body surface area underwent dose reduction of TKIs (6). Notably, the progression-free survival of patients who underwent dose reduction was not shorter than that of the patients who did not undergo dose reduction (6).

Currently, the present case has been in remission from lung adenocarcinoma for 27 months with once every 3 day administration of 250 mg gefitinib, which, to the best of our knowledge, is the lowest dose to be reported in a successfully treated case of EGFR-mutated NSCLC. In this case, dose reduction was performed due to skin AE. The patient was treated with gefitinib daily for 2 months, every other day for 1 month and then once every 3 days. From the results of previous studies (3-6) and the present one, it is speculated that dose reduction would be indicated in patients who respond well to the daily administration of gefitinib for >1 month, if required.

In the present case, measurements of serum gefitinib levels were not taken. There have been certain reports showing that the serum levels of gefitinib have an association with the effect of the drug (7,8). By contrast, other studies did not confirm the association (9-11). At present, therefore, it remains beyond our knowledge to whom exactly the reduction of gefitinib dosage should be permitted without any loss of clinical efficacy.

In summary, the present study describes a case in which dose-reduced gefitinib was effective and a 27-month disease control was achieved. However, such an irregular administration of gefitinib is not recommended. Dose reduction may be an alternative treatment option to be considered for patients who respond well to gefitinib, in cases where there is no other satisfactory choice of treatment.

References

1. Yang CH: EGFR tyrosine kinase inhibitors for the treatment of NSCLC in East Asia: Present and future. *Lung Cancer* 60 (Suppl 2): S23-S30, 2008.
2. Sanford M and Scott LJ: Gefitinib: A review of its use in the treatment of locally advanced/metastatic non-small cell lung cancer. *Drugs* 69: 2303-2328, 2009.
3. Hanaoka T, Sone S, Yamaguchi S, Okada M and Hayano T: An octogenarian case of postoperative recurrent lung cancer responding to treatments with radiation plus gefitinib. *Gan To Kagaku Ryoh* 34: 1701-1703, 2007 (In Japanese).
4. Tomisaki S, Takenaka T, Morizono G, Tanaka T, Momosaki N and Inoue F: Successful gefitinib every other day administration in an advanced lung cancer patient with brain metastasis after gamma knife radiotherapy and chemotherapy. *Gan To Kagaku Ryoh* 36: 2607-2610, 2009 (In Japanese).
5. Kitamura Y, Sakakura N, Uchida T and Suyama M: Limitation of apoptosis induced by gefitinib in a long-surviving postoperative recurrent lung cancer case. *Gan To Kagaku Ryoh* 38: 275-277, 2011 (In Japanese).
6. Sato S, Kurishima K, Miyazaki K, Kodama T, Ishikawa H, Kagohashi K, Tamura T, Homma S, Satoh H and Hizawa N: Efficacy of tyrosine kinase inhibitors in non-small-cell lung cancer patients undergoing dose reduction and those with a low body surface area. *Mol Clin Oncol* 2: 604-608, 2014.
7. McKillop D, Partridge EA, Kemp JV, Spence MP, Kendrew J, Barnett S, Wood PG, Giles PB, Patterson AB, Bichat F, Guilbaud N and Stephens TC: Tumor penetration of gefitinib (Iressa), an epidermal growth factor receptor tyrosine kinase inhibitor. *Mol Cancer Ther* 4: 641-649, 2005.
8. Wang S, Zhou Q and Gallo JM: Demonstration of the equivalent pharmacokinetic/pharmacodynamic dosing strategy in a multiple-dose study of gefitinib. *Mol Cancer Ther* 8: 1438-1447, 2009.
9. Ranson M, Hammond LA, Ferry D, Kris M, Tullo A, Murray PI, Miller V, Averbuch S, Ochs J, Morris C, Feyereislova A, Swaisland H and Rowinsky EK: ZD1839, a selective oral epidermal growth factor receptor-tyrosine kinase inhibitor, is well tolerated and active in patients with solid, malignant tumors: Results of a phase I trial. *J Clin Oncol* 20: 2240-2250, 2002.
10. Nakagawa K, Tamura T, Negoro S, Kudoh S, Yamamoto N, Yamamoto N, Takeda K, Swaisland H, Nakatani I, Hirose M, Dong RP and Fukuoka M: Phase I pharmacokinetic trial of the selective oral epidermal growth factor receptor tyrosine kinase inhibitor gefitinib ('Iressa', ZD1839) in Japanese patients with solid malignant tumors. *Ann Oncol* 14: 922-930, 2003.
11. Wolf M, Swaisland H and Averbuch S: Development of the novel biologically targeted anticancer agent gefitinib: Determining the optimum dose for clinical efficacy. *Clin Cancer Res* 10: 4607-4613, 2004.