

# Effects of preserving different veins on flow-through flap survival: An experimental study

JIAN SONG, ZONGHUAN LI and AIXI YU

Department of Orthopedics, Zhongnan Hospital of Wuhan University, Wuhan, Hubei 430071, P.R. China

Received March 8, 2015; Accepted October 29, 2015

DOI: 10.3892/etm.2015.2869

**Abstract.** Flow-through skin flap grafting is becoming widely used for the reconstruction of skin and soft tissue defects, particularly for patients with poor blood supply around the defect. However, the treatment of the veins remains controversial. In the present study, 5x2-cm skin flaps were created on the left inner thighs of rabbits in order to investigate the effects of various treatments of the veins on the survival of a flow-through skin flap. A femoral artery perforator running through the flap was preserved. Five groups were established in which no veins, one superficial vein (SV), one accompanying vein (AV), one SV plus one AV, or all trunk veins (control) were retained. The percentage of flap area survival was determined on day 10. On days 3, 5, 7 and 9, tissues were harvested from the skin flaps and immunohistochemical analysis was performed in order to count the number of microvessels. Western blot analysis was subsequently completed in order to determine the expression levels of vascular endothelial growth factor (VEGF). The flap areas in which no veins were retained demonstrated significantly reduced survival rates on day 10, as compared with those in the other four groups ( $P<0.01$ ). Furthermore, flaps with the retention of a SV also demonstrated reduced survival rates, as compared with the AV, AV plus SV and all veins groups ( $P<0.01$ ); however, there no significant differences were detected between the latter three groups ( $P>0.05$ ). Immunohistochemical analysis on day 3 detected a greater number of microvessels in the flaps of the control group, as compared with the flaps of the other groups. Furthermore, the AV and AV plus SV groups demonstrated a greater number of microvessels, as compared with the SV and no vein groups, and the no vein group demonstrated the fewest microvessels. No significant differences were found between the AV, AV plus SV and control groups on day 5, 7 and 9. Western blot analysis on day 5 demonstrated that the expression levels of VEGF were significantly increased in the flaps of the AV, AV

plus SV and control groups, as compared with those in the SV and no vein groups. No significant differences were detected between the former three groups, and increased VEGF expression levels were detected in the flaps of the SV group, as compared with the no vein group. The flow-through flap grafts with no retained veins barely survived. Anastomosing one AV was adequate for flap survival; however, further studies are required in order to investigate the survival of flow-through flaps in more detail.

## Introduction

In recent years, trauma and chronic wounds have been caused by a greater number of reasons, with a 4% increase in the number of patients suffering from soft tissue defects in combination with bone or tendon exposure reported every year since 2000 (1-4). Reconstructing the defects is essential but challenging, particularly for patients with a weak blood supply. The most common therapeutic approach in the treatment of these defects is a flap graft, while the conventional treatment of vessels is end-to-end anastomoses of the grafting flap and recipient area for the main supplying artery, with one or two grafting veins also being anastomosed. However, conventional surgery sacrifices the major vessel of the grafting flap; immediate postoperative monitoring of circulation to the graft is also required, demanding a surgical team skilled in this microvascular technique, and involving a long operative time. The flow-through technology was first introduced clinically by Soutar *et al* (5) in 1983, and the procedure involved using a radial arterial flap in the reconstruction of the head and neck. The use of a flow-through compound radial artery forearm flap in reconstruction of the extremities was reported in 1984 (6). This operative technology was adopted to recover the integrity of the grafting trunk vessel by anastomosing its two extremities; the surgery not only reconstructs the defects, but also increases the blood supply to the distal limbs, especially for patients with only one remaining trunk vessel (7-9). Patients suffering soft tissue defects combined with tendon or bone exposure are required to undergo several surgical procedures, causing severe damage to the majority of the trunk veins. Reconstructing such kinds of defects is challenging, and the optimum treatment of the grafting veins remains controversial. The present study was conducted with the aim of exploring the effects of the preservation of different grafting veins on flow-through flap survival.

---

*Correspondence to:* Professor Aixi Yu, Department of Orthopedics, Zhongnan Hospital of Wuhan University, 169 Donghu Road, Wuhan, Hubei 430071, P.R. China  
E-mail: yuaixi@whu.edu.cn

**Key words:** flow-through flap, superficial vein, accompanying vein

## Materials and methods

**Experimental animal model and skin flap measurement.** All experiments were approved by the Institutional Animal Care and Use Committee of Wuhan University (Wuhan, China), and the animal procedures were performed in strict accordance with institutional and national guidelines (10). All efforts were made to minimize suffering.

A total of 50 Japanese white ear rabbits weighing 2.5–3.5 kg were purchased from and housed in the approved animal care facility at the Center for Animal Experiments of Wuhan University (Wuhan, China). Rabbits were randomly divided into five groups (each  $n=10$ ) and were anesthetized via intramuscular injection of 1% pentobarbital sodium (30 mg/kg). Subsequently, the inner thighs of the rabbits were shaved, treated with betadine solution and sterilized with iodine followed by 75% ethanol. A 5x2-cm skin flap was then created on the left inner thigh of each rabbit.

In each rabbit, a superficial femoral artery perforator running through the flap was preserved. Skin flaps in which all trunk veins were retained were used in the control group, and various numbers/types of veins were retained in the four experimental groups: No veins, one superficial vein (SV), one accompanying vein (AV), one SV plus one AV. Each rabbit received antibiotic therapy ( $8 \times 10^5$  IU) by intramuscular injection following the surgery in order to prevent infection of the skin flaps.

Survival was determined on day 10. Tissues were collected from the central portion of the skin flaps on day 3, 5, 7 and 9 for immunohistochemical analysis to count the number of microvessels. Western blotting was also carried out to evaluate the expression levels of vascular endothelial growth factor (VEGF), which serves as an indicator of the growth of new blood microvessels. Rabbits were anesthetized via intramuscular injection of 15% pentobarbital sodium (30 mg/kg) on day 10. All rabbits were sacrificed via decapitation following the experiment.

**Percentage survival of the flap areas.** The condition of each skin flap was checked every day after the surgery. The percentage of the skin flap area that survived (survival rate) on day 10 was determined with the use of Image Pro-Plus software (version 7; Media Cybernetics, Inc., Rockville, MD, USA) due to retraction of the skin flaps. The survival rates of the flap areas were analyzed and compared between different groups with the Image Pro-Plus software.

**Immunohistochemical analysis of microvessels.** Counting of the microvessels in the skin flaps was conducted with staining of Factor VIII. Tissues collected from the skin flaps were cut to 5- $\mu$ m thickness and embedded in paraffin. For analysis, the tissue sections were deparaffinized and then treated with 20 mg/ml proteinase K (Roche Diagnostics, Basel, Switzerland) for 15 min (3x5 min). Endogenous peroxidase was blocked by incubating the sections with 3% hydrogen peroxide for  $\geq 10$  min. The sections were then washed with phosphate-buffered saline (PBS) and treated with blocking reagent (Santa Cruz Biotechnology, Inc., Dallas, TX, USA). Anti-rabbit anti-Factor VIII polyclonal antibody (1:1,000; bs-0434R; Beijing Biosynthesis Biotechnology Co., Ltd.,

Beijing, China) was applied to the sections, which were then incubated at room temperature for 1 h. The sections were rinsed with PBS repeatedly and then incubated with fluorescein isothiocyanate (FITC)-conjugated secondary antibodies (1:500; HP1201; Amyjet Scientific, Inc., Wuhan, China) for 30 min at room temperature. After treating the antibodies with avidin-biotinylated enzyme complex in combination with peroxidase substrate solution (both Roche Diagnostics) for 2 min, they were then visualized. Mayer's hematoxylin was also used to counter-stain the sections for 5 min. The stained blood microvessels on each slide in the most vascularized area of the section were counted. Tissue sections were scanned under high magnification to identify the areas with the greatest amount of vascularization; the specific number of microvessels was counted in a high-power field of x400 for five non-overlapping areas.

**Western blot analysis for VEGF.** Skin flap tissues were homogenized in buffer with an added protease inhibitor cocktail (Roche Diagnostics), which consisted of 10 mM NaCl, 50 mM Tris, 1% NP-40 and 0.02% sodium azide. Subsequently, homogenates were put into filtered centrifuge tubes and centrifuged at  $10,000 \times g$  for 15 min at room temperature. Following dissolution in Laemmli buffer (Santa Cruz Biotechnology, Inc.), the proteins were separated by 10% sodium dodecyl sulfate-polyacrylamide gel electrophoresis and transferred to polyvinylidene difluoride membranes. The membranes were blocked with 5% milk for 5–10 min and incubated with primary antibody at 4°C overnight. The polyclonal primary antibodies targeted VEGF (1:200; sc-507) or  $\beta$ -actin (1:10,000; sc-1616; both Santa Cruz Biotechnology, Inc.) as a loading control. Blots were rinsed several times with Tris-buffered saline containing 0.05% Tween-20 (TBST) and then incubated with horseradish peroxidase (HRP)-labeled secondary antibodies (1:200; HP1201; Amyjet Scientific, Inc.). Finally, the blots were washed again with TBST. Positive signals were generated after the blots were incubated with a luminescent HRP substrate (Roche Diagnostics) for 1–2 min. Using a high-resolution flatbed scanner and ImageJ densitometry software (version 1.45; National Institutes of Health, Bethesda, MD, USA), the optical densities of at least three replicates of each group were quantified and the densities were expressed for each group on the basis of their intensities relative to  $\beta$ -actin.

**Statistical analysis.** Unpaired Student's t-tests were used to perform between-group comparisons using SPSS 17.0 software (SPSS, Inc., Chicago, IL, USA).  $P < 0.05$  was considered to indicate a significant difference.

## Results

**Survival rates of the skin flap areas.** The survival status of each flap was assessed daily, representative images were captured on day 10 (Fig. 1) and the survival rates were analyzed (Fig. 2). The results of the present study demonstrated that skin flaps with no veins faced more difficult survival conditions and had a lower survival rate, as compared with the other groups ( $P < 0.01$ ). Improved survival states and rates were demonstrated in the AV, SV plus AV

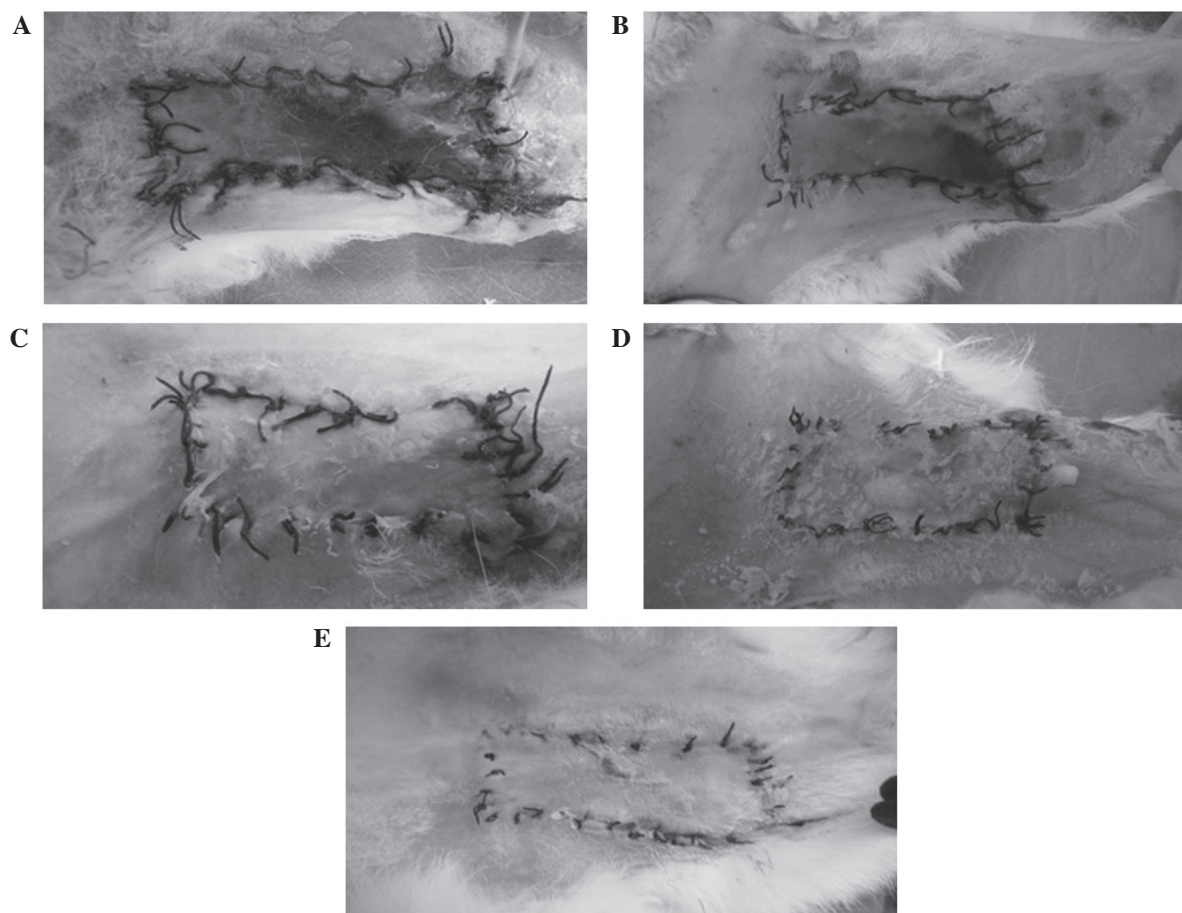


Figure 1. Survival status of the flaps on day 10. Representative images from the (A) no vein, (B) superficial vein, (C), accompanying vein, (D) superficial vein plus accompanying vein and (E) all veins (control) group.

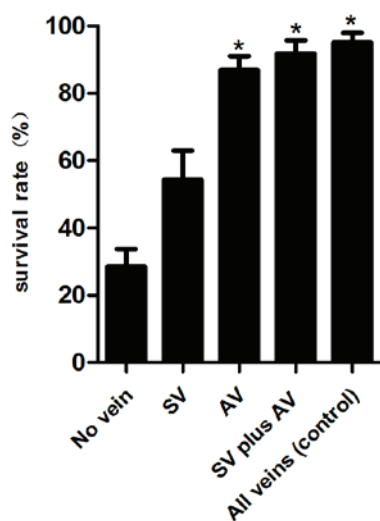


Figure 2. Survival rate of the flap areas on day 10 (n=10 rabbits per group). \* $P < 0.05$ , no significant differences were detected between the accompanying vein (AV), superficial vein (SV) plus AV and control groups. Data are presented as the mean  $\pm$  standard deviation.

and all veins (control) groups, as compared with the SV and no vein groups ( $P < 0.01$ ); however, no significant differences were detected between the former three groups ( $P > 0.05$ ).

**Density of microvessels.** Microvessels in the skin flaps were counted by staining for Factor VIII on days 3, 5, 7 and 9 (Figs. 3 and 4). On day 3, the flaps of the all veins (control) group demonstrated the greatest microvessel count; the microvessel counts of the AV and SV plus AV groups were greater than those of the SV and no vein groups; and the flaps with a SV had greater numbers of microvessels than those with no veins. However, no significant differences were identified on days 5, 7 and 9 between the AV, SV plus AV and all veins (control) groups, and the results for the remaining two groups were as described on day 3.

**Expression levels of VEGF.** VEGF expression is considered to be an important indicator of the development of new microvessels which can also promote angiogenesis in wound healing (11-13). In order to test the effects of the various vein treatments on the flow-through skin flap grafts, western blot analysis was performed to determine the expression levels of VEGF on day 5 (Figs. 5 and 6). The expression levels of VEGF were increased in the flaps of the AV, SV plus AV and all veins groups, as compared with those in the SV and no vein groups; however no significant differences were identified between the former three groups. The flaps with the retention of a SV exhibited a higher VEGF expression levels, as compared with that of the flaps in which no veins were retained.






Figure 3. Microvessels in the tissues of flaps as demonstrated by immunohistochemical staining for Factor VIII on day 5. Representative images from the (A) no vein, (B) superficial vein, (C) accompanying vein, (D) superficial vein plus accompanying vein and (E) all veins (control) groups. Magnification, x400.

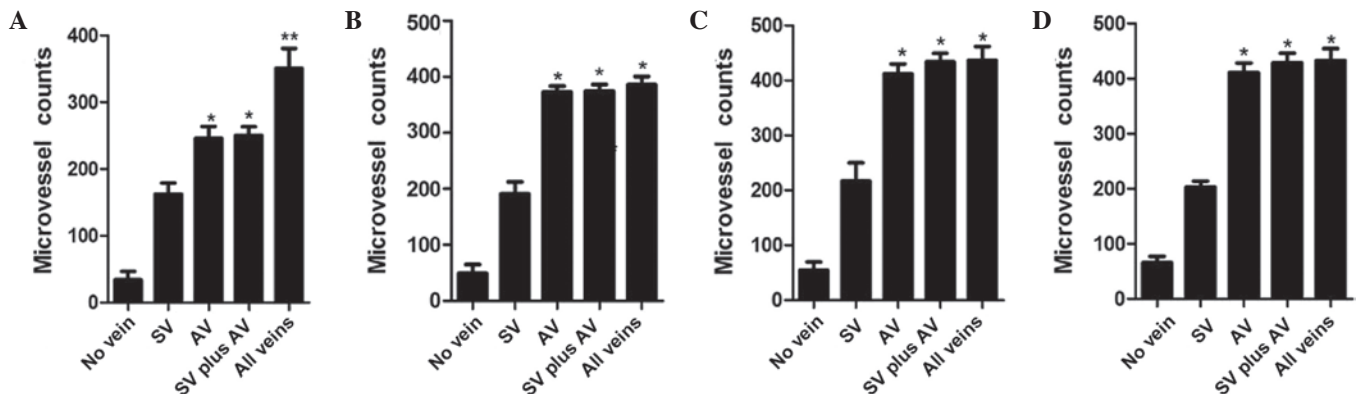


Figure 4. Microvessel counts of flaps on days (A) 3, (B) 5, (C) 7 and (D) 9. (A) Counts on day 3 (n=10 rabbits per group). \* $P < 0.05$ , no significant difference in microvessel counts between the accompanying vein (AV) and superficial vein (SV) plus AV groups; \*\* $P < 0.05$ , the control group demonstrated a significantly higher microvessel count than the AV and SV plus AV groups. (B-D) Counts on days 5, 7 and 9, respectively. \*Data are presented as the mean  $\pm$  standard deviation.  $P > 0.05$ , no significant differences between the AV, SV plus AV and control groups.

## Discussion

Soft tissue defects in combination with bone or tendon exposure are refractory, and patients suffering from them are faced with a long period of hospitalization, high expense during the hospital stay, and poor prognosis (14,15). Reconstruction of the defect is rather difficult, and the most common therapy is a flap graft, which in addition to reconstructing the defect

also provides the defect with a blood supply. The conventional treatment of the blood vessels is end-to-end anastomoses of the donor and recipient area for the artery, which help to provide the defects with a blood supply. Typically, 1 or 2 veins of the skin flaps are also anastomosed with veins near the defect area, which facilitates the return of venous blood from the grafting flaps, and improves the survival rate. However, the common operative technology destroys the integrity




Figure 5. Representative western blotting of vascular endothelial growth factor (VEGF) protein on day 5 (n=10 rabbits per group).  $\beta$ -actin was used as the loading control. SV superficial vein; AV accompanying vein.

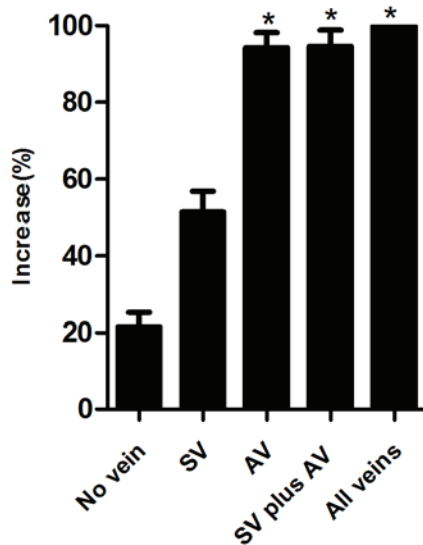


Figure 6. Expression of vascular endothelial growth factor (VEGF) protein on day 5 (n=10 rabbits per group). Data are presented as the mean  $\pm$  standard deviation. \* $P < 0.05$ , no significant differences were detected between the accompanying vein (AV), superficial vein (SV) plus AV and control groups.

and structure of the grafting vessels; the blood supply is also weakened because of ligation of the distal flap artery. The prognosis for patients with a poor blood supply to the recipient area is poor if a conventional flap grafting procedure is adopted to reconstruct the defects (16,17).

The clinical use of flow-through flap grafting to reconstruct a soft tissue defect in combination with bone or tendon exposure has been widely accepted and good results are achieved, particularly for patients with only one remaining trunk artery. The surgical technology has been applied to various flaps with axial vascular patterns and appropriate distal vessel sizes, including free forearm flaps, free fibular flaps and anterolateral thigh flaps (18-20). The application of this surgical technology not only reconstructs the defects, but also recovers continuity of the trunk vessels, and thereby stabilizes the blood circulation in the flap. It has been demonstrated that flow-through arterial anastomosis has a higher

patency rate than end-to-end and end-to-side anastomoses, and increases the flow rate through the anastomotic sites (21). Miyamoto *et al* (22) considered that flow-through arterial anastomosis helped to maintain a high rate of blood flow through the anastomotic site and facilitated early mobilization for patients undergoing skin flap grafting.

Application of venous flow-through flaps in the reconstruction of soft tissue defects has been widely used, which can involve flow-through flaps as a vessel carrier or arterialized venous flaps (23,24). The difference between venous flow-through flaps and conventional flaps is that arterial inflow-capillary-venous outflow is replaced by venous inflow-venous outflow (25). There are three main theories that may explain the possible mechanisms by which the venous flaps survive. The first is 'reverse flow', which means intermittent flow with perfusion of the blood from the flap vein to the capillary and then back to the vein (26), while the second theory is 'A-V shunting', which means retrograde flow from the venous system to the arterial system via paralyzed arterial-venous shunts (27). The third theory is 'capillary bypass', which means that the flow is through the venous system without entry into the arterial system until neovascularization has occurred (28).

The present study was conducted in order to explore the effects of different treatments of trunk veins on grafting flap survival. The results demonstrated that a flow-through flap without the retention of any veins retention exhibited the ability to survive, although the survival state was poorer than that of skin flaps in which one or two veins were retained. The processes underlying the survival remain controversial, however there are several hypotheses. Anastomosing the two extremities of the artery creates a channel, which helps to facilitate venous drainage from the grafting flap, relieving much of the hydrostatic pressure of the area; the perforating veins, which forms in the early stage of grafting, combine with the capillary network, which forms in the late stage, to create blood circulation between the donor and recipient areas, resulting in the drainage of venous blood from the grafting flap; the bone marrow cavity beneath the graft provided a venous channel, which helps to drain the majority of the venous blood from the flap (7,9,29,30). Thoracic negative pressure induced when a respiratory pump is used, and the inherent venous pressure of the flap may also be important forces that drive the return of venous blood (22).

Certain surgeons have hypothesized that performing two venous anastomoses (AV and SV) is imperative for the survival of flow-through flap grafts because multiple draining veins result in improved blood flow through the flap (31,32). Hanasono *et al* (33) considered that the blood velocity of a flap graft with two venous anastomoses did not increase significantly and resulted in a better prognosis when compared with one venous anastomosis (AV) in patients who underwent a flap graft with one or two anastomoses, due to the hypothesis that thrombosis is associated with a low-velocity state and performing two anastomoses theoretically increased the risk of thrombosis. The results of the present study are consistent with this, with regard to the survival condition on day 3, the survival rate on day 10, the microvessel counts and VEGF expression levels. Ross *et al* (34) found that flaps with two venous anastomoses did not have a higher survival rate than

flaps with one venous anastomosis (93.6 and 98.6%, respectively).

Aside from the risk of an anastomotic thrombosis, which may result in failure of the graft, it may be hypothesized that performing a single venous anastomosis could result in the loss of the flap graft as a result of insufficient drainage of the flap, because the anastomosed vein drains only a specific area of the grafting flap. However, there is little evidence in the literature to support this hypothesis, and multiple interconnections between the AV and SVs over the course of the pedicle and multiple microcirculatory communications create a channel that can help to transport blood from superficial to deep portions of the grafting flap (33). Therefore, we believe that just one deep venous anastomosis near the defect is adequate for survival of the grafting flap. It has been observed clinically and experimentally in anatomical studies that venous insufficiency caused by limited communication between the superficial and deep vascular networks may affect the survival of the grafting flap; however, this applies only to patients undergoing replants or in flaps where trauma to the donor or recipient vessel cannot be ruled out (35,36). The results of the present study also indicate that the retention of a SV is not sufficient for the complete survival of the grafting flap, because the interconnection between the AV and SV is unidirectional, which means that blood from the SV can flow to the accompanying (deep) vein, but the reverse cannot occur.

A limitation of this study is that the animal model may have some differences from clinical conditions in the aspects of blood velocity, patency rate of the blood vessels and state. Increases in the operative time of vascular anastomosis may also increase the risk of thrombosis; however, this was not examined in the present experimental study. Furthermore, the present study indicates that one SV is not sufficient for survival of the grafting flap. Further study is required to investigate whether the retention of a greater number of SVs is beneficial to flap survival.

In conclusion, the results of the present study demonstrated that a flow-through flap graft can survive with only one remaining trunk artery, and a greater number of anastomosed veins does not increase the survival of the flaps.

## Acknowledgements

The present study was supported by Hubei Province's Outstanding Medical Academic Leader Programme.

## References

- Mao H, Shi Z, Yin W, Dong W and Wapner KL: Reconstruction of great toe soft-tissue defect with the retrograde-flow medial pedis island flap. *Plast Reconstr Surg* 134: 120e-127e, 2014.
- Nikkhah D and Jones M: The bilobed flap as a lifeboat flap for a forearm soft tissue defect. *J Plast Reconstr Aesthet Surg* 68: 1153-1154, 2015.
- Chen C, Tang P and Zhang X: Treatment of soft-tissue loss with nerve defect in the finger using the boomerang nerve flap. *Plast Reconstr Surg* 131: 44e-54e, 2013.
- Melton LJ III: Does high-trauma fracture increase the risk of subsequent osteoporotic fracture? *Nat Clin Pract Endocrinol Metab* 4: 316-317, 2008.
- Soutar DS, Scheker LR, Tanner NS and McGregor IA: The radial forearm flap: A versatile method for intra-oral reconstruction. *Br J Plast Surg* 36: 1-8, 1983.
- Foucher G, van Genechten F, Merle N and Michon J: A compound radial artery forearm flap in hand surgery: An original modification of the Chinese forearm flap. *Br J Plast Surg* 37: 139-148, 1984.
- Hsiao YC, Yang JY, Chang CJ, Lin CH, Chang SY and Chuang SS: Flow-through anterolateral thigh flap for reconstruction in electrical burns of the severely damaged upper extremity. *Burns* 39: 515-521, 2013.
- Miyamoto S, Kayano S, Fujiki M, Kamizono K, Fukunaga Y and Sakuraba M: Flow-through divided latissimus dorsi musculocutaneous flap for large extremity defects. *Ann Plast Surg* 74: 199-203, 2015.
- Parr JM, Adams BM and Wagels M: Flow-through flap for salvage of fibula osseocutaneous vascular variations: a surgical approach and proposed modification of its classification. *J Oral Maxillofac Surg* 72: 1197-1202, 2014.
- Jones-Bolin S: Guidelines for the care and use of laboratory animals in biomedical research. *Curr Protoc Pharmacol Appendix* 4: 4B, 2012.
- Pitulescu ME and Adams RH: Regulation of signaling interactions and receptor endocytosis in growing blood vessels. *Cell Adh Migr* 8: 366-377, 2014.
- Bao P, Kodra A, Tomic-Canic M, Golinko MS, Ehrlich HP and Brem H: The role of vascular endothelial growth factor in wound healing. *J Surg Res* 153: 347-358, 2009.
- Keswani SG, Balaji S, Le LD, Leung A, Parvadia JK, Frischer J, Yamano S, Taichman N and Crombleholme TM: Role of salivary vascular endothelial growth factor (VEGF) in palatal mucosal wound healing. *Wound Repair Regen* 21: 554-562, 2013.
- Yang JL, Zhang GL and Zhao LX: Delayed of reverse sural nerve flap to repair large soft tissue defect on foot: A case report. *Zhongguo Gu Shang* 26: 906-907, 2013 (In Chinese).
- Lu S and Chai Y: Clinical application of sural fasciomyocutaneous perforator flap in repair of soft tissue defect in weight-bearing area of foot. *Zhongguo Xiu Fu Chong Jian Wai Ke Za Zhi* 28: 1494-1497, 2014 (In Chinese).
- Persichetti P, Brunetti B, Aveta A and Segreto F: Reverse-flow medial sural artery perforator flap: Pedicle extension for distal lower limb defects. *Ann Plast Surg* 70: 246-247, 2013.
- Shahzad MN, Ahmed N and Qureshi KH: Reverse flow posterior interosseous flap: Experience with 53 flaps at Nishtar Hospital, Multan. *J Pak Med Assoc* 62: 950-954, 2012.
- Koshima I, Kawada S, Etoh H, Kawamura S, Moriguchi T and Sonoh H: Flow-through anterior thigh flaps for one-stage reconstruction of soft-tissue defects and revascularization of ischemic extremities. *Plast Reconstr Surg* 95: 252-260, 1995.
- Kasten SJ, Chung KC and Tong L: Simultaneous revascularization and soft tissue coverage in the traumatized upper extremity with a flow-through radial forearm free flap. *J Trauma* 47: 416-419, 1999.
- Nişancı M, Selçuk I and Duman H: Flow-through use of the osteomusculocutaneous free fibular flap. *Ann Plast Surg* 48: 435-438, 2002.
- Miyamoto S, Okazaki M, Ohura N, Shiraishi T, Takushima A and Harii K: Comparative study of different combinations of microvascular anastomoses in a rat model: End-to-end, end-to-side and flow-through anastomosis. *Plast Reconstr Surg* 122: 449-455, 2008.
- Miyamoto S, Kayano S, Fujiki M, Chuman H, Kawai A and Sakuraba M: Early mobilization after free-flap transfer to the lower extremities: Preferential use of flow-through anastomosis. *Plast Reconstr Surg Glob Open* 2: e127, 2014.
- Karacalar A and Ozcan M: Free arterialized venous flap for the reconstruction of defects of the hand: New modifications. *J Reconstr Microsurg* 10: 243-248, 1994.
- Yan H, Fan C, Gao W, Chen Z, Li Z and Chi Z: Finger pulp reconstruction with free flaps from the upper extremity. *Microsurgery* 32: 406-414, 2012.
- Nakayama Y, Soeda S and Kasai Y: Flaps nourished by arterial inflow through the venous system: An experimental investigation. *Plast Reconstr Surg* 67: 328-334, 1981.
- Baek SM, Weinberg H, Song Y, Park CG and Biller HF: Experimental studies in the survival of venous island flaps without arterial inflow. *Plast Reconstr Surg* 75: 88-95, 1985.
- Chavoin JP, Rouge D, Vachaud M, Boccalon H and Costagliola M: Island flaps with an exclusively venous pedicle. A report of eleven cases and a preliminary haemodynamic study. *Br J Plast Surg* 40: 149-154, 1987.
- Matsushita K, Firrell JC, Ogden L and Tsai TM: Blood flow and tissue survival in the rabbit venous flap. *Plast Reconstr Surg* 91: 127-137, 1993.

29. Kells AF, Broyles JM, Simoa AF, Lewis VO and Sacks JM: Anterolateral thigh flow-through flap in hand salvage. *Eplasty* 13: e19, 2013.
30. Yokota K, Sunagawa T, Suzuki O, Nakanishi M and Ochi M: Short interposed pedicle of flow-through anterolateral thigh flap for reliable reconstruction of damaged upper extremity. *J Reconstr Microsurg* 27: 109-114, 2011.
31. Kroll SS, Schusterman MA, Reece GP, Miller MJ, Evans GR, Robb GL and Baldwin BJ: Timing of pedicle thrombosis and flap loss after free-tissue transfer. *Plast Reconstr Surg* 98: 1230-1233, 1996.
32. Chen KT, Mardini S, Chuang DC, Lin CH, Cheng MH, Lin YT, Huang WC, Tsao CK and Wei FC: Timing of presentation of the first signs of vascular compromise dictates the salvage outcome of free flap transfers. *Plast Reconstr Surg* 120: 187-195, 2007.
33. Hanasono MM, Kocak E, Ogunleye O, Hartley CJ and Miller MJ: One versus two venous anastomoses in microvascular free flap surgery. *Plast Reconstr Surg* 126: 1548-1557, 2010.
34. Ross GL, Ang ES, Lannon D, Addison P, Golger A, Novak CB, Lipa JE, Gullane PJ and Neligan PC: Ten-year experience of free flaps in head and neck surgery. How necessary is a second venous anastomosis? *Head Neck* 30: 1086-1089, 2008.
35. Blondeel PN, Arnstein M, Verstraete K, Depuydt K, Van Landuyt KH, Monstrey SJ and Kroll SS: Venous congestion and blood flow in free transverse rectus abdominis myocutaneous and deep inferior epigastric perforator flaps. *Plast Reconstr Surg* 106: 1295-1299, 2000.
36. Kwon SS, Chang H, Minn KW and Lee TJ: Venous drainage system of the transverse rectus abdominis musculocutaneous flap. *Scand J Plast Reconstr Surg Hand Surg* 43: 312-314, 2009.