

# Management of upper urinary tract calculi in crossed fused renal ectopic anomaly

LIANG HUANG<sup>1</sup>, YONG LIN<sup>2</sup>, ZHENGYAN TANG<sup>1</sup>, DONGJIE LIE<sup>1</sup>,  
ZHAO WANG<sup>1</sup>, HEQUN CHEN<sup>1</sup> and GUILIN WANG<sup>1</sup>

<sup>1</sup>Department of Urology, Xiangya Hospital, Central South University, Changsha, Hunan 410008, P.R. China;

<sup>2</sup>Institute for Virology, University Hospital of Essen, University of Duisburg-Essen, D-45147 Essen, Germany

Received December 25, 2016; Accepted July 7, 2017

DOI: 10.3892/etm.2017.5382

**Abstract.** The aim of the present study was to summarize the management of upper urinary tract calculi in crossed fused renal ectopia (CFRE). Two patients were retrospectively studied in Xiangya Hospital (Changsha, China) and all relevant literature published in English between 1996 and 2016 was reviewed. All patients, including those reported in the literature, were characterized by age, sex, manifestation, therapy history, ectopic side, stone location, surgery and outcome. The patients had a mean age of 42.3±18.5 years, a male: Female ratio of 5:4 and the ratio of renal ectopic side was 9:8 (left:right). All patients suffered from different degrees of pain on the affected side, with or without hematuria. Up to 89% of patients presented with renal stones. These patients received treatments including conservative management in 2, extracorporeal shock wave lithotripsy (ESWL) in 2, percutaneous nephrolithotomy (PCNL) in 11, laparoscope nephrolithotomy in 1 and retrograde intrarenal surgery (RIRS) in 3. Complete stone clearance was achieved in 14 patients (73.7%). In addition, 3 patients had a history of failed ESWL. No obvious intraoperative or postoperative complications occurred. The results suggested that, for the treatment of CFRE with upper urinary tract calculi, conservative treatment and ESWL are insufficient. PCNL is a safe and effective treatment for renal calculus, and laparoscopic nephrolithotomy is an alternative choice for treating large or staghorn renal stones. RIRS may become the first line

of treatment for renal stones ( $\leq 3.5$  cm) due to its multiple merits, including higher stone-free rates, minimal invasion and fewer complications.

## Introduction

Crossed fused renal ectopia (CFRE) is a rare congenital anomaly in which both kidneys are located and fused on the same side of the body, with a high incidence of stone formation and urinary tract infection (1). CFRE is the second most frequently observed congenital malformation of the kidney after horseshoe anomaly, and occurs in 1 in 1,000-2,000 autopsies and ~0.01% of live births (1,2). There are six primary categories of CFRE; however, there is no specific clinical manifestation or standardized guideline for the management of upper urinary tract calculi in CFRE (3). Due to the abnormal anatomical structure of the kidney and ureter, as well as the abnormal relationship with the surrounding structures (including the small bowel, vertebral column and blood vessels), the treatment of upper urinary tract calculi is technically challenging for urologists (4). Few studies have reported the treatment of kidney stones in patients with CFRE and several treatment methods are available, including extracorporeal shock wave lithotripsy (ESWL) (5,6), percutaneous nephrolithotomy (PCNL) (4,7-11), laparoscopic nephrolithotomy (12) and retrograde intrarenal surgery (RIRS) (13,14). Open stone surgery is no longer performed in many hospitals and there is not an optimal approach that is applicable in all cases due to different stones sizes and different types of CFRE as reported in the literature (11,12,15). In the present study, all patients with CFRE and upper urinary tract stones reported in the literature between 1996 and 2016 were reviewed. Two patients treated at Xiangya Hospital (Changsha, China) were retrospectively reviewed to provide suggestions for the effective management of such patients in clinical practice.

## Materials and methods

**Ethics statement.** The 2 patients involved in the present study provided written informed consent to publish their case details. The present study was reviewed and approved by the Ethics Committee of Xiangya Hospital, Central South University (Changsha, China).

---

**Correspondence to:** Professor Zhengyan Tang, Department of Urology, Xiangya Hospital, Central South University, 87 Xiangya Road, Changsha, Hunan 410008, P.R. China  
E-mail: xytzyan@163.com

**Abbreviations:** CFRE, crossed fused renal ectopic; ESWL, extracorporeal shock wave lithotripsy; F, female; Lap, laparoscopic; F-PCNL, flexible percutaneous nephrolithotomy; LNL, laparoscopic nephrolithotomy; M, male; PCN, percutaneous nephrostomy; RIRS, retrograde intrarenal surgery; URS, ureteroscopy

**Key words:** crossed renal ectopia, renal stone, ureteral calculi, minimally invasive surgery

### Case study

**Patient 1.** Patient 1 was a 51-year-old woman admitted in September 2013, who presented with a 10-day history of right flank and right lower-abdominal pain with repeated urinary infections over the past 2 years. The patient reported no gross hematuria and no history of surgery or chronic renal disease. Physical examination revealed mild knocking pain over the right flank area.

The results of routine laboratory monitoring, including hemogram, renal function and urine analysis, were normal. Radiography of the kidneys, ureters and bladder revealed several right renal lower calices calculi and two possible ureteral calculi, one located on the right side at the level of the third lumbar vertebra and the other at the left ureteral orifice. Abdominal computed tomography (CT) scan revealed a left-to-right crossed fused kidney. The CT simultaneously confirmed bilateral ureteral calculi (right, 2x1 cm; left, 0.5x0.8 cm) and right renal calculi. The bilateral pelvicalyceal systems were moderately dilated as a result (Fig. 1).

The patient was placed in a lithotomy position under general anesthesia. Ureteroscopy revealed that the left calculus was located in the left lower segment ureter ~0.5 cm from the left ureteral orifice. The calculus was subsequently fragmented with a holmium laser as previously described (16). The left ureter was completely twisted to the right side and so the ureteroscope was unable to move forward any further following intracorporeal lithotripsy. A 6 F ureteral stent was placed in the left ureter and a 4 F ureteral catheter was placed in the right ureter for the right PCNL. The patient was subsequently turned to a prone position and a posterior upper calyx puncture was performed as previously described (4). Tract dilation was serially performed using a fascial dilator from 8 F to 16 F and a matched peel-away sheath was placed in the tract as previously described (4). The stones were fragmented with a holmium laser or pneumatic lithotripter through an 8 F rigid ureteroscope. The stone-free status was confirmed, a 6 F double-J stent (Bard, Murray Hill, NJ, USA) was inserted via the percutaneous tract with the assistance of a guide wire and a matched size nephrostomy tube was inserted in the collecting system. The total surgical duration was 95 min. No obvious bleeding occurred.

The patient's postoperative course was uneventful. The duration of postoperative analgesia was 12 h and a postoperative abdominal X-ray did not reveal any stone shadows (Fig. 1F). The Foley catheter and nephrostomy tube were removed at days 1 and 2 postoperatively, respectively. The patient was discharged on day 3 post-surgery. The two double-J stents were removed via cystoscopy at 1 month post-surgery.

**Patient 2.** Patient 2 was a 62-year-old woman admitted in March 2016, who presented with a 3-month history of intermittent right flank pain and repeated urinary infections over the preceding 8 years. No abnormalities were identified in standard laboratory tests, with the exception of microhematuria. A CT scan revealed a left-to-right crossed fused kidney in her abdomen and a left ureteral stone (1.5x1 cm) was detected, causing the ectopic kidney pelvicalyceal system and the upper ureters to be moderately dilated (Fig. 2). An intracorporeal lithotripsy by ureteroscope under intravertebral

anesthesia was planned. However, the left ureter was seriously twisted to the right side, and so it was not possible to move forward to the right location of the ureteral stone with a rigid ureteroscope. As such, a flexible ureteroscope was used. The calculus was identified ~10 cm from the left ureteral orifice and subsequently completely fragmented using a holmium laser. No stent or urinary drain was inserted postoperatively, and the patient was discharged uneventfully on day 2 post-surgery.

**Literature review.** PubMed (ncbi.nlm.nih.gov/PubMed) was searched for articles published in English between May 1996 and May 2016. The search terms used were as follows: 'Stone,' 'stones,' 'calculus,' 'calculi,' 'urolithiasis,' 'crossed fused,' 'CFRE,' 'kidney' and 'renal.' 'Bladder' and 'urethral' were excluded from the search. Articles that did not describe the treatment of patients were also excluded.

### Results

**Case study.** The 2 patients were discharged uneventfully without major or minor complications. At the time of writing (follow-up duration was 31 months in case 1 and 2 months in case 2), the patients were asymptomatic and stone free with no notable complications.

**Literature review.** Details of the case study patients and the patients reported in the literature publications are summarized in Table I. Two studies (17,18) included cases of crossed fused kidneys in their study groups with more detailed description. It was therefore not possible to extract enough information for analysis and so these articles were excluded from the results. In the reviewed studies, patients were aged 12-81 years, with a mean age of 42.3±18.5 years. Of the 19 patients reported, 10 were males and 8 were females. The ratio of renal ectopic side was left:right, 9:8.

As demonstrated in Table I, all patients suffered from different degrees of pain on the affected side, with or without hematuria. Up to 89% of patients presented with renal stones, whereas a small number of patients presented with ureteral calculi. A total of 3 patients had a history of failed ESWL. Patients received a variety of different treatments including conservative management in (n=2), ESWL (n=2), PCNL (n=11), laparoscope nephrolithotomy (n=1) and RIRS (n=3). Final complete stone clearance was achieved in 14 patients (73.7%) following single or multiple treatment sessions. No intraoperative or postoperative complications, including blood transfusion, uncontrolled hemorrhage and injury of surrounding viscera, were reported.

### Discussion

CFRE is an uncommon congenital anomaly in which an ectopic kidney crosses the midline and merges with the orthotopic kidney on the other side, with two ureters inserted into their normal positions within the bladder trigone (1). CFRE has been reported to occur in 1 in 1,000-2,000 autopsies (2) and is slightly more common in males (3:2) (3). Left-to-right crossover occurs more frequently than right-to-left fusion (19). Depending on the extent of fusion, location or rotation of the fused renal mass, the anomalous entity may be categorized

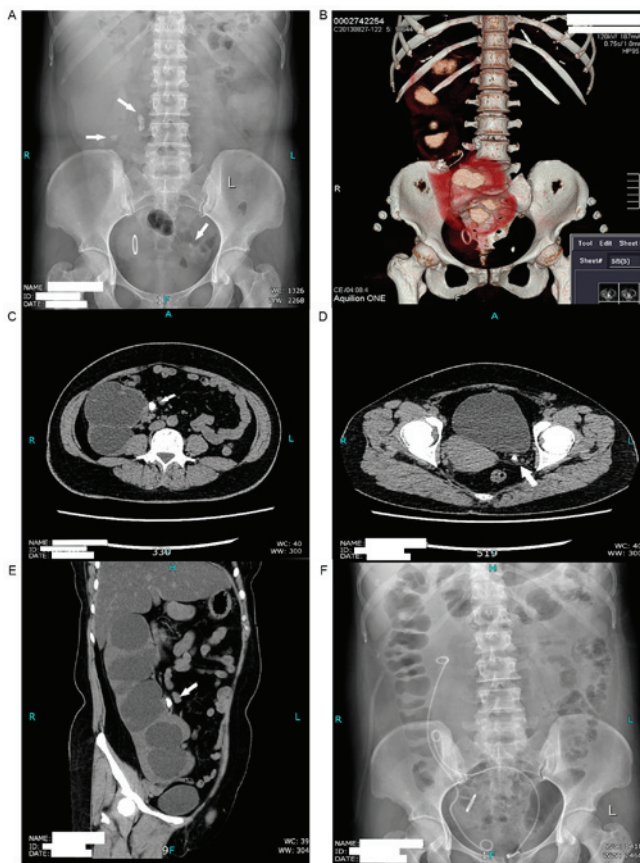


Figure 1. Radiographs, CT scans and X-ray images of patient 1. (A) Radiograph of the kidneys, ureters and bladder revealed several right renal lower calices calculi and two possible ureteral calculi, indicated by white arrows. (B) 3D reconstructed CT image revealed the left-to-right crossed renal ectopia with bilateral ureteral calculi and right renal calculi (white arrows). (C) CT scan demonstrated the right ureteral calculi (arrow) and mild dilation of the right pelvicalyceal systems. (D) CT scan demonstrated the left ureteral calculi (arrow). (E) Sagittal CT image revealed the location of the right ureteral calculi (arrow) and dilation of the bilateral pelvicalyceal systems. (F) Postoperative abdominal X-ray revealed no stone shadows. CT, computed tomography; 3D, three-dimensional.

as a unilateral fused kidney with inferior or superior ectopia, a sigmoid or S-shaped kidney, a lump kidney, an L-shaped kidney or a disc kidney (3). The mechanism that causes the ectopic renal anomaly remains to be elucidated; however, it has been hypothesized that inappropriate development of the ureteral bud and metanephric blastema in embryo may be one of the causes (19).

The majority of patients with CFRE present no symptoms during their lifetime and the congenital anomaly is often typically identified by chance during a routine physical examination (1). Due to the abnormal anatomic location, patients with CFRE are more susceptible to urinary tract infections and calculus formation; as such, the common manifestations include vague abdominal pain, hematuria, pyuria and lower urinary tract symptoms (12). The majority of patients, as well as the patients reviewed in the present study, present with varying degrees of flank pain and microscopic hematuria (6-8,20). Various imaging studies, including ultrasonography, intravenous urography, CT or magnetic resonance imaging, may be used to estimate the crossed fused kidney (12). CT is widely utilized in preoperative assessment as it may be utilized

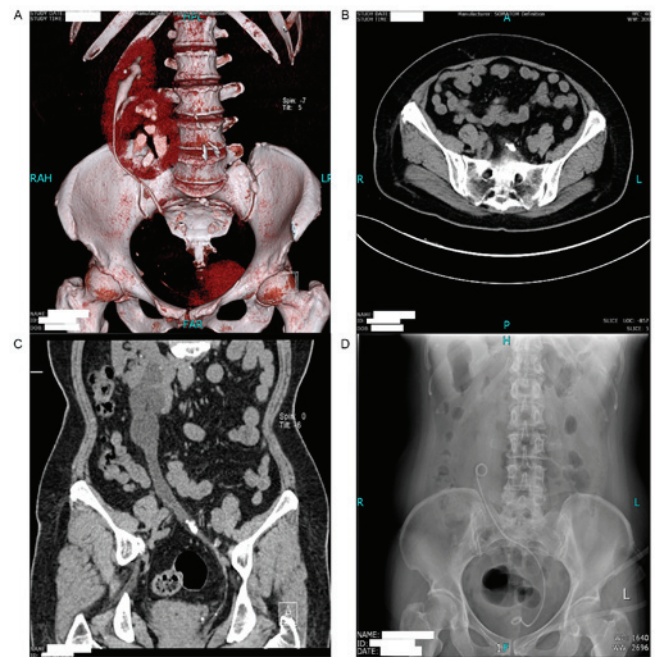


Figure 2. CT scans and X-ray images of patient 2. (A) 3D reconstructed CT image revealed left-to-right crossed renal ectopia with left ureteral calculi (white arrow). (B) Transverse section of CT image revealed the left calculi was located before the sacrum (arrow). (C) Coronal section of CT image revealed the left ureteral calculi (arrow) and moderate dilation of the collecting systems. (D) A postoperative abdominal X-ray of the kidney, ureters and bladders revealed stone-free status. CT, computed tomography; 3D, three-dimensional.

to precisely identify the anatomical characteristics of the anomaly and the anatomical relationship between the kidney and surrounding structures (21).

The majority of asymptomatic individuals do not require invasive treatment for a long time, until hydronephrosis or renal function decrease is detected or ureter calculi impedes urinary drainage (1). Techniques used for management of upper urinary tract calculi in CRFE include ESWL, PCNL, laparoscope, flexible nephroscopy or ureteroscopy (6,8,10,12,13). Urologists in many countries have abandoned open surgery due to the rapid development of minimally invasive technology (12). Conservative management has been reported in two previous articles (15,20); however, this only relieves pain and the obstruction remains. It was reported that 1 patient with a proximal ureter stone achieved final stone-free status following two sessions of ESWL (6); however, ESWL was unsuccessful for steinstrasse formation in another patient with a renal stone (5). An additional 3 patients with renal stones and a history of failed ESWL were identified in the present study (9,12,13). These results suggest that ESWL may not be a suitable choice for CFRE with upper urinary tract calculi.

PCNL as a minimally invasive method is considered the gold standard for treating stones located in the kidney and upper ureter, particularly large or complex stones, and has also been used to manage renal anomalies of ectopia, fusion or malrotated kidneys (4,18,22). A study by Blackburne *et al* (23) reported their experience of PCNL in 37 patients with horseshoe kidneys. In their series, the final stone-free rate was 81.1%. A total of 10 out of 11 patients (90.9%) who were identified to have undergone PCNL in the present study achieved stone clearance except



Table I. Previous reports of management of upper urinary tract calculi in crossed fused renal ectopia.

Author, year	Patients	Mean age, years	Sex	Manifestation	Therapy history	Side	Stone location	Mean stone burden	Surgical technique	Number of surgeries <sup>a</sup>	Outcome	(Refs.)
Aminsharifi <i>et al</i> , 2009	1	32	M	Right flank pain	ESWL	Right	Pelvis	25 mm	LNL	1	Total clearance	(12)
Kato <i>et al</i> , 2000	1	63	F	Right flank pain, microhematuria	None	Right	Proximal ureter	12 mm	ESWL	2	Total clearance	(6)
Srivastava <i>et al</i> , 2010	2	55	1 F, 1 M	-	None	-	Renal	25 mm	1 PCNL, 1 lap-assisted PCNL	1	Total clearance	(10)
Maldonado-Alcaraz <i>et al</i> , 2012	1	55	M	Left renal colic, microhematuria	None	Left	Pelvis	20 mm	PCNL	1	Total clearance	(8)
Ugurlu <i>et al</i> , 2015	1	22	F	-	ESWL	Left	Calyx	85 mm <sup>2</sup>	RIRS	2	Residual stone	(13)
Amin <i>et al</i> , 2009	1	25	M	Right flank pain, microhematuria	None	Right	Pelviccalyceal	Staghorn	Conservative	0	Residual stone	(20)
Taslim <i>et al</i> , 2012	1	34	M	Right flank pain	None	Right	Pelvis	14 mm	Conservative	0	Residual stone	(15)
Larre <i>et al</i> , 2007	1	40	M	Left ureteral colic	None	Left	Calyx	18 mm	ESWL	1	Residual stone	(5)
Abdeldaeim <i>et al</i> , 2011	1	12	-	-	ESWL	Left	Pelvis	169.7 mm <sup>2</sup>	PCNL	1	Total clearance	(9)
Gupta <i>et al</i> , 2009	4	30	F:M, 1:1	-	None	3 Left 1 Right	2 calyx 2 pelvis	22 mm	PCNL	1	Total clearance	(4)
Ghosh <i>et al</i> , 2008	1	81	M	Left flank pain	None	Left	Pelvis	-	PCN	1	Residual stone	(11)
Mishra <i>et al</i> , 2013	1	68	F	Abdominal pain	None	Right	Pelviccalyceal	Staghorn	PCNL, F-PCNL	3	Total clearance	(7)
Resorlu <i>et al</i> , 2015	1	28	M	Left flank pain	None	Left	Calyx	15 mm	RIRS	1	Total clearance	(14)
Present study	2	51	F	Right flank pain	None	Right	Calyx, ureter	20 mm	PCNL, URS	1	Total clearance	-
		62	F	Right flank pain, urinary tract infection	None	Right	Ureter	15 mm	RIRS	1	Total clearance	

<sup>a</sup>Number of surgeries specifies only procedures that successfully removed the stone. M, male; F, female; ESWL, extracorporeal shock wave lithotripsy; PCNL, percutaneous nephrolithotomy; F-PCNL, flexible-PCNL; LNL, laparoscopic nephrolithotomy; RIRS, retrograde intrarenal surgery; URS, ureteroscopy.

one patient, whose therapeutic outcome was unclear from the literature (11); unfortunately, the author did not describe the subsequent treatment of the patient. The anatomical deformity in patients with CFRE increases the risk of damaging the surrounding visceral and renal aberrant vessel injuries during surgery; therefore, special auxiliary methods, such as laparoscopic-assisted approaches, may be necessary (12). A study by Srivastava *et al* (10) reported a complex case with musculoskeletal deformities resulting in a lack of access to the collecting system by PCNL under image guidance as the bowel was posterior to the crossed kidney. Therefore, a laparoscopic-assisted PCNL was performed, which achieved complete clearance of stones in a single session without any complications (10).

For large calculus or staghorn renal stones, PCNL may not be as effective as previously believed. A recent study reported that the more invasive the chosen procedure, the higher the one-stage stone-free rate, the lower the need for ancillary procedures and the lower the cost of hospitalization (24). A study by Mishra *et al* (7) reported a 68-year-old female with a staghorn stone in her right ectopic kidney, for whom a residual stone remained following two PCNL treatments. A flexible nephroscope was used to access the site and achieve final total stone clearance in the third stage procedure. A study by Aminsharifi *et al* (12) reported another alternative treatment, laparoscopic nephrolithotomy, which consists of two procedures: Laparoscopic pyeloplasty and concomitant pyelolithotomy. However, this demanding surgery requires considerable professional surgical techniques and a long learning curve, as the existence of complex anatomical malformations and fragile renal vasculature increases the risk of injury to the aberrant renal vessels and makes it difficult to define the anatomical structures of the ectopic kidney (12).

In recent years, flexible ureterorenoscopy has been widely used to treat renal stones due to higher stone-free rates, minimal invasion and fewer complications (25). RIRS is to be an alternative to PCNL for the management of large renal calculi ( $\leq 3.5$  cm) (26) and has been demonstrated as a safe and effective measure for treating stone disease in patients with horseshoe kidneys (27). A study by Resorlu *et al* (14) reported a 28-year-old male with calyceal stones in his ectopic kidney who underwent RIRS with a good outcome. Another study reported a case in which the location of the renal calyceal stone was not reached following two RIRS procedures; however, the author did not discuss the reasons for this failure (13). In the present study, the left ureteral calculus near the ureteral orifice in patient 1 was removed using ureteroscopy. However, due to the seriously twisted ureter crossing the midline, RIRS was used to remove calculi successfully in patient 2.

In conclusion, the results of the present study suggest that, for the treatment of CFRE with upper urinary tract calculi, conservative treatment and ESWL are unsatisfactory. Ultrasonographic-guided, CT-guided or laparoscopic-assisted PCNL are safe and effective methods for treating renal calculi in such patients and laparoscopic nephrolithotomy is an alternative choice for large or staghorn renal stones. Ureteroscopy is the first choice for patients with ureter calculi, whereas RIRS should be used when the stone is unreachable in the seriously twisted ectopic ureter. RIRS may become the first line of treatment for renal stones ( $\leq 3.5$  cm) in crossed renal deformity due to its multiple merits.

## Acknowledgements

The present study was supported by the National Nature Science Foundation of China (grant no. 81570627) and the Key Program of the Science and Technology Department of Hunan Province (project no. 2015JC3132).

## References

- Shapiro E, Bauer SB and Chow JS: Anomalies of upper urinary tract. In: Wein AJ, Kavoussi LR, Novick AC, Partin AW, Peters CA (eds). Campbell Walsh Urology. 10th edition. Philadelphia, Elsevier Saunders, pp3140-3145, 2012.
- Ajayi S, Mamven M, Tabari A, Ojji D and Ibrahim A: Crossed fused renal ectopia presenting as recurrent lower abdominal pain and urinary tract infection. *Afr J Med Med Sci* 42: 193-196, 2013.
- Solanki S, Bhatnagar V, Gupta AK and Kumar R: Crossed fused renal ectopia: Challenges in diagnosis and management. *J Indian Assoc Pediatr Surg* 18: 7-10, 2013.
- Gupta NP, Mishra S, Seth A and Anand A: Percutaneous nephrolithotomy in abnormal kidneys: single-center experience. *Urology* 73: 710714, 2009.
- Larré S, Carpentier X, Sèbe P, Tassart M, Cussenot O and Traxer O: A report of unusual crossed fused renal ectopia and minimal invasive management of calculi. *Surg Radiol Anat* 29: 393-395, 2007.
- Kato M, Ioritani N, Aizawa M, Inaba Y, Watanabe R and Orikasa S: Extracorporeal shock wave lithotripsy for a ureteral stone in crossed fused renal ectopia. *Int J Urol* 7: 270-273, 2000.
- Mishra S, Ganesamoni R, Ganpule AP, Sabnis RB and Desai MR: Supine percutaneous nephrolithotomy for bilateral complete staghorn calculi in an L-shaped cross-fused renal ectopic anomaly. *Urology* 81: e3-e4, 2013.
- Maldonado-Alcaraz E, Martinez-Vargas JA, Moreno-Palacios J, Serrano-Brambila EA and Velázquez-Quintero S: Percutaneous nephrolithotomy in crossed fused renal ectopia: Superior calyceal access under fluoroscopic control. *Arch Esp Urol* 65: 582-585, 2012 (In English, Spanish).
- Abdeldaeim HM, Hamdy SA and Mokhless IA: Percutaneous nephrolithotomy for the management of stones in anomalous kidneys in children. *J Pediatr Urol* 7: 239-243, 2011.
- Srivastava A, Gupta P, Chaturvedi S, Singh P, Kapoor R, Dubey D and Kumar A: Percutaneous nephrolithotomy in ectopically located kidneys and in patients with musculoskeletal deformities. *Urol Int* 85: 37-41, 2010.
- Ghosh BC, DeSantis M, Kleyner Y and Zak Y: Crossed fused renal ectopia with calculi. *J Am Coll Surg* 206: 753, 2008.
- Aminsharifi A, Niroomand R, Kroup M and Hosseini MM: Laparoscopic nephrolithotomy in a patient with crossed fused renal ectopia. *Nat Rev Urol* 6: 675-679, 2009.
- Ugurlu IM, Akman T, Binbay M, Tekinarslan E, Yazici ö, Akbulut MF, Özgör F and Müslümanoğlu AY: Outcomes of retrograde flexible ureteroscopy and laser lithotripsy for stone disease in patients with anomalous kidneys. *Urolithiasis* 43: 77-82, 2015.
- Resorlu M, Kabar M, Resorlu B, Doluoglu OG, Kilinc MF and Karakan T: Retrograde intrarenal surgery in cross-fused ectopic kidney. *Urology* 85: e5-e6, 2015.
- Taslim BB, Abdulwasii BA, Olusegun S, Oluwatoyin AC and Omolara MM: Crossed renal ectopia coexisting with nephrolithiasis in a young Nigerian man. *Arab J Nephrol Transplant* 5: 107-110, 2012.
- Yan Z, Xie G, Yuan H and Cheng Y: Modular flexible ureteroscopy and holmium laser lithotripsy for the treatment of renal and proximal ureteral calculi: A single-surgeon experience of 382 cases. *Exp Ther Med* 10: 1467-1471, 2015.
- Nadu A, Schatloff O, Morag R, Ramon J and Winkler H: Laparoscopic surgery for renal stones: Is it indicated in the modern endourology era? *Int Braz J Urol* 35: 9-18, 2009, 17-8.
- Rana AM and Bhojwani JP: Percutaneous nephrolithotomy in renal anomalies of fusion, ectopia, rotation, hypoplasia, and pelvicalyceal aberration: Uniformity in heterogeneity. *J Endourol* 23: 609-614, 2009.

19. Bhojwani N, Hartman JB, Ahmed M, Morgan R and Davidson JC: Management of ureteral obstruction in crossed fused renal ectopia: A case report. *Can Urol Assoc J* 8: E752-E744, 2014.
20. Amin MU, Khan S and Nafees M: Crossed fused renal ectopia with staghorn calculus and gross hydronephrosis. *J Coll Physicians Surg Pak* 19: 69-70, 2009.
21. Singer A, Simmons MZ and Maldjian PD: Spectrum of congenital renal anomalies presenting in adulthood. *Clin Imaging* 32: 183-191, 2008.
22. Moosanejad N, Firouzian A, Hashemi SA, Bahari M and Fazli M: Comparison of totally tubeless percutaneous nephrolithotomy and standard percutaneous nephrolithotomy for kidney stones: a randomized, clinical trial. *Braz J Med Biol Res* 49: e4878, 2016.
23. Blackburne AT, Rivera ME, Gettman MT, Patterson DE and Krambeck AE: Endoscopic Management of Urolithiasis in the Horseshoe Kidney. *Urology* 90: 45-49, 2016.
24. Aminsharifi A, Irani D, Masoumi M, Goshtasbi B, Aminsharifi A and Mohamadian R: The management of large staghorn renal stones by percutaneous versus laparoscopic versus open nephrolithotomy: A comparative analysis of clinical efficacy and functional outcome. *Urolithiasis* 44: 551-557, 2016.
25. Elbir F, Başbüyük İ, Topaktaş R, Kardaş S, Tosun M, Tepeler A and Armağan A: Flexible ureterorenoscopy results: Analysis of 279 cases. *Türk J Urol* 41: 113-118, 2015.
26. Palmero JL, Durán-Rivera AJ, Miralles J, Pastor JC and Benedicto A: Comparative study for the efficacy and safety of percutaneous nephrolithotomy (PCNL) and retrograde intrarenal surgery (RIRS) for the treatment of 2-3,5 cm kidney stones. *Arch Esp Urol* 69: 67-72, 2016 (In English, Spanish).
27. Gokce MI, Tokatli Z, Suer E, Hajiyev P, Akinci A and Esen B: Comparison of shock wave lithotripsy (SWL) and retrograde intrarenal surgery (RIRS) for treatment of stone disease in horseshoe kidney patients. *Int Braz J Urol* 42: 96-100, 2016.