

Correlation between PPAR- α methylation level in peripheral blood and inflammatory factors of NAFLD patients with DM

JIANGHUA JU, QINGXIAN HUANG, JING SUN, YONGCHENG JIN, WENJIE MA,
XIAOHUI SONG, HUIBO SUN and WENHUI WANG

Department of Endocrinology, Qilu Hospital of Shandong University, Qingdao, Shandong 266035, P.R. China

Received June 20, 2017; Accepted October 10, 2017

DOI: 10.3892/etm.2017.5530

Abstract. The correlation between the methylation levels of peroxisome proliferator-activated receptor- α (PPAR- α) in the peripheral blood and the inflammatory factors associated with non-alcoholic fatty liver disease (NAFLD) patients with diabetes mellitus (DM) was investigated. Thirty-two samples of normal liver tissues (group N) and 35 samples of liver tissues from NAFLD patients with DM (group M) were used for the present study. The levels of alanine transaminase (ALT) and aspartate transaminase (AST) were measured using commercially available kits. The accumulation of lipid droplets and glycogen in the two groups was determined through Oil Red O staining and Sudan III staining. mRNA expression of tumor necrosis factor- α (TNF- α), interleukin- 1β (IL- 1β) and IL-6 in liver tissues of groups N and M were detected using reverse transcription-polymerase chain reaction (RT-PCR). In addition, western blotting was used to detect the protein expression of PPAR- α in liver tissues of both groups. The Statistical Product and Service Solutions (SPSS) 17.0 statistical software was used to analyze the expression difference of PPAR- α in liver tissues in the groups. The high levels of ALT and AST indicated severe liver injury in group M. Oil Red O staining and Sudan III staining showed a large number of lipid droplets and glycogen accumulation in the liver of group M patients. RT-PCR showed that the expression of inflammatory factors was extremely high and that the inflammatory injury was severe in the liver of group M patients. Western blotting showed that the expression of PPAR- α in group N was significantly higher than that in group M. ANOVA results showed that the expression of PPAR- α in liver tissues of groups N and M patients were statistically significantly different ($P < 0.01$). Therefore,

the abnormal expression of PPAR- α is closely associated with the occurrence and development of NAFLD complicated with DM, and that the abnormal expression of PPAR- α is closely related to inflammatory factors. Results from the present study suggest PPAR- α has important value in the study on NAFLD complicated with DM. The expression of PPAR- α can be used as a new basis for the diagnosis and treatment of NAFLD complicated with DM.

Introduction

Non-alcoholic fatty liver disease (NAFLD) is a type of metabolic syndrome due to intrahepatic fatty lesions caused by a variety of factors. As there have been many changes in dietary habits and life style in recent years, the incidence of NAFLD has increased significantly (1,2). Diabetes mellitus (DM) is a type of metabolic disease that is characterized by high blood sugar levels. NAFLD can lead to DM, causing serious physical and economic burdens to both patients and society (3).

A large number of studies have shown that peroxisome proliferator-activated receptors (PPARs) are widely involved in metabolic syndromes, and PPARs are closely related to the occurrence and development of NAFLD complicated with DM (4,5). PPAR- α is a key gene in the PPAR family as it can affect fat and glucose metabolism through gene activation, ultimately reducing the influence of NAFLD complicated with DM (6).

In the present study, the correlation between the methylation levels of PPAR- α in peripheral blood and inflammatory factors of NAFLD patients with DM were studied in order to investigate the association of the two factors. Furthermore, we studied the association between PPAR- α methylation levels and inflammatory factors, providing a new direction for the treatment of NAFLD patients with DM.

Materials and methods

Materials. The cohort for the study included patients who received surgery at the Qilu Hospital of Shandong University, and had complete admission data. There were 32 cases in the normal group (group N), including 17 males and 15 females. There were 35 cases in the NAFLD complicated with DM

Correspondence to: Dr Wenhui Wang, Department of Endocrinology, Qilu Hospital of Shandong University, 758 Hefei Road, Qingdao, Shandong 266035, P.R. China
E-mail: wangwenhuiqd@163.com

Key words: non-alcoholic fatty liver disease, diabetes mellitus, peroxisome proliferator-activated receptor- α , inflammatory factor

group (group M), including 19 males and 16 females. The average age of group N was 57 ± 19 years, while that of group M was 52 ± 19 years. There were no statistically significant differences between gender and age in the two groups ($P > 0.05$), and the data were comparable.

The study was approved by the Ethics Committee of Qilu Hospital of Shandong University and informed consents were signed by the patients and/or guardians.

Main reagents. The alanine transaminase (ALT) and aspartate transaminase (AST) detection kits were obtained from Jiancheng (Nanjing, China). The Oil Red O and Sudan III dyes were obtained from Sigma (St. Louis, MO, USA). The BCA protein quantification kit was purchased from Beyotime (Shanghai, China). The TRIzol total RNA extraction kit was obtained from Tiangen (Beijing, China). The reverse transcription polymerase chain reaction (RT-PCR) kit was purchased from Tiangen. Rabbit anti-human β -actin polyclonal antibody (dilution, 1:1,000; cat. no. 4967; Cell Signaling Technology, Inc., Boston, MA, USA) and mouse anti human PPAR- α monoclonal antibodies (1 mg/ml, GTX22779; GeneTex Int., Co., Hsinchu, Taiwan) were used in the present study.

Experimental methods

Determination of ALT and AST in serum. ALT and AST levels in serum were measured in accordance with instructions of the ALT and AST detection kits, and the differences between liver function in groups N and M was analyzed.

Oil Red O staining and Sudan III staining of liver tissue sections. The liver tissues in groups N and M were prepared in frozen sections, followed by Oil Red O staining and Sudan III staining. The stained sections were observed under a light microscope (x400; Olympus, Tokyo, Japan) for histopathological analysis.

Real-time PCR analysis. The appropriate amount of liver tissues in groups N and M were immediately transferred into 1 ml of TRIzol reagent for full tissue grinding to prepare them into a homogenate. The samples were placed at room temperature for 5 min and centrifuged at $12,000 \times g$ at 4°C for 5 min prior to removal of the supernatant. Chloroform was added to the supernatant and mixed uniformly. The solution was placed at room temperature for 5 min and centrifuged at $12,000 \times g$ at 4°C for 5 min and then the supernatant was removed. Subsequently, the same volume of isopropanol was added to the supernatant, and the solution was placed at room temperature for 10 min and centrifuged at $12,000 \times g$ at 4°C for 10 min. The precipitate was taken and 75% ethanol was added to wash the RNA precipitates. Finally, RNase-free water was added to dissolve the precipitates completely. The $\text{OD}_{260}/\text{OD}_{280}$ ratio was determined and the RNA concentration was measured. Finally, the stepwise amplification was performed according to the instructions based on the primer sequence template (Table I) and the RT-PCR analysis was carried out on the reaction products received.

Western blot analysis

Protein extraction. Liver tissues were washed twice with ice-cold saline according to instructions of the protein extraction kit. Lysis buffer was added, followed by homogenate using the tissue homogenizer for 1 min and centrifugation

Table I. RT-PCR primer sequence of PPAR- α and β -actin mRNA.

Gene name	Primer sequences
PPAR- α	5'-3' AGTGACATTGCTAAAATACGGAGT
	3'-5' GTCATCAGTTCCAGTGCATT
β -actin	5'-3' CGAGAAGATGACCCAGATCATGT
	3'-5' CCAGGTCCAGACGCAGCA
PPAR- α , peroxisome proliferator-activated receptor- α .	

at $12,000 \times g$ for 10 min. The supernatant was collected, which was designated as the total protein of liver tissues. The protein concentration was determined using the bicinchoninic acid (BCA) protein concentration determination kit. The proteins were stored at -80°C for subsequent use.

Protein denaturation. The whole protein extracting solution and 2X loading buffer were mixed at 1:1, followed by a boiling water bath for 5 min and then natural cooling. The solution was stored at 4°C for subsequent use.

Sodium dodecyl sulfate-polyacrylamide gel electrophoresis (SDS-PAGE). According to the target protein molecular weight, the appropriate proportion of SDS-PAGE separation gel was prepared, followed by solidification for 1 h. A 5% SDS-PAGE spacer gel was then prepared, followed by solidification for 30 min. Electrophoretic buffer solution and denatured protein samples were added into the wells for loading according to the protein concentration. Electrophoresis was performed under a constant voltage of 220 V until bromophenol blue reached the bottom of the gel.

Membrane transfer. According to the target protein molecular weight, the gel was cut and placed into a transfer buffer. The PVDF membrane was soaked in the methanol for 10 sec, and then PVDF membrane and filter paper were placed into the transfer buffer. The positive pole, 3 layers of filter paper, PVDF membrane, gel, 3 layers of filter paper and negative pole were placed successively into the membrane transfer instrument. The edges were aligned to prevent foaming. The membrane transfer was performed under the constant voltage of 110 V for 2 h.

Blocking. The protein-covered PVDF membrane was blocked in 5% skim milk powder at room temperature for 2 h.

Antibody incubation. The membrane was washed with Tween-20/Tris-buffered saline (TTBS) for 5 min and the corresponding proportion of antibody was added for incubation overnight at 4°C . The membrane was then washed with TTBS 3 times (10 min/time) and the corresponding secondary antibody was added for incubation on a shaking table at room temperature for 3 h. Finally, the membrane was washed with TTBS 3 times (10 min/time).

Electrochemiluminescence (ECL). The gel-imaging instrument was preheated for 30 min, and the isopycnic

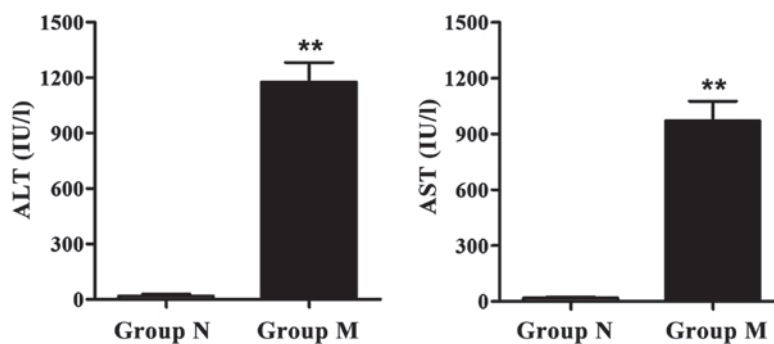


Figure 1. Alanine transaminase (ALT) and aspartate transaminase (AST) expression in groups N and M. ** $P < 0.01$ compared with group N.

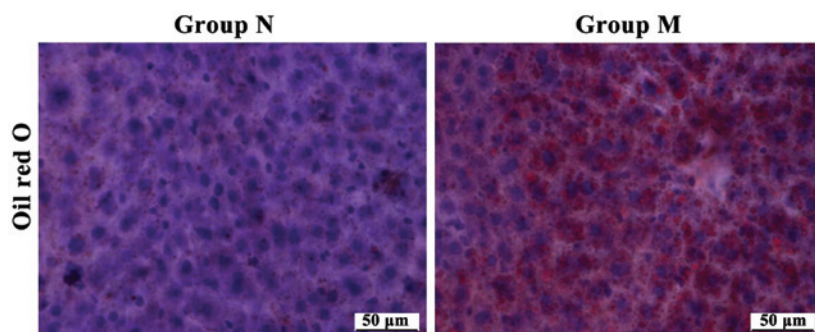


Figure 2. Oil Red O staining results of liver tissues in groups N and M (magnification, x400).

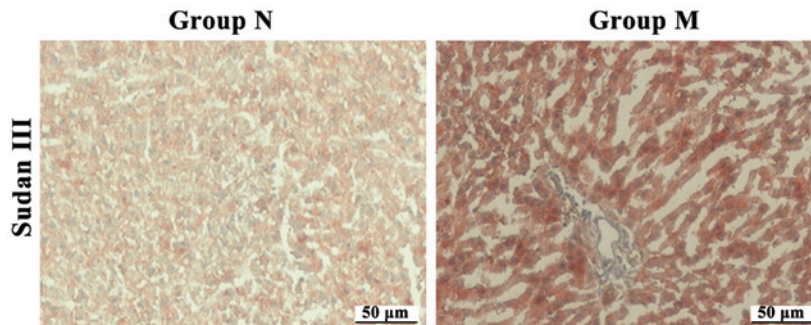


Figure 3. Sudan III staining results of liver tissues in groups N and M (magnification, x400).

reagents A and B in the ECL kit were mixed uniformly and dropped onto the PVDF membrane, followed by color development in the dark for 1 min. The excess liquid around the membrane was dried with filter paper, and the membrane was placed onto a gel-imaging instrument, followed by photography using the dynamic integral method and observation. Image analysis was conducted using the image analysis software.

Statistical analysis. Data are presented as mean \pm standard error of the mean (mean \pm SEM). Statistical analysis was performed for experimental results using the SPSS 17.0 statistical software. The means between the groups were compared using the t-test, while the means among the groups were compared using the one-way analysis of variance (ANOVA). The P-test was used for pairwise comparison. $P < 0.05$ suggested that the difference was statistically significant.

Results

ALT and AST expression in serum. AST and ALT are specific aminotransferases in the liver, and liver injury can increase the release of ALT and AST. The levels of ALT and AST in the serum of rats were determined according to the kit instructions in order to evaluate the extent of liver injury. ALT and AST releases were increased in group M compared to group N, suggesting that the liver injury is severe in the M group (Fig. 1).

Pathological conditions via Oil Red O and Sudan III staining. The Oil Red O- and Sudan III-stained sections of liver tissues in groups N and M were used to analyze the pathological differences between samples. As shown in Figs. 2 and 3, compared to liver tissue sections of group N, the liver structures of liver tissue sections of group M were destroyed, there

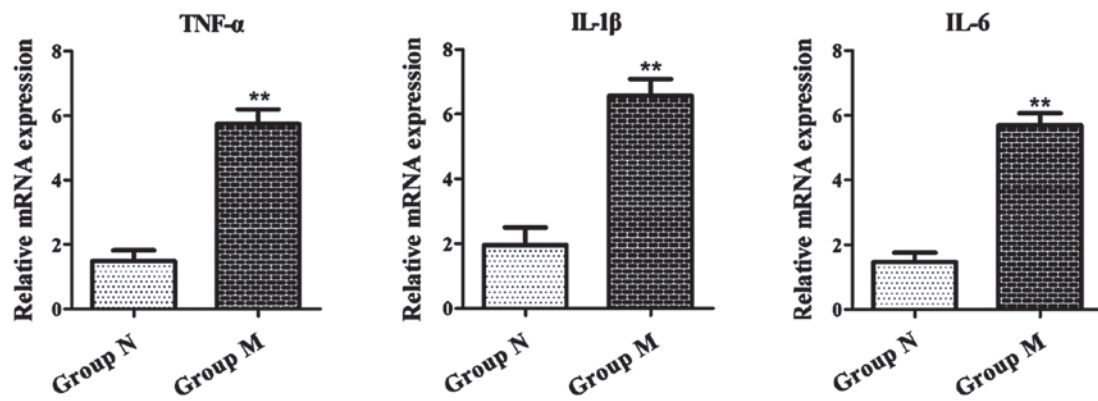


Figure 4. mRNA expression of tumor necrosis factor- α (TNF- α), interleukin-1 β (IL-1 β) and IL-6 in groups N and M. ** $P<0.01$ compared with group N, (n=3).

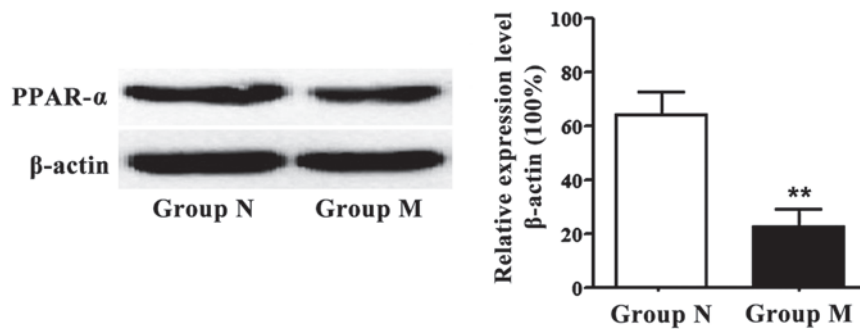


Figure 5. Peroxisome proliferator-activated receptor- α (PPAR- α) protein expression of groups N and M. ** $P<0.01$ compared with group N (n=3).

was severe fatty degeneration in hepatocytes in the central venous peripheral region, and the hepatocytes were different sizes with hydropic degeneration and cloudy swelling. We observed a large number of glycogen and fat accumulation in group M, accompanied by severe inflammatory injury.

RT-PCR results. Total RNA was extracted from the liver tissues of groups N and M. RT-PCR showed that the mRNA expression of tumor necrosis factor- α (TNF- α), interleukin-1 β (IL-1 β) and IL-6 in the liver tissues of group M patients was significantly higher than that of group N (Fig. 4).

Protein expression of PPAR- α in liver tissues of groups N and M. Western blot results revealed the protein expression of PPAR- α in liver tissues of groups N and M. The protein expression of PPAR- α in the liver tissues of group N were much higher than that of group M (Fig. 5). Thus, PPAR- α plays an important role in the occurrence and development of NAFLD complicated with DM, which is also closely related to inflammation.

Discussion

NAFLD is a type of clinical syndrome with fatty degeneration and lipid accumulation in parenchymal hepatic cells as the major pathological features without excessive drinking history (7,8). The disease spectrum of NAFLD is a process that develops from simple fatty degeneration to severe diseases, including steatohepatitis, liver fibrosis, irreversible cirrhosis and hepatocellular carcinoma (9,10). In recent years, with the

improvement of living standards, changes have occurred in lifestyle and dietary structure, with a rapidly increasing rate of NAFLD. Long-term NAFLD can cause severe disorders of glucose and lipid metabolism, and can trigger a large number of inflammatory responses and eventually lead to DM (11,12). The number of NAFLD patients with DM increases annually, and therefore, it is essential to identify practical and effective methods in treating NAFLD complicated with DM.

The pathogenesis of NAFLD remains unclear. Previous findings have shown that the fatty acids and their metabolites, rather than triglyceride deposition in the liver, may have toxic effects on the liver (13). PPAR- α is a member of the nuclear receptor superfamily and is a type of ligand-activated transcription factor that is expressed in a variety of organs, especially in the liver and adipose tissues (14). PPAR- α can be activated by many ligands, such as fatty acids, bile acids, as well as high- and low-density lipoprotein (15). Activated PPAR- α has the effect of regulating lipid metabolism and glucose metabolism, anti-inflammatory effects and other immunomodulatory effects, and plays a central role in the occurrence of NAFLD complicated with DM (16). Thus, PPAR- α may be used as a new target for the treatment of NAFLD complicated with DM, and the study on the relationship between PPAR- α and inflammatory factors may provide a new possibility for the treatment of NAFLD complicated with DM.

Epigenetics studies, especially those conducted on DNA methylation, suggest that the methylation of PPARs has a promoting effect on the occurrence and development of NAFLD and DM (17,18). Moreover, the greatest significance of DNA methylation is that DNA methylation is reversible (19).

Therefore, it is important to explain the PPAR- α regulation of glucose metabolism, fat metabolism, insulin resistance and other gene expressions from the DNA methylation level (20). The results of the present study have shown that ALT and AST levels were higher in group M compared to group N, suggesting severe liver injury. At the same time, results of Oil Red O and Sudan III staining showed a large number of lipid droplets and glycogen accumulation in the liver tissues of group M patients, suggesting a glucose-lipid metabolism disorder in these patients. RT-PCR and western blotting of PPAR- α further showed that the mRNA and protein expression of PPAR- α in the liver tissues of group N were significantly higher than those of group M. Results from the present study suggest that PPAR- α is of importance in the study on NAFLD complicated with DM. PPAR- α may also be a precondition for the early diagnosis and targeted therapy and can provide a theoretical basis for the development of new drugs and strong evidence for the clinical treatment of NAFLD complicated with DM.

References

1. Ratziu V, Goodman Z and Sanyal A: Current efforts and trends in the treatment of NASH. *J Hepatol* 62 (Suppl 1): S65-S75, 2015.
2. Ahmed A, Wong RJ and Harrison SA: Nonalcoholic fatty liver disease review: Diagnosis, treatment, and outcomes. *Clin Gastroenterol Hepatol* 13: 2062-2070, 2015.
3. Castera L, Vilgrain V and Angulo P: Noninvasive evaluation of NAFLD. *Nat Rev Gastroenterol Hepatol* 10: 666-675, 2013.
4. Kersten S, Desvergne B and Wahli W: Roles of PPARs in health and disease. *Nature* 405: 421-424, 2000.
5. Jay MA and Ren J: Peroxisome proliferator-activated receptor (PPAR) in metabolic syndrome and type 2 diabetes mellitus. *Curr Diabetes Rev* 3: 33-39, 2007.
6. Vamecq J and Latruffe N: Medical significance of peroxisome proliferator-activated receptors. *Lancet* 354: 141-148, 1999.
7. Yeh MM and Brunt EM: Pathological features of fatty liver disease. *Gastroenterology* 147: 754-764, 2014.
8. Sanyal AJ, Chalasani N, Kowdley KV, McCullough A, Diehl AM, Bass NM, Neuschwander-Tetri BA, Lavine JE, Tonascia J, Unalp A, *et al*: NASH CRN: Pioglitazone, vitamin E, or placebo for nonalcoholic steatohepatitis. *N Engl J Med* 362: 1675-1685, 2010.
9. Marchesini G, Brizi M, Morselli-Labate AM, Bianchi G, Bugianesi E, McCullough AJ, Forlani G and Melchionda N: Association of nonalcoholic fatty liver disease with insulin resistance. *Am J Med* 107: 450-455, 1999.
10. Haas JT, Francque S and Staels B: Pathophysiology and mechanisms of nonalcoholic fatty liver disease. *Annu Rev Physiol* 78: 181-205, 2016.
11. Williams CD, Stengel J, Asike MI, Torres DM, Shaw J, Contreras M, Landt CL and Harrison SA: Prevalence of nonalcoholic fatty liver disease and nonalcoholic steatohepatitis among a largely middle-aged population utilizing ultrasound and liver biopsy: A prospective study. *Gastroenterology* 140: 124-131, 2011.
12. Loomba R, Abraham M, Unalp A, Wilson L, Lavine J, Doo E and Bass NM: Nonalcoholic Steatohepatitis Clinical Research Network: Association between diabetes, family history of diabetes, and risk of nonalcoholic steatohepatitis and fibrosis. *Hepatology* 56: 943-951, 2012.
13. Doycheva I, Patel N, Peterson M and Loomba R: Prognostic implication of liver histology in patients with nonalcoholic fatty liver disease in diabetes. *J Diabetes Complications* 27: 293-300, 2013.
14. Fruchart JC: Peroxisome proliferator-activated receptor-alpha (PPARalpha): At the crossroads of obesity, diabetes and cardiovascular disease. *Atherosclerosis* 205: 1-8, 2009.
15. Schoonjans K, Staels B and Auwerx J: Role of the peroxisome proliferator-activated receptor (PPAR) in mediating the effects of fibrates and fatty acids on gene expression. *J Lipid Res* 37: 907-925, 1996.
16. Forman BM, Chen J and Evans RM: Hypolipidemic drugs, polyunsaturated fatty acids, and eicosanoids are ligands for peroxisome proliferator-activated receptors alpha and delta. *Proc Natl Acad Sci USA* 94: 4312-4317, 1997.
17. Niculescu MD and Zeisel SH: Diet, methyl donors and DNA methylation: Interactions between dietary folate, methionine and choline. *J Nutr* 132 (Suppl 8): 2333S-2335S, 2002.
18. Dreyer C, Keller H, Mahfoudi A, Laudet V, Krey G and Wahli W: Positive regulation of the peroxisomal beta-oxidation pathway by fatty acids through activation of peroxisome proliferator-activated receptors (PPAR). *Biol Cell* 77: 67-76, 1993.
19. Osada S, Tsukamoto T, Takiguchi M, Mori M and Osumi T: Identification of an extended half-site motif required for the function of peroxisome proliferator-activated receptor alpha. *Genes Cells* 2: 315-327, 1997.
20. Viswakarma N, Jia Y, Bai L, Vluggens A, Borensztajn J, Xu J and Reddy JK: Coactivators in PPAR-regulated gene expression. *PPAR Res* 2010: 250126, 2010.



This work is licensed under a Creative Commons Attribution-NonCommercial-NoDerivatives 4.0 International (CC BY-NC-ND 4.0) License.