

Comparison of single- and triple-injection methods for ultrasound-guided interscalene brachial plexus blockade

CUN-JIN WANG*, YA-LI GE*, JU GAO, FENG-YUN LONG, ZHI-HUA MI, TIAN-FENG HUANG, XIANG-ZHI FANG, XIAO-PING CHEN, YU-SI HUA and YANG ZHANG

Department of Anesthesiology, Clinical Medical College of Yangzhou University, Subei People's Hospital of Jiangsu, Yangzhou, Jiangsu 225001, P.R. China

Received April 15, 2016; Accepted March 23, 2017

DOI: 10.3892/etm.2018.5771

Abstract. Ultrasound-guided interscalene brachial plexus blockade (IBPB) has a relatively high success rate in shoulder surgery; however, whether multiple injections are superior to a single injection (SI) is currently unknown. In the present study, ultrasound-guided SI and triple-injection (TI) IBPBs were compared in a prospective randomized trial. A total of 111 patients undergoing arthroscopic shoulder surgery and presenting with an American Society of Anesthesiologists physical status grading of I-II were randomly allocated to receive IBPB with 15 ml of 1% ropivacaine as a SI or TI. Performance time, procedure-related pain scores, success rate and prevalence of complications were recorded. The distribution of sensory and motor block onset in the radial, median, ulnar and axillary nerves were assessed every 5 min until 30 min post-local anesthetic injection. The duration of sensory and motor blocks were also assessed. A significantly longer performance time was recorded in the TI group ($P<0.001$). No significant difference was observed in success rate (91% in TI vs. 88% in SI) 30 min post-injection, and the prevalence of complications and procedure-related pain were similar between the two groups. Sensory and motor blocks of the ulnar nerve in the TI group were significantly faster and more successful compared with the SI group at all time points ($P<0.041$). It was also observed that sensory and motor blocks in the TI group were prolonged compared with the SI group ($P<0.041$). In conclusion, the TI method exhibited a faster time of onset and resulted in a more successful blockade of the

ulnar nerve. TI method may be a more effective approach for IBPB in a clinical setting.

Introduction

Blockade of the brachial plexus through an interscalene approach has a relatively high success rate in shoulder surgery (1-3). Ultrasound imaging of the brachial plexus between the anterior and middle scalene muscles is feasible (4), and it has been documented that use of ultrasound improves the success rate and reduces the prevalence of complications (5). Furthermore, the site of injection may affect the spread of local anesthetic (LA) (6), and a number of studies comparing different approaches for nerve blocks have documented that multiple injections of LA around the nerve result in a higher prevalence of success and a shorter time of onset compared with LA deposition at a single location (7-9). Furthermore, the present authors have previously observed that triple injection (TI) is necessary if LA is deposited inside the paraneural sheath, and that the paraneurium 'entraps' LA molecules, thereby ensuring circumferential spread around the interscalene brachial plexus nerve (7). Therefore, ultrasound-guided TI may increase the efficacy and quality of interscalene brachial plexus blocks (IBPBs).

In the present study, a prospective, randomized, observer-blinded trial was conducted to compare the efficacy and safety of single injection (SI) and TI methods of IBPB for arthroscopic shoulder surgery. The primary aims were to compare the onset time of sensory and motor blocks and their distribution in the radial, median, ulnar and axillary nerves, as well as the duration of IBPBs. The secondary aims were to compare the performance times, procedure-related pain, success rate and prevalence of complications for the two methods.

Subjects and methods

Study subjects. A total of 111 patients undergoing arthroscopic shoulder surgery between September and December 2015 at Subei People's Hospital of Jiangsu Province (Yangzhou, China) were included in the present study. The study protocol was approved by the Ethics Review Board of the Clinical Medical College of Yangzhou University (Yangzhou, China). All patients gave written informed consent to participate in the

Correspondence to: Mr. Ju Gao, Department of Anesthesiology, Clinical Medical College of Yangzhou University, Subei People's Hospital of Jiangsu, 98 Nan Tong Western Road, Yangzhou, Jiangsu 225001, P.R. China
E-mail: gaoju_003@163.com

*Contributed equally

Key words: ultrasound, brachial plexus, single-injection, triple-injection, shoulder surgery

study. The current trial is registered in the Chinese Clinical Trial Registry (ChiCTR-ICR-15007037).

The present study included patients presenting with an American Society of Anesthesiologists (ASA) physical status of I or II, aged ≥ 18 years and scheduled for elective arthroscopic shoulder surgery. Patients with severe chronic obstructive pulmonary disease, previous radiotherapy to the neck, coagulopathy or a body mass index (BMI) >35 kg/m² were excluded from the present study. Patient characteristics are listed in Table I. Patients were randomly assigned to the SI (n=56) or TI (n=55) group.

Interscalene blockade. Patients adopted a supine position with the head turned 45° to the non-operative side. An electrocardiograph was performed, and pulse oximetry and blood pressure monitoring was conducted as part of routine procedure.

Standard monitoring (pulse oximeter, electrocardiogram, noninvasive blood pressure) was performed during the study and oxygen (2 l/min) was supplied via a nasal cannula, and patients were intravenously administered with midazolam (0.01-0.03 mg/kg, Jiangsu Nhwa Pharmaceutical Co., Ltd., Jiangsu, China). A portable ultrasound machine (M-turbo; Fujifilm SonoSite, Inc., Bothell, WA, USA) with a 6-13-MHz linear probe was used. A 50 mm, 22 G stimulating needle (Stimuplex; B. Braun Medical, Bethlehem, PA, USA) was used to administer blocks. Blocks were performed by three anaesthesiologists with substantial experience of this method.

Using an aseptic technique, the interscalene area was imaged to obtain a clear view of the brachial plexus (Fig. 1A). Roots of C5, C6, and C7 were identified according to the description by Spence *et al* (10). Following injection of the skin with 1-2 ml of 1% lidocaine (Jiangsu Nhwa Pharmaceutical Co., Ltd.), the needle was introduced from a lateral-to-medial direction. For the SI group, the needle-tip was positioned in the middle section of the interscalene brachial plexus (Fig. 1B), and 15 ml of the LA 1% ropivacaine (Yichang Humanwell Pharmaceutical Company, Ltd., Yichang, China) was incrementally injected. In the TI group, 1% ropivacaine was injected in three aliquots of 5 ml. Aliquots were deposited in the upper-, middle, and lower-third of the interscalene brachial plexus (Fig. 1C).

Assessment of blockade. Evaluation of nerve blockades was performed by a separate anesthesiologist to those who administered the blocks. The primary outcome was the onset of sensory and motor blocks of the four nerves (radial, median, ulnar and axillary) assessed at 5 min intervals for 30 min post-injection.

Sensory blockade was defined as a loss in pinprick sensation in the territories of the radial, median, ulnar and axillary nerves, with an identical stimulus delivered to the opposite side, as a control. Sensory blockade was scored according to a four-point scale (identical sharpness = 3; reduced sharpness = 2; sensation present but not sharp = 1; sensation absent = 0).

Motor blockade was evaluated according to a modified scale of that used by Kapral *et al* (Table II) (11). The scale was based on thumb abduction (radial nerve), thumb opposition (median nerve), forearm supination/pronation (radial and

Table I. Patient characteristics of the study groups.

Variable	SI (n=56)	TI (n=55)	P-value
Age, years	55.42±14.20	53.28±15.07	0.443
Male/female	29/27	26/29	0.706
BMI, kg/m ²	26.71±6.89	27.13±7.02	0.751
ASA physical status (I/II)	30/26	31/24	0.849

Continuous variables are presented as the mean \pm standard deviation and categorical variables are presented as numbers. SI, single injection; TI, triple injection; BMI, body mass index; ASA, American Society of Anesthesiologists.

Table II. Rating scale for muscle force.

Rating	Description
6	Normal muscle force
5	Slightly reduced muscle force
4	Greatly reduced muscle force
3	Slightly impaired mobility
2	Greatly impaired mobility
1	Near complete paralysis
0	Complete paralysis

median nerves), thumb adduction (ulnar nerve), and abduction of the upper arm (axillary nerve).

Blockade duration was determined 24 h following nerve blockade by a research assistant blinded to the study protocol. Patients were instructed to record on a pre-printed card the time at which they were first able to flex their elbow, and this was defined as the endpoint of the block. Patients were instructed to attempt to flex their arm every 30 min following discharge from the operating room. Arm flexion at the elbow was chosen as the least ambiguous test to evaluate motor function during follow-up. Similarly, the first occurrence of pain as perceived by the patient ('When did you first start feeling the pain?') was used as a proxy for the return of sensory function.

Blockade performance time was defined as the time between the first ultrasound scan and removal of the needle at the end of the block. A successful blockade was determined as one with a good primary outcome (as defined above). An adequate surgical blockade was defined as one able to tolerate a simulated surgical stimulus (forceps pinching the prospective surgical area) at 30 min post-injection. Unexpected vascular punctures, symptomatic hemidiaphragmatic paresis, Horner syndrome, pneumothorax or neurological deficits were recorded. Pain intensity related to the procedure was assessed at the end of blockade using an 11-point verbal numerical rating scale (NRS) from 0 (no pain) to 10 (worst imaginable pain) by an observer blinded to the study protocol.

Statistical analysis. SPSS v. 15 (SPSS, Inc., Chicago, IL, USA) was used to perform all statistical analyses. A pilot

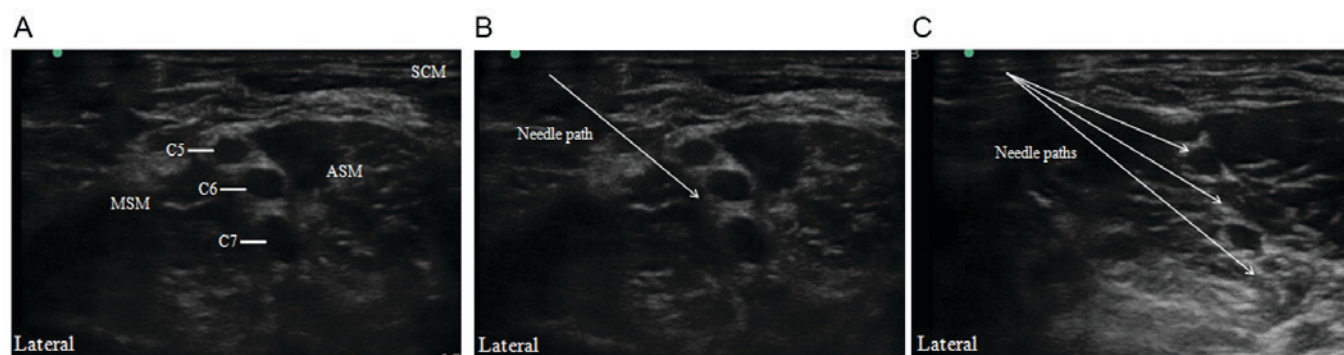


Figure 1. Ultrasound images of (A) the interscalene brachial plexus prior to needle insertion, (B) the interscalene brachial plexus with the needle positioned at the middle of the cluster and (C) sites of injection in the triple-injection method. ASM, anterior scalene muscle; MSM, middle scalene muscle; SCM, sternocleidomastoid muscle.

study was conducted on 20 patients to estimate the prevalence of a satisfactory sensory block. A satisfactory block was found to be 75% at 30 min post-injection using an SI (data not shown). It was hypothesized that multiple injections may increase this proportion to 90%. A calculated sample size of 111 patients per group was required for a statistical power of 0.90 and type-I error of 0.05. Categorical variables, including the proportion of patients with successful sensory and motor blocks at 5, 10, 15, 20, 25 and 30 min, were expressed as percentages. Continuous variables, including age and BMI, were expressed as the mean + standard deviation. The χ^2 test was used to evaluate categorical variables between the two groups, and the Student's t-test was used to compare continuous variables. Successful sensory and motor blocks at different times were compared using a Friedman's repeated-measures analysis of variance on ranks for within-group comparisons, and a Kruskal-Wallis one-way analysis of variance on ranks for intergroup comparisons. The P-value was calibrated using the Benjamini and Hochberg method. Kaplan-Meier life-table analysis was used to analyze the duration of sensory and motor blocks. $P < 0.05$ was considered to indicate a statistically significant difference.

Results

A total of 117 patients were enrolled, and 111 patients completed the study (Fig. 2). Age, sex, BMI or ASA physical status did not differ significantly between the SI and TI groups (Table I).

Success of individual sensory and motor blocks. The success rates for sensory and motor blocks in the ulnar, radial, median and axillary nerves differed between the SI and TI groups (Figs. 3 and 4). The success rates for sensory and motor blocks of the ulnar nerve from 5-30 min post-injection were significantly higher in the TI group compared with the SI group ($P < 0.05$; Figs. 3A and 4A). The prevalence of complete sensory and motor blocks of the radial and median nerves was significantly higher in the TI group at 5, 10 and 15 min ($P < 0.05$; Figs. 3B and C, and 4B and C); however, they did not differ significantly at 20, 25 or 30 min post-injection. The prevalence of complete sensory and motor blocks of the axillary nerve was significantly greater in the TI group at 5 and

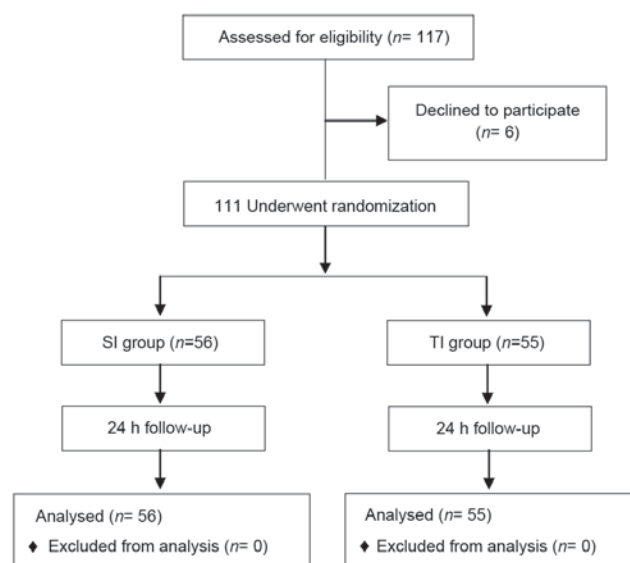


Figure 2. Flowchart of the study procedure. SI, single injection; TI, triple injection.

10 min post-injection ($P < 0.05$), while no significant difference was observed between the SI and TI groups at 15, 20, 25 or 30 min post-injection (Figs. 3D and 4D).

TI enhanced the duration of blockade. Sensation or strength did not differ significantly between the two groups at baseline testing. However, the duration of sensory and motor blocks differed significantly between the groups ($P < 0.05$; Fig. 5). Patients in the TI group described a greater sensory block to pain, beginning at 30 min following the interscalene blockade, which persisted throughout the 17 h assessment period (Fig. 5A). Similarly, motor blockade in the TI group had a longer duration compared with the SI group (Fig. 5B).

Other secondary outcomes. The blockade performance time was significantly longer in the TI group compared with the SI group ($P < 0.001$; Table III). SI and TI methods resulted in a similar rate of success at 30 min. There were no significant differences in the prevalence of unexpected vascular punctures or Horner syndrome, and symptomatic hemidiaphragmatic paresis, pneumothorax or neurological deficits were not

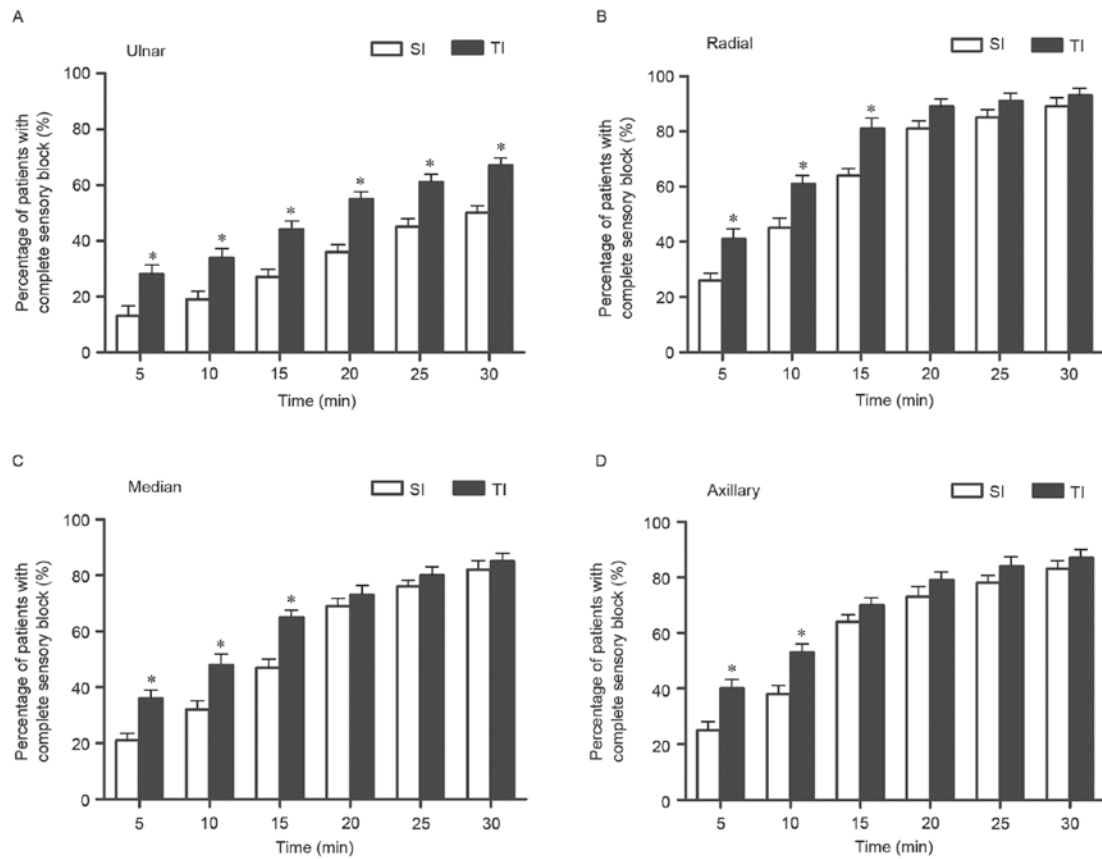


Figure 3. Percentage of complete sensory blocks of the (A) ulnar, (B) radial, (C) median and (D) axillary nerves assessed at 5 min intervals until 30 min post-injection. * $P < 0.05$ vs. SI group. SI, single injection; TI, triple injection.

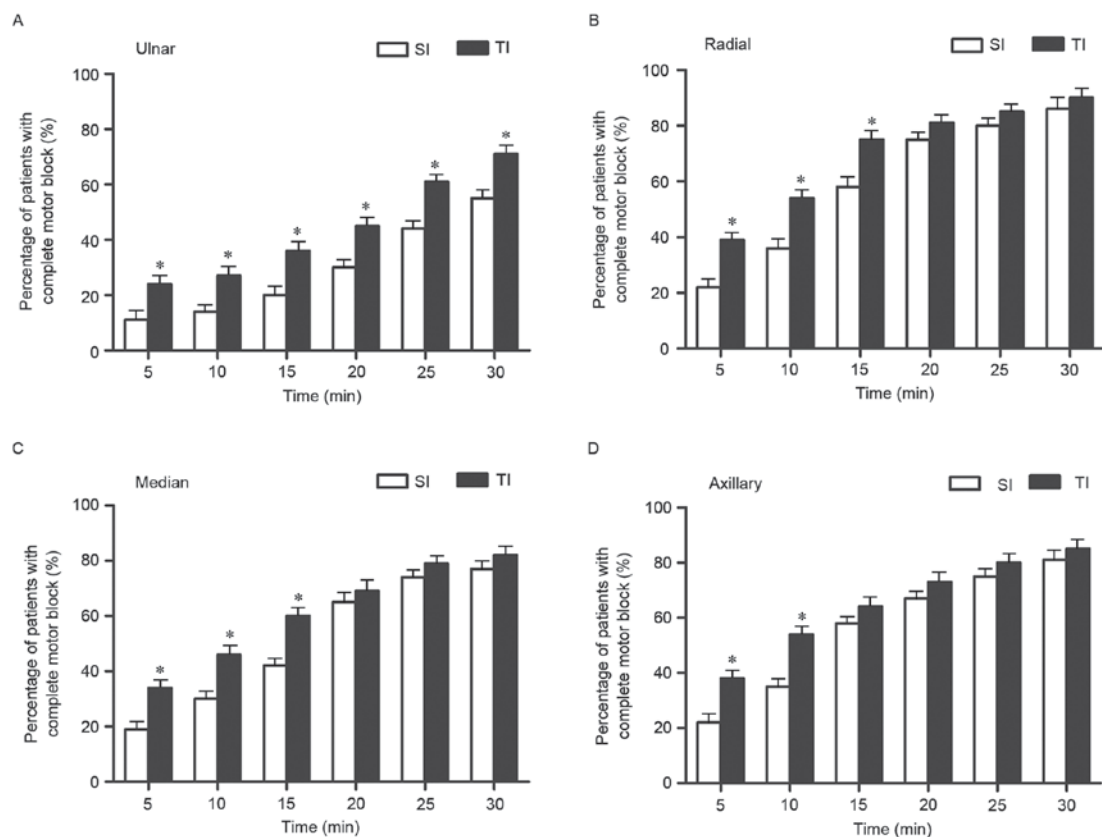


Figure 4. Percentages of complete motor blocks of the (A) ulnar, (B) radial, (C) median and (D) axillary nerves assessed at 5 min intervals until 30 min post-injection. * $P < 0.05$ vs. SI group. SI, single injection; TI, triple injection.

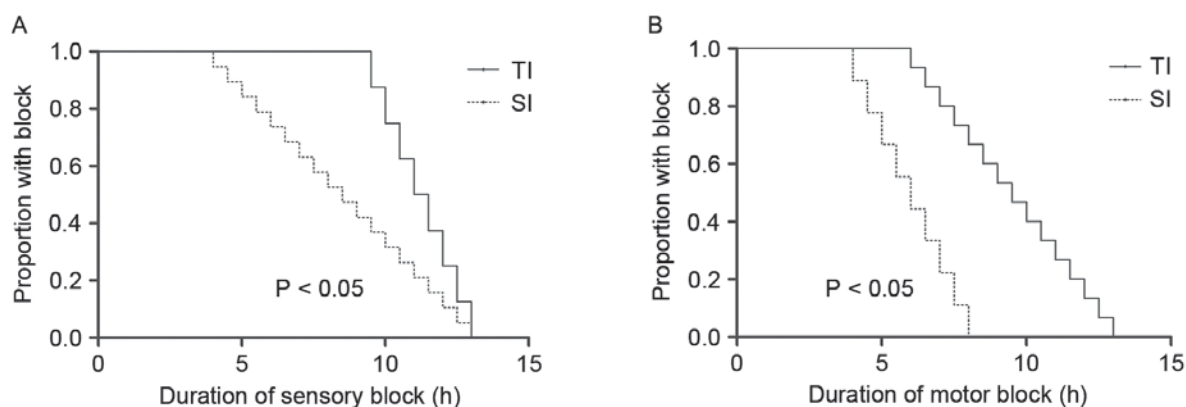


Figure 5. Survival analyses for regression of sensory and motor blocks. This was measured as the longevity of the block from the time of placement and analyzed using survival analyses (Cox model). The figure exhibits the proportion of patients reporting a block over time. Patients in the TI group reported significantly longer durations of (A) sensory and (B) motor blocks compared to patients in the SI group. SI, single injection; TI, triple injection.

Table III. Block characteristics and outcome of the two study groups.

Characteristic	SI (n=56)	TI (n=55)	P-value
Performance time, min	4.15±2.21	7.22±2.46	<0.001
Success	49 (88%)	50 (91%)	0.761
Vascular puncture	1	2	
Horner syndrome	2	2	
Symptomatic hemidiaphragmatic paresis	0	0	
Pneumothorax	0	0	
Neurological deficits	0	0	
NRS values for procedural pain	2.5 (0-7)	3 (0-8)	0.082

Continuous variables are presented as the mean ± standard deviation and categorical variables are presented as numbers. NRS is presented as the median (range). SI, single injection; TI, triple injection; NRS, verbal numerical rating scale.

observed. No significant differences were observed in the NRS results for pain during the procedure (Table III).

Discussion

In the present study, the SI and TI methods of ultrasound-guided SI and TI interscalene blocks were compared. The TI method exhibited a faster onset post-injection compared to the SI method, and patients in the TI group experienced longer sensory and motor blocks compared with the SI group. However, there was no significant difference in the success rate of surgical anesthesia at 30 min post-injection.

There have been conflicting reports regarding the quality of nerve blockade with TI compared with SI. A recent systematic review of randomized controlled trials comparing ultrasound-guided TI and SI for supraclavicular brachial plexus blockade suggested that TI may provide a modest improvement in the onset and quality of blockade (7). In the present study,

no significant differences were observed in the success rate of the two methods. However, to the best of our knowledge, this is the first study to focus on the onset of sensory and motor blocks of four nerves, as well as the duration of blockade as a primary outcome.

The TI group surpassed the SI group in achieving sensory and motor blocks at 5 min intervals for the first 10 min. A paraneural sheath surrounds the brachial plexus as a thin membrane (10,12), and it is possible that the paraneural sheath precludes the need for direct circumferential injection. As the space between nerve roots is limited, the area becomes saturated with LA, and multiple injections force incoming LA molecules to find alternate paths of less resistance. In time, this phenomenon results in the indirect spread of LA around the roots of C5, C6, and C7 (7). This mechanism may explain why, initially, the TI method provided a shorter time of onset and more successful blocks in the first 10 min. In the present study, sensory and motor blocks of the ulnar nerve were significantly more effective with TI compared with SI at all time points. The first injection of the TI was deep and potentially close to the lower trunk. Accordingly, the subsequent difference in the success of the ulnar nerve blockade may have eliminated the need for further injections, as the initial deep injection typically targets the lower region of the brachial plexus that gives origin to the ulnar nerve (13,14).

Another notable observation in the present study was that the duration of blockade was prolonged in the TI group compared with the SI group. This may have been due to reduced systemic uptake of LA in the TI group, due to more LA being contained within the brachial plexus sheath, thus increasing the reservoir volume of LA solution (10). Franco *et al* (12) described the interior of the sheath surrounding the neuronal tissue as a combination of loose connective tissue and fat, with few veins running along the sheath interior. These observations potentially explain the results of the present study, as there may have been decreased systemic absorption of LA in the TI group due to reduced vascularity on the interior of the sheath.

In conclusion, and in accordance with previous work (7,15,16), no significant difference was observed in the success rates of the SI and multiple injection methods. However, the TI method for IBPB resulted in improved onset time and

more complete sensory and motor blocks at 10 min compared with the SI method. Furthermore, the TI method deposited LA in the interscalene brachial plexus more caudally than in the SI method, which may have resulted in greater distal distribution of anesthesia and a higher blockade success in the ulnar nerve. The TI method also achieved a longer blockade duration than the SI method, and was more effective in producing postoperative analgesia. The results of the present study also suggest that the TI method may be more suitable for IBPB than the SI method due to its faster onset time and persistent analgesic effect.

Acknowledgements

The present study was supported by the National Natural Science Foundation of China (grant no. 81500947), the Jiangsu Provincial Commission of Health and Family Planning Research Project (project no. H2017059) and the Jiangsu Province Youth Medical Talent Project (grant no. QNRC2016338).

References

- Desmet M, Vanneste B, Reynvoet M, Van Cauwelaert J, Verhelst L, Pottel H, Missant C and Van de Velde M: A randomised controlled trial of intravenous dexamethasone combined with interscalene brachial plexus blockade for shoulder surgery. *Anaesthesia* 70: 1180-1185, 2015.
- Fritsch G, Danninger T, Allerberger K, Tsodikov A, Felder TK, Kapeller M, Gerner P and Brummett CM: Dexmedetomidine added to ropivacaine extends the duration of interscalene brachial plexus blocks for elective shoulder surgery when compared with ropivacaine alone: A single-center, prospective, triple-blind, randomized controlled trial. *Reg Anesth Pain Med* 39: 37-47, 2014.
- Woo JH, Kim YJ, Kim DY and Cho S: Dose-dependency of dexamethasone on the analgesic effect of interscalene block for arthroscopic shoulder surgery using ropivacaine 0.5%: A randomised controlled trial. *Eur J Anaesthesiol* 32: 650-655, 2015.
- Tsui BC and Lou L: Learning the 'traceback' approach for interscalene block. *Anaesthesia* 69: 83-85, 2014.
- Danelli G, Bonarelli S, Tognu A, Tognú A, Ghisi D, Fanelli A, Biondini S, Moschini E and Fanelli G: Prospective randomized comparison of ultrasound-guided and neurostimulation techniques for continuous interscalene brachial plexus block in patients undergoing coracoacromial ligament repair. *Br J Anaesth* 108: 1006-1010, 2012.
- Bowens C Jr, Gupta RK, O'Byrne WT, Schildcrout JS, Shi Y, Hawkins JJ, Michaels DR and Berry JM: Selective local anesthetic placement using ultrasound guidance and neurostimulation for infraclavicular brachial plexus block. *Anesth Analg* 110: 1480-1485, 2010.
- Arab SA, Alharbi MK, Nada EM, Alrefai DA and Mowafi HA: Ultrasound-guided supraclavicular brachial plexus block: Single versus triple injection technique for upper limb arteriovenous access surgery. *Anesth Analg* 118: 1120-1125, 2014.
- Tiyaprasertkul W, Bernucci F, González AP, Leurcharusmee P, Yazer MS, Techasuk W, Arnuntasupakul V, de la Garza DC, Finlayson RJ and Tran DQ: A Randomized comparison between single- and triple-injection subparaneural popliteal sciatic nerve block. *Reg Anesth Pain Med* 40: 315-320, 2015.
- Yamamoto H, Sakura S, Wada M and Shido A: A prospective, randomized comparison between single- and multiple-injection techniques for ultrasound-guided subgluteal sciatic nerve block. *Anesth Analg* 119: 1442-1448, 2014.
- Spence BC, Beach ML, Gallagher JD and Sites BD: Ultrasound-guided interscalene blocks: Understanding where to inject the local anaesthetic. *Anaesthesia* 66: 509-514, 2011.
- Kapral S, Krafft P, Eibenberger K, Fitzgerald R, Gosch M and Weinstabl C: Ultrasound-guided supraclavicular approach for regional anesthesia of the brachial plexus. *Anesth Analg* 78: 507-513, 1994.
- Franco CD, Rahman A, Voronov G, Kerns JM, Beck RJ and Buckenmaier CC III: Gross anatomy of the brachial plexus sheath in human cadavers. *Reg Anesth Pain Med* 33: 64-69, 2008.
- Bloc S, Rontes O, Mercadal L and Delbos A: Low approach to interscalene brachial plexus block: Safer under ultrasound guidance. *Anesth Analg* 113: 1282-1283, 2011.
- Kim JH, Chen J, Bennett H, Lesser JB, Resta-Flarer F, Barczewska-Hillel A, Byrnes P and Santos AC: A low approach to interscalene brachial plexus block results in more distal spread of sensory-motor coverage compared to the conventional approach. *Anesth Analg* 112: 987-989, 2011.
- Fredrickson MJ, Wolstencroft P, Kejriwal R, Yoon A, Boland MR and Chinchawala S: Single versus triple injection ultrasound-guided infraclavicular block: Confirmation of the effectiveness of the single injection technique. *Anesth Analg* 111: 1325-1327, 2010.
- Tran DQ, Bertini P, Zaouter C, Muñoz L and Finlayson RJ: A prospective, randomized comparison between single- and double-injection ultrasound-guided infraclavicular brachial plexus block. *Reg Anesth Pain Med* 35: 16-21, 2010.