SPANDIDOS PUBLICATIONS

EXPERIMENTAL AND THERAPEUTIC MEDICINE 19: 2632-2640, 2020

Fat-suppressed magnetic resonance volume interpolated examination for deep venous thrombosis compared with duplex sonography

QING FU[1,2*], QIGUANG CHENG[1,2*], SHENG WU[1,2] and XIANGCHUANG KONG[1,2]

[1]Department of Radiology, Union Hospital, Tongji Medical College, Huazhong University of Science and Technology; [2]Hubei Province Key Laboratory of Molecular Imaging, Wuhan, Hubei 430022, P.R. China

Received June 22, 2019; Accepted December 4, 2019

DOI: 10.3892/etm.2020.8500

Abstract. The aim of the present study was to evaluate magnetic resonance venography (MRV) scanned by breath-hold volume interpolated body examination with spectral fat saturation (VIBE-fs), combined with Dixon fat-suppressed VIBE (VIBE-Dixon) by using a 1.5T MR scanner for detecting deep venous thrombosis (DVT) compared with duplex sonography. A total of 31 patients with DVT were identified using duplex sonography and were enrolled in the present study for MRV examination, from the inferior vena cava to the ankle level after injection of gadopentetate dimeglumine. Venous segment-to-segment comparison was assessed for DVT detection between MRV and duplex sonography. A total of two radiologists separately performed subjective image quality assessment using a 5-point scale. Cohen's κ coefficient, Wilcoxon rank sum test and intraclass correlation coefficient values were used for statistical analysis. Of the 303 evaluated vein segments, duplex sonography identified 119 (39.3%; 119/303) venous segments with thrombus, while MRV detected 170 (56.1%; 170/303) venous segments with thrombus. The diagnostic agreement rate of DVT between duplex sonography and MRV was poor in the deep femoral vein and anterior tibial veins, while it was excellent in the inferior vena cava (IVC), common iliac vein, external iliac vein, femoral vein, popliteal vein, posterior tibial veins and peroneal veins. In addition, poor reliability was detected in the deep femoral vein, anterior tibial veins and peroneal veins, but good to excellent reliability was observed in IVC, common iliac vein, external iliac vein, femoral vein, popliteal vein and posterior tibial veins. Furthermore, image quality scores of each venous segment between the two radiologists indicated no statistical difference. Therefore, MRV scanned using VIBE-fs for the suprainguinal and VIBE-Dixon for the infrainguinal region may be a useful method for detecting DVT compared with duplex sonography. The results of present study proved this MR protocol to be a beneficial alternative imaging modality for the detection of DVT when duplex sonography is inadequate or not able to be performed.

Correspondence to: Professor Xiangchuang Kong, Department of Radiology, Union Hospital, Tongji Medical College, Huazhong University of Science and Technology, 1277 Jiefang Avenue, Wuhan, Hubei 430022, P.R. China
E-mail: hongke80@hust.edu.cn

*Contributed equally

Abbreviations: DVT, deep venous thrombosis; MRV, magnetic resonance venography; VIBE, Volume Interpolated body examination; CDFI, Color Doppler flow imaging

Key words: magnetic resonance venography, volume interpolated body examination, deep venous thrombosis, duplex sonography, fat suppression

Introduction

Conventional venography has been considered as the gold standard in detecting deep venous thrombosis (DVT), even in patients who are asymptomatic (1,2). However, its clinical application has been limited due to several disadvantages, including pain, the requirement of ionic contrast agents, radiation exposure, the fact it is time consuming and the lack of reliability in cases due to patient contraindication or technical issues (3). CT allows the evaluation of DVT with a 'combined CT venography and pulmonary angiography imaging procedure initially introduced by Loud *et al* (4), but radiation exposure of CT venography notably increases the gonadal dose (5). Further limitations include poor venous enhancement and streak artifacts from orthopedic implants (6). Alternatively, duplex sonography is the most widely used imaging modality for symptomatic DVT assessment from the common femoral to the popliteal vein due to its high sensitivity at 76-100% and specificity at 96-100%, compared with conventional venography (7,8). However, the accurate evaluation of pelvic and abdominal veins is operator-dependent and requires extensive experience (9).

MRI has gained growing interest due to absence of radiation exposure, improved ability for displaying soft tissues, visualization of proximal and peripheral venous vasculatures with high spatial resolution (6,7,10). Magnetic resonance venography (MRV) offers superior evaluation for venous thrombus

in the abdomen, pelvis and lower limbs of patients (10,11), despite complications including swollen legs, edema, wounds, obesity, plaster involvement, iodinated contrast agents and interference of bowel gas, which are also technical limitations for conventional venography and duplex sonography (12).

A variety of MRI techniques are available for the evaluation of the venous system (13). Time-of-flight MRV is a non-contrast-enhanced method that relies on the intrinsic properties of flowing blood, but it requires longer image acquisition time and is limited by flow artifacts and saturation effect, which may decrease diagnostic accuracy (7). MR direct thrombus imaging involves injecting dilute gadolinium directly into the distal extremity of expected pathology (14-16). However, MR direct thrombus imaging cannot be used if alternative sites of intravenous access if thrombus or obstruction have been identified, as this method requires venous cannulation of the affected extremity (15,16).

Volume interpolated body examination (VIBE) is a gradient echo MR sequence first introduced by Rofsky *et al* (17), which can produce high isotropic resolution images, combined with fat-suppression technique, by minimizing partial volume effect and maximizing tissue contrast in contrast-enhanced MR examinations. Visualization of vascular structures maybe improved by administration of an intravenous contrast agent, and contrast-enhanced MRV using fat-suppressed VIBE is an efficient method with superior visualization capability to depict thrombus in the abdomen, pelvis and lower limbs (18-21).

VIBE with spectral fat saturation (VIBE-fs) in previous MRV studies requires frequency-selective saturation pulse, which must be equal to the fat resonance frequency (22). VIBE-fs is sensitive to static magnetic field non-uniformity, thus is inadequate when used in large field of view imaging (22), and results in an unsatisfied fat saturation efficacy, which may affect visualization and the evaluation of small vessels. In contrast to spectral fat saturation, the Dixon fat-suppressed technique does not require a fat-selective pulse (20,22). To the best of our knowledge, there have been no previous studies investigating the use of Dixon fat-suppressed VIBE (VIBE-Dixon) for DVT detection in the lower leg.

The present study investigated the feasibility of using high resolution MRV, breath-hold VIBE-fs for the abdominopelvic region and VIBE-Dixon for the lower legs on a 1.5T MR scanner, to evaluate DVT compared with duplex sonography.

Materials and methods

Study population. The current prospective study was approved by The Medical Ethics Committee of Huazhong University of Science and Technology. Patients were informed of procedures, and written consent was obtained.

In total, 31 consecutive patients (men, 18; women, 13; mean age, 50.1±14.8 years; age range, 17-75 years) with DVT identified by duplex sonography between January 2015 and March 2016 were included in the present study. All patients presented with leg swelling or leg pain, and were recruited from Union Hospital, Tongji Medical College, Huazhong University of Science and Technology (Wuhan, China). Of the 31 patients, there were 29 in patients and 2 out patients; a total of 10 patients (32.3%) presented with DVT only, 21 (67.7%) exhibited pulmonary embolism and DVT. D-Dimer is a marker of endogenous fibrinolysis and can be detected in patients with DVT (23). A total of 2 ml of blood was taken from the 20 patients who were required to undergo D-Dimer testing, followed by duplex sonography, and the results of the D-Dimer test ranged from 0.9-20.0 mg/l (6.0±5.1 mg/l; reference value, <0.5 mg/l); the other 11 patients were not required to take the test as their DVT had previously been confirmed using duplex sonography. The exclusion criteria were as follows: i) Pregnant women; ii) inability to accomplish MR imaging due to severe dyspnea, continuous cough and shock; iii) contraindication to MR scanning; iv) acute or chronic severe renal impairment (estimated glomerular filtration rate, <30 ml/min/1.73 m^2); and v) inability to establish intravenous access.

Duplex sonography. Duplex sonography was performed by a specialized radiologist, with >15 years of experience in duplex sonography, using the same duplex sonography device (LOGIQ E9; GE Healthcare) equipped with a 7.5-MHz probe for the lower leg, and a 3.0- or 5.0-MHz probe for the abdominal-pelvic region. The medical reports were acquired via the electronic medical record of our hospital. Duplex sonography examined and detected DVTs in the left leg of 22 patients, the right leg in five patients and on both sides of the leg in four patients, according to clinical demands. Therefore, duplex sonography examined 35 single legs in all [22+5+(4x2)=35]; the inclusion and exclusion of patients are presented in Fig. 1. Diagnostic standards for DVT were as follows: i) The infrainguinal veins could be imaged by Color Doppler flow imaging (CDFI) and compression sonography; ii) DVT could be diagnosed with the visualization of intraluminal thrombus; iii) venous lumen filled with weak echo; iv) venous lumen cannot be completely flattened when being pressured; and v) the absence of blood flow within the veins on CDFI. As suprainguinal veins are too deep to be fully compressible, longitudinal and transverse sections of the abdominal-pelvic veins were examined using Doppler for the presence of spontaneous flow, and DVT was diagnosed by the absence of flow using Doppler and the absence of blood flow on CDFI (24).

MR scanning protocol. All patients were scanned using a 1.5T MR scanner system (MAGNETOMAera; Siemens Healthineers) equipped with 45 mT/m gradient strength and a 200 T/m/s maximum slew rate. The MR scanning was carried out 1.7±1.8 days after duplex sonography. The abdomen and pelvic regions were covered with two matrix coils with 12 channels. A peripheral angiography phased-array coil equipped with 32 channels covered the lower extremities. Patients were positioned in the supine position, head-first toward the bore of the magnetic field. The arms of the patients were positioned on the bilateral sides, the bilateral legs were tied up using the belts of peripheral coil and ankles were elevated using a folded soft sponge to avoid compression of leg veins and motion artifacts. Gadopentetate dimeglumine (Magnevist; Bayer Schering Pharma AG) was administered via a right intravenouscatheter at the rate of 2.5 ml/s, with a total volume 0.15 mmol/kg using a power injector (Stellant injection system MedRad; Bayer AG). A 15 ml saline chaser bolus was also administered at the same aforementioned rate.

MRV examinations were performed by applying fat-suppressed VIBE in the coronal projection. The craniocaudal scanning range from diaphragm to ankle level was divided into

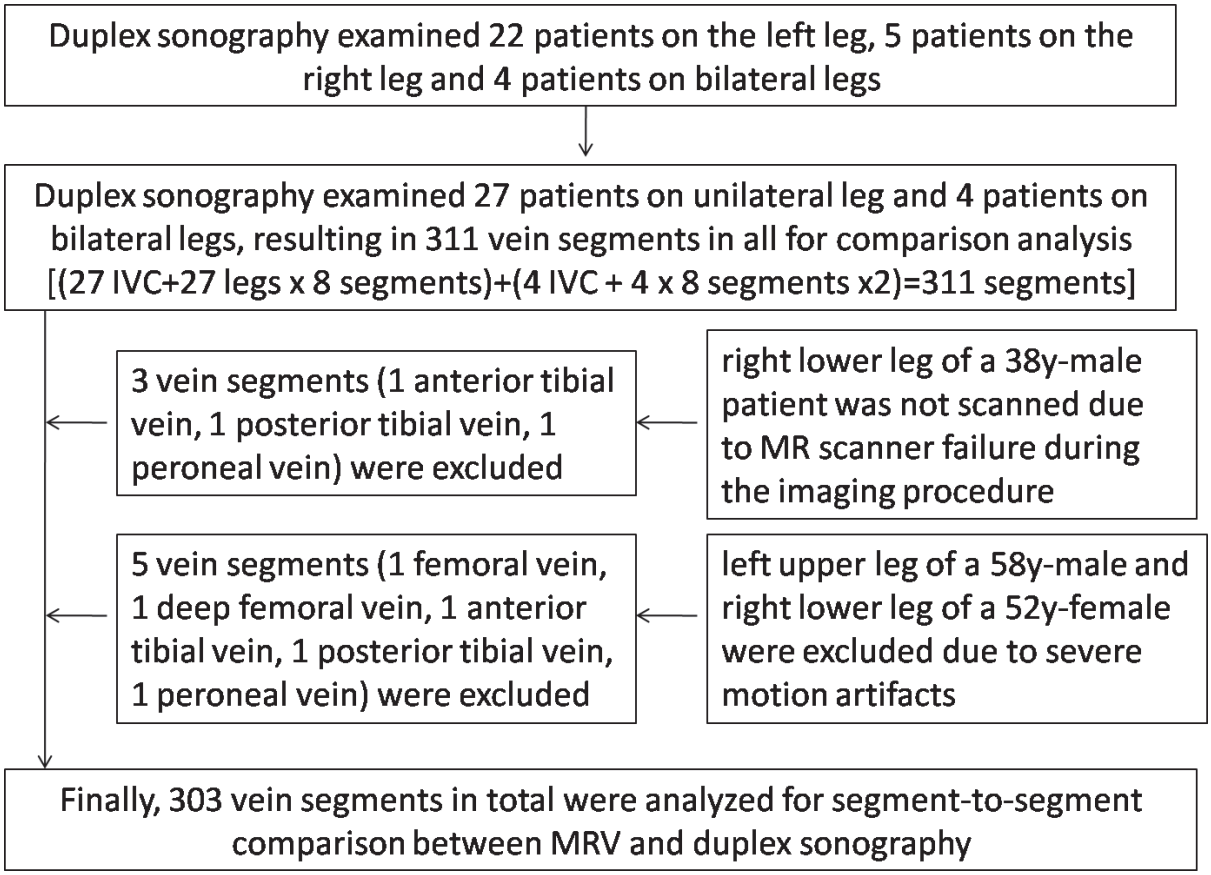

Figure 1. Inclusion and exclusion of the venous segments for the per-vein-segment comparison between MRV and duplex sonography. IVC, inferior vena cava; MRV, magnetic resonance venography.

three stacks, the abdominal and pelvic region, the upper leg region and the lower leg region. Imaging acquisition was initiated 3 min after gadolinium injection via a right intravenous antecubital catheter. The total imaging matrix technique (TIM) was applied, which eliminated the need for patient positioning and manual coil changes during MR scans. The abdominal and pelvic region was scanned from the diaphragm to the iliac vein region for the inferior vena cava (IVC), bilateral common, external and internal iliac veins. Breath-hold VIBE-fs was performed to avoid motion artifacts in the abdominal-pelvic region, and patients held their breath for 18 sec during each examination. Upper and lower legs from the iliac vein region to ankle level were analyzed in two consecutive regions using high-resolution VIBE-Dixon without breath-holding; these two regions were acquired with voxel size of 0.5x0.5x1 mm. Detailed parameters of gradient echo VIBE are listed in Table I. The diagnostic criterion for DVT in MRV were defined as visualization of direct hypointensity filling defects in venous lumen or non-visualization of a venous segment (13).

MR image processing. The generated coronal images were transferred to the Syngo MR workstation (Siemens AG) for analysis and review. Coronal images and reconstructed axial images were used for evaluation in a fixed order: IVC, pelvic veins, upper leg veins and lower leg veins. Multiplanar reconstruction, curved planar reconstruction and maximum intensity projection were reconstructed as required according to diagnostic demands.

Subjective image quality evaluation. In the present study, two radiologists with 12 years and 5 years of MR experience, who were unaware of duplex sonography results or D-Dimer test results, analyzed the MR images for DVT detection. The venous segment-to-segment comparison analysis between MRV and duplex sonography for DVT detection was based on vein segments of i) IVC; ii) common iliac vein; iii) external iliac vein; iv) internal iliac vein; v) femoral vein; vi) deep femoral vein; vii) popliteal vein; viii) anterior tibial veins; ix) posterior tibial veins; and x) peroneal veins. The venous segments i-x) were evaluated independently for MRV image quality by the two experienced radiologists using a modified 5-point scaling system (21). The following point system was used: 5, Excellent, without blurring/artifacts, sharply defined vessel borders; 4, good, with minimal blurring/artifacts, good sharply of the vessel borders; 3, moderate, with vessel segments clearly definable with moderate blurring/artifacts, sharpness of vessel border is insufficient: 2, poor, with vessel segments definable but with significant blurring/artifacts, vessel borders only suspected but not clearly visible; and 1, non-diagnostic.

Statistical analysis. Statistical analysis was performed using Cohen's κ coefficient statistic in MRV and duplex sonography diagnostic agreement of DVT for venous segment-to-segment comparison. According to the Fleiss classification (25) (poor, <0.40; moderate, 0.40-0.59; good, 0.60-0.75; excellent, >0.75), inter-observer variability between two attending radiologists was analysed using Wilcoxon rank sum test. Intraclass

Table I. Parameters of gradient echo VIBE for abdominal, pelvic and lower extremities.

Imaging region	Abdominal and pelvic region	Upper and lower leg regions
Sequence	VIBE with spectral fat saturation	VIBE with Dixon
Repetition time/echo time, ms	3.47/1.27	6.95/2.39
Field of view, mm^2	400	400
Slice thickness, mm	1.50	1.00
Slice interval, mm	0.30	0.20
Number of slices	88	104
Flip angle, °	10	10
Bandwidth, Hz/px	450	450
Phase encoding direction	R/L	R/L
iPAT acceleration factor	3	2
Matrix size	237x320	384x384
Acquisition time	18 sec	2 min 27 sec for upper or lower legregions, 4 min 54 sec for whole legs

VIBE, volume interpolated body examination; R/L, right/left; iPAT, integrated parallel acquisition technique.

Table II. Per-vein-segment analysis of deep vein thrombosis between magnetic resonance venography and duplex sonography in 31 patients.

Vein segment	Duplex sonography	Magnetic resonance venography	K value	ICC	95% CI
Inferior vena cava	4	5	0.89	0.87	0.76-0.94
Common iliac vein	10	13	0.87	0.74	0.54-0.86
External iliac vein	9	13	0.81	0.74	0.54-0.86
Femoral vein	13	14	0.96	0.94	0.89-0.97
Deep femoral vein	2	12	0.28	0.21	0.07-0.48
Popliteal vein	25	27	0.96	0.86	0.73-0.92
Anterior tibial veins	4	23	0.28	0.13	0.09-0.38
Posterior tibial veins	26	31	0.90	0.55	0.27-0.75
Peroneal veins	26	32	0.89	0.43	0.13-0.67

ICC, intraclass correlation coefficient; CI, confidence interval.

correlation coefficient (ICC) estimates and 95% CI were calculated using SPSS software (SPSS 22; IBM Corp.) based on absolute agreement, a two-way random model was used for the reliability analysis (poor reliability, <0.5; moderate reliability, 0.5-0.75; good reliability, 0.75-0.9; excellent reliability, >0.9). P<0.05 was considered to indicate a statistically significant difference.

Results

Patient data. All 31 enrolled patients finished MRV successfully without allergic reactions. A total of eight venous segments were excluded due to MR scanner failure during the imaging procedure (three venous segments), and severe motion artifacts (five venous segments; Fig. 1). A total of 303 vein segments were analyzed for segment-to-segment comparison between MRV and duplex sonography in the present study. Of the 303 evaluated vein segments, duplex sonography identified 119 (39.3%) vein segments with thrombus, while MRV detected 170 (56.1%) vein segments with thrombus (Table II). Therefore, a total of 51 additional DVT vein segments were detected using MRV compared with duplex sonography (images of one representative patient shown in Fig. 2A-M). In six patients, separation of water-only and fat-only images were incorrectly reconstructed, so that one leg demonstrated fat-only signal, the other leg revealed water-only signal in the water-only image and the same condition in the fat-only image (images of one representative patient shown in Fig. 2E-G).

Agreement evaluation. The detection agreement rate of DVT between MRV and duplex sonography was poor in deep femoral vein (κ value=0.28) and anterior tibial veins (κ value=0.28), while excellent in other vein segments (Table II). Excellent reliability was detected in the femoral vein, good reliability in IVC and popliteal vein, moderate reliability in common iliac vein, external femoral vein and posterior tibial

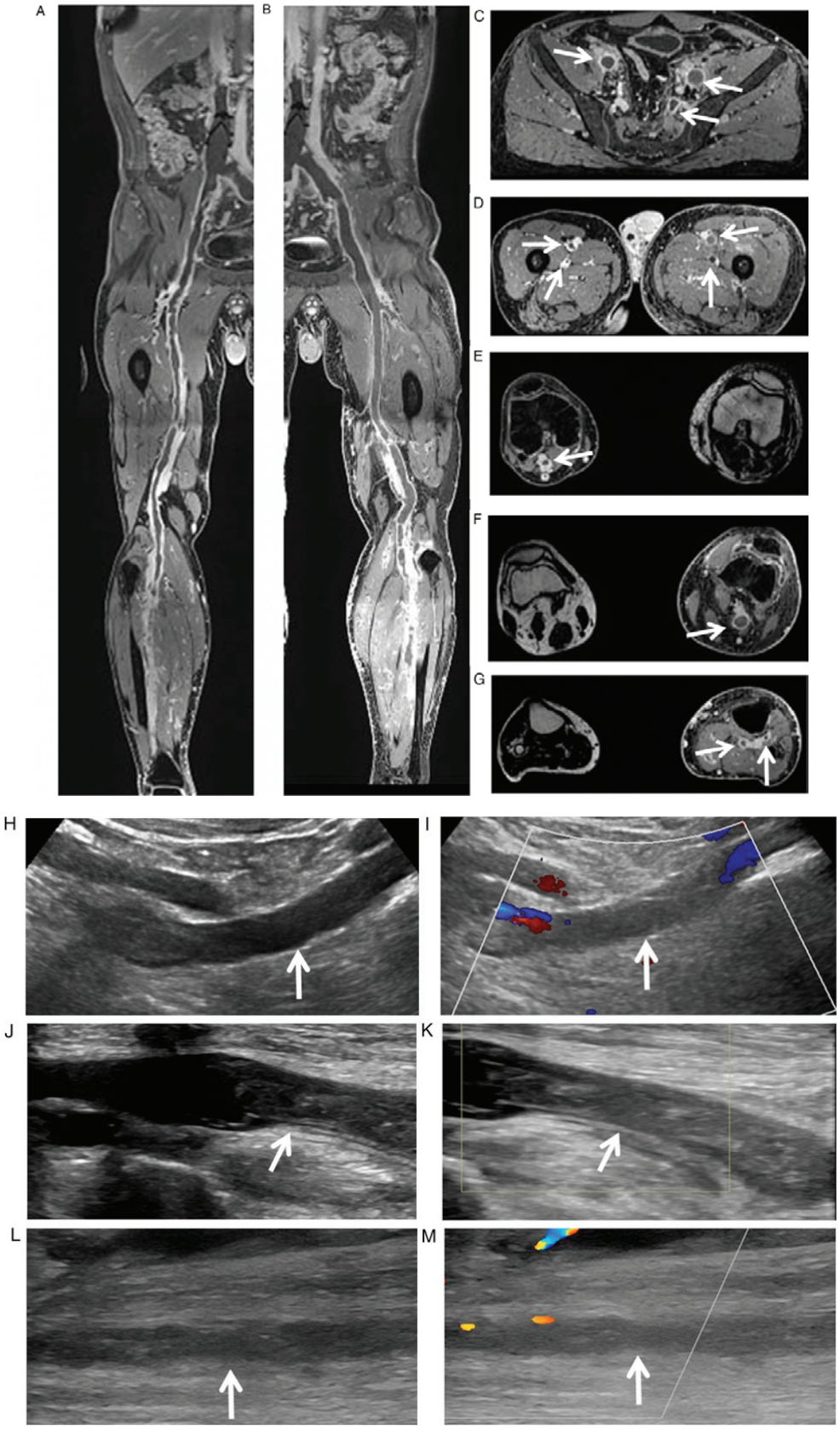

Figure 2. DVT from distal extremities extended to IVC. The images were obtained from a 53-year-old female patient who had leg swelling for 2 weeks, and accepted IVC filter implantation 1 year prior. (A) Coronal curved planar reconstruction (CPR) image and (B) coronal CPR image of abdomen, pelvic and lower extremities showed extended range of the thrombus. (C) Axial multiplanar reconstruction (MPR) image and (D) axial MPR image indicated thrombus in the bilateral external iliac veins and left internal iliac vein, bilateral deep femoral vein and femoral veins, as depicted by the arrows. (E) Axial MPR image and (F) axial MPR image showed thrombus in right popliteal vein and left popliteal vein, as depicted by the arrows. (G) Axial MPR images of the thrombus in the left posterior tibial vein and peroneal vein, as depicted by the arrows. Compression sonography images of (H) the left external iliac vein, (J) left popliteal vein and (L) left peroneal vein showed that the thrombus could be depicted and venous lumen could not be completely flattened when pressure was applied, as indicated by the arrows. CDFI images of the (I) left external iliac vein, (K) left popliteal vein and (M) left peroneal vein showed that absent blood flow within these veins could be detected clearly, as indicated by the arrows. CDFI, Color Doppler flow imaging; IVC, inferior vena cava.

Table III. Image quality scores of magnetic resonance venography based on per-vein-segment, based on a 5-point scale.

Vein segment	Observer A	Observer B	P-value
Inferior vena cava	4.74±0.45	4.77±0.43	0.71
Common iliac vein	4.82±0.38	4.81±0.40	0.76
External iliac vein	4.84±0.37	4.87±0.34	0.41
Internal iliac vein	4.90±0.30	4.84±0.37	0.16
Femoral vein	4.97±0.18	4.98±0.13	0.32
Deep femoral vein	4.98±0.13	5.00±0.00	0.32
Popliteal vein	4.95±0.22	5.00±0.00	0.08
Anterior tibial veins	4.69±0.50	4.74±0.44	0.18
Posterior tibial veins	4.71±0.50	4.76±0.43	0.32
Peroneal veins	4.76±0.47	4.81±0.40	0.18
Overall mean scores	4.85±0.37	4.87±0.33	0.05

Data are presented as the mean ± SD.

veins, and poor reliability in the deep femoral vein, anterior tibial veins and peroneal veins (Table II). As for the 35 internal iliac veins, duplex sonography only detected 18 internal iliac vein segments, including one DVT involved, 16 were diagnosed to be negative and one was not assessible. However, MRV examined all the 35 internal iliac vein segments and found thrombus in nine internal iliac veins, while the other 26 were negative.

Image quality. Image quality was poor in five vein segments due to severe motion artifacts, which were excluded from the segment-to-segment comparison mentioned above. The present results suggested that the scores of venous segments in MRV between two radiologists indicated no statistical difference. The overall mean score for visualization of vein segments was 4.86±0.35, indicating excellent image quality (Table III). No statistical difference in the interobserver variability was observed between the two radiologists. In addition, the ICC value was 0.62, with 95% CI 0.56-0.66 (P<0.001), thus indicating moderate interobserver reliability.

Additional findings. Along with the vein segments used for segment-to-segment comparison, MRV additionally examined 27 other single legs, which were not identified by duplex sonography, and indicated 38 vein segments with thrombosis. This included one common iliac vein, one internal iliac vein, one external iliac vein, two femoral veins, three popliteal veins, four anterior tibial veins, 14 posterior tibial veins and 12 peroneal veins. In addition, except for the thrombus detected in the deep venous system, duplex sonography incidentally identified thrombus in five great saphenous vein segments and five small saphenous vein segments, while MRV detected thrombus in 11 great saphenous vein segments and six small saphenous vein segments. Furthermore, duplex sonography identified varicosities with thrombus in the great saphenous vein in three patients, which were also clearly visible in MRV images, and had been identified by high ligation of great saphenous vein and varicose vein stripping surgery after duplex sonography and MRV (Fig. 3).

Discussion

To the best of our knowledge, the present study is the first to demonstrate the application of high resolution MRV compared with duplex sonography for DVT assessment, using VIBE-fs for abdominopelvic DVT (acquisition time, 18 sec) and VIBE-Dixon for lower leg DVT (acquisition time, 4 min 54 sec). The deep venous system was assessed using per-vein-segment analysis rather than per-embolus or per-patient analysis, despite the limited number of patients enrolled in the present study. Overall, MRV detected more DVT-involved vein segments compared with duplex sonography, especially in the deep femoral vein and anterior tibial veins.

MRV VIBE has been reported to be a faster and more efficient method for identification of a normal venous system of legs (18). Hansch *et al* (19) introduced a combined protocol for pulmonary arteries and abdominal/pelvic/leg veins by scanning VIBE-fs after a blood pool contrast agent injection; in this protocol venous system from ankle to IVC were visualized at a high level of image quality. In addition, Bashir *et al* (26) used VIBE-fs to compare iron-based ferumoxytol and gadolinium-based gadofosveset for abdominopelvic and lower extremity venous enhancement, from the central IVC to popliteal vessels, in patients with end-stage renal diseases. However, differing from these previous MRV studies using VIBE-fs, the present study included high resolution VIBE-Dixon for infrainguinal DVT in the MRV protocol.

Unlike spectral fat saturation, Dixon fat-suppressed technique used in present study is a multi-echo modulating technique based on difference of the frequency between fat and water molecules. Dixon fat-suppressed technique produces four tissue-contrast images: In-phase, opposed-phase, fat-only and water-only images; fat-only and water-only images can be subsequently reconstructed by complex signal addition or subtraction calculation by signals of in-phase and opposed-phase images; the water-only image obtained by the Dixon's technique can be used for fat suppression (20,27-29). A previous mouse study reported that Dixon fat separation provided a more reliable and homogenous fat suppression compared with a chemical saturation method in phantoms and *in vivo* experiments (27). In previous phantom studies, signal-to-noise-ratio is higher in Dixon fat saturation T1 weighted images compared with conventional fat saturation (28,29). In the present study, the separation of fat and water was not achieved completely in six patients, which may be related with B0-inhomogeneity phase differences (20). However, this did not reduce the observations of the venous system of the lower legs, as fat suppressed images could be obtained by fat-only and water-only images. Therefore, the venous vasculatures could be visualized continuously by combining the two images.

Although the gadolinium-based blood pool contrast agent gadofosveset trisodium was not applied in the present study, the conventional extracellular gadolinium-based contrast agent gadopentetate dimeglumine used had been proven to be feasible in previous studies (21,30). Furthermore, the MRV VIBE sequence was initiated 3 min after contrast administration in the present study, in order to achieve veins fully filled with contrast material in the venous system.

Sensitivity for distal DVT of MRV has been reported to be lower than proximal DVT (62.1% vs. 93.9%) in a previous

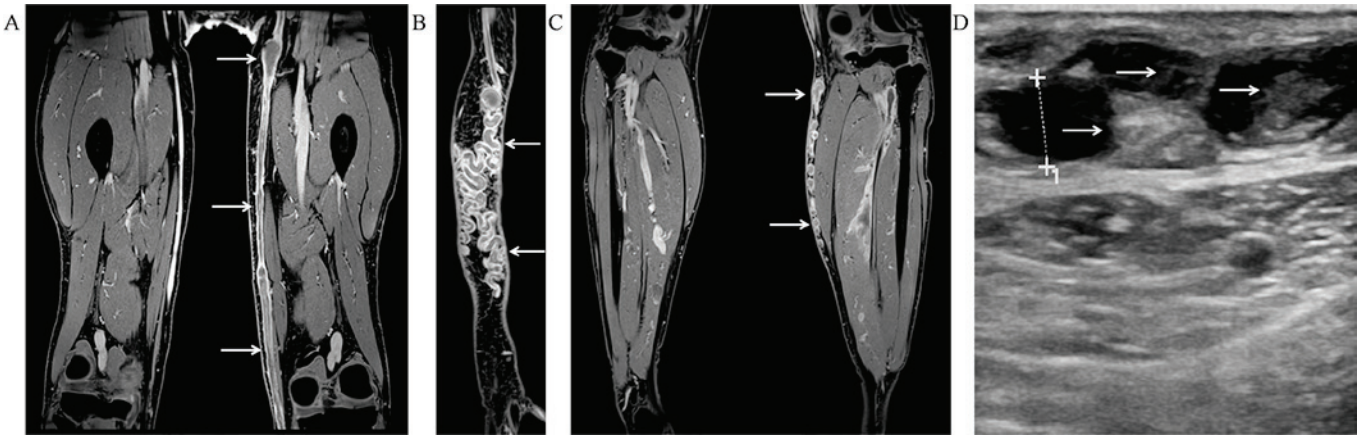

Figure 3. Thrombus and varicosity in left great saphenous vein in a 49-year-old man, these were identified by high ligation of the left great saphenous vein and varicose vein stripping surgery 3 days after MRV and duplex sonography. MRV by VIBE-Dixon. (A) Coronal curved planar reconstruction image. (B) Sagittal curved planar reconstruction image and (C) coronal image showed the thrombus and varicosity, as indicated by the arrows. (D) Compression sonography showed thrombus in the left great saphenous vein with incomplete compression, as indicated by the arrows. MRV, magnetic resonance venography; VIBE, volume interpolated body examination.

meta-analysis (13). High signals caused by intravenous gadolinium-based contrast agent in the vessels allows for better depiction of venous characterization in contrast enhanced MRV, and the more homogenous fat suppression using the Dixon fat saturation technique may improve the visualization of small vessels (28). Therefore, the present study used VIBE-Dixon with a higher resolution (voxel size, 0.5x0.5x1) in the lower leg.

MRV VIBE-Dixon in the present study detected 13 and 30 more vein segments with DVT compared with duplex sonography in femoropopliteal veins and distal veins, especially for deep femoral vein and anterior tibial veins. The poor visualization of deep femoral vein may be related to the depth and the relative inaccessibility of duplex sonography, due to the limited range of ultrasound waves in tissues. Anterior tibial veins are not recommended to be investigated routinely as they have been previously reported to be rarely affected by DVT (31-33).

In the present study, the patients enrolled were all symptomatic with leg swelling and leg pain, so the anterior tibial veins were examined and evaluated. The inferiority of duplex sonography in anterior tibial veins observed in the present study may be related to the edema in the legs, and the inexperienced operators for detecting the anterior tibial veins which is not performed routinely in clinical practice. Moreover, benefitting from higher spatial resolution, MRV for visualizing subtle vein segments and hypointensity filling defects could be displayed clearly with the surrounding high intravascular enhancement. In addition, homogeneous fat suppression allows MRV to be useful for visualizing these vein segments (20).

With regards to the abdominopelvic region, duplex sonography has a limited ability to detect pelvic and abdominal thrombus due to complications, including obesity, bowel gas, impeded acoustic penetration and its operator dependent feature (9,32). In the present study, MRV VIBE-fs used for the abdominopelvic region detected eight more DVT involved vein segments compared with duplex sonography, including one in the IVC, three in common iliac veins and four in the external iliac vein. Although the internal iliac vein was not used for segment-to-segment comparison, the present results suggested that MRV may also be suitable for displaying the anatomy of internal iliac veins, related thrombus inside the IVC and pelvic veins, which is consistent with previous studies (10,11,21).

Evaluation of abdominopelvic veins, especially for the IVC scanned with VIBE-fs, was assessed as contrast-enhanced MRV offers good tissue contrast between thrombus and intravascular blood in the IVC despite the interference of bowels, which is essential to determine the accurate site for IVC filter placement in clinical practice. Moreover, in the present study, MRV could display the bilateral venous system of lower extremities and the bilateral pelvic vessels simultaneously with the help of the peripheral angiography phased-array coil.

Despite the limitations of duplex sonography, it has advantages for DVT diagnosis. Duplex sonography is non-invasive, cost effective treatment, which is available for critically ill patients and has largely replaced conventional venography as the standard for clinically suspected DVT diagnosis with a high sensitivity and specificity (12). Compression sonography alone would be an appropriate test when identifying proximal DVT as it can achieve an optimal specificity of 97.8%, while combined color-doppler method is the appropriate technique for identifying distal DVT (12). Ultrasound elastography (UE) can estimate elastic properties of soft tissues such as stiffness, and it has been reported that UE may be a promising technique to distinguish between acute and chronic DVT (34). However the clinical applicability of UE to DVT has not yet been fully investigated (34).

With the advantages of MRV, this technique may be considered as an alternative method for DVT assessment to duplex sonography. However, it is not feasible in patients with contraindications to gadolinium-contrast MR imaging, such as patients with renal insufficiency with an estimated glomerular filtration rate<30, pregnant women, those with a history of allergic reaction to gadolinium-based contrast material, critically ill patients who cannot tolerate MR scanning, claustrophobic patients or those unable to establish venous access, which is necessary for contrast-enhanced MRV (35). Moreover, compared with duplex sonography, MR examination

has a relatively higher cost with the use of contrast material and a higher acoustic noise, and the main reason for the noise is related to mechanical vibrations of gradient coil during rapid switching of gradients (36).

The present study had limitations. First, while conventional venography is generally accepted as the gold standard for imaging DVT, it is rarely performed in clinical practice (6). It is also a limitation to use duplex sonography alone as the reference standard. Additionally, whilst acquisition time for lower leg is only 4 min 54 sec, VIBE-Dixon with a higher resolution in the present study requires enormous reconstruction data, which consumed 6 min for each Dixon-region to obtain coronal images. Therefore, the five vein segments excluded from the comparative evaluation, related with severe motion artifacts, were not scanned again in a timely manner, despite a dedicated reconstruction computer available in the department. Due to this reason, the present study had scanned the abdominopelvic region with breath-hold VIBE-fs, as the images could be visualized simultaneously after the scanning, which is helpful to scan the sequence again if the images are affected by motion artifacts related with the breath-hold. Moreover, since thrombus detection in the deep venous system was the primary aim of the present study, there was no systematic analysis of the superficial veins between duplex sonography and MRV, thus further studies are required. Another limitation was that the time used in duplex sonography and MRV was not recorded, as acquisition time for MRV was ~6 min in the present study, and time for patient-positioning and image reconstruction was not included. In addition, although CT venography (CTV) has considerable ionizing radiation exposure, a lower kVp setting with a modified reconstruction technique can help to decrease the radiation dose while maintaining the image quality in CTV (37). Therefore, a limitation of the present study includes the absence of a comparison between MRV and CTV.

In conclusion, the results of the present study suggested that contrast enhanced MRV scanned by VIBE-fs for supra-inguinal and VIBE-Dixon for infrainguinal regions may be a feasible method for venous system depiction and DVT detection in abdomen, pelvic and lower extremities. Agreement rate analysis results suggested that MRV, compared with duplex sonography, may be a good alternative imaging modality for DVT assessment when duplex sonography is inadequate or not feasible.

Acknowledgements

The authors would like to thank Dr Qing-Chang Chen, (Department of Ultrasound, Union Hospital, Tongji Medical College, Huazhong University of Science and Technology, Wuhan, China) for his assistance in providing images of duplex sonography.

Funding

No funding was received.

Availability of data and materials

The datasets used and/or analyzed during the present study are available from the corresponding author on reasonable request.

Authors' contributions

QF and QGC performed the scans, prepared the figures and wrote the manuscript. SW performed the statistical analysis. SW and XCK analyzed the images. All authors approved the final manuscript.

Ethics approval and consent to participate

This prospective study was approved by The Medical Ethics Committee of Tongji Medical College, Huazhong University of Science and Technology. Patients were informed of procedure and purpose of this study, and written consent was obtained.

Patient consent for publication

All the patients provided written informed consent for the publication of the associated data and accompanying images.

Competing interests

The authors declare that they have no competing interests.

References

1. Kearon C, Ginsberg JS, Douketis J, Crowther MA, Turpie AG, Bates SM, Lee A, Brill-Edwards P, Finch T and Gent M: A randomized trial of diagnostic strategies after normal proximal vein ultrasonography for suspected deep venous thrombosis: D-dimer testing compared with repeated ultrasonography. Ann Intern Med 142: 490-496, 2005.
2. Gaitini D: Multimodality imaging of the peripheral venous system. Int J Biomed Imaging 2017: 54616, 2007.
3. Eikelboom JW, Hirsh J, Spencer FA, Baglin TP and Weitz JI: Antiplatelet drugs: Antithrombotic therapy and prevention of thrombosis, 9th ed: American College of chest physicians evidence-based clinical practice guidelines. Chest 141 (2 Suppl): e89S-e119S, 2012.
4. Loud PA, Grossman ZD, Klippenstein DL and Ray CE: Combined CT venography and pulmonary angiography: A new diagnostic technique for suspected thromboembolic disease. AJR Am J Roentgenol 170: 951-954, 1998.
5. Rademaker J, Griesshaber V, Hidajat N, Oestmann JW and Felix R: Combined CT pulmonary angiography and venography for diagnosis of pulmonary embolism and deep vein thrombosis: Radiation dose. J ThoracImag 16: 297-299, 2001.
6. Karande GY, Hedgire SS, Sanchez Y, Baliyan V, Mishra V, Ganguli S and Prabhakar AM: Advanced imaging in acute and chronic deep vein thrombosis. Cardiovasc Diagn Ther 6: 493-507, 2016.
7. Carpenter JP, Holland GA, Baum RA, Owen RS, Carpenter JT and Cope C: Magnetic resonance venography for the detection of deep venous thrombosis: Comparison with contrast venography and duplex Doppler ultrasonography. J Vasc Surg 18: 734-741, 1993.
8. Ozbudak O, Eroğullari I, Öğüş C, Çilli A, Türkay M and Özdemir T: Doppler ultrasonography versus venography in the detection of deep vein thrombosis in patients with pulmonary embolism. J Thromb Thrombolys 21: 159-162, 2006.
9. Labropoulos N, Borge M, Pierce K and Pappas PJ: Criteria for defining significant central vein stenosis with duplex ultrasound. J Vasc Surg 46: 101-107, 2007.
10. Huang SY, Kim CY, Miller MJ, Gupta RT, Lessne ML, Horvath JJ, Boll DT, Evans PD, Befera NT, Krishnan P, *et al*: Abdominopelvic and lower extremity deep venous thrombosis: Evaluation with contrast-enhanced MR venography with a blood-pool agent. AJR Am J Roentgenol 201: 208-214, 2013.
11. Gary T, Steidl K, Belaj K, Hafner F, Froehlich H, Deutschmann H, Pilger E and Brodmann M: Unusual deep vein thrombosis sites: Magnetic resonance venography in patients with negative compression ultrasound and symptomatic pulmonary embolism. Phlebology 29: 25-29, 2014.

12. Goodacre S, Sampson F, Thomas S, van Beek E and Sutton A: Systematic review and meta-analysis of the diagnostic accuracy of ultrasonography for deep vein thrombosis. BMC Med Imaging 5: 6, 2005.
13. Sampson FC, Goodacre SW, Thomas SM and van Beek EJ: The accuracy of MRI in diagnosis of suspected deep vein thrombosis: Systematic review and meta-analysis. Eur Radiol 17: 175-181, 2007.
14. Ruehm SG, Wiesner W and Debatin JF: Pelvic and lower extremity veins: Contrast-enhanced three-dimensional MR venography with a dedicated vascular coil-initial experience. Radiology 215: 421-427, 2000.
15. Tan M, Mol GC, van Rooden CJ, Klok FA, Westerbeek RE, Iglesias Del Sol A, van de Ree MA, de Roos A and Huisman MV: Magnetic resonance direct thrombus imaging differentiates acute recurrent ipsilateral deep vein thrombosis from residual thrombosis. Blood 124: 623-627, 2014.
16. Westerbeek RE, Van Rooden CJ, Tan M, Van Gils AP, Kok S, De Bats MJ, De Roos A and Huisman MV: Magnetic resonance direct thrombus imaging of the evolution of acute deep vein thrombosis of the leg. J ThrombHaemost 6: 1087-1092, 2008.
17. Rofsky NM, Lee VS, Laub G, Pollack MA, Krinsky GA, Thomasson D, Ambrosino MM and Weinreb JC: Abdominal MR imaging with a volumetric interpolated breath-hold examination. Radiology 212: 876-884, 1999.
18. Pfeil A, Betge S, Poehlmann G, Boettcher J, Drescher R, Malich A, Wolf G, Mentzel H and Hansch A: Magnetic resonance VIBE venography using the blood pool contrast agent gadofosveset trisodium-An interrater reliability study. Eur J Radiol 81: 547-552, 2012.
19. Hansch A, Betge S, Poehlmann G, Neumann S, Baltzer P, Pfeil A, Waginger M, Boettcher J, Kaiser WA, Wolf G and Mentzel HJ: Combined magnetic resonance imaging of deep venous thrombosis and pulmonary arteries after a single injection of a blood pool contrast agent. Eur Radiol 21: 318-325, 2011.
20. Michaely HJ, Attenberger UI, Dietrich O, Schmitt P, Nael K, Kramer H, Reiser MF, Schoenberg SO and Walz M: Feasibility of gadofosveset-enhanced steady-state magnetic resonance angiography of the peripheral vessels at 3 Tesla with Dixon fat saturation. Invest Radiol 43: 635-641, 2008.
21. Kluge A, Mueller C, Strunk J, Lange U and Bachmann G: Experience in 207 combined MRI examinations for acute pulmonary embolism and deep vein thrombosis. AJR Am J Roentgenol 186: 1686-1696, 2006.
22. Delfaut EM, Beltran J, Johnson G, Rousseau J, Marchandise X and Cotten A: Fat suppression in MR imaging: Techniques and pitfalls. Radiographics 19: 373-382, 1999.
23. Wells PS, Anderson DR, Rodger M, Forgie M, Kearon C, Dreyer J, Kovacs G, Mitchell M, Lewandowski B and Kovacs MJ: Evaluation of D-dimer in the diagnosis of suspected deep-vein thrombosis. N Engl J Med 349: 1227-1235, 2003.
24. Killewich LA, Bedford GR, Beach KW and Strandness DJ: Diagnosis of deep venous thrombosis. A prospective study comparing duplex scanning to contrast venography. Circulation 79: 810-814, 1989.
25. Landis JR and Koch GG: The measurement of observer agreement for categorical data. Biometrics 33: 159-174, 1977.
26. Bashir MR, Mody R, Neville A, Javan R, Seaman D, Kim CY, Gupta RT and Jaffe TA: Retrospective assessment of the utility of an iron-based agent for contrast-enhanced magnetic resonance venography in patients with endstage renal diseases. J Magn Reson Imaging 40: 113-118, 2014.
27. Ragan DK and Bankson JA: Two-point Dixon technique provides robust fat suppression for multi-mouse imaging. J Magn Reson Imaging 31: 510-514, 2010.
28. Ma J, Vu AT, Son JB, Choi H and Hazle JD: Fat-suppressed three-dimensional dual echo Dixon technique for contrast agent enhanced MRI. J Magn Reson Imaging 23: 36-41, 2006.
29. Reeder SB, McKenzie CA, Pineda AR, Yu H, Shimakawa A, Brau AC, Hargreaves BA, Gold GE and Brittain JH: Water-fat separation with IDEAL gradient-echo imaging. J Magn Reson Imaging 25: 644-652, 2007.
30. Fraser DG, Moody AR, Davidson IR, Martel AL and Morgan PS: Deep venous thrombosis: Diagnosis by using venous enhanced subtracted peak arterial MR venography versus conventional venography. Radiology 226: 812-820, 2003.
31. Elias A, Cadène A, Elias M, Puget J, Tricoire JL, Colin C, Lefebvre D, Rousseau H and Joffre F: Extended lower limb venous ultrasound for the diagnosis of proximal and distal vein thrombosis in asymptomatic patients after total hip replacement. Eur J Vasc Endovasc Surg 27: 438-444, 2004.
32. Forbes K and Stevenson AJ: The use of power Doppler ultrasound in the diagnosis of isolated deep venous thrombosis of the calf. Clin Radiol 53: 752-754, 1998.
33. Mattos MA, Melendres G, Sumner DS, Hood DB, Barkmeier LD, Hodgson KJ and Ramsey DE: Prevalence and distribution of calf vein thrombosis in patients with symptomatic deep venous thrombosis: A color-flow duplex study. J Vasc Surg 24: 738-744, 1996.
34. Mumoli N, Mastroiacovo D, Giorgi-Pierfranceschi M, Pesavento R, Mochi M, Cei M, Pomero F, Mazzone A, Vitale J, Ageno W and Dentali F: Ultrasound elastography is useful to distinguish acute and chronic deep vein thrombosis. J Thromb Haemost 16: 2482-2491, 2018.
35. Pressacco J, Papas K, Lambert J, Paul Finn J, Chauny JM, Desjardins A, Irislimane Y, Toporowicz K, Lanthier C, Samson P, *et al*: Magnetic resonance angiography imaging of pulmonary embolism using agents with blood pool properties as an alternative to computed tomography to avoid radiation exposure. Eur J Radiol 113: 165-173, 2019.
36. Fischer S, Grodzki DM, Domschke M, Albrecht M, Bodelle B, Eichler K, Hammerstingl R, Vogl TJ and Zangos S: Quiet MR sequences in clinical routine: Initial experience in abdominal imaging. Radiol Med 122: 194-203, 2017.
37. Baek HJ, Choo KS, Nam KJ, Hwang J, Lee JW, Kim JY and Jung HJ: Comparison of image qualities of 80 kVp and 120 kVp CT venography using Model-Based iterative reconstruction at same radiation dose. J Korean Soc Radiol 78: 235-241, 2018.