SPANDIDOS PUBLICATIONS

EXPERIMENTAL AND THERAPEUTIC MEDICINE 20: 591-598, 2020

Loganin attenuates intestinal injury in severely burned rats by regulating the toll-like receptor 4/NF-κB signaling pathway

HAILING WEN[1*], LIANG XING[2*], KUI SUN[1], CHANGSHUAN XIAO[1], XIANGXI MENG[1] and JINGZHE YANG[1]

[1]Department of Burns and Plastic Surgery, Affiliated Hospital of Chengde Medical University, Chengde, Hebei 067000; [2]Department of Burns and Plastic Surgery, The First Hospital of Hebei Medical University, Shijiazhuang, Hebei 050000, P.R. China

Received June 27, 2019; Accepted December 4, 2019

DOI: 10.3892/etm.2020.8725

Abstract. Severe burns may lead to intestinal inflammation and oxidative stress, resulting in intestinal barrier damage and gut dysfunction. Loganin, an iridoid glycoside compound, has been isolated from *Cornus officinalis* Sieb. et Zucc; however, its role in the treatment of burn injury is yet to be fully elucidated. Therefore, the present study examined the effect of loganin administration on burn-induced intestinal inflammation and oxidative stress after severe burns in male Sprague-Dawley rats. Histological injury was assessed by hematoxylin and eosin staining. Furthermore, cytokine expression in intestinal tissues was measured by ELISA and reverse transcription-quantitative PCR. Antioxidative activities were assessed by determining the levels of reactive oxygen species (ROS), superoxide dismutase (SOD), catalase (CAT), glutathione peroxidase (GSH-Px) and malondialdehyde (MDA). Apoptosis was detected by flow cytometry. Apoptosis-related proteins, toll-like receptor 4 (TLR4) protein and NF-κB translocation were examined by western blotting. Immunohistochemical staining was used to observe TLR4 and NF-κB p65 expression in intestinal tissues. The present study suggested that loganin administration significantly reduced burn injury-induced intestinal histological changes, tumor necrosis factor-α, interleukin (IL)-6 and IL-1β production and oxidative stress, evidenced by decreased ROS levels and MDA content ($P<0.05$). Furthermore, loganin increased SOD, CAT and GSH-Px levels and intestinal epithelial cell apoptosis. Loganin treatment also significantly inhibited activation of the TLR4/NF-κB signaling pathway in the intestine of severely burned rats ($P<0.05$). In conclusion, loganin reduced burns-induced intestinal inflammation and oxidative stress, potentially by regulating the TLR4/NF-κB signaling pathway.

Correspondence to: Dr Jingzhe Yang, Department of Burns and Plastic Surgery, Affiliated Hospital of Chengde Medical University, 36 Nanyingzi Street, Chengde, Hebei 067000, P.R. China
E-mail: jingzheyang_12@163.com

[*]Contributed equally

Abbreviations: CAT, catalase; GSH-Px, glutathione peroxidase; IL, interleukin; LPS, lipopolysaccharide; MDA, malondialdehyde; MODS, multiple organ dysfunction syndrome; MyD88, myeloid differentiation factor 88; ROS, reactive oxygen species; SOD, superoxide dismutase; TBSA, total body surface area; TLR4, toll-like receptor 4; TNF-α, tumor necrosis factor-α

Key words: burns, intestinal inflammation, loganin, oxidative stress, TLR4/NF-κB signaling pathway

Introduction

The intestinal epithelium functions as a natural barrier against the invasion of intestinal bacteria, toxins and other harmful substances, and serves and important role in the occurrence and development of multiple organ dysfunction syndrome (MODS) (1). Intestinal injury is the most common organ damage during the early stages of severe burn injuries (2). Severe burns can directly or indirectly result in the overgrowth of pathogenic bacteria in the intestines and the disruption of intestinal mechanical barriers, which in turn can trigger the translocation of intestinal bacteria or toxins, leading to systemic inflammatory response syndrome, sepsis and MODS (3,4). Meanwhile, apoptotic and necrotic intestinal epithelial cells enhance intestinal mucosal permeability, oxidative stress and the inflammatory response, thereby damaging the mechanical and immune barriers of the intestinal tissues (5,6). Therefore, intestinal protection plays an important role in the treatment of severe burns (7).

It has become increasingly clear that the inflammatory response and oxidative stress play crucial roles in the pathological process of burn injury (8). Toll-like receptor 4 (TLR4) is an innate immunity pattern recognition receptor, which initiates the immune response and oxidative damage by activating NF-κB, a crucial proinflammatory transcription factor (9,10). Therefore, it has been proposed that therapeutic targets that abolish intestinal inflammation and oxidative stress may function by mediating the TLR4 signaling pathway (11). For example, Zhou *et al* (12) reported that pharmacological administration of the mTOR inhibitor AZD8055 or the autophagy activator rapamycin significantly attenuated lipopolysaccharide (LPS)-induced intestinal inflammation and oxidative stress by inhibiting the TLR4-MyD88-mitogen-activated protein kinase and the NF-κB signaling pathways.

Loganin is an iridoid glycoside extracted from the crude herb *Cornus officinalis* Sieb. et Zucc. (13). A number of previous studies have reported that loganin displays anti-inflammatory, neuroprotective, antiatherosclerotic and antidiabetic activities in acute pancreatitis (14), neurodegenerative disorders (15), atherosclerosis (16) and diabetes (17), respectively. However, the role of loganin in the treatment of burn injury is not completely understood. The aim of the present study was to establish an experimental model of burn injury in rats to evaluate the effects of loganin on intestinal inflammation and oxidative stress. Therefore, the present study provided novel insights into the potential anti-inflammatory and antioxidant effects of loganin *in vivo*.

Materials and methods

Animals. Male Sprague-Dawley rats aged 4-6 weeks and weighing 150-200 g (n=18) were purchased from the Laboratory Animal Center of The Affiliated Hospital of Chengde Medical University. Before experimentation, all rats were allowed to acclimatize for one week under specific pathogen-free conditions. The rats were maintained at 25˚C with the humidity of 55% and 12-h light/dark cycles and were fed a standard chow diet with free access to food and water. All animals were handled according to the Animal Welfare Guidelines issued by The Affiliated Hospital of Chengde Medical University for the Care and Use of Laboratory Animals. The experimental procedures were approved by the Animal Care and Use Committee of The Affiliated Hospital of Chengde Medical University.

Burn procedure. Burn injuries were established by scalding the skin of the rats' back using boiling water as described in previously published studies (5). Briefly, the rats were anesthetized by the intraperitoneal injection of 30 mg/kg sodium pentobarbital. The dorsal area was then dehaired and completely immersed in 100˚C water for 15 sec to create a 20% total body surface area (TBSA) full-thickness burn.

Experimental design. A total of 18 rats were randomly divided into three groups as follows: i) Sham-operated rats, which served as the control group (n=6); ii) rats subjected to burn injury, which served as the burn group (n=6); and iii) rats intragastrically administered 50 mg/kg loganin (Sigma-Aldrich; Merck KGaA; 5 mg loganin dissolved in 1 ml normal saline; extrasynthese) daily for 7 days before burn injury, which served as the burn + loganin group (n=6). Additionally, untreated rats were used as blank normal controls (n=6). All rats were anesthetized by the intraperitoneal injection of 30 mg/kg sodium pentobarbital, placed in room temperature water for 15 sec and administered an equal volume of normal saline to the loganin dose. At 24 h after burn injury, all rats were euthanized by the intraperitoneal injection of 120 mg/kg sodium pentobarbital, as previously described (18). Following euthanasia, intestinal tissues were surgically resected and immediately immersed in 10% formalin overnight at 4˚C.

Histopathological examination. Intestines were fixed in 10% formalin overnight at 4˚C and were subsequently embedded in paraffin. After deparaffinization with xylene and rehydration using a graded ethanol series, the 5-μm thick sections were stained for 5 min with hematoxylin, rinsed, and stained for 30 sec using 0.5% eosin at room temperature for histological assessment of intestinal damage. The images were observed by a pathologist from the Affiliated Hospital of Chengde Medical University, and five randomly selected areas were examined using a light microscope (magnification, x400; Leica DM1000, Leica Microsystems, Inc.).

ELISA. The intestinal levels of tumor necrosis factor (TNF)-α (cat. no. 550610), interleukin (IL)-6 (cat. no. 550799) and IL-1β (cat. no. 557966) were determined by commercial ELISA kits (BD Biosciences), according to the manufacturer's instructions. Expression levels were determined at a wavelength of 450 nm. Each sample was assayed in duplicate.

Reverse transcription-quantitative PCR (RT-qPCR). The RT-qPCR experiments were independently carried out three times, with three repeats each. Total RNA was extracted from intestinal tissues using TRIzol® reagent (Thermo Fisher Scientific, Inc.), according to the manufacturer's instructions. RNA was then reverse transcribed to cDNA using the PrimeScript™ 1st Strand cDNA Synthesis kit (Takara Biotechnology Co., Ltd.) according to manufacturer's protocol. qPCR was subsequently performed using the Primer-ScriptTM One Step RT-PCR kit (Takara Biotechnology Co., Ltd.) on a 7900 HT Fast Real-Time PCR system (Applied Biosystems; Thermo Fisher Scientific, Inc.). The thermocycling conditions were as follows: pre-denaturation at 95˚C for 30 sec, followed by 95˚C for 5 sec, annealing at 60˚C for 20 sec, extension at 72˚C for 30 sec for a total of 40 cycles. The primer sequences used were as follows: TNF-α forward, 5'-GCCCACGTCGTAGCAA-3' and reverse, 5'-GTCTTTGAGATCCATGCCAT-3'; IL-6 forward, 5'-AGAAGACCAGAGCAGATTTT-3' and reverse, 5'-GAGAAAGAGTTGTGCAATG-3'; IL-1β forward, 5'-GAGCTGAAAGCTCTCCACCT-3' and reverse, 5'-TTCCATCTTCTTCTTTGGGT-3'; and β-actin forward, 5'-GAAGATCAAGATCATTGCTCCT-3' and reverse, 5'-TACTCCTGCTTGCTGATCCA-3'. The relative expression levels of TNF-α, IL-6 and IL-1β were analyzed by the $2^{-\Delta\Delta Cq}$ method (19) and normalized to β-actin.

Measurement of antioxidative activities. The experiments were independently carried out three times, with three repeats each. Intestinal tissues were centrifuged at 1,500 x g for 15 min at 4˚C and homogenized in normal saline. The supernatant was transferred into new tubes for evaluation of reactive oxygen species (ROS) accumulation and superoxide dismutase (SOD), catalase (CAT), glutathione peroxidase (GSH-Px) and malondialdehyde (MDA) activities, according to the manufacturer's protocol. Intracellular ROS accumulation (Reactive oxygen species Assay kit; cat. no. E004-1-1; Nanjing Jiancheng Bioengineering Institute) was measured using a spectrofluorophotometer at excitation/emission wavelengths of 488/525 nm. SOD level was detected by a water-soluble tetrazolium salt method (Superoxide Dismutase assay kit; cat. no. A001-3-2; Nanjing Jiancheng Bioengineering Institute), and the sample absorbance was analyzed using a microplate reader at a wavelength of 450 nm. The levels of CAT (Catalase assay kit; cat. no. A007-1-1; Nanjing Jiancheng Bioengineering Institute),

GSH-Px (Glutathione Peroxidase assay kit; cat. no. A005-1-2; Nanjing Jiancheng Bioengineering Institute) and MDA (Malondialdehyde assay kit; cat. no. A003-1-2; Nanjing Jiancheng Bioengineering Institute) were determined colorimetrically using a spectrophotometer at a wavelength of 405, 412 and 532 nm, respectively.

Apoptosis detection. The experiments were independently carried out three times, with three repeats each. Following trypsinization for 2 h using 0.05% trypsin at 4˚C, resected segments of intestines were washed with PBS to collect the intestinal epithelial cells. Cell apoptosis was assessed using the Annexin V-FITC/PI detection kit (Sigma-Aldrich; Merck KGaA), according to the manufacturer's instructions. Briefly, the intestinal epithelial cells ($1x10^6$ cells) were resuspended in the binding buffer and stained with the Annexin V/FITC for 15 min and PI solution for 5 min at 4˚C. The early and late apoptosis was analyzed using a flow cytometer and estimated using the ModFit software (version 3.0; BD Biosciences).

Western blotting. The frozen intestines were lysed in RIPA buffer (Santa Cruz Biotechnology, Inc.). The lysates were centrifuged at 12,000 x g at 4˚C for 20 min. The protein content in the supernatant was measured by the bicinchoninic acid protein assay (Pierce; Thermo Fisher Scientific, Inc.). Protein samples (30 μg) were resolved in 10% SDS-PAGE gels and transferred onto PVDF membranes in 5% non-fat dry milk in tris-buffered saline containing 0.1% Tween 20 for 2 h at room temperature. Immunoblotting was performed on the membranes using the following primary antibodies: Anti-Bcl-2 (cat. no. 3498; 1:1,000; Cell Signaling Technology, Inc.), anti-Bax (cat. no. 5023; 1:1,000; Cell Signaling Technology, Inc.), anti-cleaved caspase-3 (cat. no. 9661; 1:1,000; Cell Signaling Technology, Inc.), anti-TLR4 (cat. no. 14358; 1:1,000; Cell Signaling Technology, Inc.), anti-phosphorylated (p)-inhibitor of κB-α (IκB-α; cat. no. 2859; 1:1,000; Cell Signaling Technology, Inc.), anti-IκB-α (cat. no. 4812; 1:1,000; Cell Signaling Technology, Inc.), anti-p-NF-κB p65 (cat. no. 8214; 1:1,000; Cell Signaling Technology, Inc.) and anti-NF-κB p65 (cat. no. 8242; 1:1,000; Cell Signaling Technology, Inc.) overnight at 4˚C. Subsequently, membranes were incubated with horseradish peroxidase-conjugated secondary antibodies (cat. no. 7076; 1:1,000; Cell Signaling Technology, Inc.) at room temperature for 2 h. Immunoreactive bands were visualized using the ECL western blot detection system (Abcam). The same membranes were probed with GAPDH (cat. no. 5176; 1:1,000; Cell Signaling Technology, Inc.) as a loading control. Quantitative results of Western blotting were obtained by densitometry using ImageJ software (version 1.46; National Institutes of Health). The experiments were independently carried out three times, with three repeats each.

Immunohistochemical staining. Formalin-fixed, paraffin-embedded intestines were cut into 5-μm thick slices and permeabilized in 0.3% Triton X-100 for 20 min at 4˚C. The sections were incubated overnight at 4˚C with primary antibodies against TLR4 (cat. no. ab22048; 1:100; Abcam) and NF-κB p65 (cat. no. ab207297; 1:2,000; Abcam). Subsequently, the sections were incubated with horseradish peroxidase-conjugated secondary antibodies (cat. no. 3900; 1:1,000; Cell Signaling Technology, Inc.) for 30 min at 37˚C. After sections were washed three times with PBS, slides were stained with 3,3'-diaminobenzidine for 5 min at 37˚C, counter-stained with hematoxylin for 2 min at 37˚C, and imaged under a light microscope (x400 magnification).

Statistical analysis. All data are expressed as mean ± standard deviation. SPSS software (version 19.0; IBM Corp.) was used for statistical analysis. The results were analyzed by one-way ANOVA with Student-Newman-Keuls or Tukey's post hoc test. $P<0.05$ was considered to indicate a statistically significant difference.

Results

Loganin ameliorates intestinal histopathology caused by severe burn in rats. The normal group displayed normal histopathology (Fig. 1). The control group also displayed no destructive changes in the hematoxylin and eosin-stained intestinal tissues (Fig. 1). At 24 h after 20% TBSA burn injury, rats displayed intestinal damage characterized by intestinal edema, the loss of villi integrity and inflammatory cell infiltration (Fig. 1). By contrast, intragastric injection of loganin to rats with severe burns resulted in less histological inflammation compared with the burn group (Fig. 1).

Loganin inhibits TNF-α, IL-6 and IL-1β production induced by burn injury. Inflammation plays a critical role in the pathogenesis of burn injury (20). To determine the effect of loganin on the inflammatory response induced by severe burns in rats, the expression levels of the proinflammatory cytokines TNF-α, IL-6 and IL-1β in the intestinal tissues were examined by ELISA and RT-qPCR. The protein levels of TNF-α, IL-6 and IL-1β in the intestinal tissues from rats with severe burns were significantly elevated compared with those from the control rats (Fig. 2A; $P<0.05$). However, compared with the burned rats, loganin treatment significantly decreased the intestinal expression of TNF-α, IL-6 and IL-1β at the protein level ($P<0.05$). Furthermore, the administration of loganin significantly reduced burns-induced upregulation of TNF-α, IL-6 and IL-1β mRNA levels compared with the burned rats (Fig. 2B; $P<0.05$).

Loganin ameliorates oxidative stress in intestinal tissues in the rat burn model. Subsequently, changes in oxidative stress marker activity in the intestinal tissues were measured. The results suggested that loganin treatment suppressed the burn-induced production of ROS (Fig. 3) and oxidative damage of the intestines, as indicated by increased SOD, CAT and GSH-Px levels, as well as reduced MDA level, compared with the burn group (Fig. 3).

Loganin reduces intestinal epithelial cell apoptosis in severely burned rats. Apoptosis of intestinal epithelial cells was then assessed by Annexin V-FITC/PI double staining and flow cytometry. The percentage of apoptotic intestinal epithelial cells was significantly increased in the burn group compared with the control group, while loganin treatment reduced the level of burns-induced apoptosis of intestinal epithelial cells compared with the burn group (Fig. 4A; $P<0.05$). To

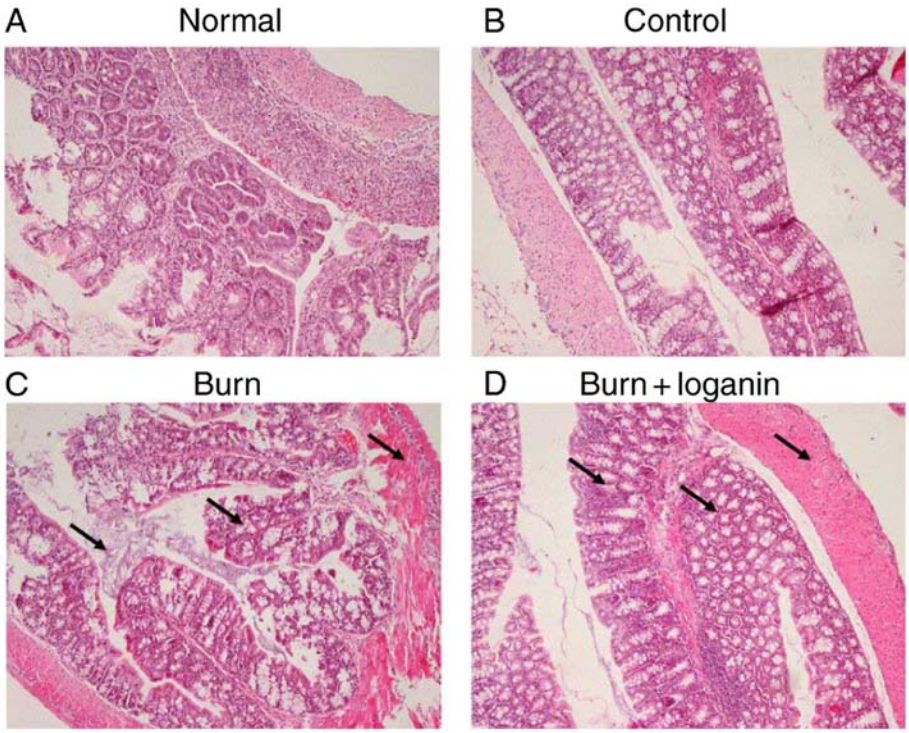

Figure 1. Effect of loganin on burn-induced intestinal histological changes. Representative micrographs of hematoxylin and eosin-stained intestinal sections (magnification, x400) in the (A) normal, (B) control, (C) burn and (D) burn + loganin groups (n=6 per group). The black arrows indicate the features that differed between the burn rats and burn + loganin rats. Burned rats displayed intestinal damage characterized by intestinal edema, the loss of villi integrity and inflammatory cell infiltration. By contrast, intragastric injection of loganin to rats with severe burns resulted in less histological inflammation compared with the burn group.

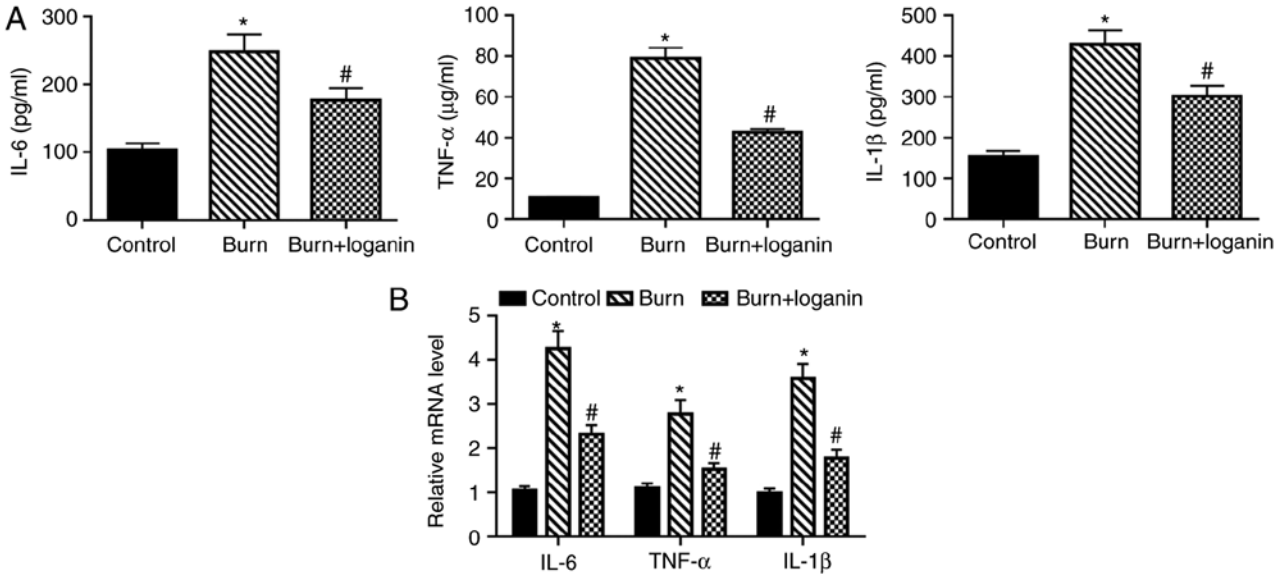

Figure 2. Effect of loganin on the burn-induced intestinal inflammatory response. The (A) protein and (B) mRNA expression levels of IL-6, TNF-α and IL-1β in the intestinal tissues of the control, burn and burn + loganin groups (n=6 per group). *P<0.05 vs. the control group; #P<0.05 vs. the burn group. IL, interleukin; TNF, tumor necrosis factor.

further investigate the antiapoptotic effects of loganin, the effects of loganin on the expression of the apoptosis-related proteins Bax, Bcl-2 and cleaved-caspase-3 were analyzed by western blotting. Loganin significantly reduced the burn injury-induced upregulation of Bax and cleaved-caspase-3 and the downregulation of Bcl-2, compared with the burn group (Fig. 4B; P<0.05).

Loganin suppresses severe burn-induced TLR4/NF-κB signaling pathway activation in intestinal tissues. The TLR/NF-κB signaling pathway plays an important role in inflammation and oxidative stress (9,10). Hence, the present study investigated whether loganin could inhibit burns-induced TLR4/NF-κB signaling pathway activation. Immunohistochemical analysis suggested that loganin limited

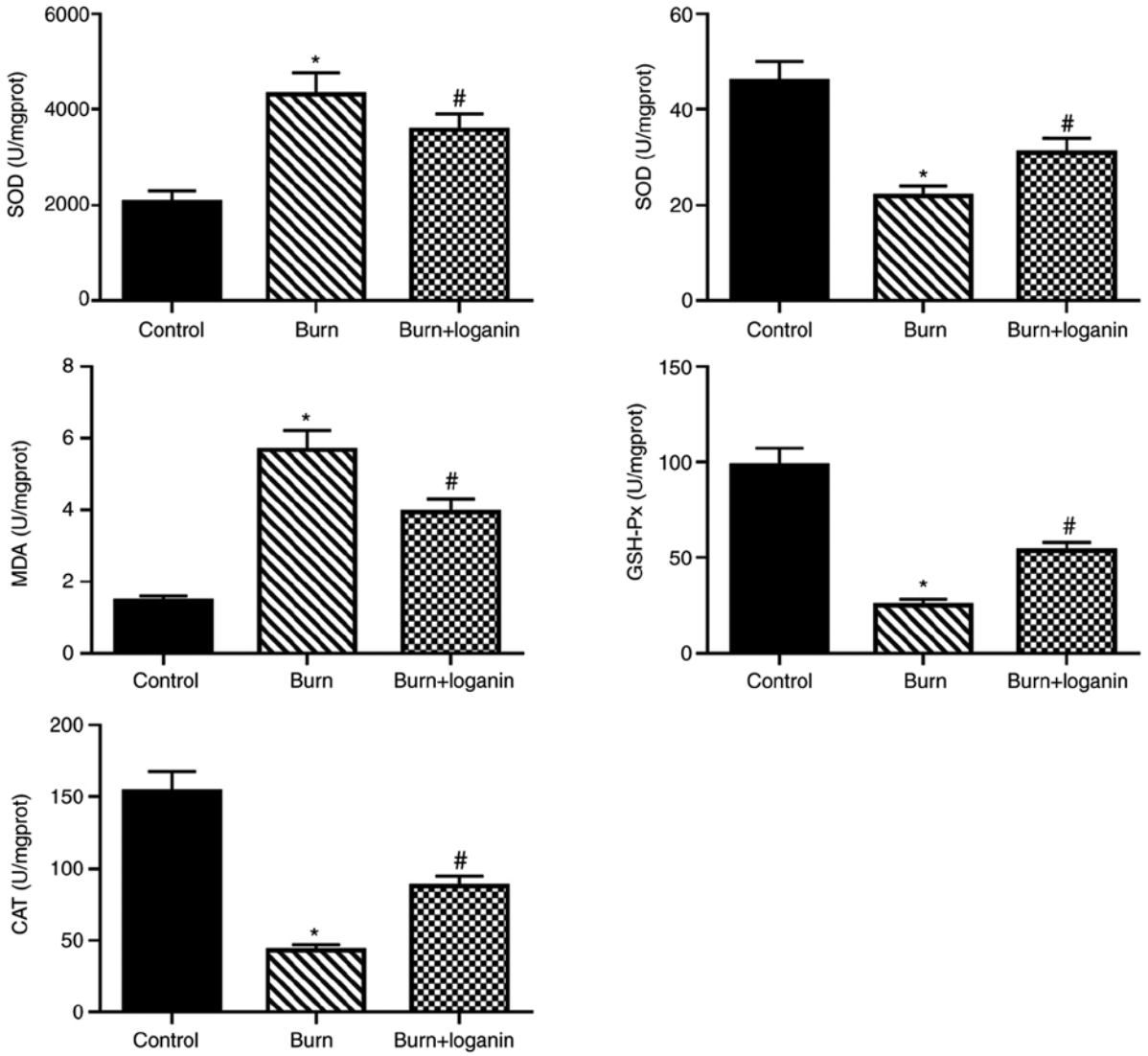

Figure 3. Effect of loganin on burn-induced intestinal oxidative stress. The levels of ROS, SOD, MDA, GSH-Px and CAT in intestinal tissues of the control, burn and burn + loganin groups (n=6 per group). *P<0.05 vs. the control group; #P<0.05 vs. the burn group. ROS, reactive oxygen species; SOD, superoxide dismutase; MDA, malondialdehyde; GSH-Px, glutathione peroxidase; CAT, catalase.

the expression of TLR4 and NF-κB p65 in intestinal tissues of burned rats (Fig. 5A). Furthermore, the burn group displayed significant TLR4 upregulation and induction of IκBα and NF-κB p65 phosphorylation in intestinal tissues compared with the control group (P<0.05). By contrast, compared with the burn group, administration of loganin downregulated TLR4 protein levels, impaired IκBα degradation and reduced the phosphorylation of NF-κB p65 (Fig. 5B; P<0.05).

Discussion

The present study demonstrated that the administration of loganin inhibited severe burn-induced intestinal pathology, intestinal inflammation, oxidative stress and intestinal epithelial cell apoptosis by targeting the TLR4/NF-κB signaling pathway.

Thermal burn injury is a leading cause of mortality and disability worldwide (21,22). Previous studies support the existence of intestinal injury following severe burn in rats (23,24). Histopathological examination in the present study further suggested that the intestinal tissues were noticeably damaged at 24 h after 20% TBSA full-thickness burn wound induction. Severe burns result in intestinal inflammation and oxidative stress, eventually leading to intestinal barrier damage and gut dysfunction (8,25,26). The present study suggested that damaged intestines of Sprague-Dawley rats following severe burn injuries displayed intracellular ROS overproduction, subsequent excessive consumption of SOD, CAT, GSH-Px and increased lipid peroxidation compared with control rats. Oxidative stress can provoke the production of inflammatory cytokines, which contribute to chronic and acute inflammatory reactions (27). The present study observed a significant increase in the mRNA and protein levels of the proinflammatory cytokines TNF-α, IL-6 and IL-1β in the intestinal tissues of rats with burns (P<0.05). Growing evidence suggests that gut epithelial apoptosis is implicated in changes in mucosal integrity and impaired intestinal barrier function after severe burns, provoking further oxidative stress and inflammation (28,29). The present study demonstrated that the percentage of apoptotic cells in the intestinal tissues significantly increased 24 h

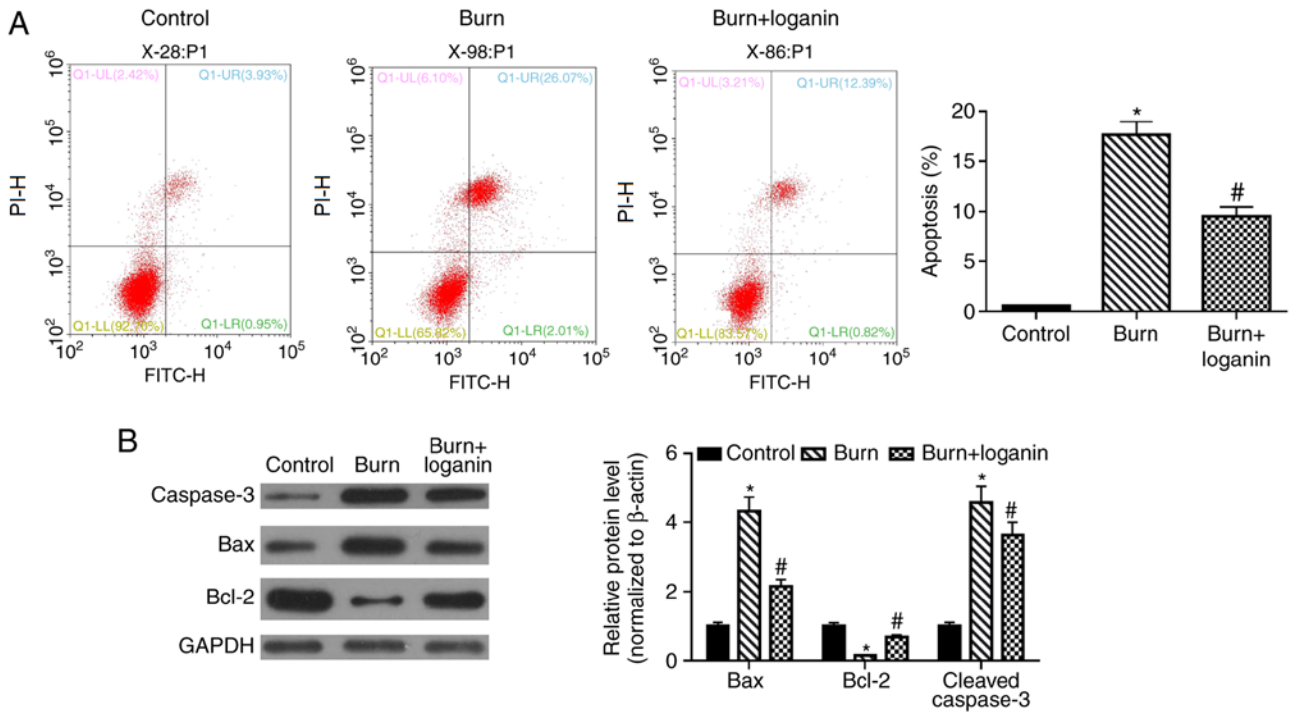

Figure 4. Effect of loganin on burn-induced intestinal epithelial cell apoptosis. (A) Intestinal epithelial cell apoptosis was detected by flow cytometry. (B) The protein expression of Bax, Bcl-2 and cleaved-caspase-3 was determined by western blotting (n=6 per group). *P<0.05 vs. the control group; #P<0.05 vs. the burn group. PE, phycoerythrin.

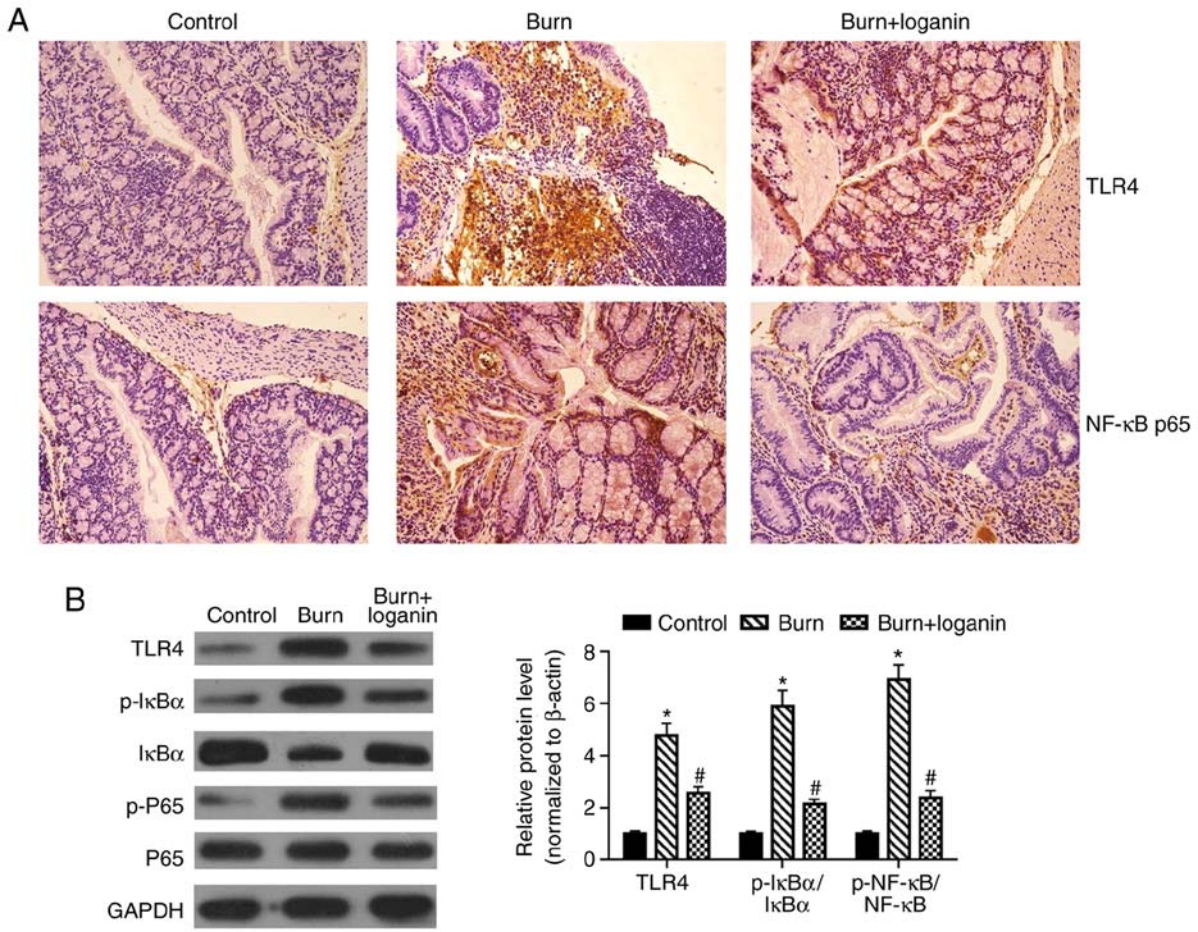

Figure 5. Effect of loganin on the burn-induced activation of the TLR4/NF-κB signaling pathway. (A) The expression of TLR4 and NF-κB p65 was evaluated by immunohistochemical staining (x400 magnification). (B) The protein levels of TLR4, p-IκBα, IκBα, p-NF-κB p65 and NF-κB p65 were determined by western blot analysis (n=6 per group). *P<0.05 vs. the control group; #P<0.05 vs. the burn group. TLR, toll-like receptor; p, phosphorylated; IκBα, inhibitor of κBα.

after the burn injury (P<0.05). The TLR4/NF-κB signaling pathway is involved in the regulation of the inflammatory response and cell apoptosis (9,10). Wang *et al* (8) suggested that isoquercetin mitigated myocardial inflammation and apoptosis by suppressing the TLR4/NF-κB signaling pathway. Furthermore, Minden-Birkenmaier *et al* (26) indicated that harmine attenuated LPS-induced acute kidney injury by reducing oxidative stress and inflammatory responses via inhibition of the TLR4-NF-κB signaling pathway. Similarly, the present study suggested that severe burn injury induced NF-κB signaling pathway activation and TLR4 upregulation.

It is generally accepted that loganin is a bioactive component with anti-inflammatory and antioxidant effects (13,16). For example, Fei *et al* (27) illustrated that loganin could attenuate neuroinflammation in BV-2 microglia cells by inhibiting the activation of the TLR4 signaling pathway. Furthermore, Carter *et al* (28) suggested that loganin exerted a neuroprotective effect by decreasing neuronal apoptosis and oxidative stress. The present study used a rat burn injury model to evaluate the role of loganin in intestinal protection following burn injury. The results revealed that the intragastric injection of loganin (50 mg/kg) after severe burn injury ameliorated intestinal pathological changes. Following the intragastric administration of loganin in the burn + loganin group, the production of ROS, MDA, TNF-α, IL-6 and IL-1β were significantly reduced, while SOD, CAT and GSH-Px levels improved in intestinal tissue samples, compared with the untreated burn group (P<0.05). Loganin has been well documented to antagonize the oxidative stress-induced apoptosis of various cell types, including renal mesangial cells (13), neurons (30) and hepatocytes (31) *in vivo*. The present study demonstrated that loganin treatment significantly decreased the percentage of apoptotic intestinal epithelial cells following severe burn injury (P<0.05). This suggested that loganin protected intestinal epithelial cells from burns-induced apoptosis. Additionally, loganin inhibited the burn injury-induced upregulation of cleaved caspase-3 and Bax expression, and downregulation of Bcl-2 expression. Furthermore, treatment with loganin significantly attenuated the burn injury-induced TLR4 activation and phosphorylation of NF-κB p65 (P<0.05). These results suggested that the protective effects of loganin against burns-induced apoptosis in the intestinal epithelium may be due to mediation of the TLR4/NF-κB signaling pathway.

Despite the lack of clinical data and *in vitro* experiments, the present study suggested that the anti-inflammatory and antioxidant effects of loganin in severe burn injury may be mediated by targeting the TLR4/NF-κB signaling pathway. Further investigations are required to verify the therapeutic action of loganin in severe burn injury.

Acknowledgements

Not applicable.

Funding

No funding was received.

Availability of data and materials

The datasets used and/or analyzed during the present study are available from the corresponding author on reasonable request.

Authors' contributions

HW and LX designed the study. KS, CX and XM conducted the experiments and analyzed the data. JY conducted the experiments and wrote the manuscript.

Ethics approval and consent to participate

This study was approved by the Animal Care and Use Committee of The Affiliated Hospital of Chengde Medical University. The patients provided consent to participate.

Patient consent for publication

Not applicable.

Competing interests

The authors declare that they have no competing interests.

References

1. Fay KT, Ford ML and Coopersmith CM: The intestinal microenvironment in sepsis. Biochim Biophys Acta Mol Basis Dis 1863: 2574-2583, 2017.
2. He W, Wang Y, Wang P and Wang F: Intestinal barrier dysfunction in severe burn injury. Burns Trauma 7: 24, 2019.
3. Qin Y, Hamilton JL, Bird MD, Chen MM, Ramirez L, Zahs A, Kovacs EJ and Makowski L: Adipose inflammation and macrophage infiltration after binge ethanol and burn injury. Alcohol Clin Exp Res 38: 204-213, 2013.
4. Earley ZM, Akhtar S, Green SJ, Naqib A, Khan O, Cannon AR, Hammer AM, Morris NL, Li X, Eberhardt JM, *et al*: Burn injury alters the intestinal microbiome and increases gut permeability and bacterial translocation. PLoS One 10: e0129996, 2015.
5. Gong ZY, Yuan ZQ, Dong ZW and Peng YZ: Glutamine with probiotics attenuates intestinal inflammation and oxidative stress in a rat burn injury model through altered iNOS gene aberrant methylation. Am J Transl Res 9: 2535-2547, 2017.
6. Haines RJ, Wang CY, Yang CGY, Eitnier RA, Wang F and Wu MH: Targeting palmitoyl acyltransferase ZDHHC21 improves gut epithelial barrier dysfunction resulting from burn-induced systemic inflammation. Am J Physiol Gastrointest Liver Physiol 313: G549-G557, 2017.
7. Li JY, Sheng ZY, Lu Y, Yu Y and Zhou BT: Severe trauma induced intestinal barrier function injury and protection. World Chin J Digestol 8: 1093-1096, 2000.
8. Wang Z, Chen R, Zhu Z, Zhang X and Wang S: Effects of insulin combined with ethyl pyruvate on inflammatory response and oxidative stress in multiple-organ dysfunction syndrome rats with severe burns. Am J Emerg Med 34: 2154-2158, 2016.
9. Wang L, Liu XH, Chen H, Chen ZY, Weng XD, Qiu T and Liu L: Picroside II protects rat kidney against ischemia/reperfusion-induced oxidative stress and inflammation by the TLR4/NF-κB pathway. Exp Ther Med 9: 1253-1258, 2015.
10. Zhang L, Sun S, Li W, Zhang W, Wang X and Yang SY: Effect of Scutellarin inhibits collagen-induced arthritis through TLR4/NF-κB-mediated inflammation. Mol Med Rep 16: 5555-5560, 2017.
11. Latorre E, Mendoza C, Layunta E, Alcalde AI and Mesonero JE: TLR2, TLR3, and TLR4 activation specifically alters the oxidative status of intestinal epithelial cells. Cell Stress Chaperones 19: 289-293, 2014.

12. Zhou M, Xu W, Wang J, Yan J, Shi Y, Zhang C, Ge W, Wu J, Du P and Chen Y: Boosting mTOR-dependent autophagy via upstream TLR4-MyD88-MAPK signalling and downstream NF-κB pathway quenches intestinal inflammation and oxidative stress injury. EBioMedicine 35: 345-360, 2018.
13. Xu H, Shen J, Liu H, Shi Y, Li L and Wei M: Morroniside and loganin extracted from Cornus officinalis have protective effects on rat mesangial cell proliferation exposed to advanced glycation end products by preventing oxidative stress. Can J Physiol Pharmacol 84: 1267-1273, 2006.
14. Kim MJ, Bae GS, Jo IJ, Choi SB, Kim DG, Shin JY, Lee SK, Kim MJ, Shin S, Song HJ and Park SJ: Loganin protects against pancreatitis by inhibiting NF-κB activation. Eur J Pharmacol 765: 541-550, 2015.
15. Tseng YT, Chen CS, Jong YJ, Chang FR and Lo YC: Loganin possesses neuroprotective properties, restores SMN protein and activates protein synthesis positive regulator Akt/mTOR in experimental models of spinal muscular atrophy. Pharmacol Res 111: 58-75, 2016.
16. Li Y, Li Z, Shi L, Zhao C, Shen B, Tian Y and Feng H: Loganin inhibits the inflammatory response in mouse 3T3L1 adipocytes and mouse model. Int Immunopharmacol 36: 173-179, 2016.
17. Rajabi M, Mohaddes G, Farajdokht F, Nayebi Rad S, Mesgari M and Babri S: Impact of loganin on pro-inflammatory cytokines and depression- and anxiety-like behaviors in male diabetic rats. Physiol Int 105: 199-209, 2018.
18. Zhou Q, Price DD, Caudle RM and Verne GN: Visceral and somatic hypersensitivity in a subset of rats following TNBS-induced colitis. Pain 134: 9-15, 2008.
19. Livak KJ and Schmittgen TD: Analysis of relative gene expression data using real-time quantitative PCR and the 2(-Delta Delta C(T)) method. Methods 25: 402-408, 2001.
20. Nakazawa H, Chang K, Shinozaki S, Yasukawa T, Ishimaru K, Yasuhara S, Yu YM, Martyn JA, Tompkins RG, Shimokado K and Kaneki M: iNOS as a driver of inflammation and apoptosis in mouse skeletal muscle after burn injury: Possible involvement of Sirt1 S-Nitrosylation-mediated acetylation of p65 NF-κB and p53. PLoS One 12: e0170391, 2017.
21. Möller H, Falster K, Ivers R, Clapham K, Harvey L and Jorm L: High rates of hospitalised burn injury in Indigenous children living in remote areas: A population data linkage study. Aust N Z J Public Health 42: 108-109, 2018.
22. Botchey IM Jr, Hung YW, Bachani AM, Paruk F, Mehmood A, Saidi H and Hyder AA: Epidemiology and outcomes of injuries in Kenya: A multisite surveillance study. Surgery 162 (Suppl): S45-S53, 2017.
23. Yuan ZQ, Peng YZ, Li XL, Huang YS and Yang ZC: Induction of heat shock protein 70 by sodium arsenite attenuates burn-induced intestinal injury in severe burned rats. Burns 34: 247-253, 2008.
24. Sun YX, Han LN, Gao Z, Wu XS, Zhou M, Wang F, Peszel A and Chen XL: 200 mM hypertonic saline resuscitation attenuates intestinal injury and inhibits p38 signaling in rats after severe burn trauma. Burns 43: 1693-1701, 2017.
25. O'Dea KP, Porter JR, Tirlapur N, Katbeh U, Singh S, Handy JM and Takata M: Circulating microvesicles are elevated acutely following major burns injury and associated with clinical severity. PLoS One 11: e0167801, 2016.
26. Minden-Birkenmaier BA, Meadows MB, Cherukuri K, Smeltzer MP, Smith RA, Radic MZ and Bowlin GL: The effect of manuka honey on dHL-60 cytokine, chemokine, and matrix-degrading enzyme release under inflammatory conditions. Med One 4: e190005, 2019.
27. Fei Y, Sun L, Yuan C, Jiang M, Lou Q and Xu Y: CFTR ameliorates high glucose-induced oxidative stress and inflammation by mediating the NF-κB and MAPK signaling pathways in endothelial cells. Int J Mol Med 41: 3501-3508, 2018.
28. Carter SR, Zahs A, Palmer JL, Wang L, Ramirez L, Gamelli RL and Kovacs EJ: Intestinal barrier disruption as a cause of mortality in combined radiation and burn injury. Shock 40: 281-289, 2013.
29. Li YM, Wang HB, Zheng JG, Bai XD, Zhao ZK, Li JY and Hu S: Dimethyl sulfoxide inhibits zymosan-induced intestinal inflammation and barrier dysfunction. World J Gastroenterol 21: 10853-10865, 2015.
30. Kwon SH, Kim JA, Hong SI, Jung YH, Kim HC, Lee SY and Jang CG: Loganin protects against hydrogen peroxide-induced apoptosis by inhibiting phosphorylation of JNK, p38, and ERK 1/2 MAPKs in SH-SY5Y cells. Neurochem Int 58: 533-541, 2011.
31. Park CH, Tanaka T, Kim JH, Cho EJ, Park JC, Shibahara N and Yokozawa T: Hepato-protective effects of loganin, iridoid glycoside from Corni Fructus, against hyperglycemia-activated signaling pathway in liver of type 2 diabetic db/db mice. Toxicology 290: 14-21, 2011.