SPANDIDOS PUBLICATIONS

EXPERIMENTAL AND THERAPEUTIC MEDICINE 20: 2721-2729, 2020

One-year outcomes of 27G core-pars plana vitrectomy of idiopathic epiretinal membrane

XIN LIAO, KHUSBU KEYAL, HUI LI and FANG WANG

Department of Ophthalmology, Shanghai 10th People's Hospital affiliated to Tongji University, Shanghai 200072, P.R. China

Received August 1, 2019; Accepted March 10, 2020

DOI: 10.3892/etm.2020.8995

Abstract. The present study aimed to assess the feasibility and safety of 27G core-pars plana vitrectomy (PPV) for idiopathic epiretinal membrane (IERM). A retrospective analysis was performed on 38 eyes from 38 patients with IERM with a mean age of 62.73±5.61 years. 27G core-PPV was combined with IERM and internal limiting membrane (ILM) peeling. Pre-operative and post-operative best-corrected visual acuity (BCVA) and lens density were measured. Optical coherence tomography (OCT) and OCT angiography were performed to determine the patients' macular area. Ultrasound biomicroscopy and B-mode ultrasound were subsequently performed to observe any complications and the follow-up period ranged from 1 week to 12 months post-operatively. A total of 36 patients achieved visual improvement of ≥2 Snellen lines, of which 33 patients exhibited improvements within 1 week and the lens density remained unchanged. The mean central macular thickness significantly decreased at 12 months post-operatively ($P \leq 0.05$); however, it was not observed to be correlated with BCVA ($r=0.41$; $P>0.05$). The foveal avascular zone of the affected eye was significantly smaller than that of the healthy fellow eye ($P \leq 0.05$) and negatively correlated with post-operative BCVA ($r=-0.72$; $P \leq 0.05$). Superficial retinal capillary density and deep retinal capillary density decreased post-operatively (both $P \leq 0.05$) and no complications were observed. Taken together, the results of the present study indicate that application of 27G core-PPV with ILM peeling is minimally invasive for IERM and facilitates rapid post-operative BCVA recovery.

Correspondence to: Professor Fang Wang, Department of Ophthalmology, Shanghai 10th People's Hospital affiliated to Tongji University, 301 Middle Yan Chang Road, Shanghai 200072, P.R. China
E-mail: 18917683335@163.com

Key words: 27G core-pars plana vitrectomy, idiopathic epiretinal membrane, best corrected visual acuity, lens density, optical coherence tomography angiography

Introduction

Idiopathic epiretinal membrane (IERM) may be classified into two types based on its composition of pathology, complex (type 1) and simple (type 2) (1,2). The symptoms experienced by patients with IERM are determined by the extent of the impact that the ERM has on macular ultrastructure and primarily include visual impairment and metamorphopsia. IERM may easily be diagnosed through fundus examination and optical coherence tomography (OCT).

Pars plana vitrectomy (PPV) remains the predominant treatment for patients with IERM (3). In all, the surgical procedures involved are not considered to be complex; however, the most common post-operative complication of IERM treatment is cataracts, which leads to further visual impairment in those patients (4). The incidence rate of post-operative cataracts in patients with IERM reaches 80%. Cataracts generally occur at 8-12 months post-surgery, potentially due to exposure of the lens to oxidative stress damage, phototoxicity and intra-operative perfusion following vitrectomy (5).

To avoid post-operative cataracts in IERM-PPV, certain retinal surgeons attempted the application of non-pars plana vitrectomy (N-PPV) with IERM peeling ~10 years ago. However, during follow-up, it was revealed that, compared to conventional PPV, the recurrence of IERM in N-PPV-treated cases was 7.5-38%, and thus, this technique was not widely promoted (6).

Oshima *et al* (7) were the first to introduce 27G vitrectomy in 2010. In recent years, 27G PPV, which involves a smaller incision compared with 23G and 25G PPV, has been applied for the treatment of macular diseases, vitreous haemorrhage and retinal detachment. Previous studies have demonstrated that 27G PPV is more efficient than 23G PPV and has a lower incidence of post-operative incision-associated complications, including subconjunctival air bubbles and hypotony (7). The aim of IERM surgery is to loosen and remove the epiretinal proliferative membrane, which involves the vitreous and macula, and no other procedures are required, including laser and intraocular tamponade. Thus, application of 27G core-PPV may be effective, combined with a double-staining technique to perform partial resection of the epimacular posterior vitreous cortex, followed by ERM and internal limiting membrane (ILM) peeling. This may resolve the high post-operative recurrence of IERM after N-PPV, while also retaining a large portion of the vitreous body and decreasing damage to the lens.

The present study applied 27G core-PPV in patients with IERM and evaluated the effects of this modified IERM surgery for the lens, as well as the efficacy and safety of the procedure.

Patients and methods

Patient information. The present study was approved by the Institutional Ethical Review Board of Shanghai 10th People's Hospital affiliated to Tongji University (Shanghai, China). Written informed consent was obtained from all patients or their guardians prior to the start of the study. A total of 38 patients who received 27G core-PPV for IERM were recruited between October 2015 and December 2016. The inclusion criteria were as follows: Confirmation of ERM using funduscopic examination under slit-lamp microscopy and OCT; visual impairment; metamorphopsia, Amsler Grid Test-positive; phakic eye and a complete 12-month follow-up period. The exclusion criteria were as follows: History of other ocular diseases, surgery and trauma; myopia ≤-6 diopters or hyperopia ≥+6 diopters; axial length ≥26 mm or ≤22 mm; Grades of N2, C1 and above, according to the Lens Opacities Classification System III (LOCS III) (8), and occurrence of diabetes, renal dysfunction and other systemic diseases, which may have interfered with the measurements.

Surgical methods. 27G three-port PPV was performed (Alcon Constellation Vision System). All surgeries were performed by an experienced physician. The affected eye was retrobulbar anesthetized using 2% lidocaine + 1% ropivacaine. Three cannula trocar systems were transconjunctivally inserted in the eye. The small sutureless incisions of 27G PPV were made by trocars, first at 4 mm from the limbus in the infero-temporal quadrant (4:30 or 7:30) for the infusion line and then in the supero-temporal and supero-nasal quadrants (10:30 and 2:30, respectively). The surgical parameters were as follows: 6,000-7,000 cuts/min; vacuum of 500-600 mmHg and perfusion pressure of 25-30 mmHg. The OPMI LUMERA 700 surgical microscope (Carl Zeiss AG) was used and RESIGHT® Fundus Viewing System (Carl Zeiss AG) was applied. In brief, 0.05 ml from 10 mg/ml of triamcinolone acetonide was injected above the optic disc using an ultra-wide-angle lens in order to identify the posterior vitreous cortex before the disc and macula, prior to performing core vitrectomy. After switching to a 60 D posterior-pole lens, the complete detachment of posterior vitreous cortex and the posterior retinal pole was validated. Subsequently, the intraocular perfusion pressure was decreased and staining with 0.025% indocyanine green was performed for 30 sec. The ILM and ERM within the macular area were subsequently peeled using 27G ILM tweezers (27G™ Grieshaber Revolution® DSP; Alcon). The peeling range was within the vascular arches, above and below the posterior pole. The procedure was completed following resection of the vitreous body within a 40˚ range centred on the optic disc, which was roughly defined as the nearly circular region with a radius of the distance (~5.5 mm) from the optic disc to the temporal vascular arch, under an ultra-wide-angle lens. None of the affected eyes received combined cataract surgery. The entire surgical process was video-recorded and the operation time and process were also recorded.

Pre-operative and post-operative examinations. In addition to the patients' medical history, the following information was recorded pre-operatively: Sex, age, disease duration (the time of distorted vision complained by patients), best-corrected visual acuity (BCVA), Amsler grid, intraocular pressure and slit-lamp microscopy-assisted dilated fundus examination with a 90 D funduscopic lens (Volk Digital Wide Field Slit Lamp Indirect Ophthalmoscopy Lens; Volk optical, Inc.). A precise fundus examination was required in order to prevent retinal tears and detachment. In the case of the occurrence of either, the affected patient was removed from the study group and treated by retinal photocoagulation or vitrectomy.

Assessment of lens density was performed using 40˚ slit-lamp imaging of the lens after mydriasis, followed by cataract grading using the LOCS III system. Bilateral fundus images were captured using Model CR-2 (Canon, Inc.). OCT was performed using the Zeiss Cirrus HD-OCT 400 Macular Cube 512 x 128 scanning mode (Carl Zeiss AG) in order to scan the patients' macular area, and an in-built software was used to automatically assess the CMT. OCT angiography (OCTA) was performed using an angioscope with 3 mm x 3 mm measurement range (Optovue RTVue XR Avanti, Optovue, Inc.) to scan the patients' macular are, whilst the flow density map software AngioAnalytics in-built version 2016.1.0.26 was used to quantity the FAZ, superficial retinal capillary density (SRCD) and deep retinal capillary density (DRCD) automatically.

Panoramic ultrasound biomicroscopy (UBM; Model UBMSW-3200L; Tianjin Suowei Electronic Technology) was performed to monitor the PPV scleral incision. B-mode ultrasound (Aviso A/B; Quantel Medical; Bozeman) was performed to observe the post-operative vitreous body and vitreous base.

All patients returned for follow-up at 1 week and at 1, 3, 6 and 12 months post-operatively. During each follow-up, the pre-operative examinations were repeated. UBM, B-mode ultrasound and OCTA were also performed at 6 months post-operatively.

Statistical analysis. Statistical analysis was performed using SPSS software (version 21.0; IBM Corp.). Values are expressed as the mean ± standard deviation. BCVA was converted to Logarithm of the Minimum Angle of Resolution scoring. The repeated-measure analysis of variance (ANOVA) followed by a paired t-test with Bonferroni's corrections was used to compare differences in follow-up data between the pre-operative and post-operative groups in Figs. 1 and 5, and in Tables II, III and V. Pearson correlation analysis was performed between BCVA and FAZ. $P<0.05$ was considered to indicate a statistically significant difference.

Results

Pre- and post-operative BCVA. The baseline characteristics of the 38 patients (18 male, 20 female) are presented in Table I. The mean age of these patients was 62.73±5.61 years. The mean pre-operative BCVA and post-operative BCVA at 1 week and 1, 3, 6 and 12 months are listed in Table II. The post-operative BCVA were all found to be significantly improved compared with those in pre-operative BCVA ($P<0.05$; Fig. 1A; Table II). Based on ≥2 Snellen lines considered as the criterion for improvement (9), 36 of the 38 cases

Table I. Baseline characteristics of 38 eyes of 38 patients with IERM.

Item	Value
Age (years)	45-76 (62.73±5.61)
Sex (male/female)	18/20
Affected eye right/left	22/16
Disease duration (months)	1-15 (7.55±4.21)
Axial length of eye (mm)	23.6±1.4
IOP (mmHg)	13.7±2.5
Operation time (min)	11.52±2.21
Rhegmatogenous retinal detachment	1/38
IERM recurrence	2/38

IERM, idiopathic epiretinal membrane; IOP, intraocular pressure.

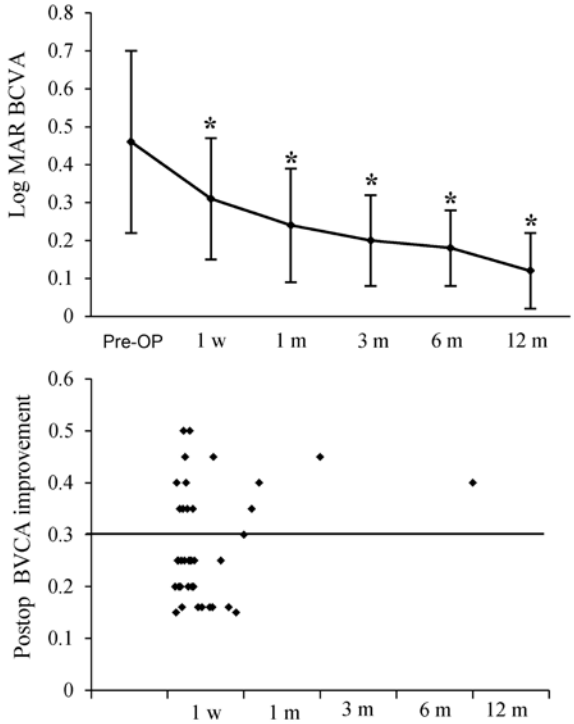

Figure 1. Pre-operative and post-operative changes in BCVA and time distribution of post-operative BCVA recovery. (A) The mean post-operative BCVA at 1 week and 1, 3, 6 and 12 months are significantly improved compared with that in the pre-operative BCVA. (B) During the 12-month follow-up, the post-operative BCVA were >0.15 or ≥2 lines in 36 of 38 patients. Among these, 33 showed significant improvement at 1 week post-operatively, one at 1 month post-operatively and one at 12 months post-operatively. Post-operative BCVA of 18 patients exhibited a score of >0.3, represented by the horizontal line in the lower panel. P<0.05. BCVA, best-corrected visual acuity; w, week; m, month; OP, operation; postop, post-operative.

(94.74%) exhibited improvements in post-operative BCVA. As Fig. 1B shows, 86.84% (33/38) of patients exhibited improved visual acuity at 1 week post-operatively, which means that the post-operative BCVA was improved >0.15 or by 2 lines compared with those of pre-operative BCVA. Furthermore, two additional patients demonstrated improved visual acuity at 1 month post-operatively and 1 additional patient exhibited improvement at 12 months post-operatively. During the entire follow-up, BCVA improved >0.3 (lower panel, Fig. 1) in 50% of the patients (18/38).

Post-operative changes in CMT. Fig. 2 presents the pre- and post-operative CMT of a patient with IERM. The patients' pre-operative CMT ranged from 274 to 626 μm, with a mean value of 435.10±86.36 μm. The mean CMT values at 1, 3, 6 and 12 months post-operatively are presented in Table III. The difference from the pre-operative CMT at 1 week post-operatively was not statistically significant (P=0.60). The subsequent decreases in CMT values were all statistically significant (P<0.05) and the greatest drop of CMT occurred between 1 week and 1 month post-operatively (Table III).

Changes in lens density. According to the LOCS III scoring system, nuclear density of the lens was scored from 0.1 to 6.9 whilst the cortical and posterior subcapsular densities were scored from 0.1 to 5.9 (8). The total LOCS III score of the normal lens is typically ≤5 (nuclear density, ≤2; cortical density, ≤2 and posterior subcapsular density, ≤1) (8,10). Patients with a total LOCS III score of ≥2 were regarded as exhibiting development of post-operative lens opacity (10) compared with the pre-operative group. Fig. 3 presents the pre- and post-operative lens images of a patient with IERM. The pre- and post-operative mean LOCS III total scores of the 38 patients are presented in Table IV. The density changes at different parts of the lens from the pre-operative levels were not statistically significant (P>0.05).

Association between post-operative BCVA with FAZ and vascular density (VD). Fig. 4 presents the images of pre- and post-operative FAZ in a patient with IERM. The mean pre-operative FAZ was 0.19±0.08 mm^2 (range, 0.083-0.460 mm^2), which was low compared with that of the unaffected contralateral eye (0.390±0.180 mm^2). At 6 months post-operatively, the patients' FAZ increased to 0.23±0.14 mm^2, which was higher than the pre-operative value but still lower than the FAZ of the unaffected contralateral eyes. The differences between the pre- and post-operative FAZs in the affected eye, and that between the affected and healthy eyes were statistically significant (P<0.05; Fig. 5).

The post-operative SRCD and DRCD values (45.58±3.58 and 52.71±3.21%, respectively) were significantly lower than the pre-operative values (50.58±3.55 and 54.58±3.46%, respectively) and the values of the fellow eyes (51.76±5.83 and 56.40±5.21%, respectively) at 6 months (P<0.05; Fig. 5).

Correlation analysis indicated that the patients' post-operative BCVA was negatively associated with the FAZ (r=-0.72; P≤0.05; Fig. 5).

B-mode ultrasound and UBM observation of scleral incision. Imaging observation of the scleral incision was performed for all patients at 6 months post-operatively using B-mode ultrasound and UBM. The post-operative UBMs demonstrated no abnormal echoes at the scleral incisions. Furthermore, the vitreous body and vitreous base did not indicate any abnormalities compared with the pre-operative observations (Fig. 6).

Table II. Comparison of pre- and post-OP BCVA in the 38 patients with idiopathic epiretinal membrane.

Time-point	BCVA	F-value	P-value[a]
Pre-OP	0.40±0.23	-	-
1 week post-OP	0.52±0.20	5.18	2.68×10^{-2}
1 month post-OP	0.65±0.20	12.43	1.26×10^{-3}
3 months post-OP	0.65±0.18	18.92	1.05×10^{-4}
6 months post-OP	0.68±0.16	22.80	3.54×10^{-5}
12 months post-OP	0.75±0.16	21.85	3.84×10^{-5}

[a]vs. Pre-OP, repeated-measures ANOVA followed by a paired t-test with Bonferroni's corrections. BCVA, best-corrected visual acuity; OP, operation.

Table III. Pre- and post-operative CMT of the 38 patients with idiopathic epiretinal membrane.

Time-point	CMT (μm)	F-value	P-value[a]
Pre-OP	435.1±86.36	-	-
1 week post-OP	415.75±70.20	0.60	0.60
1 month post-OP	385.15±57.23	4.65	0.04
3 months post-OP	369.5±47.88	8.83	8×10^{-3}
6 months post-OP	342.4±46.51	17.86	2×10^{-4}
12 months post-OP	318.05±37.50	30.91	3.49×10^{-6}

[a]vs. Pre-OP, repeated-measures ANOVA followed by a paired t-test with Bonferroni's correction. CMT, central macular thickness; OP, operation.

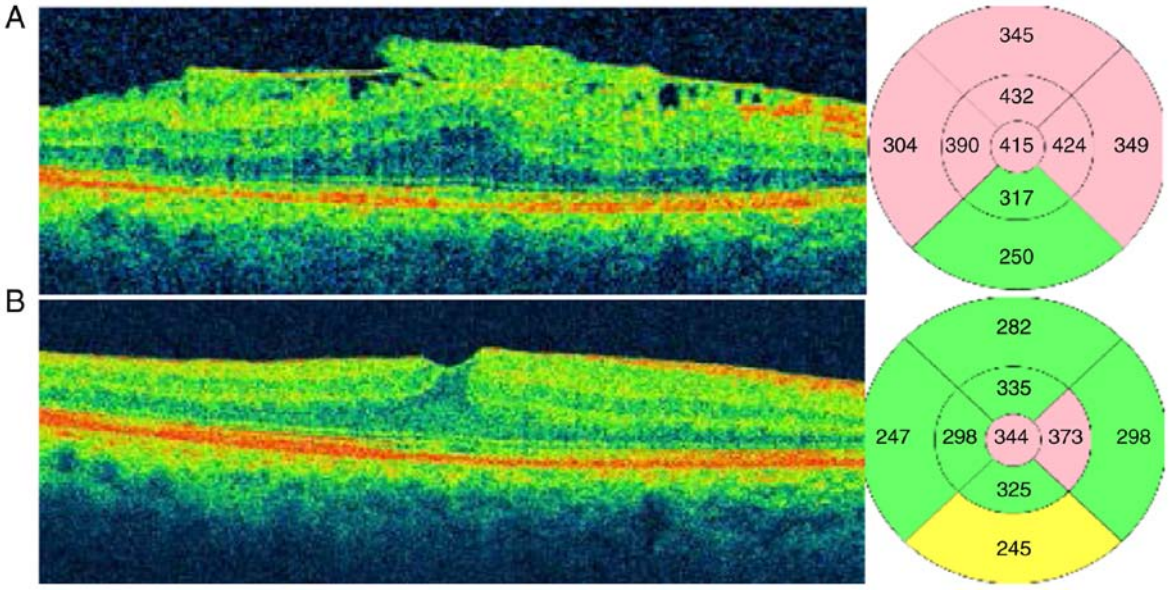

Figure 2. Pre-operative and post-operative analysis CMT of a 61-year old female patient with idiopathic epiretinal membrane. The far-right chart represents the CMT values obtained at 6 mm x 6 mm scan range using the Zeiss Cirrus HD-OCT in-built software automatically. (A) Pre-operative images and (B) images taken 6 months after the operation of the macular area on optical coherence tomography in the same patient, which demonstrated quantitatively that the CMT was markedly decreased from 415 to 344 μm. Magnification, x10. CMT, central macular thickness.

Discussion

PPV remains the predominant treatment for IERM. Oshima *et al* (7) were the first to introduce 27G vitrectomy in 2013. The 27G surgical instruments have smaller diameters, a larger port and a shorter distance between the port and tip compared with 25G vitrectomy. Thus, 27G is able to be used closer to the retina, which increases the space for delicate

Table IV. LOCS III score grades post-OP time-points in the 38 patients with idiopathic epiretinal membrane (38 eyes)[a].

Variable	Pre-OP	1 month post-OP	3 months post-OP	6 months post-OP	12 months post-OP
Nuclear opalescence score	2.53±0.94	2.86±0.87	2.97±0.89	3.33±0.78	3.54±0.63
Cortical score	0.89±0.42	1.18±0.35	1.32±0.34	1.54±0.46	1.66±0.49
Posterior subcapsular score	0.60±0.29	0.76±0.27	0.92±0.27	1.08±0.30	1.18±0.33
LOCS III score	4.63±1.42	5.34±1.43	5.6±1.17	6.26±1.10	6.42±1.05
F-value	-	0.63	1.40	4.13	5.30
P-value[b]	-	0.60	0.38	0.96	0.08

[a]According to the LOCS III scoring system, lens nuclear density was scored between 0.1 and 6.9, whilst the cortical and posterior subcapsular density were scored between 0.1 and to 5.9. The LOCS III total score of a normal lens is ≤5 (nuclear density, ≤2; cortical density, ≤2; and posterior subcapsular density, ≤1). [b]vs. Pre-OP, repeated-measures ANOVA followed by a paired t-test with Bonferroni's corrections. OP, operation; LOCS III, Lens Opacities Classification System III.

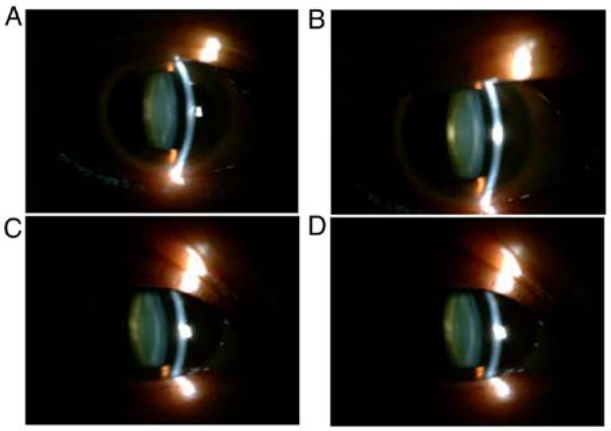

Figure 3. Pre-operative and post-operative lens images of a patient with IERM. Lens images at (A) the pre-operative stage and (B) 1 month, (C) 3 months and (D) 6 months post-operatively of a patient with IERM. IERM, idiopathic epiretinal membrane.

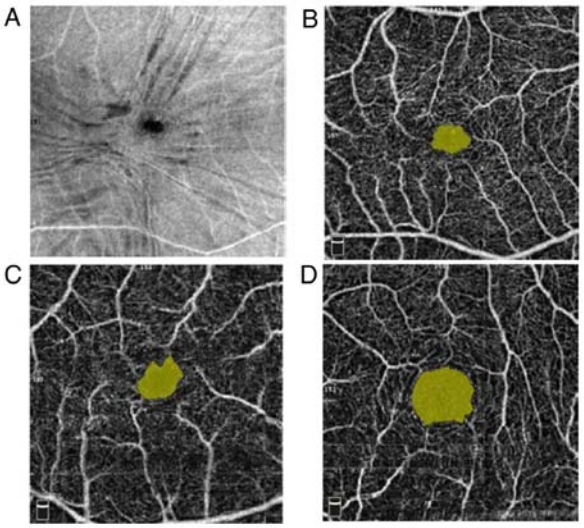

Figure 4. Pre-operative and post-operative FAZ in a patient with idiopathic epiretinal membrane. (A) Image of the fundus of the patient. FAZ images of (B) the affected eye prior to surgery, (C) the affected eye at 6 months post-operatively and (D) of the fellow eye. The pre-operative area of the FAZ was 0.112 mm^2, which decreased compared with that of the unaffected contralateral eye, which was 0.372 mm^2. The area of the FAZ increased to 0.173 mm^2 at 6 months post-operatively, which was higher than the pre-operative thickness but still lower than that of the unaffected contralateral eye. Magnification, x10. FAZ, foveal avascular zone.

operations (11). In addition, the system operating parameters, including cutting speed and vacuum level, have been improved, whereby the 27G probe has an ultra-high cutting speed of 7,500 r/min and the valved sleeves of the 27G vitrectomy probe strengthen its stiffness to a certain extent (12,13).

In contrast to treatments for other fundus diseases, IERM surgery predominantly involves the macular area, while intensive surgery on the peripheral vitreous and retina are not required. Hence, it is the most preponderant indication for PPV with minimal incision (14). Thus, the present study applied the concept of core-PPV in IERM surgery. Core vitrectomy was predominantly applied in conjunction with anterior segment surgeries, including anterior vitrectomy of malignant glaucoma, intraocular lens suspension and cornea transplant (15,16). Naser *et al* (17) performed core-PPV prior to intravitreal injection. Thus, core-PPV involves partial resection of the vitreous body, in accordance with the treatment aims. This technique is advantageous, as it protects the lens and does not interfere with the anterior vitreous body, which in turn decreases the incidence of post-operative cataracts (18).

Cataract is the most common complication following IREM surgery, which has a high incidence rate of 42.5-81.0% (19,20). The decline in oxygen absorption following vitrectomy is considered to be the major cause of subsequent oxidative stress damage to the lens (21). Saito *et al* (22) performed the N-PPV with IERM peeling technique, which has been confirmed to protect the lens post-operatively, and thus avoids cataracts in IERM-PPV. However, the recurrence rate of IERM in N-PPV was reported to be between 10 and 38% (22-24), which is higher than that of conventional PPV, at 1-16% (25,26). The high recurrence rate is considered to be due to the inability to remove the posterior vitreous cortex effectively and the presence of residual ERM without the assistance of staining.

In the present study, the N-PPV with IERM peeling was modified and core epimacular vitrectomy combined with double-staining was performed (27). As this modified surgery preserves the lens behind the vitreous body, the lens density

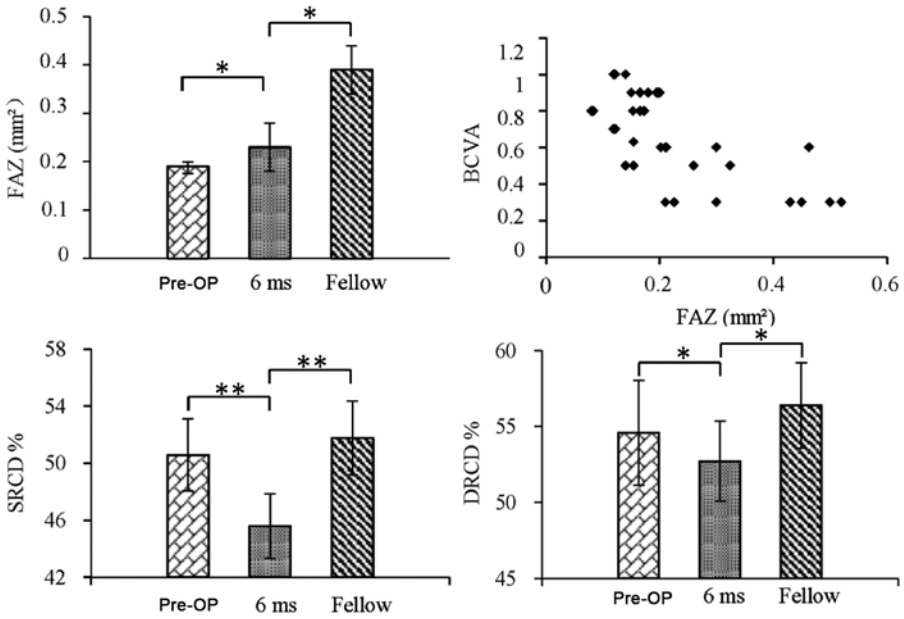

Figure 5. Comparison of the FAZ, SRCD and DRCD at 6 months post-operatively with pre-operative levels among the 38 patients. The FAZ area was significantly increased at 6 months post-operatively compared with that of the pre-operative value, but remained lower compared with those of fellow eyes. The SRCD and DRCD were significantly lower than the pre-operative values and the values for the fellow eyes at 6 months post-operatively. Univariate logistic analysis indicated that the BCVA was negatively correlated with the FAZ at the post-operative stage (r=-0.72; P≤0.05). *P<0.05 and **P<0.01. FAZ, foveal avascular zone; SRCD, superficial retinal capillary density; DRCD, deep retinal capillary density; BCVA, best-corrected visual acuity; ms, months; OP, operation.

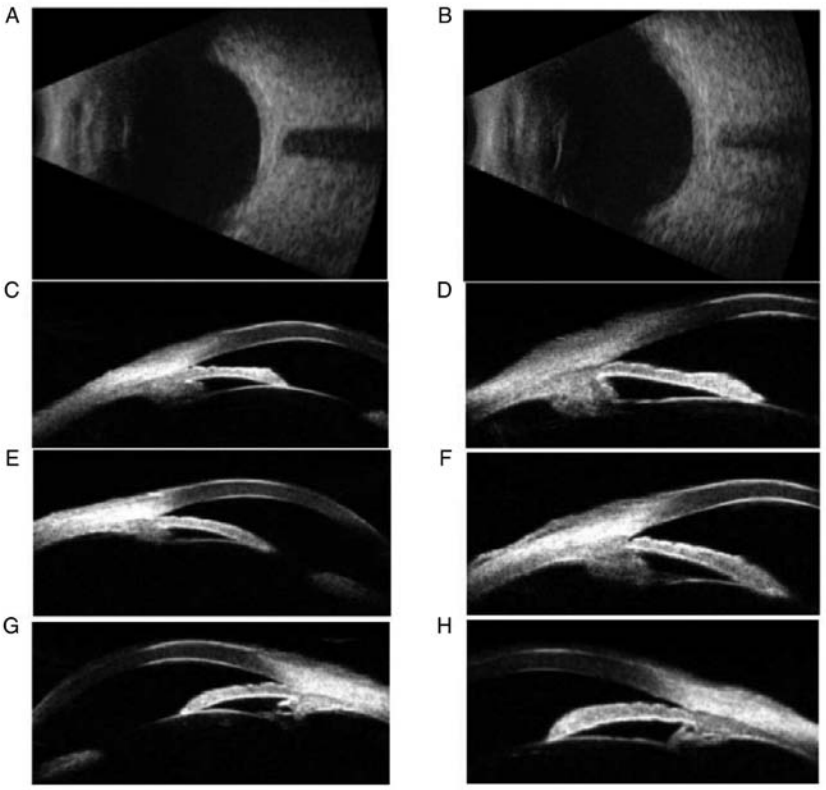

Figure 6. Pre-operative and post-operative (A and B) B-mode ultrasound and (C-H) UBM in a patient with idiopathic epiretinal membrane. (D, F and H) The post-operative UBMs demonstrated no abnormal echoes at the scleral incisions compared with (C, E and G) the pre-operative UBMs. (B) The post-operative vitreous body and vitreous base demonstrated no abnormalities compared with the (A) pre-operative B-mode ultrasound observations. UBM, ultrasound biomicroscopy (magnification, x8).

of the 38 patients was not significantly increased compared with the pre-operative values after 12 months. The combined use of staining techniques also ensured effective removal of the ERM. The post-operative IERM recurrence among the 38 patients was only 5%, which is less than that reported for conventional PPV [23G, 7.9% (28); 25G, 5.1 % (2)].

The results of the present study demonstrated a higher and faster visual recovery rate in the 1st week post-operatively. A total of 33 of the 38 patients (86.84%) exhibited visual improvement of ≥2 Snellen lines, which is higher than the post-operative visual acuity reported after conventional PPV (44.5-80.0%) (9,29,30). Similarly, Sandali *et al* (25) reported that using smaller incisions to treat patients with ERM results in earlier post-operative recovery of visual acuity In that previous study, visual improvement was higher at 8 days postoperatively in the 25G group compared with that observed in the 20G and 23G groups (P=0.035), but not at 6 weeks postoperatively (P=0.186). The major factors affecting earlier visual recovery include corneal astigmatism, inflammatory reaction and post-operative cataract development (26). In the present study, post-operative cataract development of the 38 patients was not statistically significant, which may be the major reason as to why corneal astigmatism and inflammatory reaction were not analyzed. Furthermore, the smaller incision and lower vitreous interference of the 27G procedure may result in faster recovery of visual acuity in patients who underwent the modified core-PPV.

Post-operative CMT of the 38 patients demonstrated a significant decrease compared with the pre-operative value and the maximum CMT decrease was observed at 1 month post-operatively, which was consistent with a previous study by Jung *et al* (31). However, no association was observed between BCVA and CMT in the present study. CMT fails to fully predict the patients' level of post-operative visual acuity in clinical practice. According to certain scholars, the preservation of the foveal photoreceptor inner/outer segment and external limited membrane may be key factors in the prognosis of BCVA (32). Laban *et al* (33) reported that OCT characteristics are not associated with post-operative BCVA and according to them, pre-operative BCVA is the most influential factor.

In the present study, OCTA was also performed to assess the association between FAZ and VD with post-operative BCVA. First of all, the refractive system of the eye is composed of the cornea, aqueous humor, lens and vitreous body. The total refractive force of the eyeball was +58.64 D, including +43.05 D for the cornea and +16.0 - +20.0 D for the lens; thus, the vitreous has low refractive power. A relevant study reported that most of the progression of myopia after vitrectomy was linked to cataract progression (34). However, in the present study, no significant cataract progression was detected at 12 months post-operatively. Thus, it may be concluded that there was almost no change in refraction after vitrectomy, which made the FAZ and VD between the pre- and post-operative examination comparable.

Kitagawa *et al* (35) reported that the mean post-operative FAZs were significantly larger than the pre-operative value; however, they still remained smaller than those of the fellow eyes, which was consistent with the results of the present study. These changes in the FAZ suggest that IERM may directly alter the distribution of macular capillaries. Furthermore, the results of the present study demonstrated that the FAZ was positively associated with visual acuity. Thus, the FAZ of patients with IERM may be a useful indicator of post-operative visual acuity. Furthermore, the mean SRCD and DRCD at 6 months post-operatively were significantly lower than the pre-operative values and the values of the fellow eyes. Similarly, Kim *et al* (36) demonstrated that eyes with ERM following surgery had a lower parafoveal VD and a smaller FAZ in the superficial capillary plexus and deep capillary plexus compared with the fellow eyes. The reasons for the decrease in SRCD and DRCD remain elusive; however, the results indicate that surgery may cause potential damage to retinal function.

A major concern over the use of core-PPV for the treatment of ERM is its potential to induce post-operative proliferative vitreoretinopathy (PVR). All patients underwent B-mode ultrasound and UBM at 6 and 12 months, respectively, which did not reveal any proliferative changes. In theory, two major factors may lead to the onset of PVR: Epithelial-to-mesenchymal transition of the retinal pigment epithelium cells and the extensive secretion of inflammatory mediators, cytokines and growth factors (37). Thus, undetected tears are a risk factor. In the present study, precise pre-operative fundus examination was performed to exclude retinal tears and detachment. In the case of either, the affected patient was removed from the study group and treated by retinal photocoagulation or vitrectomy. 27G core-PPV is also able to minimize invasiveness of the surgery and the low inflammatory response of the operated eye markedly decreases the probability of PVR.

During the follow-up period, one patient experienced inferior retinal detachment at 3 months post-operatively. Peripheral retinal tears were observed at the 6 o'clock position through the second thorough vitrectomy. In subsequent surgeries, examination of the peripheral retina was enhanced under a wide-angle lens, which prevented the occurrence of similar cases.

In conclusion, in the present study, a modified surgical technique of 27G core-PPV was applied, which was combined with ILM peeling for the treatment of IERM and achieved effective clinical outcomes. Higher and faster visual recovery rates were observed compared with conventional PPV post-operatively in the first week. At 12 months post-surgery, the lens densities of the 38 patients were not significantly increased compared with the pre-operative values. The mean post-operative FAZs were significantly larger than the pre-operative values; however, they still remained smaller than those of the fellow eyes. Following surgery, eyes with ERM demonstrated a lower VD and a smaller FAZ compared with the fellow eyes. Compared with conventional PPV (23G, 25G) reported in previous studies, better clinical outcomes were achieved in the present study. However, the present study lacked control groups (no surgery group and 27G conventional PPV group). Further clinical studies are required to confirm the outcomes of this modified surgery.

Acknowledgements

Not applicable.

Funding

This work was supported by Shanghai 10th People's Hospital New Emerging Talent Program (grant no. 2018SYPDRC036).

Availability of data and materials

The datasets used and/or analyzed during the current study are available from the corresponding author on reasonable request.

Authors' contributions

LX and FW designed the study protocol, analyzed the data and drafted the manuscript. FW was the only surgeon who performed all the surgeries in the study. KK and LH contributed to data acquisition and examination of the patients. All authors had read and approved the final version of the manuscript and have full responsibility for all primary data.

Ethics approval and consent to participate

All patients or their guardians provided written informed consent to participate in the present study and the present study was approved by the institutional ethical review board of Shanghai 10th People's Hospital affiliated to Tongji University (approval no. SHSY-IEC-4.0/16-148/02; Shanghai, China).

Patient consent for publication

Not applicable.

Competing interests

The authors declare that they have no competing interests.

References

1. Seidel G, Weger M, Stadlmüller L, Pichler T and Haas A: Association of preoperative optical coherence tomography markers with residual inner limiting membrane in epiretinal membrane peeling. PLoS One 8: e66217, 2013.
2. Reilly G, Melamud A, Lipscomb P and Toussaint B: Surgical outcomes in patients with macular pucker and good preoperative visual acuity after vitrectomy with membrane peeling. Retina 35: 1817-1821, 2015.
3. Liu HY, Hsieh YT and Yang CM: Paravascular abnormalities in eyes with idiopathic epiretinal membrane. Graefes Arch Clin Exp Ophthalmol 254: 1723-1729, 2016.
4. Hejsek L, Stepanov A, Dusova J, Marak J, Nekolova J, Jiraskova N and Codenotti M: Microincision 25G pars plana vitrectomy with peeling of the inner limiting membrane and air tamponade in idiopathic macular hole. Eur J Ophthalmol 27: 93-97, 2017.
5. Do DV, Gichuhi S, Vedula SS and Hawkins BS: Surgery for post-vitrectomy cataract. Cochrane Database Syst Rev 12: CD006366, 2013.
6. Mizutani Y, Sato Y and Shimda H: Outcome of nonvitrectomizing vitreous surgery for epimacular membranes. Nippon Ganka Kiyo 52: 302-306, 2001.
7. Oshima Y, Wakabayashi T, Sato T, Ohji M and Tano Y: A 27-gauge instrument system for transconjunctival sutureless microincision vitrectomy surgery. Ophthalmology 117: 93-102. e2, 2010.
8. Chylack LT Jr, Wolfe JK, Singer DM, Leske MC, Bullimore MA, Bailey IL, Friend J, McCarthy D and Wu SY: The Lens Opacities Classification System III. The Longitudinal Study of Cataract Study Group. Arch Ophthalmol 111: 831-836, 1993.
9. Chang WC, Lin C, Lee CH, Sung TL, Tung TH and Liu JH: Vitrectomy with or without internal limiting membrane peeling for idiopathic epiretinal membrane: A meta-analysis. PLoS One 12: e0179105, 2017.
10. Varma R, Richter GM, Torres M, Foong AW, Choudhury F and Azen SP; Los Angeles Latino Eye Study Group: Four-year incidence and progression of lens opacities: The Los Angeles Latino Eye Study. Am J Ophthalmol 149: 728-34.e1, 2, 2010.
11. Osawa S and Oshima Y: Innovations in 27-Gauge vitrectomy for sutureless microincision vitrectomy surgery. Rsetina 4: 42-45, 2014.
12. Osawa S and Oshima Y: 27-Gauge vitrectomy. Dev Ophthalmol 54: 54-62, 2014.
13. Kim YJ, Park SH and Choi KS: Fluctuation of infusion pressure during microincision vitrectomy using the constellation vision system. Retina 35: 2529-2536, 2015.
14. Yoneda K, Morikawa K, Oshima Y, Kinoshita S and Sotozono C; Japan Microincision Vitrectomy Surgery Study Group: Japan microincision vitrectomy surgery study group. Surgical outcomes of 27-gauge vitrectomy for a consecutive series of 163 eyes with various vitreous diseases. Retina 37: 2130-2137, 2017.
15. Sachdev R, Gupta A, Narula R and Deshmukh R: Limited vitrectomy in phacomorphic glaucoma. Indian J Ophthalmol 65: 1422-1424, 2017.
16. Higaki S, Fukuda M, Matsumoto C and Shimomura Y: Results of penetrating keratoplasty triple procedure with 25-gauge core vitrectomy. Cornea 31: 730-733, 2012.
17. Naser H, Koss MJ, Singh P and Koch F: Combined pharmacosurgery as treatment for diabetic macular edema: Core pars plana vitrectomy and intravitreal injection of bevacizumab and triamcinolone. Klin Monatsbl Augenheilkd 228: 910-914, 2011 (In German).
18. Rizzo S, Genovesi-Ebert F, Murri S, Belting C, Vento A, Cresti F and Manca ML: 25-gauge, sutureless vitrectomy and standard 20-gauge pars plana vitrectomy in idiopathic epiretinal membrane surgery: A comparative pilot study. Graefes Arch Clin Exp Ophthalmol 244: 472-479, 2006.
19. Song SJ, Kuriyan AE and Smiddy WE: Results and prognostic factors for visual improvement after pars plana vitrectomy for idiopathic epiretinal membrane. Retina 35: 866-872, 2015.
20. Gupta OP, Weichel ED, Regillo CD, Fineman MS, Kaiser RS, Ho AC, McNamara JA and Vander JE: Postoperative complications associated with 25-gauge pars plana vitrectomy. Ophthalmic Surg Lasers Imaging 38: 270-275, 2007.
21. Nam Y, Chung H, Lee JY, Kim JG and Yoon YH: Comparison of 25- and 23-gauge sutureless microincision vitrectomy surgery in the treatment of various vitreoretinal diseases. Eye (Lond) 24: 869-874, 2010.
22. Saito Y, Lewis JM, Park I, Ikuno Y, Hayashi A, Ohji M and Tano Y: Nonvitrectomizing vitreous surgery: A strategy to prevent postoperative nuclear sclerosis. Ophthalmology 106: 1541-1545, 1999.
23. Reibaldi M, Longo A, Avitabile T, Bonfiglio V, Toro MD, Russo A, Viti F, Nicolai M, Saitta A, Giovannini A, *et al*: Transconjunctival Nonvitrectomizing vitreous surgery versus 25-gauge vitrectomy in patients with epiretinal membrane: A Prospective Randomized Study. Retina 35: 873-879, 2015.
24. Sakaguchi H, Oshima Y and Tano Y: 27-gauge transconjunctival nonvitrectomizing vitreous surgery for epiretinal membrane removal. Retina 27: 1302-1304, 2007.
25. Sandali O, El Sanharawi M, Lecuen N, Barale PO, Bonnel S, Basli E, Borderie V, Laroche L and Monin C: 25-, 23-, and 20-gauge vitrectomy in epiretinal membrane surgery: A comparative study of 553 cases. Graefes Arch Clin Exp Ophthalmol 249: 1811-1819, 2011.
26. Hikichi T, Matsumoto N, Ohtsuka H, Higuchi M, Matsushita T, Ariga H, Kosaka S and Matsushita R: Comparison of one-year outcomes between 23- and 20-gauge vitrectomy for preretinal membrane. Am J Ophthalmol 147: 639-643.e1, 2009.
27. Stalmans P, Feron EJ, Parys-Van Ginderdeuren R, Van Lommel A, Melles GR and Veckeneer M: Double vital staining using trypan blue and infracyanine green in macular pucker surgery. Br J Ophthalmol 87: 713-716, 2003.
28. Ahn SJ, Ahn J, Woo SJ and Park KH: Photoreceptor change and visual outcome after idiopathic epiretinal membrane removal with or without additional internal limiting membrane peeling. Retina 34: 172-181, 2014.
29. Pournaras CJ, Emarah A and Petropoulos IK: Idiopathic macular epiretinal membrane surgery and ILM peeling: Anatomical and functional outcomes. Semin Ophthalmol 26: 42-46, 2011.
30. Kim TW, Song SJ, Chung H and Yu HG: Internal Limiting Membrane Peeling In Surgical Treatment of Macular Epiretinal Membrane. J Korean Ophthalmol Soc 6: 989-994, 2005.
31. Jung JJ, Hoang QV, Ridley-Lane ML, Sebrow DB, Dhrami-Gavazi E and Chang S: Long-term retrospective analysis of visual acuity and optical coherence Topographic changes after single versus double peeling during vitrectomy for macular epiretinal membranes. Retina 36: 2101-2109, 2016.
32. Deák GG, Bolz M, Ritter M, Prager S, Benesch T and Schmidt-Erfurth U; Diabetic Retinopathy Research Group Vienna: A systematic correlation between morphology and functional alterations in diabetic macular edema. Invest Ophthalmol Vis Sci 51: 6710-6714, 2010.
33. Laban KG, Scheerlinck LM and van Leeuwen R: Prognostic Factors Associated with Visual Outcome after Pars Plana Vitrectomy with Internal Limiting Membrane Peeling for Idiopathic Epiretinal Membrane. Ophthalmologica 234: 119-126, 2015.

34. Muto T, Nishimura T, Yamaguchi T, Chikuda M and Machida S: Refractive changes after lens-sparing vitrectomy for macular hole and epiretinal membrane. Clin Ophthalmol 11: 1527-1532, 2017.
35. Kitagawa Y, Shimada H, Shinojima A and Nakashizuka H: Foveal avascular zone area analysis using optical coherence tomography angiography before and after idiopathic epiretinal membrane surgery. Retina 39: 339-346, 2019.
36. Kim YJ, Kim S, Lee JY, Kim JG and Yoon YH: Macular capillary plexuses after epiretinal membrane surgery: An optical coherence tomography angiography study. Br J Ophthalmol 102: 1086-1091, 2018.
37. Yang S, Yao H, Li M, Li H and Wang F: Long Non-Coding RNA MALAT1 Mediates Transforming Growth Factor Beta1-Induced Epithelial-Mesenchymal Transition of Retinal Pigment Epithelial Cells. PLoS One 11: e0152687, 2016.