Myasthenia gravis that has developed long after radical resection of lung cancer: A case report

SHINICHIRO OKAUCHI[1], AYAKO SHIOYA[2], KESATO IGUCHI[3], KINYA FURUKAWA[4] and HIROAKI SATOH[1]

Divisions of [1]Respiratory Medicine, [2]Neurology and [3]Thoracic Surgery, Mito Medical Center, University of Tsukuba, Mito, Ibaraki 3100015; [4]Division of Thoracic Surgery, Ibaraki Medical Center, Tokyo Medical University, Ami, Ibaraki 3000395, Japan

Received April 8, 2022; Accepted May 19, 2022

DOI: 10.3892/etm.2022.11492

Abstract. Myasthenia gravis (MG) is the most common disorder of neuromuscular transmission and is a heterogeneous disorder generally caused by auto-antibody to the nicotinic acetylcholine receptor. The current study presented a rare case of MG that occurred a long time after surgical resection of lung cancer. A 58-year-old man with lung adenocarcinoma underwent upper lobectomy and mediastinal lymph node dissection. Severe myasthenic symptoms began 7 years after the operation, and emergent mechanical ventilation was needed because of myasthenic crises. Levels of serum anti-acetylcholine receptor antibody were high and typical decremental responses to repetitive stimulation on electromyography were observed. Appropriate therapies for a severe acute condition were performed, and MG has been controlled for 6 years since then. There is no recurrence of lung cancer or appearance of thymoma. In conclusion, although very rare, physicians should be aware of MG as a potential comorbidity developing in patients with a history of lung cancer.

Introduction

Clinically, myasthenia gravis (MG) and Lambert-Eaton syndrome are characterized by muscle weakness and easy fatigability. These symptoms are brought about by an impairment of nerve and muscle synaptic transmission (1). MG is often caused by autoantibodies to the acetylcholine receptors on the postsynaptic membrane (2), whereas, Lambert-Eaton syndrome develops mainly due to autoantibodies to calcium channels in the presynaptic membrane (3). Numerous patients with MG also develop thymic abnormalities such as thymoma and thymus hyperplasia (2). In contrast, Lambert-Eaton syndrome frequently occurs concomitantly with lung cancer, especially small cell lung cancer (3). Patients with lung cancer who develop MG are extremely rare (4-17). Furthermore, there have been no reports of MG developing several years after the lung cancer was completely resected. We herein report a rare case of MG that occurred seven years after a surgical resection of lung cancer. This patient developed myasthenic crisis, a critical condition in which rapidly occurred severe weakness of the pharyngeal and respiratory muscles. After successful treatment with mechanical ventilation, plasma exchange and methylprednisolone, the patient has been followed up for more than 6 years.

Case report

A 58-year-old man underwent upper lobectomy and mediastinal lymph node dissection due to T2aN0M0, stage IB lung adenocarcinoma (Fig. 1) at Ibaraki Medical Center, Tokyo Medical University (Ami, Ibaraki, Japan) in January 2008. He had neither thyroid nor other autoimmune disorders, nor a family history of neuromuscular or autoimmune disorder. He did not have any postoperative recovery difficulties that might have suggested pre-existing neuromuscular transmission disorder. Fifteen months after resection, there was swelling of the left lower tracheal bronchial lymph node, which was irradiated with 60 Gy. Six years after the end of irradiation, he presented at Mito Medical Center, University of Tsukuba (Mito, Ibaraki, Japan) with a chief complaint of double vision, bilateral eyelid drooping, and difficulty swallowing for one month. He was not taking any antiarrhythmic agents or other drugs impairing neuromuscular transmission. Development of thymic disease and recurrence of lung cancer were ruled out on imaging studies. Neurologic examination showed ptosis and gaze palsy with facial muscle weakness and reduced gag reflex. The repetitive nerve stimulation test (RNS) showed abnormal (>10%) decrement in facial, accessory, median nerve (Fig. 2; median nerve, stimulation frequency 10 Hz). Waning was observed in the repeated stimulation test, and the serum anti-acetylcholine receptor (AchR) antibody level was 67.0 nmol/l (normal: up to 0.2 nmol/l). With these findings, we diagnosed generalized MG of Ossermann II type. In addition to cholinesterase inhibitors (180 mg/day, oral), we started plasma exchange and treatment with prednisolone (2.5 mg/day, oral)

Correspondence to: Dr Hiroaki Satoh, Division of Respiratory Medicine, Mito Medical Center, University of Tsukuba, 3-2-7 Miya-machi, Mito, Ibaraki 3100015, Japan
E-mail: hirosato@md.tsukuba.ac.jp

Key words: myasthenia gravis, curative resection, lung cancer, postoperative, adenocarcinoma

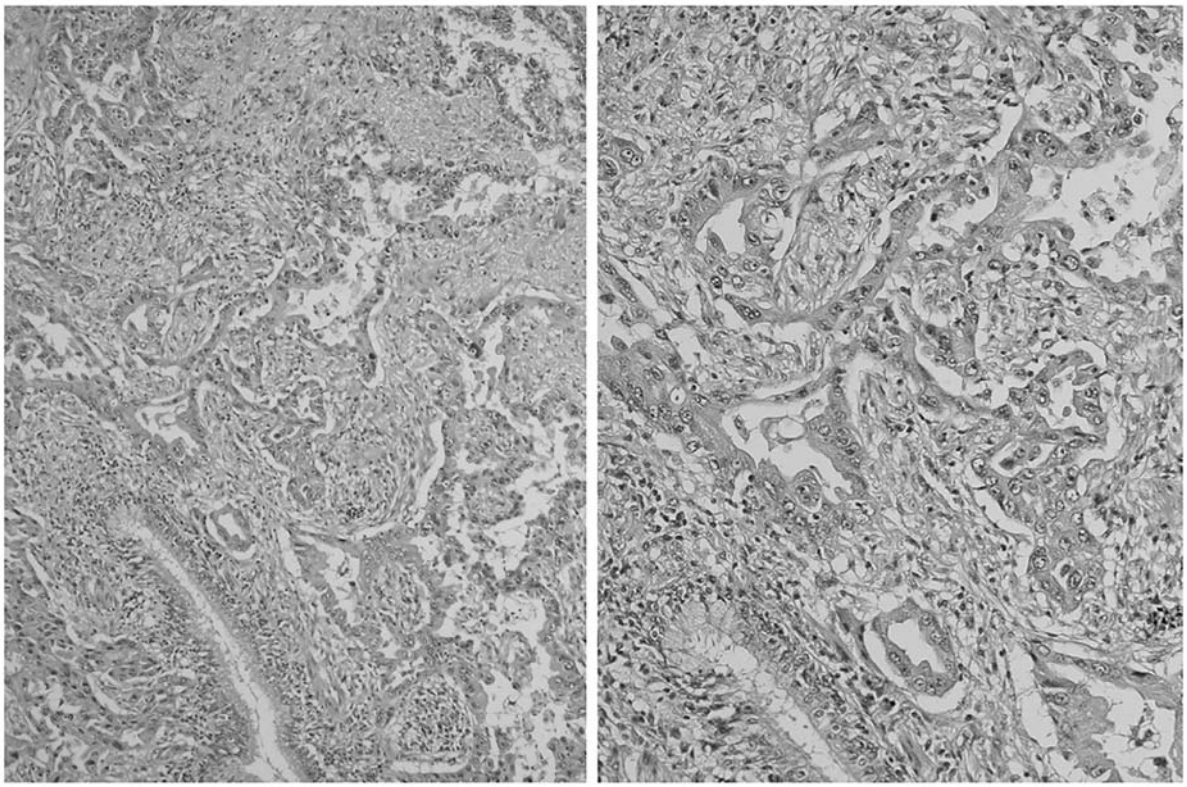

Figure 1. Histological findings of the surgically resected specimens of the tumor. As glandular structures that were round to oval shaped, with a central luminal space surrounded by cancer cells, the pathological diagnosis of the tumor was papillary lung adenocarcinoma [left, low power field (magnification, x100); right, high power field (magnification, x400)].

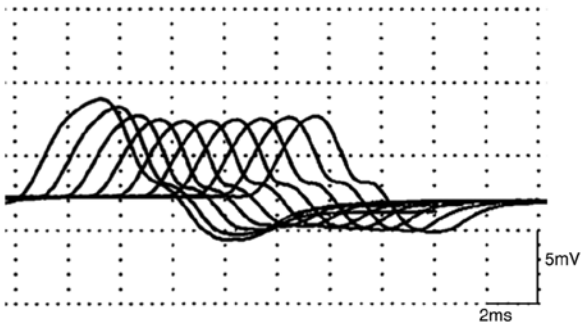

Figure 2. Findings on the evoked electromyogram of the patient. The amplitude of the fifth wave was 26.9% lower compared with that of the first wave when the left facial nerve was stimulated at 10 Hz repetition frequency. Comparing the first wave and the fifth wave, the gradual decrease rate of the amplitude is considered to be normal within 10%. The waning phenomenon on electromyography in this patient suggested a diagnosis of myasthenia gravis.

which was gradually increased. On day 26 after hospitalization, he had acute respiratory failure and needed mechanical ventilation for myasthenic crisis. He had pulse therapy with methylprednisolone at 1,000 mg/day (three days) and plasma exchange six times within a month, and was successfully discharged from the hospital. Prednisolone (60 mg/day) gradually decreased to 10 mg/day, and pyridostigmine (180 mg/day, oral) continued at the same dose for 16 weeks. However, the symptoms of MG worsened 17 and 25 months after the start of treatment for MG, and the dose of prednisolone was increased up to 30 mg/day and plasma exchange was performed again. Symptoms of MG were improved, and these drugs gradually decreased. Six years have passed since the end of treatment, but neither recurrence of lung cancer nor development of thymoma has been confirmed. AchR antibody level in recent years has been 6.5-8.2 nmol/l, which are higher than the normal value, but the symptoms associated with MG are controlled. At present, prednisolone has been tapered down to 60 mg/day and 13 mg/day, respectively. Fig. 3 shows a timeline with relevant data from the episode of care.

Discussion

When symptoms such as double vision, eyelid drooping, and difficulty in swallowing occur in patients with a history of thymic disease, a patient may have developed MG and should be diagnosed and treated accordingly. When such myasthenic symptoms manifest in patients with lung cancer, Eaton-Lambert syndrome should be included in the differential diagnosis. In our patient, whole-body imaging studies, including of the chest, showed no recurrence and no development of thymoma for 14 years after the diagnosis of lung cancer. MG was diagnosed on the basis of elevated serum AchR level, a typical decreasing response to repeated stimulation of EMG, and positive findings on the tensilon test.

The first case with MG associated with lung cancer was reported by Hazard *et al* in 1986 (4). Since then, to our best knowledge, 14 lung cancer patients with MG have been reported (4-17). Of these 14 cases, six were small cell lung cancer, one was LCNEC, and seven were non-small cell lung cancer. Previous reports have reported that MG

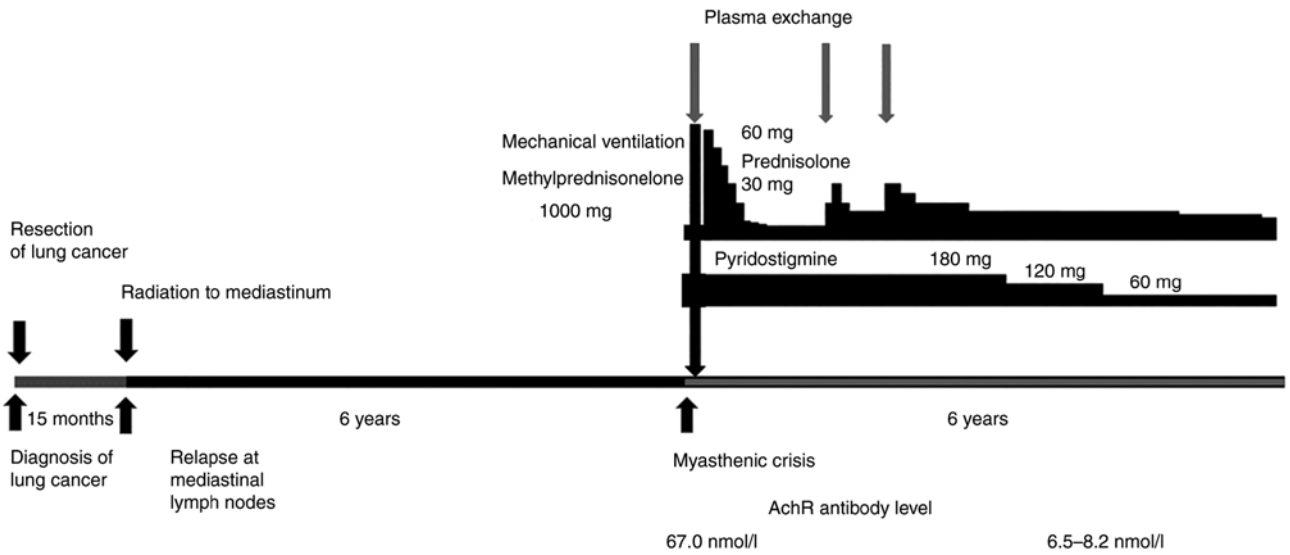

Figure 3. Timeline with relevant data from the episode of care.

onset was more common in patients with small cell lung cancer (4-6,13,16,17), but there were cases of non-small cell lung cancer that also developed MG (7-12,14,15). Regarding the onset time of lung cancer and MG, nine patients were diagnosed with lung cancer at the time of MG onset (4,5,9,10,12-16). In three cases, however, the onset of MG preceded the diagnosis of lung cancer by eight months to six years (6,8,17). On the other hand, in two cases, the onset of MG anteceded the diagnosis of lung cancer by two to three years (7,11). One patient developed MG when lung cancer recurred (11). In this patient, chemotherapy, radiation therapy, and surgical resection were performed, but two years later, lung cancer recurred with pleural effusion and MG developed (11). Interestingly, in one case, as in our patient, the diagnosis of lung cancer preceded the onset of MG (7). This patient had developed MG three years after the diagnosis of lung cancer. Due to invasion of the vertebral body at the time of his diagnosis of lung cancer, complete resection was not performed. The pathological diagnosis of lung cancer in this patient was poorly differentiated anaplastic malignancy with a number of atypical cells and multiple mitoses consistent with large-cell carcinoma of the lung (7). One year later, the patient developed adenocarcinoma of the other lung and he died of systemic complications of MG ~2 years after the initial diagnosis of MG (7). Considering this course, the possibility of residual lung cancer and involvement of new lung cancer in the onset of MG could not be ruled out in this patient. In our patient with completely resected stage IB lung cancer, there had been no lung cancer recurrence and no development of thymoma until the onset of MG six years after irradiation. Although the mechanism was unknown, considering that AchR antibody levels were higher than normal even in recent years, we speculated that the memory of immunocompetent cells was involved in the onset of MG (18), not the residual lesions of lung cancer.

Treatment of advanced lung cancer has made great strides in the last decade; particularly, treatment with immune checkpoint inhibitors (ICPIs) has significantly improved prognosis. Alongside, the immune-related side effects (irAEs) caused by ICPI have attracted attention, including ICPI-related MG (19,20). Safa *et al* reported that MG is a life-threatening irAE of acute onset and rapid progression after ICPI initiation (19). In a previous review of the 23 reported cases of ICPI-associated MG, 72.7% were *de novo* presentations, 18.2% were exacerbations of pre-existing MG and 9.1% were exacerbations of subclinical MG (20). Our patient did not receive any ICPI treatment, therefore, the possibility of developing ICPI-related MG can be completely ruled out. However, ICPI-related MG is an interesting irAE from the viewpoint of pathogenesis and treatment method, and future research will be expected.

Survival time was described in 6 lung cancer patients with MG (7,8,10,15-17). Three of them died within two years after initiation of therapy for these diseases (7,16,17). Only one patient was followed up for more than 3 years (10). This patient had lung cancer and MG found at the same time, and the symptoms of MG disappeared after lung cancer resection, and he had been taking pyridostigmine bromide for 4 years and 2 months (10). In our patient, recurrence occurred at the mediastinal lymph nodes 15 months after the resection, and radical irradiation was performed on the mediastinum. MG developed 6 years after the irradiation. No additional treatment for lung cancer was subsequently given, but there has been no recurrence of lung cancer for 6 years. To the best of our knowledge, this was the longest survived patient, and is interesting in terms of treatment of lung cancer and MG.

In our patient, recurrence of lung cancer or development of thymic disease could be ruled out on imaging studies for more than six years after MG was controlled. We must carefully follow up the patient not to overlook the recurrence of lung cancer and the development of thymic disease, even if MG is controlled. This case indicates that physicians should be aware that MG as a potential comorbid disease can develop in patients with a history of lung cancer.

Acknowledgements

Not applicable.

Funding

No funding was received.

Availability of data and materials

The datasets used and/or analyzed during the current study are available from the corresponding author on reasonable request.

Authors' contributions

SO, AS, KI, KF and HS contributed to the planning, conduct, reporting, conception, design and acquisition of data and drafting the manuscript. All authors read and approved the final manuscript. SO and HS confirm the authenticity of all the raw data.

Ethics approval and consent to participate

This study was approved by the Institutional Review Board of the Mito Medical Center, University of Tsukuba-Mito Kyodo General Hospital (approval no. 16-39).

Patient consent for publication

Written informed consent from the patient for the publication of their data was obtained from the patient.

Competing interests

The authors declare that they have no competing interests.

References

1. Rodríguez Cruz PM, Cossins J, Beeson D and Vincent A: The neuromuscular junction in health and disease: Molecular mechanisms governing synaptic formation and homeostasis. Front Mol Neurosci 13: 610964, 2020.
2. Dresser L, Wlodarski R, Rezania K and Soliven B: Myasthenia gravis: Epidemiology, pathophysiology and clinical manifestations. J Clin Med 10: 2235, 2021.
3. Huang K, Luo YB and Yang H: Autoimmune channelopathies at neuromuscular junction. Front Neurol 10: 516, 2019.
4. Hazard PB, Bertorini TE and Griffin JP: Myasthenia gravis associated with small cell carcinoma of the lung. J Tenn Med Assoc 79: 273-276, 1986.
5. Fujita J, Yamadori I, Yamaji Y, Yamagishi Y, Takigawa K and Takahara J: Myasthenia gravis associated with small-cell carcinoma of the lung. Chest 105: 624-625, 1994.
6. Miyoshi R, Yamaji Y, Shima S, Fujita J, Okada H and Takahara J: A case of small cell lung cancer that developed during therapy for myasthenia gravis. Nihon Kyobu Shikkan Gakkai Zasshi 33: 456-462, 1995 (In Japanese).
7. Leavitt JA and Myasthenia gravis with a paraneoplastic marker. J Neuroophthalmol 20: 102-105, 2000.
8. Sakamaki Y, Yoon HE and Oda N: Non-small-cell lung cancer associated with non-thymomatous myasthenia gravis. Jpn J Thorac Cardiovasc Surg 54: 207-211, 2006.
9. Takagi M and Akiba T: A case of surgically treated primary lung cancer with myasthenia gravis. Nihon Kokyuki Gakkai Zasshi 45: 198-201, 2007 (In Japanese).
10. Kataoka K, Fujiwara T, Matsuura M and Seno N: A case of simultaneously operated primary multiple lung cancers with nonthymomatous myasthenia gravis. Jpn J Lung Cancer 49: 273-277, 2009 (In Japanese).
11. Peltier AC, Black BK, Raj SR, Donofrio P, Robertson D and Biaggioni I: Coexistent autoimmune autonomic ganglionopathy and myasthenia gravis associated with non-small-cell lung cancer. Muscle Nerve 41: 416-419, 2010.
12. Shaygannejad V, Ghasemi M and Rajaee Z: Myasthenia gravis as a presenting feature in a patient with lung cancer: A case report. J Res Med Sci 16: 229-232, 2011.
13. Ohira M, Jeong D and Oh SJ: Seropositive myasthenia gravis associated with small-cell lung carcinoma. J Clin Neurol 7: 43-46, 2011.
14. Takizawa M, Oda M, Matsumoto I, Waseda R, Tanaka N and Watanabe G: Myasthenia gravis complicated with lung cancer and middle mediastinal thymoma. Asian Cardiovasc Thorac Ann 20: 486-488, 2012.
15. Niimi K, Nagata E, Murata N, Sato M, Tanaka J, Horio Y, Takiguchi H, Tomomatsu H, Tomomatsu K, Hayama N, *et al*: Lung cancer associated with seronegative myasthenia gravis. Intern Med 54: 1381-1384, 2015.
16. Yamasaki M, Funaishi K, Saito N, Yonekawa T, Yamawaki T, Ihara D, Daido W, Ishiyama S, Deguchi N, Taniwaki M and Hattori N: Acetylcholine receptor antibody-positive myasthenia gravis associated with small-cell lung cancer: A case report. Medicine (Baltimore) 97: e0541, 2018.
17. Jia R, Chen J, Ge R, Zheng Q, Chen F and Zhao Z: Coexistence of myasthenia gravis and Lambert-Eaton myasthenic syndrome in a small cell lung cancer patient: A case report. Medicine (Baltimore) 97: e10976, 2018.
18. Stathopoulos P, Kumar A, Heiden JA, Pascual-Goñi E, Nowak RJ and O'Connor KC: Mechanisms underlying B cell immune dysregulation and autoantibody production in MuSK myasthenia gravis. Ann NY Acad Sci 1412: 154-165, 2018.
19. Safa H, Johnson DH, Trinh VA, Rodgers TE, Lin H, Suarez-Almazor ME, Fa'ak F, Saberian C, Yee C, Davies MA, *et al*: Immune checkpoint inhibitor related myasthenia gravis: Single center experience and systematic review of the literature. J Immunother Cancer 7: 319, 2019.
20. Makarious D, Horwood K and Coward JI: Myasthenia gravis: An emerging toxicity of immune checkpoint inhibitors. Eur J Cancer 82: 128-136, 2017.