A rare rectal gastrointestinal stromal tumor with indolent biological behavior: A case study

JIAN YANG[1], YING LIU[2], XUE-JIA SUN[3], ZHONG-WEI AI[4] and SHI LIU[5]

[1]Department of General Surgery, The First Affiliated Hospital of Jiamusi University, Jiamusi, Heilongjiang 154003; Departments of [2]Medical Oncology and [3]Radiology, The Third Affiliated Hospital of Qiqihar Medical University, Qiqihar, Heilongjiang 161000; [4]Pathology Center, Qiqihar Medical University, Qiqihar, Heilongjiang 161003; [5]Central Laboratory, The Third Affiliated Hospital of Qiqihar Medical University, Qiqihar, Heilongjiang 161000, P.R. China

Received May 16, 2022; Accepted July 27, 2022

DOI: 10.3892/etm.2022.11578

Abstract. The overall incidence of rectal gastrointestinal stromal tumor (RGIST) has risen, but it remains a rare disease. Furthermore, tumor rupture is associated with poor prognosis. The present study reported a rare case of RGIST with indolent biological behavior. The biological behavior of this RGIST was analyzed and its malignant potential was evaluated using a guideline-based risk stratification assessment. The patient was diagnosed with a rectal tumor at the Third Affiliated Hospital of Qiqihar Medical University (Qiqihar, China) in April 2020 and a partial resection biopsy was then performed. This resection counts as a rupture. The biopsy confirmed RGIST and the patient refused further examination and treatment due to economic concerns. However, the patient survives with no tumor progression and metastasis until now, May 2022. In conclusion, based on the present case, tumor rupture in indolent RGIST is not necessarily associated with poor outcome.

Introduction

Gastrointestinal stromal tumor (GIST) accounts for 0.1-3% of all GI tumors (1). This type of tumor may occur in any part of the digestive tract but is most common in the stomach (~60% of cases) and least common in the rectum (~5% of cases) (2,3). The incidence of GISTs among all types of rectal malignancies is as low as 0.6% (4). GISTs are different from other mesenchymal tissue-derived tumors. Approximately 90% of them highly express CD117, as indicated by immunohistochemical staining (5). In terms of morphology, ~70% of GISTs are spindle cell tumors, 20% are epithelioid cell tumors and 10% are mixed cell type tumors (6). In recent years, rectal GISTs (RGISTs) have exhibited certain potential malignant features, and they are characterized by easy relapse following treatment; therefore, RGIST has a poorer prognosis compared with gastric GIST (7). The recently confirmed anorectal GIST cases had a local recurrence rate of 50% (8). Even among patients receiving imatinib treatment, the ratio of RGIST recurrence may still reach 1/3 (9).

The risk stratification assessment results of GIST are closely related to patient prognosis. Globally influential guidelines were retrospectively searched, and search strategies and screening strategies are provided in Supplementary Materials 1 and 2. There is a comprehensive consensus on using tumor size, mitotic index (MI) and anatomical site as optimal parameters for the risk stratification assessment of GIST (10-15). In recent years, the impact of tumor rupture on the risk assessment and prognosis of GIST has been reported several times, but the use of GIST rupture as an independent predictor of prognosis remains controversial (12,16-21). The globally influential National Institutes of Health (NIH) 2008 guidelines included tumor rupture as an independent indicator for the risk assessment of GIST, and it has been proposed that, as long as the tumor ruptures, regardless of tumor size and MI, it is regarded as high risk (12). However, numerous influential studies had limitations, including insufficient sample size of ruptured GISTs (16-21), making it difficult to evaluate the significance of GIST rupture.

Using certain guidelines or prognostic evaluation models, due to the limited sample size of RGIST, its malignant potential and biological behavior cannot be accurately evaluated, which has become a limitation of research (11,16,17). In certain recent guidelines, total area of 5 mm^2 has replaced 50 high-power microscopic fields (HPF) as the assessment area of the MI, but it is not a worldwide consensus (10-15). The prognosis may reflect the biological behavior of RGIST to a certain extent. The European Society for Medical Oncology

Correspondence to: Professor Shi Liu, Central Laboratory, The Third Affiliated Hospital of Qiqihar Medical University, 27 Taishun Street, Tiefeng, Qiqihar, Heilongjiang 161000, P.R. China
E-mail: shiliu2199@163.com

Abbreviations: AFIP, Armed Forces Institute of Pathology; HPF, high-power microscopic fields; MI, mitotic index; NIH, National Institutes of Health; NCCN, National Comprehensive Cancer Network; RGIST, rectal gastrointestinal stromal tumor; UICC, International Union Against Cancer; WHO, World Health Organization

Key words: rectal gastrointestinal stromal tumor, tumor rupture, risk assessment, prognosis, case report

(ESMO) 2022 guidelines pointed out that gene sequencing is the class I evidence for the prognosis of GIST and recommends it as a routine examination in outpatient clinics (10). However, real-world evidence has suggested that gene sequencing is unavailable in several areas due to its high cost. In China, it is difficult for a patient with GIST to receive standardized diagnosis and treatment in most primary hospitals, due to the absence of a sufficient understanding of GIST until the first clinical guidelines for GISTs were released in August 2020 (22).

In the present case report, the biological behavior and malignant potential of ruptured RGIST was analyzed according to the guidelines' risk stratification assessment criteria. The aim of the present study was to provide case-based evidence for future clinical research in this field.

Case report

A 59-year-old male patient visited The Third Affiliated Hospital of Qiqihar Medical University (Qiqihar, China) in April 2020, complaining of incomplete obstruction in defecating for 1 year. Incomplete obstruction is consistent with the patient's symptoms: The patient had a sense of not being clean, and a change in bowel habits with an increased stool frequency (3/4 times a day); no change in the total stool volume over 24 h, and a decrease in a single stool volume than before. While there was no blood in the stools, abdominal pain, bloating or diarrhea, and flatus was normal. The patient's diet, sleep and urine were normal, and the patient's body weight had not significantly decreased. The patient had no other complaints except for the incomplete obstruction in defecating. The patient had no history of any past illness.

In terms of physical examination, no obvious mass in the abdomen indicated by abdominal palpation. Digital rectal examination revealed a large mass in the front wall of the rectum ~20 mm from the anus. The rectal mass was pliable but strong, the base was wide, the uppermost part was out of reach and mobility was poor, but the rectal mucosa was smooth and there was no blood staining on the fingers, indicating a rectal space-occupying lesion.

From the laboratory examination, the patient's blood, biochemistry, urine and stools were indicated to be normal. Serum tumor markers were normal [total prostate-specific antigen 0.47 ng/ml (reference range, 0-4.0 ng/ml); carcinoembryonic antigen 1.27 ng/ml (reference range, 0-5.0 ng/ml); a-fetoprotein 4.09 ng/ml (reference range, 0-20.0 ng/ml); carbohydrate antigen-199 4.1 U/ml (reference range, 0-37.0 U/ml); all items were within the reference range] (23-25).

In terms of imaging examinations, the patient underwent colonoscopy. A rectal mass was found 20 mm from the patient's anal margin. The tumor surface was smooth, the border was clear and there was no ulceration or bleeding on it, indicating a rectal submucosal tumor (Fig. 1). Subsequently, the patient was admitted to the hospital for further examination. The tumor exhibited an exogenous growth tendency on the contrast-enhanced computed tomography (CT) scan and its maximum diameter was 53 mm. The seminal vesicles, prostate and levator ani muscle were being squeezed by the tumor, which was suspected the possibility of malignancy initially due to the tumor is poorly demarcated from surrounding tissue (Fig. 2). On contrast-enhanced magnetic resonance imaging (MRI), the tumor was unevenly enhanced in the arterial phase and it had a rich blood supply. The tumor had a high signal on the diffusion-weighted imaging scan and exhibited certain necrotic foci inside, but there was no regional lymphadenopathy (Fig. 3), which also indicated the possibility of a malignancy. There were no abnormalities in the head and chest CT.

In terms of biopsy, the patient was recommended to go to a higher-level hospital, since endoscopic ultrasound and multi-core needle examination were unavailable at our hospital. The patient did not follow the recommendation and asked for a definitive diagnosis. Therefore, a tissue excision biopsy was performed. The tumor tissue was soft and gray-white. A total of three tumor tissue specimens (from two regions, near the anal opening and the anterior wall of the rectum) were excised; each tumor tissue volume was ~0.5 cm^3, with the total volume being 1.5x1x1 cm (1.5 cm^3). H&E staining and immunohistochemistry were performed at The Pathology Center of Qiqihar Medical University (Qiqihar, China). Specimens were fixed in 10% formalin at 20˚C for 12 h, sectioned at a thickness of 5 μm and stained with hematoxylin for 10 min and eosin for 20 sec at 20˚C. Under the microscope, the spindle cells were observed to be densely arranged and uniform in shape. The nuclei were arranged in a palisade shape, there were vacuoles next to the nucleus and mitotic figures of 2 nuclei were able to be observed under the microscope at a magnification of x200 (Fig. 4). For immunohistochemistry, specimens were fixed in 10% formalin at 20˚C for 12 h, sectioned at a thickness of 5 μm and followed by dewaxing, rehydration and high-pressure antigen retrieval. Subsequently, they were blocked with 5% normal goat serum (Beyotime Institute of Biotechnology) for 1 h at room temperature. Samples were incubated with the primary antibody overnight at 4˚C and with the secondary antibody for 1 h at room temperature. The corresponding antibodies used in the experiments are listed in Table I. Finally, the sections were sealed with neutral gum after staining and the results were observed under a microscope. The immunohistochemistry findings were as follows: CD117(+); the staining was located in the cytoplasm/membrane and the positive rate was 80-100%. Dog-1 (Discovered On GISTs Protein 1) (+), whose staining was located at the membrane/plasma, is a GIST-specific antibody and was diffusely positive. CD34(+), whose staining was located in the cell membrane, had a positive rate of 50-80%. Ki67 (1%), whose staining was located in the nucleus, was used to reflect the proliferative activity of GIST and had a positive rate of 1% (Fig. 5). The histology of the biopsy specimen confirmed RGIST and immunohistochemistry suggested the possibility of receptor tyrosine kinase (KIT) gene mutation. KIT is also known as CD117, and the vast majority of CD117-positive GISTs contain 70-80% of KIT mutations (26).

The RGIST was diagnosed as high risk, according to the 2008 revised National Institutes of Health (NIH) Guidelines (12). A multidisciplinary treatment group was involved in this assessment and the final recommendation was genetic testing followed by preoperative oral imatinib therapy. Abdominoperineal resection or TransAnal Minimally

Invasive Surgery (TAMIS) would be performed according to the tumor response to imatinib. However, the patient refused further examination and treatment due to economic concerns.

The patient was followed up by telephone every 6 months, and the total follow-up time was 2 years. Abdominal CT (from April 2020 to May 2022) suggested that the tumor had shrunk and no lymph node metastasis was found in the lateral rectum, obturator foramen or groin area (Fig. 6). The head and chest CT identified no abnormalities. Furthermore, the patient exhibited no defecation difficulties, hematochezia or other complaints.

Discussion

The ESMO 2022 guidelines propose that radiographic changes in GIST should be considered as tumor reactivity, which indicates the potential of malignancy (10). Tumor size and density may be used as indicators of GIST responsiveness (10). The response of this GIST was assessed using CT. As presented in Fig. 5, the tumor was smaller than previously (April 2020); considering that the tumor tissue had been partially resected during the biopsy, the tumor volume was evaluated as not increased and the density of this RGIST was consistent during follow-up. Therefore, according to the ESMO 2022 guidelines, in the present case, the ruptured RGIST was judged as not having progressed. Furthermore, there was no evidence of metastasis during the follow-ups, indicating that the patient achieved a 2-year progression-free survival (PFS).

Tumor rupture was defined in the ESMO 2022 guidelines as intra-abdominal tumor spillage or fracture, segmental resection, laparoscopic/open incision biopsy, abdominal gastrointestinal perforation, bloody ascites or microscopic transperitoneal infiltrate into adjacent structures (10). The RGIST of the present case was biopsied by an open incision so was considered a tumor rupture. Although there are certain influential guidelines and consensuses supporting the link between tumor rupture and poor prognosis (10,12), whether tumor rupture may be an independent risk factor for the prognosis of GIST remains controversial (16-21). Since tumor rupture is a rare event, the number of cases is not sufficient to meet the inclusion criteria of clinical studies (16,17).

The risk assessment staging of RGIST directly affects the treatment options and prognostic benefits for patients. In the present case, the patient achieved a 2-year PFS with tumor rupture, suggesting that the RGIST is a tumor with indolent biological behavior. However, it was rated as high risk according to the NIH 2008 guidelines, which is clearly inconsistent with its indolent biological behavior. In order to explore the reasons for indolent biological behavior of the RGIST, a review of the main global guidelines was performed, followed by a comprehensive risk assessment of the RGIST in this case. All risk assessment systems (the latest revisions) used in the present study are listed in Tables SI-V. These assessment systems have a comprehensive consensus on using tumor size, MI and anatomical site as the best parameters for GIST risk stratification assessment (11-15). At present, the authority of the NIH 2008 guidelines on the risk stratification assessment of GIST is recognized worldwide, but it appears to not provide a good explanation for the indolent biological behavior of RGIST in the present case. The study by Joensuu *et al* (16) from 2012 suggested that the identification of mitosis is subjective; the number detected depends on the fixation time of the tissue and the size of the microscopic field, which may affect staging. Mitotic counts are probably best based on per 5 mm^2 of tumor tissue, rather than per 50 HPF. Certain recent guidelines have agreed with this (Table SI-V). Guidelines developed in earlier years used per 50 HPF as the assessment area [including Armed Forces Institute of Pathology guidelines (AFIP) 2006 guidelines (Table SI) and NIH 2008 guidelines (Table SII)], and the guidelines in recent years gradually replaced per 50 HPF with per 5 mm^2 [including International Union Against Cancer (UICC) 2016 guidelines (Table SIII) and World Health Organization (WHO) 2020 guidelines (Table SIV)]. The change in the assessment area mentioned in the WHO 2020 guidelines helps to standardize the calculation of the true area of mitosis, since different microscopes have different sizes of high-power fields. ESMO 2022 guidelines also argue that using per 5 mm^2 as the assessment area may avoid variability. Although the National Comprehensive Cancer Network (NCCN) 2022 guidelines (Table SV) do not change the assessment area of MI, this is enough to indicate that the risk assessment system of GIST has been gradually perfected. Whether there are assessment indicators could be updated to optimize the existing RGIST risk assessment system needs to be confirmed by further research.

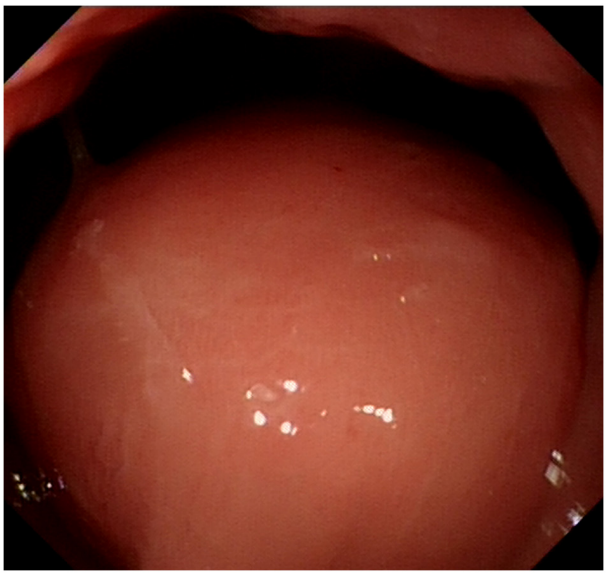

Figure 1. Fiber colonoscopy. The rectal gastrointestinal stromal tumor was large and protruded into the intestinal cavity.

Therefore, the RGIST of the present case was evaluated using per 50 HPF or 5 mm^2 as the assessment area for the MI according to the guidelines. Using per 50 HPF as the assessment area for the MI, the RGIST in this case was rated as stage III intermediate malignant potential using the AFIP guidelines from 2006 (Table SI) (11), stage IV high risk using the revised NIH guidelines from 2008 (Table SII) (12) and moderate risk using the NCCN guidelines from 2022 with a metastasis probability rate of 24% (Table SV) (15). For the present case, two pathologists reassessed the MI as 2/5 mm^2. Using per 5 mm^2 as the assessment area for the MI, the

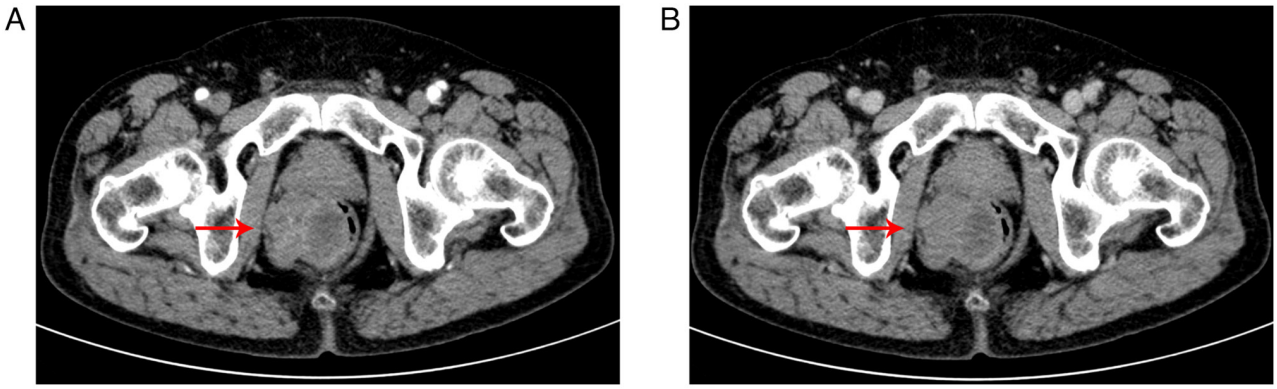

Figure 2. Contrast-enhanced CT. (A) Arterial phase of enhanced abdominal CT. (B) Venous phase of enhanced abdominal CT. The red arrow points at tumor. CT, computed tomography.

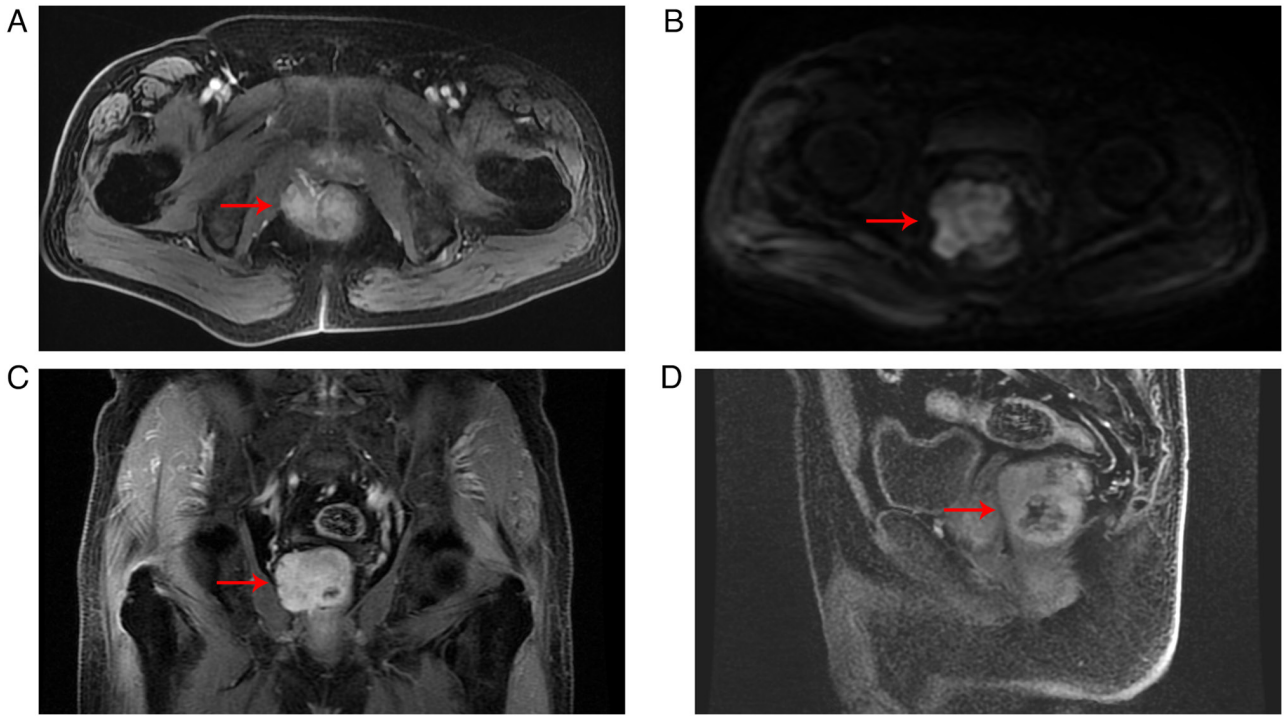

Figure 3. Contrast-enhanced MRI. (A) Enhanced MRI showing the main blood supply of the tumor. (B) Diffusion-weighted imaging of the tumor. (C) Enhanced MRI of the tumor in the coronal plane. (D) Enhanced MRI of the tumor in the sagittal plane. The red arrow points at tumor. MRI, magnetic resonance imaging.

RGIST was rated as stage II intermediate malignant potential according to the UICC 2016 guidelines (Table SIII) (13) and stage I benign according to the WHO guidelines from 2020 (Table SIV) (14). In conclusion, the RGIST was rated as intermediate risk by category 2 guidelines and high risk by category 1 guidelines before the MI was adjusted. After adjusting for the MI, RGIST was assessed as intermediate risk by category 1 guidelines and benign by category 1 guidelines. The ruptured RGIST in the present case was evaluated using different guidelines with different risk stratification results, and it was only rated as high risk according to the NIH 2008 guidelines. In the present study, the WHO 2020 guidelines were used to evaluate the indolent biological behavior of the RGIST, as the RGIST was not progressing following rupture. Furthermore, the present case reflected the significant heterogeneity in the results of RGIST assessment based on different guidelines, indicating that this case was a rare one.

The RGIST in the present case underwent iatrogenic rupture, which belongs to involuntary rupture in biological behavior, which is different from spontaneous rupture; since GIST originates from mesenchymal tissue, spontaneously ruptured GIST requires to break through the surrounding gastrointestinal wall first, which suggests that the ruptured GIST is more aggressive and has malignant potential. Furthermore, the present case suggested that our understanding of the malignant potential and biological behavior of GIST is not sufficient and further research is required to prove whether there are other independent optimal parameters that may be included in the risk assessment of GIST. Based on guidelines and patient prognostic assessments, it is valid for indolent or low-grade GIST to be diagnosed. The evidence in the present

Table I. Primary and secondary monoclonal antibodies used for immunohistochemical analysis.

Antibody	Supplier	Dilution ratio	Species raised in	Catalogue number
CD117	Cell Signaling Technology	1/100	Rabbit	37805S
Dog-1	Cell Signaling Technology	1/100	Mouse	54598S
CD34	Cell Signaling Technology	1/50	Mouse	3569S
Ki67	Cell Signaling Technology	1/1000	Mouse	9449S
Anti-rabbit IgG HRP	Beyotime Institute of Biotechnology	1/50	Rabbit	A0208
Anti-mouse IgG HRP	Beyotime Institute of Biotechnology	1/50	Mouse	A0216

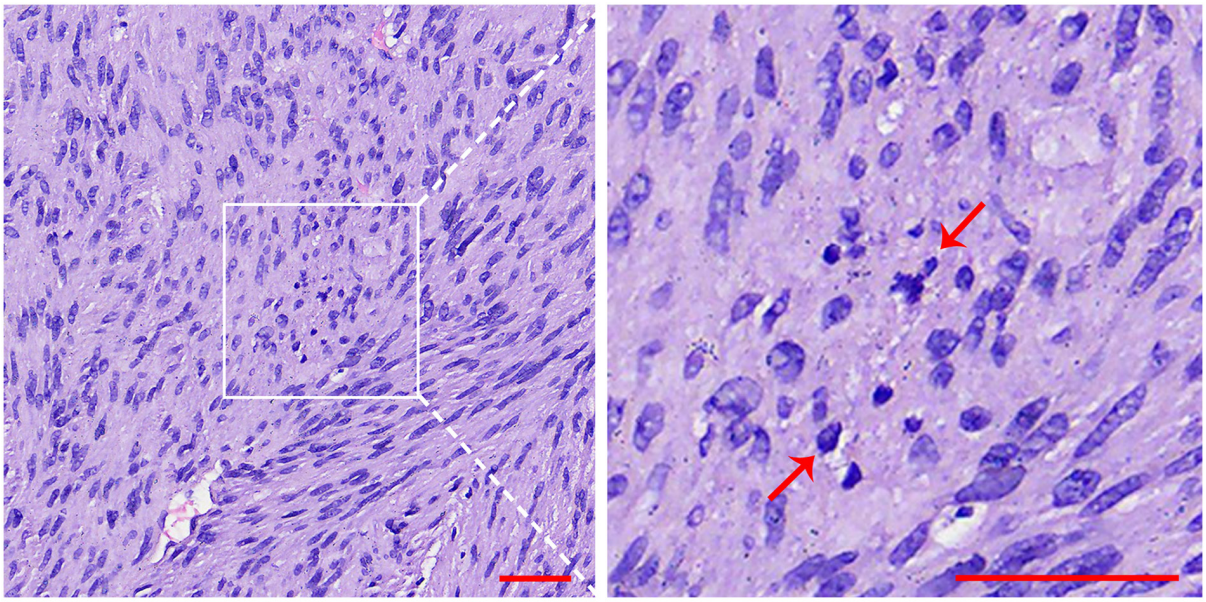

Figure 4. Pathological section. The right figure is a magnified window from the left image. Cell mitosis, 2/50 high-power microscopic fields (H&E staining; magnification, x200; scale bars, 50 μm). The red arrow points at cell mitosis.

case indicated that it may not be appropriate for indolent RGIST that tumor rupture increases the risk of poor prognosis. Further clinical trials are required in order to demonstrate that the worsening of the prognosis associated with tumor rupture applies to different tumor types (high-risk or indolent). In the future, prospective multicenter cohort studies or randomized controlled trials may be performed to compare the survival outcomes (overall survival, PFS and recurrence-free survival) between ruptured and non-ruptured RGISTs, so as to provide clinical ideas for perfecting the risk assessment system for RGIST.

The ESMO 2022 guidelines explicitly propose genetic sequencing as a class I evidence of prognostic relevance for GIST (10). For instance, GISTs with platelet-derived growth factor receptor A mutations corresponding to D842V are generally associated with a favorable prognosis (10). By contrast, GIST deletions at codons 557-558 of KIT exon 11 are associated with a higher risk of recurrence (27). In the present case, gene sequencing was not performed. However, the pathological evidence was sufficient and the immunohistochemical results were consistent with the diagnosis of RGIST. The indolent biological behavior of this RGIST may be related to the genotype, which requires further examination and verification after obtaining the patient's consent. In recent years, Ki67 has been repeatedly reported to be associated with the prognosis of GIST (28), but the opposite opinion can be found in the ESMO 2022 guidelines and Ki67 is not part of the established prognostic assessment system for GISTs. Further research is required to resolve this controversy.

The major limitations of the present case are the iatrogenic rupture of the tumor and the refusal of the patient to receive further treatment due to economic concerns, which is a real-world problem. The doctors in primary hospitals were lacking a comprehensive understanding of the standardized diagnosis and treatment of GIST until the release of the first Chinese GIST guidelines in August 2020 (22). Gene sequencing is expensive and thus difficult to perform in the real world, even though it is recommended as a routine checkup item in outpatient clinics in the ESMO 2022 guidelines (10).

If economic issues are not considered, the standardized management for patients is as follows: Gene sequencing is performed first to identify preoperative chemotherapy drugs (e.g., imatinib), adjuvant therapy is administered for at least 6 months (15) and the response is assessed every

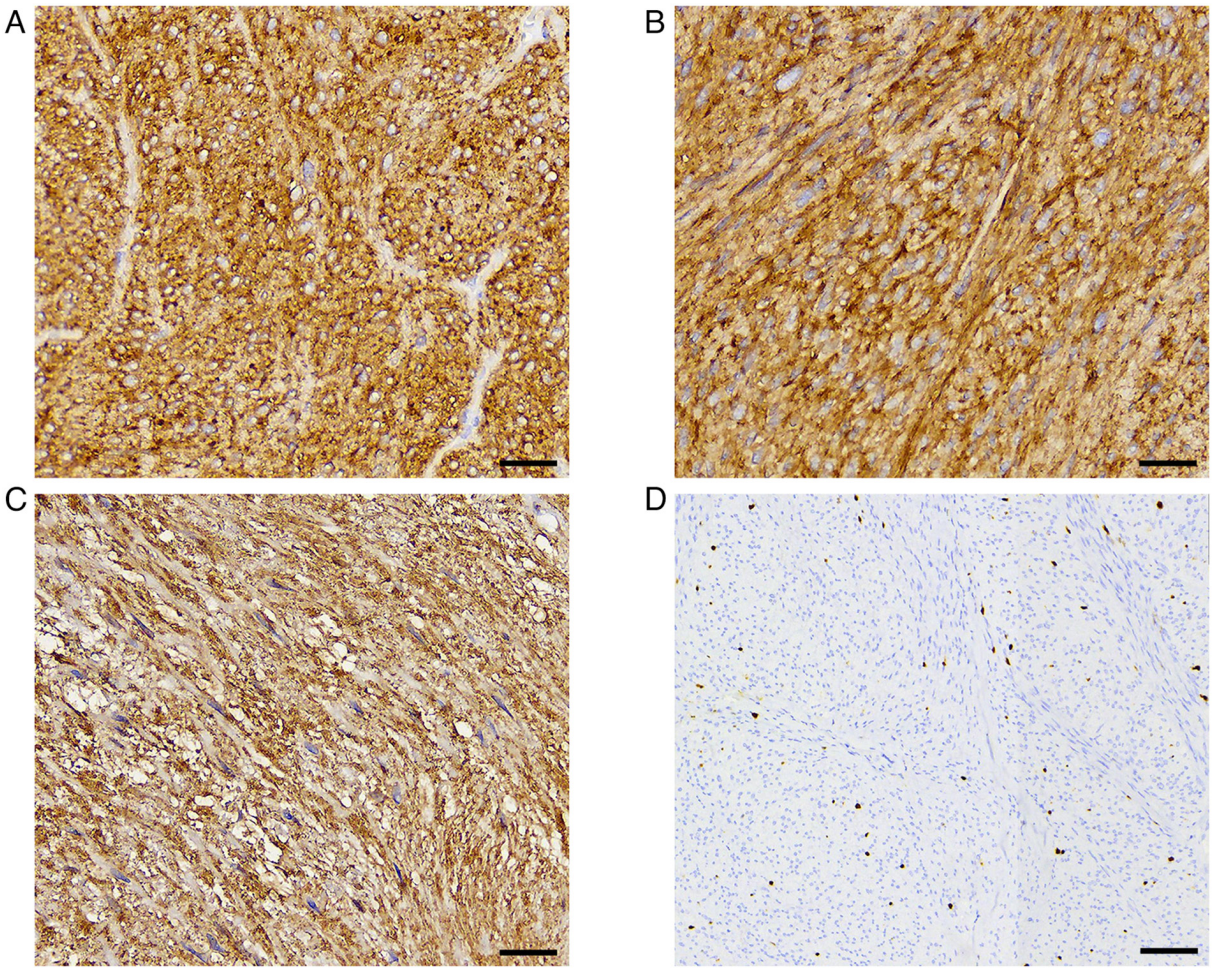

Figure 5. Immunohistochemistry indicating (A) CD117(+), (B) Dog-1(+), (C) CD34(+) and (D) Ki67 (1%) (magnification, x400; scale bars, 25 μm).

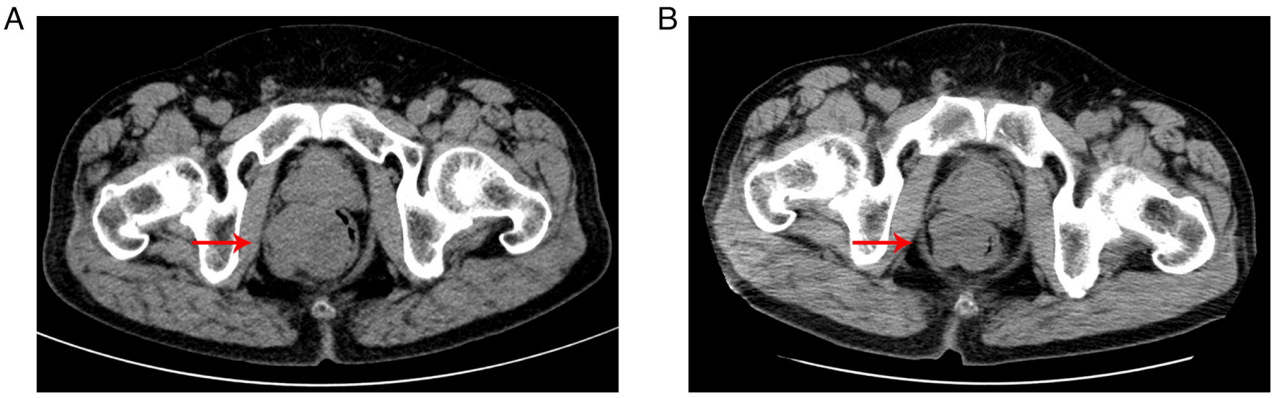

Figure 6. CT. (A) CT in April 2020. (B) Review CT in May 2022. The red arrow points at tumor. CT, computed tomography.

3-6 months (10). It is recommended to perform R0 resection by transanal endoscopic microsurgery or TAMIS (29), and apply postoperative adjuvant chemotherapy (e.g., imatinib) for at least 3 years (30), with routine follow-up of abdominal CT or MRI every 3-6 months. In most parts of the world, it is not uncommon for patients not undergo standardized diagnosis and treatment due to financial constraints. Therefore, more real-world-based health economics in clinical research are required in order to provide more evidence-based guidelines for the rational allocation and utilization of medical resources and maximize patients' benefits of medical care.

In conclusion, based on the present case, it may not be possible to assume that for indolent RGIST, tumor rupture worsens the prognosis, the confirmation of which may require further clinical trials. Furthermore, this rare case may be able to contribute to perfecting the risk assessment system of RGIST.

Acknowledgements

The authors would like to thank Professor Zhong-Yan Wang and Professor Xue-Feng Bai (Department of Anorectal Surgery, The Third Affiliated Hospital of Qiqihar Medical University, Qiqihar, China), for their contribution during surgery and patient management.

Funding

No funding was received.

Availability of data and materials

The datasets used and/or analyzed during the current study are available from the corresponding author on reasonable request.

Authors' contributions

JY contributed to the conception and design of the study, acquisition of data, analysis and interpretation of data and manuscript drafting. YL contributed to manuscript drafting and acquisition of data. XJS analyzed and interpreted the imaging findings. ZWA analyzed and interpreted the pathological and immunohistochemical findings. SL contributed to the analysis and interpretation of data and reviewed and edited the manuscript. SL and JY confirm the authenticity of all the raw data. All authors have read and approved the final manuscript.

Ethics approval and consent to participate

Not applicable.

Patient consent for publication

The patient provided written informed consent for the treatment interventions, images, data collection and submission of this article for publication.

Competing interests

The authors declare that they have no competing interests.

References

1. Bucher P, Villiger P, Egger JF, Buhler LH and Morel P: Management of gastrointestinal stromal tumors: From diagnosis to treatment. Swiss Med Wkly 134: 145-153, 2004.
2. Kameyama H, Kanda T, Tajima Y, Shimada Y, Ichikawa H, Hanyu T, Ishikawa T and Wakai T: Management of rectal gastrointestinal stromal tumor. Transl Gastroenterol Hepatol 3: 8, 2018.
3. Ulanja MB, Rishi M, Beutler BD, Konam KG, Ambika S, Hinojosa T, Djankpa FT, Yang W and Gullapalli N: Racial disparity in incidence and survival for gastrointestinal stromal tumors (GISTs): An analysis of SEER database. J Racial Ethn Health Disparities 6: 1035-1043, 2019.
4. Tran T, Davila JA and El-Serag HB: The epidemiology of malignant gastrointestinal stromal tumors: An analysis of 1,458 cases from 1992 to 2000. Am J Gastroenterol 100: 162-168, 2005.
5. Fletcher CD, Berman JJ, Corless C, Gorstein F, Lasota J, Longley BJ, Miettinen M, O'Leary TJ, Remotti H, Rubin BP, *et al*: Diagnosis of gastrointestinal stromal tumors: A consensus approach. Int J Surg Pathol 10: 81-89, 2002.
6. Marrari A, Wagner AJ and Hornick JL: Predictors of response to targeted therapies for gastrointestinal stromal tumors. Arch Pathol Lab Med 136: 483-489, 2012.
7. Cavnar MJ, Seier K, Curtin C, Balachandran VP, Coit DG, Yoon SS, Crago AM, Strong VE, Tap WD, Gönen M, *et al*: Outcome of 1000 patients with gastrointestinal stromal tumor (GIST) treated by surgery in the pre- and post-imatinib Eras. Ann Surg 273: 128-138, 2021.
8. Agaimy A, Vassos N, Märkl B, Meidenbauer N, Köhler J, Spatz J, Hohenberger W, Haller F, Croner RS, Schneider-Stock R and Matzel K: Anorectal gastrointestinal stromal tumors: A retrospective multicenter analysis of 15 cases emphasizing their high local recurrence rate and the need for standardized therapeutic approach. Int J Colorectal Dis 28: 1057-1064, 2013.
9. Stuart E, Banerjee S, de la Torre J, Wang Y, Scherzer N, Burgoyne AM, Parry L, Fanta PT, Ramamoorthy S and Sicklick JK: Frequent rectal gastrointestinal stromal tumor recurrences in the imatinib era: Retrospective analysis of an International patient registry. J Surg Oncol 120: 715-721, 2019.
10. Casali PG, Blay JY, Abecassis N, Bajpai J, Bauer S, Biagini R, Bielack S, Bonvalot S, Boukovinas I, Bovee JVMG, *et al*: Gastrointestinal stromal tumours: ESMO-EURACAN-GENTURIS clinical practice guidelines for diagnosis, treatment and follow-up. Ann Oncol 33: 20-33, 2022.
11. Miettinen M and Lasota J: Gastrointestinal stromal tumors: Review on morphology, molecular pathology, prognosis, and differential diagnosis. Arch Pathol Lab Med 130: 1466-1478, 2006.
12. Joensuu H: Risk stratification of patients diagnosed with gastrointestinal stromal tumor. Hum Pathol 39: 1411-1419, 2008.
13. Brierley JD, Gospodarowicz MK and Wittekind C (eds.): Gastrointestinal Stromal Tumour (GIST). In: TNM Classification of Malignant Tumours. 8th edition. Union for International Cancer Control (UICC), Wiley Blackwell, New York, USA, pp 127-130, 2016.
14. Dei Tos AP, Hornick JL, Miettinen M, Wanless IR, Wardelmann E: Gastrointestinal stromal tumour. In: Digestive System Tumours WHO Classification of Tumours. Fukuyama M, Goldblum JR, Miettinen M and Lazar AJ (eds.). 5th edition. WHO, Geneva, Austria, pp 439-443, 2019.
15. National Comprehensive Cancer Network guidelines: NCCN Guidelines Version 1: 2022 Gastrointestinal Stromal Tumors (GISTs). https://www.nccn.org/guidelines/guidelines-detail?category=1&id=1507. Accessed August 25, 2022.
16. Joensuu H, Vehtari A, Riihimäki J, Nishida T, Steigen SE, Brabec P, Plank L, Nilsson B, Cirilli C, Braconi C, *et al*: Risk of recurrence of gastrointestinal stromal tumour after surgery: An analysis of pooled population-based cohorts. Lancet Oncol 13: 265-274, 2012.
17. Gold JS, Gönen M, Gutiérrez A, Broto JM, García-del-Muro X, Smyrk TC, Maki RG, Singer S, Brennan MF, Antonescu CR, *et al*: Development and validation of a prognostic nomogram for recurrence-free survival after complete surgical resection of localised primary gastrointestinal stromal tumour: A retrospective analysis. Lancet Oncol 10: 1045-1052, 2009.
18. Rutkowski P, Bylina E, Wozniak A, Nowecki ZI, Osuch C, Matlok M, Switaj T, Michej W, Wroński M, Głuszek S, *et al*: Validation of the Joensuu risk criteria for primary resectable gastrointestinal stromal tumour-the impact of tumour rupture on patient outcomes. Eur J Surg Oncol 37: 890-896, 2011.
19. Rutkowski P, Nowecki ZI, Michej W, Debiec-Rychter M, Woźniak A, Limon J, Siedlecki J, Grzesiakowska U, Kakol M, Osuch C, *et al*: Risk criteria and prognostic factors for predicting recurrences after resection of primary gastrointestinal stromal tumor. Ann Surg Oncol 14: 2018-2027, 2007.
20. Takahashi T, Nakajima K, Nishitani A, Souma Y, Hirota S, Sawa Y and Nishida T: An enhanced risk-group stratification system for more practical prognostication of clinically malignant gastrointestinal stromal tumors. Int J Clin Oncol 12: 369-374, 2007.
21. Hohenberger P, Ronellenfitsch U, Oladeji O, Pink D, Ströbel P, Wardelmann E and Reichardt P: Pattern of recurrence in patients with ruptured primary gastrointestinal stromal tumour. Br J Surg 97: 1854-1859, 2010.
22. Cao H and Wang M: Act following etiquette and change with time: Analysis and discussion on the difference between the current guidelines and clinical practice of gastrointestinal stromal tumor. Zhonghua Wei Chang Wai Ke Za Zhi 24: 749-757, 2021 (In Chinese).

23. Fujii T, Shimada K, Tanaka N, Fujimoto K and Konishi N: Phyllodes tumor of the prostate. Pathol Int 62: 204-208, 2012.
24. Cheng Y, Chen D, Shi L, Yang W, Sang Y, Duan S and Chen Y: Surgical treatment of an esophageal bronchogenic cyst with massive upper digestive tract hematoma without esophagectomy: A case report and the review of the literature. Ther Clin Risk Manag 14: 699-707, 2018.
25. Lin HH, Chang CC, Yang SH, Chang SC, Chen WS, Liang WY, Lin JK and Jiang JK: Elevated serum alpha-fetoprotein in poorly differentiated adenocarcinoma with neuroendocrine differentiation of the ascending colon: A case report. World J Surg Oncol 14: 84, 2016.
26. Corless CL, Barnett CM and Heinrich MC: Gastrointestinal stromal tumours: Origin and molecular oncology. Nat Rev Cancer 11: 865-878, 2011.
27. Wozniak A, Rutkowski P, Schöffski P, Ray-Coquard I, Hostein I, Schildhaus HU, Le Cesne A, Bylina E, Limon J, Blay JY, *et al*: Tumor genotype is an independent prognostic factor in primary gastrointestinal stromal tumors of gastric origin: A european multicenter analysis based on ConticaGIST. Clin Cancer Res 20: 6105-6116, 2014.
28. Pyo JS, Kang G and Sohn JH: Ki-67 labeling index can be used as a prognostic marker in gastrointestinal stromal tumor: A systematic review and meta-analysis. Int J Biol Markers 31: e204-e210, 2016.
29. Hawkins AT, Wells KO, Krishnamurty DM, Hunt SR, Mutch MG, Glasgow SC, Wise PE and Silviera ML: Preoperative chemotherapy and survival for large anorectal gastrointestinal stromal tumors: A National analysis of 333 cases. Ann Surg Oncol 24: 1195-1201, 2017.
30. Joensuu H, Eriksson M, Sundby Hall K, Reichardt A, Hartmann JT, Pink D, Ramadori G, Hohenberger P, Al-Batran SE, Schlemmer M, *et al*: Adjuvant imatinib for high-risk GI stromal tumor: Analysis of a randomized trial. J Clin Oncol 34: 244-250, 2016.