Ataxia with oculomotor apraxia type 1 associated with mutation in the *APTX* gene: A case study and literature review

RAIDAH ALBARADIE[1], ALANOUD ALHARBI[1], GADA ALSAFFAR[1], BAYADER ALHAMAD[1] and SHAHID BASHIR[2]

[1]Department of Pediatric Neurology, Neuroscience Center; [2]Neuroscience Center, King Fahad Specialist Hospital Dammam, Dammam 31444, Saudi Arabia

Received March 22, 2022; Accepted August 24, 2022

DOI: 10.3892/etm.2022.11645

Abstract. Cerebellar ataxia is a disorder characterized by a broad spectrum of phenotypes. Ataxia with oculomotor apraxia type 1 (AOA1) is an autosomal recessive disease presenting with early-onset and slowly progressing cerebellar ataxia, areflexia and peripheral axonal neuropathy. Mutations in the *APTX* gene c.751C>T p.(His251Tyr) were detected with probable homozygosity in the *APTX* gene (chromosome 9) that encodes a nuclear protein called aprataxin that is involved in DNA repair. AOA1 also contributes to neuronal development and function. Ocular apraxia is most prominent in the early stages of the disease, while hypoalbuminemia, hypercholesterolemia and cognitive impairment are common symptoms in the adult stage. The present study reported the clinical features of an 8-year-old female patient with mutations in the *APTX* gene and discussed the differential diagnosis from other forms of hereditary ataxia.

Introduction

Cerebellar ataxia is a progressive neurological disorder that is most frequently caused by inflammation or injury to the cerebellum. As the cerebellum regulates movement and muscular function, individuals with cerebellar ataxia often experience a lack of coordination and struggle to accomplish everyday chores. Ataxia with oculomotor apraxia type 1 (AOA1) is an autosomal recessive disease. It presents early in life and its symptoms include progressive cerebellar ataxia, oculomotor apraxia, dysarthria, peripheral axonal neuropathy and hypoalbuminemia (1).

Acquired ataxias may be transient or chronic and may be triggered by environmental (trauma or toxin exposure) or medical (infection, tumors or stroke) factors. Hereditary ataxias are heterogeneous, with causal mutations documented in >50 genes and inheritance patterns ranging from classical dominant to recessive, mitochondrial to X-linked (2). Of note, four genes have been implicated in the development of AOA (3). AOA1 is prevalent in Japanese and Portuguese populations (4). Mutations in the *APTX* gene are primarily responsible for AOA1 (5). This gene is located on chromosome 9p21. It encodes aprataxin and is involved in mitochondrial DNA repair through transcription regulation (5). Pathogenic variants of the *APTX* gene destabilize aprataxin and subsequently increase the effects of single-strand breaks in DNA, even when there are no apparent gross errors (6).

A total of 18 other mutations were identified as pathogenic variants of *APTX*; these mutations were found in 39 families (5). In the present case report, a patient with AOA1 is described, who had a novel homozygous missense mutation, His251Tyr, due to c.751 C>T substitution.

Case report

An eight-year-old female patient presented in 2021 at the pediatric neurology clinic of King Fahad Specialist Hospital Dammam (Dammam, Saudi Arabia) with progressive ataxia and an unsteady gait. The patient was the first child of healthy consanguineous parents. The patient had three healthy brothers and no family history of gait disturbances or neurological disorders. The patient's mother's pregnancy with the patient was uneventful and the patient was delivered at full term via normal vaginal delivery. The patient's birth weight was within the normal range and she was a healthy infant. The patient also achieved normal developmental milestones until the age of 14 months. The patient was able to sit without support at eight months of age and began walking at 14 months of age. The patient then began to experience imbalances during walking and recurrent falls. As the patient grew older, the patient's family noticed that the patient's ataxic gait was progressively worsening. The patient also subsequently presented with

Correspondence to: Dr Raidah Albaradie, Department of Pediatric Neurology, Neuroscience Center, King Fahad Specialist Hospital Dammam, Building 7, First Floor, Ammar Bin Thabit Street, Dammam 31444, Saudi Arabia
E-mail: Raidah.Baradi@kfsh.med.sa

Abbreviations: ARCA, autosomal recessive cerebellar ataxia; MRI, magnetic resonance imaging; NGS, next-generation sequencing; AOA, ataxia with oculomotor apraxia; CNV, copy number variation

Key words: ataxia with oculomotor apraxia type 1, aprataxin, homozygous, missense mutation

dysarthria and ataxic handwriting. A brief mental examination revealed that the patient performed normally at school and that the patient's cognitive function was normal. Prior to presentation, the patient was a healthy child with an unremarkable medical and surgical history. The patient had no history of recent infection, abnormal movements, visual or hearing difficulties, or developmental regression.

General examination revealed mild telangiectasia. The patient's growth parameters were within normal ranges, apart from the patient's head circumference, which was 50 cm below the 25th percentile. Motor examination revealed normal muscle bulk, tone and power bilaterally. The patient's deep tendon reflexes were +1 bilaterally in both the upper and lower extremities. Furthermore, the patient's Babinski reflex was bilaterally normal. Sensory examination results were also normal. An ocular examination revealed oculomotor apraxia. The patient had no nystagmus and the rest of the cranial nerves were unremarkable. A cerebellar examination revealed wide-based ataxic gait, head titubation, dysarthria, scanning speech, intention tremor, dysmetria and dysdiadochokinesia.

Brain magnetic resonance imaging (MRI) indicated diffused cerebellar atrophy (Fig. 1). No other brain parenchymal abnormalities were detected. Otherwise, the patient's MRI was unremarkable.

Laboratory analyses were performed to measure ammonia, lactate, albumin, lipid profile, immunoglobulins, alpha-fetoprotein, peripheral smear, serum vitamin E, serum and urine amino acids, serum and urine acylcarnitine, urine organic acids and fatty acids; all were normal and so were the patient's liver and renal function. The patient's audiological and ophthalmological examinations were also unremarkable.

Next-generation sequencing of 214 genes was performed using genomic DNA extracted from a blood sample using Human All Exon V6 (SureSelectXT Target Enrichment System for Illumina Paired-End Sequencing Library, version 1.3.1) (7). A variant of uncertain significance was identified; c.751C>T p.(His251Tyr) was detected with probable homozygosity in the *APTX* gene (chromosome 9). This variant of the *APTX* gene may be responsible for early-onset ataxia with oculomotor apraxia and hypoalbuminemia.

Discussion

Pathogenic variants of the *APTX* gene have been associated with early-onset ataxia. The present study reported on a rare case of an *APTX* gene mutation in an eight-year-old female patient. The patient was diagnosed with hereditary progressive ataxia. The identified variant, c.751C>T p.(His251Tyr) with probable homozygosity in the *APTX* gene (chromosome 9), was of uncertain significance. It is located in a highly conserved residue. This variant was detected with high confidence according to best practice guidelines (8,9). The following discussion explores the previously published literature on autosomal recessive cerebellar ataxias, with an emphasis on the *APTX* gene.

Autosomal recessive cerebellar ataxia (ARCA) is a set of disorders. ARCA subtypes related to AOA have recently been identified and classified into two major types: AOA1 and AOA2 (10). Mutations in the *APTX* gene may lead to ataxia, with oculomotor apraxia and hypoalbuminemia (11,12). Aprataxin, a member of the histidine triad family, is encoded by the *APTX* gene (10). It has been identified as the causal gene in ataxia-oculomotor apraxia syndrome in a different group of individuals with autosomal recessive inheritance.

Individuals of various ethnicities may have mutations in the *APTX* gene (4,10,13,14) (Table I). The most prevalent ARCA mutation in Japan is c.689 690insT; in Portugal, it is c.837G>A (15,16). Shimazaki *et al* (15) performed a sequencing analysis of the *APTX* gene in six patients from four Japanese families. Except for one patient with a sporadic mutation, all other patients had inherited the condition in an autosomal recessive manner. Furthermore, two patients had a novel homozygous missense mutation (c.80A>G). In one case, a missense compound heterozygous c.95C>T mutation led to the replacement of proline with leucine at amino acid position 32. Tranchant *et al* (16) found two variants of the *APTX* gene in three non-Portuguese and non-Japanese individuals. One of these patients had a nonsense W279X mutation; the other two patients were French siblings who carried a missense K197Q mutation and a compound heterozygous nonsense W279X mutation. Sekijima *et al* (11) reported 689 insT in the *APTX* gene in a 14-year-old female with severe generalized dystonia. Another study reported 14 patients with *APTX* gene mutations in nine families, including five novel variants in exons 5 and 6 (A198V, D267G, W279R and IVS5+1) (13). To screen for *APTX* mutations, Habeck *et al* (17) tested 165 patients with early-onset ataxia in Germany. Another genetic study of 13 patients from three unrelated Tunisian families with AOA1 identified mutations in the *APTX* gene (18). APTX exon 7 deletions were detected in a family with normal clinical presentation of AOA1 and no severe phenotypes. With AOA1, it is difficult to establish an association between genotype and phenotype, as symptoms vary among different families with the same mutation (18).

Recently, the *APTX* mutation c.484-2A>T was reported for the first time in a patient with Charcot-Marie-Tooth disease (19). Pedroso *et al* (20) described the case of a female patient with slow progressive gait impairment. Neurological tests revealed ocular motor apraxia and myoclonic jerks. AOA1 was verified by a homozygous mutation in the *APTX* gene (c.[837G>A];[837G>A]). In 2020, Ababneh *et al* (21) discovered a recurrent homozygous nonsense mutation (c.837G>A, p.W279*) in the *APTX* gene in three patients with AOA1. In a study of Palestinian and Israeli Arab families, WES identified a homozygous mutation, c.837G>A: p.(Trp279*), in a patient with speech and oculomotor apraxias and cerebellar ataxia (22).

Renaud *et al* (23) identified a p.Trp279 mutation in 53 patients with AOA1. In a consanguineous Iranian family with hereditary AOA1 (five affected and six unaffected individuals), WES revealed a novel homozygous stop-gain *APTX* gene mutation (c.739A>T; p.Lys247*) (3). Hirano *et al* (24) identified a homozygous two-base deletion in the middle of exon 3 of the *APTX* gene. Karimzadeh *et al* (25) reported a homozygous frameshift mutation, c.418_418 del, in the *APTX* gene. Complete homozygous deletion of *APTX* (62 kb) has also been reported in a patient with AOA1 (26). Deletion of exon 6 of *APTX* in an 18-year-old female was reported by Paucar *et al* (27). A new homozygous deletion in c.643 and an A>T single nucleotide polymorphism in c.641 in exon 6 were discovered in a seven-year-old pediatric

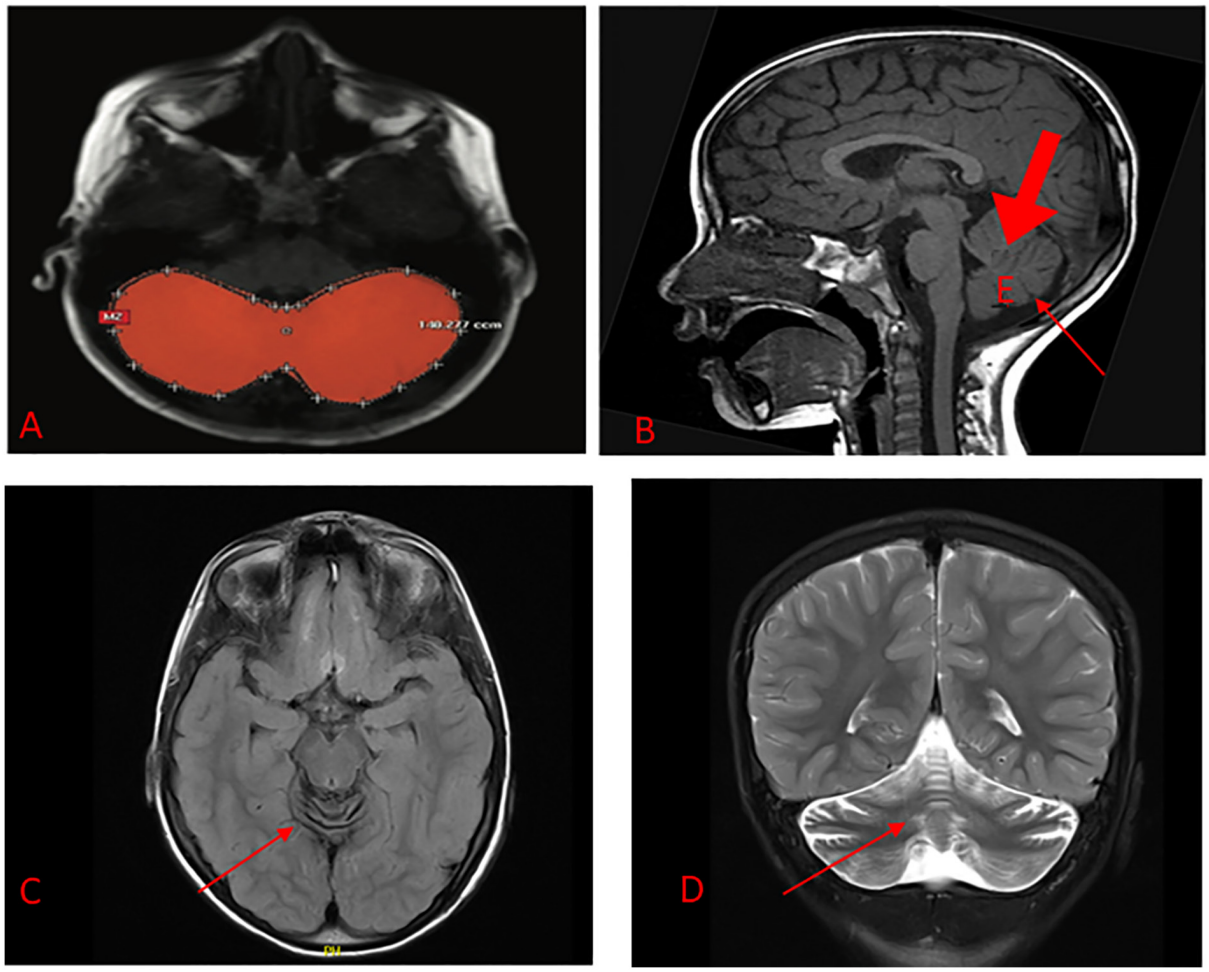

Figure 1. MRI images of the patient. (A) Axial MRI displaying cerebellar volume measurement; the red zone indicates the brain area. (B) Normal brain MRI of a sagittal view demonstrates normal vermis structures. (C) axial view and (D) coronal view demonstrate diffused cerebellar atrophy and vermian hypoplasia. Primary fissures (thick arrow) and pre-pyramidal fissures (thin arrow) are visible in the fastigium. (E) fastigium.

patient (28). Another study described a patient with a homozygous deletion of *APTX* and behavioral abnormalities (29). Castellotti *et al* (14) screened a large cohort and found variants of the *APTX* gene in 13 ataxic individuals (6%), 11 of whom were homozygous for the mutations p.W279X, p.W279R and p.P206L. They also observed three new mutations: c.477delC, c.C541T and c.C916T. A unique homozygous missense variant of *APTX* was discovered in a 34-year-old female patient born to consanguineous parents (30).

Although the above-mentioned studies provide valuable information about the likely function of *APTX* mutations in early-onset ataxia, genotype-phenotype correlations have not yet been clearly confirmed (18,31). In essence, while further research is required to establish the effect on the protein, a homozygous missense mutation, His251Tyr, caused by a c.751 C>T substitution in *APTX*, is probably deleterious for AOA1 in an autosomal recessive manner (32,33). Yokoseki *et al* (34) provided a comprehensive overview of this issue, finding that patients with the p.Pro206Leu or p.Val263Gly mutations had less gait disruption than those with the c.689 690insT mutations and that patients with the p.Pro206Leu or p.Val263Gly mutations had less gait disruption than those with the c.689 690insT mutations. In that study, patients with the c.689 690insT mutation exhibited a higher cumulative rate of inability to walk without assistance than those with the other mutations. Patients with p.Pro206Leu or p.Val263Gly mutations were found to have reduced ocular motor apraxia and no cognitive impairment, whereas patients with early-onset ataxia and hypoalbuminemia and the c.689 690insT mutation had more severe phenotypes. Those with the p.Pro206Leu or p.Val263Gly mutations presented with less ocular motor apraxia and no cognitive impairment, whereas patients with the c.689 690insT mutation had more severe symptoms, including early-onset ataxia and hypoalbuminemia (34).

Before drawing broad conclusions from the present study, it is necessary to recognize its limitations. The fact that the present study is a case study on a single patient means that various features of genotype-phenotype association may arise in other contexts. In addition, the present analysis is based on only exome sequencing data, which has constraints on its own. Future research should extend this area by using other methods for copy number variation detection, such as XHMM, CANOES and CLAMMS (35,36). Utilizing Sanger sequencing to validate the existence and homozygous condition of the variation will further reaffirm the conclusion of this report. In addition, it was not assessed whether the mutation was inherited, since no genetic testing was performed on any of the other family members because the parents refused further testing.

Table I. Comparative studies including clinical characteristics of previously reported cases.

First author, year	Number of patients	Region	Age of onset	Clinical features	Genes	(Refs.)
Moreira, 2001	15 families	Portugal and Japan	2-5 years	Early-onset ataxia, cerebellar atrophy, ocula-motor apraxia and hypoalbuminemia	Exon 5: c.617C>T; c.689dupT (689insT), (689-690insT); Exon 6: c.837G>A	(4)
Date, 2001	7 families	Japan	First or second decade of life	Progressive ataxia, areflexia, sensory loss and hypoalbuminemia	Exon 5: c.617C>T; c.689dupT (689insT), (689-690insT);Exon 6: c.788T>G; c.841delT	(10)
Castellotti, 2011	13	Italy	3-7 years	Ataxia, dysarthria, nystagmus, areflexia, sensory neuropathy	Exon 3: c.477delC Exon 4: c.C541T Exon 7: c.C916T	(14)
Shimazaki, 2002	5	Japan	3-12 years	Cerebellar ataxia, peripheral neuropathy, oculomotor apraxia, external ophthalmoplegia, choreiform movements, facial grimacing, mental deterioration, cerebellar atrophy, hypoalbuminemia, hypercholesterolemia	Exon 5: c.602A>G; c.617C>T; c.689dupT (689insT), (689-690insT)	(15)
Tranchant, 2003	3	France and Italy	2 years and 15-22 years	1st Italian patient: Progressive ataxia, areflexia, oculomotor apraxia, hypoalbuminemia and hypercholesterolemia; 2 French siblings: Later onset of ataxia, areflexia, dysarthria and dystonia	Exon 5: c.589A>C Exon 6: c.837G>A	(16)
Le Ber, 2003	14	France (7 families), Italy (1 family) and Algeria (1 family)	2-18 years	Gait ataxia, chorea, dystonia, dysarthria, areflexia, axonal sensorimotor neuropathy	Exon 5: c.593C>T; c.770+1G>A Exon 6: c.835T>C; c.837G>A	(13)
Habeck, 2004	3	Germany	4-6 years	Cerebellar ataxia, dysarthria, oculomotor apraxia, areflexia and hypotonia	Exon 6: c.837G>A	(17)
Amouri, 2004	3 unrelated families	Tunisia	Mean of 5 years	Cerebellar ataxia, dysarthria, ocular apraxia, distal axonal neuropathy, cerebellar atrophy, hypoalbuminemia, hypercholesterolemia	Exon 7: c.875-1G>A; total deletion of gene	(18)

In conclusion, the present study reported on the identification of a variant of uncertain significance, c.751C>T p.(His251Tyr), in an eight-year-old female patient with hereditary progressive ataxia. Based on a detailed review of the literature, it was concluded that in patients with autosomal recessive or solitary instances of cerebellar ataxia that worsen over time, after Friedreich's ataxia has been ruled out, genetic testing should be used to check for *APTX* mutations. At first, there are usually

no signs of oculomotor apraxia or other functional problems. However, choreic movements are likely caused by AOA1. As the AOA1 phenotype initially appears similar to other types of choreic disorders, early-onset choreic patients who do not have significant mutations in the IT15 or JPH3 genes should also be checked for *APTX* mutations. Early detection of hyperkinetic movement disorders in patients with AOA1 is important to ensure the right treatment is provided. Finally, patients with early-onset ataxia and mixed-movement disorders should be genetically tested for a number of diseases, including AOA1.

With breakthroughs in genetic testing, the identification of children with this disease will become easier in the future. Current treatments for AOA1 focus on rehabilitation therapy; there is currently no specific treatment for AOA1. Although the present results are encouraging, more research is required to establish the etiology of AOA1 in terms of causative mutations.

Acknowledgements

Not applicable.

Funding

No funding was received.

Availability of data and materials

The datasets used and/or analyzed during the current study are available from the corresponding author on reasonable request.

Authors' contributions

RA, AA and SB designed the study. AA, GA and BA collected the clinical data. AA, GA, BA and RA analysed and interpreted the data. RA, AA, GA, BA and SB drafted the manuscript. RA and SB confirmed the authenticity of the raw data. All authors read and approved the final manuscript.

Ethics approval and consent to participate

The study was carried out in accordance with the code of international and local Ethics (Declaration of Helsinki). This study was reviewed and approved by the local ethics committee of the King Fahad Specialist Hospital Dammam (Dammam, Saudi Arabia).

Patient consent for publication

The parents of the patient provided written informed consent for publication.

Competing interests

The authors declare that they have no competing interests.

References

1. Coutinho P, Barbot C and Coutinho P: Ataxia with oculomotor apraxia type 1. In: Adam MP, Everman DB, Mirzaa GM, Pagon RA, Wallace SE, Bean LJH, Gripp KW, Amemiya A, editors. GeneReviews® [Internet]. Seattle (WA): University of Washington, Seattle; 1993: 2022, 2002.
2. Sandford E and Burmeister M: Genes and genetic testing in hereditary ataxias. Genes (Basel) 5: 586-603, 2014.
3. Inlora J, Sailani MR, Khodadadi H, Teymurinezhad A, Takahashi S, Bernstein JA, Garshasbi M and Snyder MP: Identification of a novel mutation in the APTX gene associated with ataxia-oculomotor apraxia. Cold Spring Harb Mol Case Stud 3: a002014, 2017.
4. Moreira MC, Barbot C, Tachi N, Kozuka N, Uchida E, Gibson T, Mendonça P, Costa M, Barros J, Yanagisawa T, *et al*: The gene mutated in ataxia-ocular apraxia 1 encodes the new HIT/Zn-finger protein aprataxin. Nat Genet 29: 189-193, 2001.
5. Sun Y, Zheng L, Yang Y, Qian X, Fu T, Li X, Yang Z, Yan H, Cui C and Tan W: Metal-Organic framework nanocarriers for drug delivery in biomedical applications. Nanomicro Lett 12: 103, 2020.
6. Ahel I, Rass U, El-Khamisy SF, Katyal S, Clements PM, McKinnon PJ, Caldecott KW and West SC: The neurodegenerative disease protein aprataxin resolves abortive DNA ligation intermediates. Nature 443: 713-716, 2006.
7. Chen R, Im H and Snyder M: Whole-Exome enrichment with the agilent sureselect human all exon platform. Cold Spring Harb Protoc 2015: 626-633, 2015.
8. Richards S, Aziz N, Bale S, Bick D, Das S, Gastier-Foster J, Grody WW, Hegde M, Lyon E, Spector E, *et al*: Standards and guidelines for the interpretation of sequence variants: A joint consensus recommendation of the American college of medical genetics and genomics and the association for molecular pathology. Genet Med 17: 405-424, 2015.
9. Koboldt DC: Best practices for variant calling in clinical sequencing. Genome Med 12: 91, 2020.
10. Date H, Onodera O, Tanaka H, Iwabuchi K, Uekawa K, Igarashi S, Koike R, Hiroi T, Yuasa T, Awaya Y, *et al*: Early-onset ataxia with ocular motor apraxia and hypoalbuminemia is caused by mutations in a new HIT superfamily gene. Nat Genet 29: 184-188, 2001.
11. Sekijima Y, Hashimoto T, Onodera O, Date H, Okano T, Naito K, Tsuji S and Ikeda S: Severe generalized dystonia as a presentation of a patient with aprataxin gene mutation. Mov Disord 18: 1198-1200, 2003.
12. Zheng J, Croteau DL, Bohr VA and Akbari M: Diminished OPA1 expression and impaired mitochondrial morphology and homeostasis in Aprataxin-deficient cells. Nucleic Acids Res 47: 4086-4110, 2019.
13. Le Ber I, Moreira MC, Rivaud-Péchoux S, Chamayou C, Ochsner F, Kuntzer T, Tardieu M, Saïd G, Habert MO, Demarquay G, *et al*: Cerebellar ataxia with oculomotor apraxia type 1: Clinical and genetic studies. Brain 126 (Pt 12): 2761-2772, 2003.
14. Castellotti B, Mariotti C, Rimoldi M, Fancellu R, Plumari M, Caimi S, Uziel G, Nardocci N, Moroni I, Zorzi G, *et al*: Ataxia with oculomotor apraxia type1 (AOA1): Novel and recurrent aprataxin mutations, coenzyme Q10 analyses, and clinical findings in Italian patients. Neurogenetics 12: 193-201, 2011.
15. Shimazaki H, Takiyama Y, Sakoe K, Ikeguchi K, Niijima K, Kaneko J, Namekawa M, Ogawa T, Date H, Tsuji S, *et al*: Early-onset ataxia with ocular motor apraxia and hypoalbuminemia: The aprataxin gene mutations. Neurology 59: 590-595, 2002.
16. Tranchant C, Fleury M, Moreira MC, Koenig M and Warter JM: Phenotypic variability of aprataxin gene mutations. Neurology 60: 868-870, 2003.
17. Habeck M, Zühlke C, Bentele KH, Unkelbach S, Kress W, Bürk K, Schwinger E and Hellenbroich Y: Aprataxin mutations are a rare cause of early onset ataxia in Germany. J Neurol 251: 591-594, 2004.
18. Amouri R, Moreira MC, Zouari M, El Euch G, Barhoumi C, Kefi M, Belal S, Koenig M and Hentati F: Aprataxin gene mutations in Tunisian families. Neurology 63: 928-929, 2004.
19. Yan J, Qiao L, Peng H, Liu A, Wu J and Huang J: A novel missense pathogenic variant in NEFH causing rare Charcot-Marie-Tooth neuropathy type 2CC. Neurol Sci 42: 757-763, 2021.
20. Pedroso JL, Vale TC, da Costa SCG, Santos M, Alonso I and Barsottini OGP: Complex movement disorders in ataxia with oculomotor apraxia type 1: Beyond the cerebellar syndrome. Tremor Other Hyperkinet Mov (N Y) 10: 39, 2020.
21. Ababneh NA, Ali D, Al-Kurdi B, Sallam M, Alzibdeh AM, Salah B, Ryalat AT, Azab B, Sharrack B and Awidi A: Identification of APTX disease-causing mutation in two unrelated Jordanian families with cerebellar ataxia and sensitivity to DNA damaging agents. PLoS One 15: e0236808, 2020.

22. Hengel H, Buchert R, Sturm M, Haack TB, Schelling Y, Mahajnah M, Sharkia R, Azem A, Balousha G, Ghanem Z, *et al*: First-line exome sequencing in Palestinian and Israeli Arabs with neurological disorders is efficient and facilitates disease gene discovery. Eur J Hum Genet 28: 1034-1043, 2020.
23. Renaud M, Moreira MC, Ben Monga B, Rodriguez D, Debs R, Charles P, Chaouch M, Ferrat F, Laurencin C, Vercueil L, *et al*: Clinical, biomarker, and molecular delineations and genotype-phenotype correlations of ataxia with oculomotor apraxia type 1. JAMA Neurol 75: 495-502, 2018.
24. Hirano M, Matsumura R, Nakamura Y, Saigoh K, Sakamoto H, Ueno S, Inoue H and Kusunoki S: Unexpectedly mild phenotype in an ataxic family with a two-base deletion in the APTX gene. J Neurol Sci 378: 75-79, 2017.
25. Karimzadeh P, Khayatzadeh Kakhki S, Esmail Nejad SS, Houshmand M and Ghofrani M: Ataxia oculomotor apraxia type 1 in the siblings of a family: A novel mutation. Iran J Child Neurol 11: 78-81, 2017.
26. van Minkelen R, Guitart M, Escofet C, Yoon G, Elfferich P, Bolman GM, van der Helm R, van de Graaf R and van den Ouweland AM: Complete APTX deletion in a patient with ataxia with oculomotor apraxia type 1. BMC Med Genet 16: 61, 2015.
27. Paucar M, Alonso I, Eriksson M, Beniaminov S, Coutinho P and Svenningsson P: Novel APTX mutation in a hispanic subject affected by ataxia with oculomotor apraxia type 1. Mov Disord Clin Pract 2: 90-92, 2014.
28. Nouri N, Nouri N, Aryani O, Kamalidehghan B, Sedghi M and Houshmand M: A novel mutation in the aprataxin (APTX) gene in an Iranian individual suffering early-onset ataxia with oculomotor apraxia type 1(AOA1) disease. Iran Biomed J 16: 223-225, 2012.
29. Yoon G, Westmacott R, Macmillan L, Quercia N, Koutsou P, Georghiou A, Christodoulou K and Banwell B: Complete deletion of the aprataxin gene: Ataxia with oculomotor apraxia type 1 with severe phenotype and cognitive deficit. BMJ Case Rep 2009: bcr08.2008.0688, 2009.
30. Ferrarini M, Squintani G, Cavallaro T, Ferrari S, Rizzuto N and Fabrizi GM: A novel mutation of aprataxin associated with ataxia ocular apraxia type 1: Phenotypical and genotypical characterization. J Neurol Sci 260: 219-224, 2007.
31. Hirano M, Asai H, Kiriyama T, Furiya Y, Iwamoto T, Nishiwaki T, Yamamoto A, Mori T and Ueno S: Short half-lives of ataxia-associated aprataxin proteins in neuronal cells. Neurosci Lett 419: 184-187, 2007.
32. Ceyhan-Birsoy O, Murry JB, Machini K, Lebo MS, Yu TW, Fayer S, Genetti CA, Schwartz TS, Agrawal PB, Parad RB, *et al*: Interpretation of genomic sequencing results in healthy and Ill Newborns: Results from the babyseq project. Am J Hum Genet 104: 76-93, 2019.
33. Manzoor H, Bukhari I, Wajid M, Zhang Y, Zhang H, Brüggemann N, Klein C, Shi Q and Naz S: A Novel APTX variant and ataxia with oculomotor apraxia type 1. J Clin Neurol 13: 303-305, 2017.
34. Yokoseki A, Ishihara T, Koyama A, Shiga A, Yamada M, Suzuki C, Sekijima Y, Maruta K, Tsuchiya M, Date H, *et al*: Genotype-phenotype correlations in early onset ataxia with ocular motor apraxia and hypoalbuminaemia. Brain 134 (Pt 5): 1387-1399, 2011.
35. Backenroth D, Homsy J, Murillo LR, Glessner J, Lin E, Brueckner M, Lifton R, Goldmuntz E, Chung WK and Shen Y: CANOES: Detecting rare copy number variants from whole exome sequencing data. Nucleic Acids Res 42: e97, 2014.
36. Gordeeva V, Sharova E, Babalyan K, Sultanov R, Govorun VM and Arapidi G: Benchmarking germline CNV calling tools from exome sequencing data. Sci Rep 11: 14416, 2021.