Endodontic treatment of the mandibular first molar with six root canals: A case report and literature review

MEIWEI LIU[1,2*], YAN ZHANG[2,3*], PEI SUN[1,2], YANYA QIAO[1,2] and KEQING PAN[1,2]

[1]Department of Stomatology, The Affiliated Hospital of Qingdao University, Qingdao, Shandong 266000; [2]School of Stomatology, Qingdao University, Qingdao, Shandong 266003; [3]Department of Stomatology, Linyi People's Hospital, Linyi, Shandong 276002, P.R. China

Received May 23, 2022; Accepted September 16, 2022

DOI: 10.3892/etm.2022.11696

Abstract. The mandibular first molars normally have three or four root canals and rarely have five or more root canals. The present study reported a rare anatomical configuration with six root canals in the mandibular right first molar diagnosed during endodontic treatment using a dental operating microscope and confirmed with the help of cone-beam computed tomography (CBCT) images. The present case report revealed that there is an increasing possibility of detecting additional canals through the magnification of the microscope and the improvement of CBCT diagnostic technology. As more abnormal morphologies in root canals are reported, dentists need to understand this diversity in anatomical structure and improve treatment techniques.

Introduction

The aim of root canal treatment is to clean and shape the root canal system and to fill it with an inert filling material. The inability to appropriately understand the anatomical configuration of teeth and identify all the root canals for subsequent disinfection and obturation may lead to endodontic treatment failure (1). It is essential to adequately know about the root canal system for successful endodontic treatment; however, there are frequent variations in the root canal system (2).

The mesial and distal roots of the mandibular first molars typically include two mesial canals and one or two distal canals, respectively. Rarely, the mesiolingual and mesiobuccal canals are separated by a third canal called the middle mesial canal, which is situated in the developing groove. The incidence of a middle mesial (MM) canal is reported to range from 1 to 15% (3). The middle distal (MD) canal, which is situated in between the distolingual and distobuccal canals, is another uncommon occurrence. Three canals in the distal root are uncommon, with a prevalence of 0.2-3% (4,5).

The present study reported on the successful endodontic treatment of a Chinese female patient with a mandibular first molar with six root canals (three in the mesial root and three in the distal root).

Case report

A 28-year-old Chinese female patient presented at the Department of Endodontics, the Affiliated Hospital of Qingdao University (Qingdao, China) in September 2017 with the chief complaint of swelling and discomfort in the gum of a lower right tooth for one month. Clinical examination revealed that the gingiva of the mandibular right first molar (tooth #46) was swollen and there was a previous filling on the mesio-occlusal surface of the tooth (Fig. 1A). The gingiva bled excessively on probing and a 13.5-mm deep periodontal pocket was found in the buccal center of the tooth (Fig. 1B). The probing depth of the periodontal pocket at the remaining points was 1-3 mm. Horizontal percussion of the tooth caused moderate pain, whereas the pain was more intense during vertical percussion of the tooth. Thermal testing (heated gutta-percha and popsicles) caused no reaction and electric pulp testing indicated complete necrosis of the pulp. Neither distinct mobility nor clinical fractures were discovered. All adjacent teeth were normal.

The preoperative periapical radiograph of tooth #46 revealed a low-density area surrounding the filling on the mesio-occlusal area of the crown, approaching the pulp (Fig. 2A). The radiographic images of the root canals were inconspicuous and they overlapped with each other. The radiograph also indicated that the periapical periodontal ligament space with regard to the mesial root apex and root bifurcation had widened. To further clarify the morphology of the root canals and the scope of lesions, cone-beam computed tomography (CBCT; i-CAT CBCT; KaVo Dental) was proposed, and the patient agreed to undergo the same. CBCT images (Fig. 2B) confirmed the six canals and the scope of periapical inflammation; while the distal apical inflammation was limited to the

Correspondence to: Dr Keqing Pan, Department of Stomatology, The Affiliated Hospital of Qingdao University, 16 Jiangsu Road, Shinan, Qingdao, Shandong 266000, P.R. China
E-mail: pankeqing77@qdu.edu.cn

[*]Contributed equally

Key words: mandibular first molar, six root canals, dental operating microscope, cone-beam computed tomography

apical third, the proximal apical inflammation expanded to the apical half.

Based on the clinical and radiographic examination findings, a diagnosis of necrotic pulp with symptomatic apical periodontitis (chronic apical periodontitis) in tooth #46 was made. After explaining the clinical condition, the dentist recommended nonsurgical endodontic treatment and informed the patient that periodontal surgery may be required. The risks and benefits of the treatment were explained to the patient and written informed consent was obtained prior to starting the treatment. Tooth #46 was first isolated with a rubber dam; subsequently, the previous filling and dental caries were removed and a conventional endodontic access was established. The pulp chamber was examined with a DG-16 endodontic explorer and four canal orifices were observed: Two in the mesial root mesiobuccal (MB) and mesiolingual (ML) and two in the distal root distolingual (DL) and distobuccal (DB). Using an operating microscope (Zumax Medical Co., Ltd), a third orifice, MM, was located between MB and ML and an additional orifice, MD, was located between DB and DL. The canals were explored with a size 10 ISO K-file (Dentsply Sirona); it was observed that each of the six separate root canals had an independent apical foramen. The working length of each root canal was measured with an electronic apex locator (Root ZX; J. Morita Corp.) and confirmed by a radiograph with size 10 K-files (Fig. 2C). The root canals were then cleaned and shaped with ProTaper nickel-titanium rotary instruments (Dentsply Sirona) till F2 (tip diameter, 25 mm; taper, 8) using the crown-down technique (Fig. 3). During the procedure, 17% EDTA gel was used as a lubricant and 5.25% sodium hypochlorite solution was used as an irrigant. For the final irrigation, ultrasonic irrigation with normal saline was used. Calcium hydroxide was used as intracanal medication and zinc oxide eugenol was used as a sealer.

At the next appointment after 2 weeks, the patient had improved. There was no pain when the tooth was percussed and the gingival swelling was significantly reduced. After placing a rubber dam, the canals were finally rinsed by ultrasonic irrigation with normal saline and the canals were dried with absorbent paper points and obturated using the warm gutta-percha condensation technique with AH Plus (Dentsply Sirona) as the sealer (Fig. 4A). After completion of root canal treatment, the tooth was restored with a composite resin (Z350 3M; Filtek) (Fig. 4B). A final radiograph was taken to assess the quality of the obturation. The filling in the root canal was uniform and the gutta-percha points did not extend beyond the apical hole; however, overfilling was observed in certain root canals, because excessive paste was utilized during root filling to maximise root canal sealing (Fig. 5).

After one year, the patient experienced no post-treatment discomfort. The color and texture of the gums returned to normal (Fig. 6A). The tooth was not tender on palpation or percussion. The periodontal probing depths around the tooth were within the physiological limits (Fig. 6B). The CBCT images (Fig. 7) indicated that the sealer was still present in certain root tips, the range of radiolucency near the mesial root and the root bifurcation had narrowed and the bone mineral density had increased. It takes ~4 years for the AH plus to completely absorb (6) and in follow-up visits, the patient's subjective symptoms and apical shadow healing will be continuously observed. If periapical inflammation does not heal well, apical surgery may be performed when necessary.

Table I. Case reports on mandibular first molar.

Author, year	Number of root canals			(Refs.)
	Mesial root	Distal root	Total	
Ramachandran, 2019	3	3	6	(7)
Jabali, 2018	3	3	6	(8)
Vineet, 2018	4	2	6	(9)
Kamble , 2017	3	3	6	(10)
Banode, 2016	3	4	7	(11)
Acharya, 2015	3	3	6	(12)
Martins, 2015 (A)	3	3	6	(13)
Martins, 2015 (B)	4	2	2	(13)
Maniglia-Ferreira, 2015	3	3	6	(14)
Baziar, 2014	2	4	6	(15)
Sinha, 2014	4	2	6	(16)
Hasan, 2014	3	3	6	(17)
Martins, 2014	4	3	7	(18)
Alves, 2012	3	3	6	(19)
Gupta, 2012	3	3	6	(20)
Ryan, 2011	3	3	6	(21)
Mohsen, 2010	4	2	6	(22)

Discussion

Root canal treatment is currently recognized as an effective therapy for pulpitis and periapical periodontitis. Mandibular first molars are the first permanent posterior teeth to erupt and most frequently have carious lesions that may necessitate endodontic treatment. Recently, there has been an ongoing trend of case reports that highlight the presence of more than four root canals in mandibular first molars. However, there are a limited number of case reports on the rare anatomical configuration with six root canals in the mandibular right first molar. A detailed review of case reports of mandibular first molars with six or more root canals in the last 12 years is summarized in Table I (7-22). These studies were retrieved from a database (https://www.x-mol.com/) using the following search terms: Mandibular first molar, middle distal canal, middle mesial canal, six canals, tooth anatomy, extra root.

There have been certain reports of mandibular first molars with extra roots and canals from different authors. Maniglia-Ferreira *et al* (14) reported a case with six canals in a mandibular first molar; during the 18-month follow-up, healing of a periapical lesion was achieved. Ryan *et al* (21) published a case report that discussed the endodontic management of a rare anatomical variation in the root canal system of a mandibular first molar with six canals (3 mesial and 3 distal); the patient was asymptomatic during a follow-up period of 3 years and recall radiographs after treatment indicated resolution of the previous apical periodontitis. Regarding the ideal apical preparation size and taper, the literature is divided.

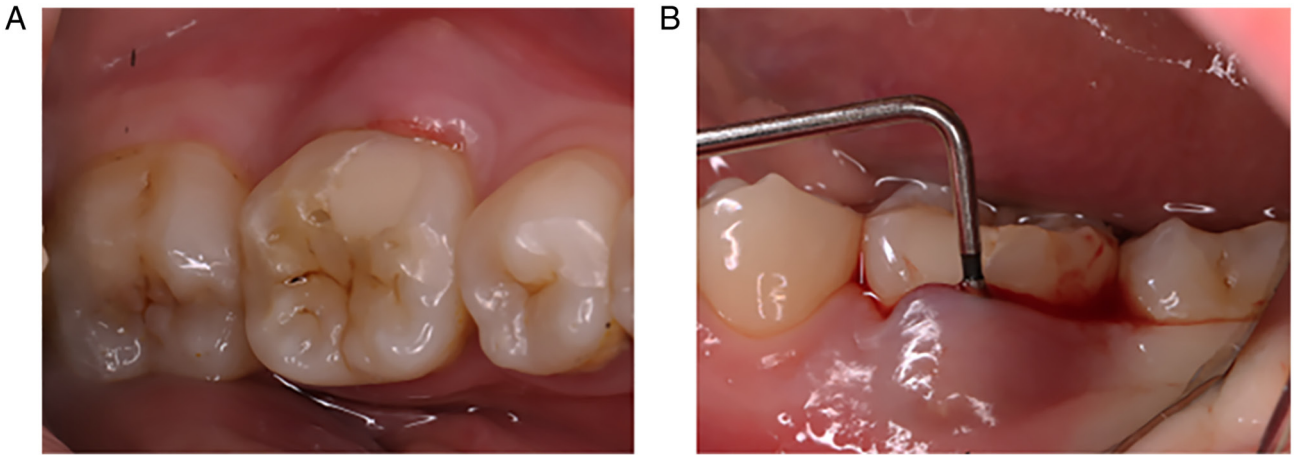

Figure 1. (A) Occlusal surface of tooth #46. (B) Buccal surface of tooth #46; the periodontal probing depth was 13.0 mm.

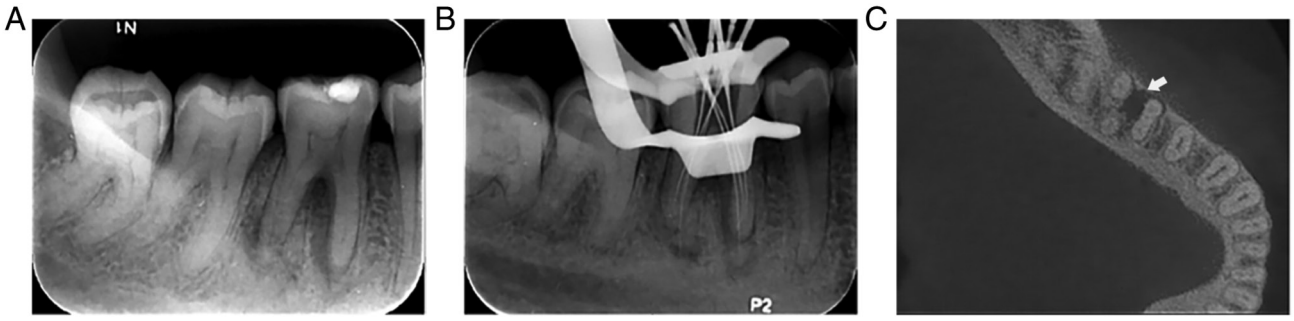

Figure 2. (A) Preoperative radiograph of tooth #46. (B) Periapical radiograph for determination of the working length displaying two roots and six canals. (C) Preoperative cross-section image of cone-beam computed tomography, with arrow indicating the scope of periapical inflammation.

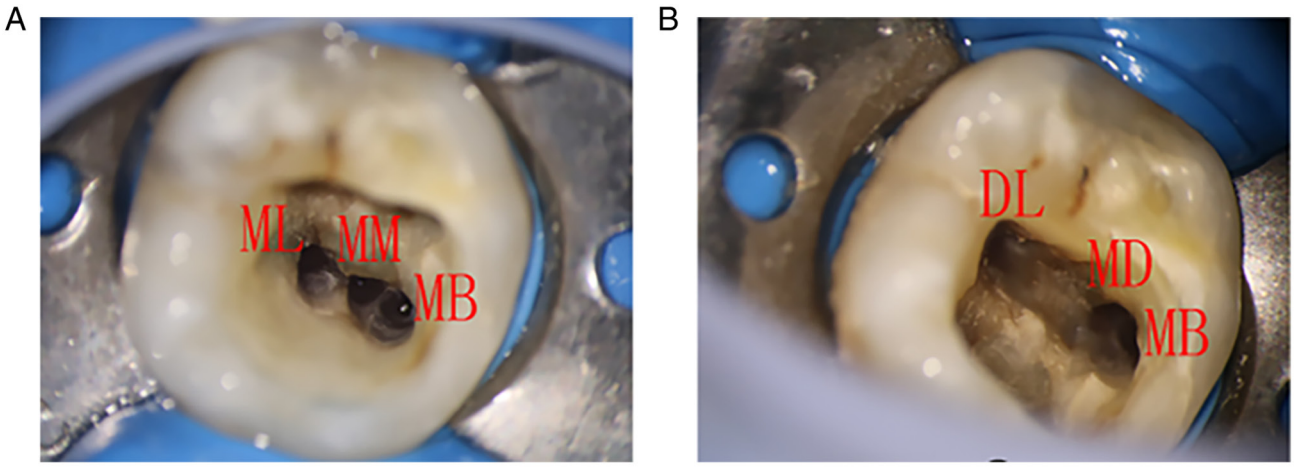

Figure 3. (A) Access opening revealing the three mesial canal orifices by the magnification of the DOM. (B) Access opening displaying the three distal canal orifices by the magnification of the DOM (magnification, x15). DOM, dental operating microscope; MM, middle mesial; MD, middle distal; MB, mesiobuccal; ML, mesiolingual; DL, distolingual.

Previous research has indicated that by enlarging the apical size and taper, it is possible to more easily remove bacteria and debris from the root canal, increase the effectiveness of irrigation solutions relative to the working length and improve the distribution of the lateral and vertical forces produced during filling (23). When compared to size 20, the apical size of 25 produced noticeably cleaner canal walls in the top third (24). According to a study, the fracture strength of mandibular molar teeth is decreased when the apical diameter and taper in the MM canal are increased. When instrumentation sizes of >25.04 were used, the fracture strength among the evaluated instrumentation sizes markedly decreased (25). Since the patient of the present study was a young female with a wide root canal lumen, the root canal was prepared to F2

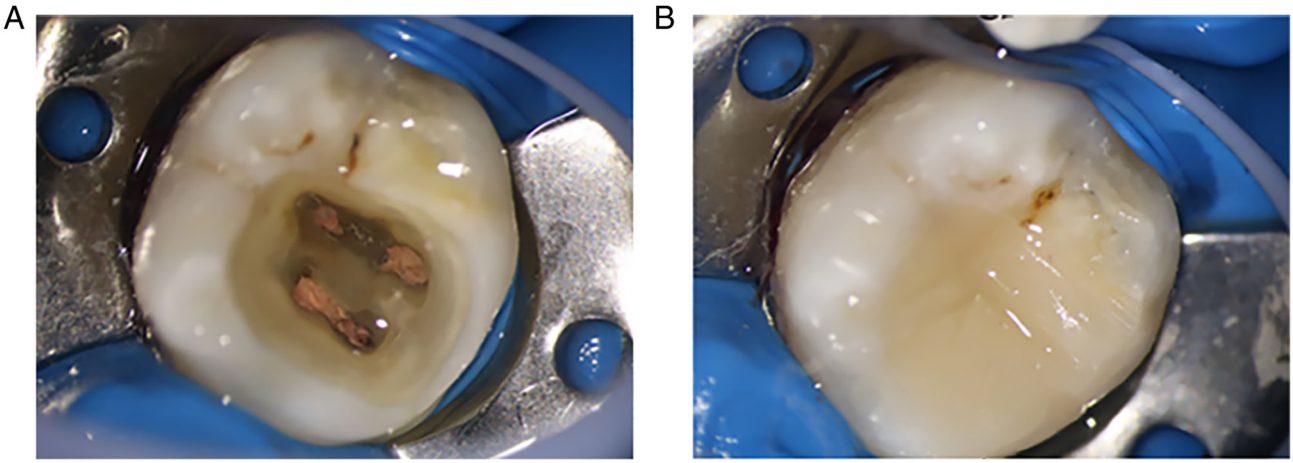

Figure 4. (A) Pulp chamber view after root canal obturation. (B) Final resin filling (magnification, x15).

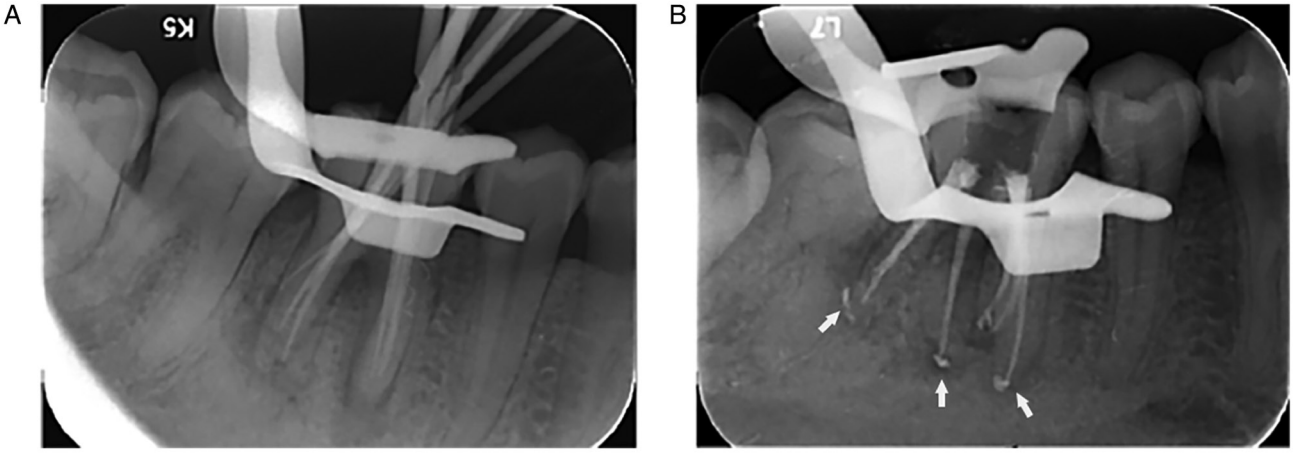

Figure 5. (A) Radiograph displaying gutta-percha cones placed in six separated canals of tooth #46. (B) Post obturation radiograph, with arrows indicating overfilling was present in certain root canals.

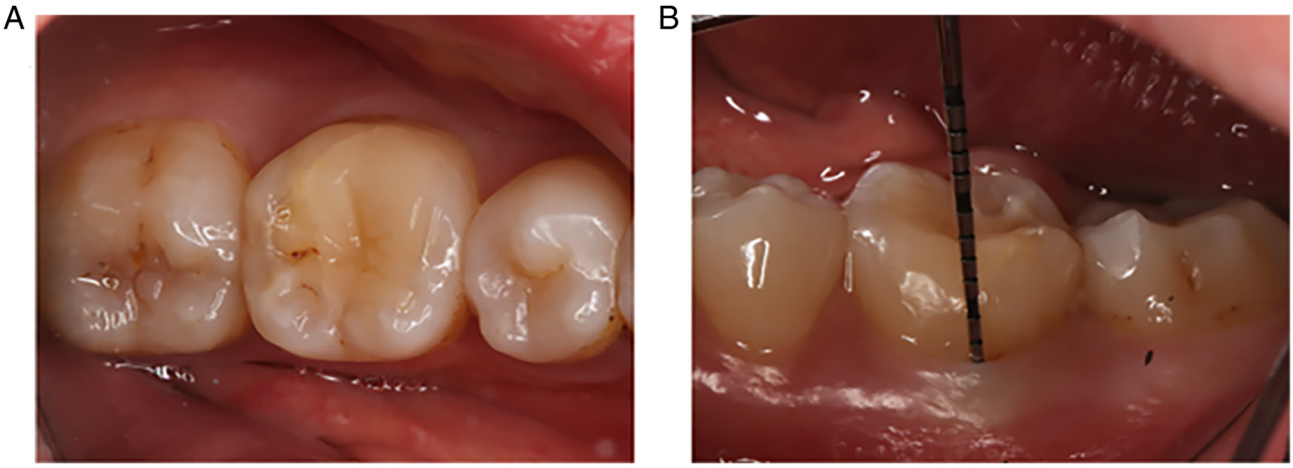

Figure 6. (A) Occlusal surface of tooth #46 after one year. (B) Buccal surface of tooth #46 after one year; the periodontal probing depth was 2.0 mm.

(tip diameter, 25 mm; taper, 8) to better clean the root canal infection.

This tendency warns dentists to be more careful when dealing with mandibular first molars requiring endodontic treatment. Certain canals may be left untreated if their presence is not detected by the dentist. Thus, all possible methods should be used to locate and detect the entire root canal system. Traditional periapical radiography is essential

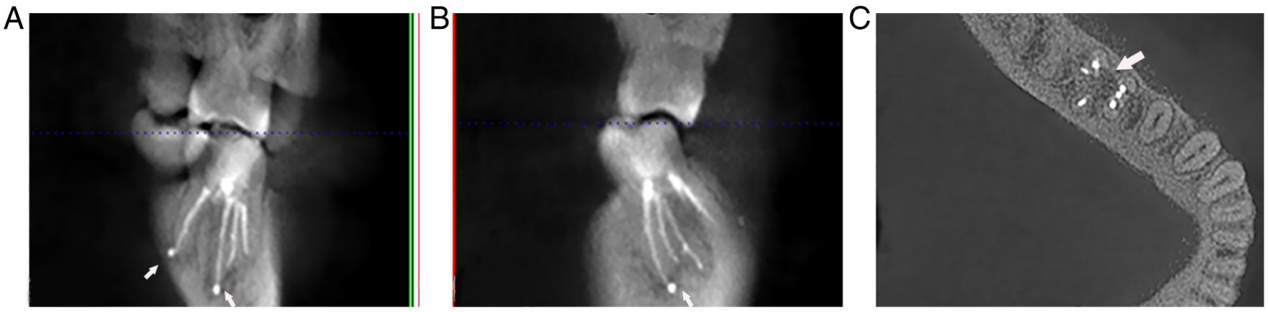

Figure 7. (A) Mesial vertical plane image of CBCT after one year, displaying three mesial canals, with arrows indicating overfilling was also observed in the mesiolingual canal, and the scope of periapical inflammation was reduced. (B) Distal vertical plane image of CBCT after one year, displaying three distal root canals, with arrows indicating overfilling was also observed in distolingual canals, and the scope of periapical inflammation was reduced. (C) Cross-section image of CBCT after one year, with arrow indicating that the scope of periapical inflammation was reduced. CBCT, cone-beam computed tomography.

for preoperative diagnosis; however, it may only provide two-dimensional information. When root canals overlap with each other and complex anatomies are present, such as multi-canal systems or dens invaginatus, three-dimensional CBCT images may be beneficial to form an accurate diagnosis and morphological evaluation in endodontics (26). In the present case, the standard periapical radiograph indicated that the root canal images were overlapped and blurry. To confirm this, a CBCT was advised for the right mandibular molar. The CBCT images provided a clearer view of the anatomical morphology of the root canal and inflammatory range and indicated that there were 3 apical holes in the mesial root and distal root, respectively, which was similar to the present findings. The use of CBCT affected the reviewers' choices when making pulpal and periapical diagnoses and more notably when determining etiologic factors and recommending a treatment. This was confirmed in a study by Chogle *et al* (27), in which CBCT imaging had a significant effect in determining the etiologic factors contributing to endodontic pathosis (55% change overall) and making treatment recommendations (49% change overall).

DOM provides dentists with superior lighting and magnification capacity, and enhanced illumination and visibility enable endodontists to improve the predictability of their procedures and may help dentists identify morphological deviations and thoroughly understand the anatomy of the pulp chamber floor and the exact location of canal orifices (28). These advantages of DOM provide physicians with the ability to treat cases that previously may have been deemed untreatable or which may have resulted in a compromised prognosis, which is evident from numerous studies and clinical practice in endodontics. The use of magnification is considered helpful for the successful completion of endodontic treatment. Maniglia-Ferreira *et al* (14) reported on a mandibular first molar with four separate mesial and two separate distal canals observed under the magnification of DOM. Wu *et al* (29) from the Affiliated Stomatology Hospital of Nanjing Medical University used DOM to treat patients whose treatment had failed by conventional methods. The patients previously had unsuccessful treatments due to canal calcification, separated instruments, missed canals or canal perforation. Using DOM, 74.4% of canals were successfully treated and for the affected teeth whose treatment failed due to missing root canal, the success rate of retreatment through the microscope was 80%. even more to the point that the treatment success rate of missing root canal cases was ~80%. In the present case, with the help of DOM, the six independent root canal openings at the bottom of the pulp chamber were clearly observed and it was possible to check whether the pulp cavity and root canal were cleaned and ready for root canal filling.

The use of DOM and CBCT images in certain challenging cases may facilitate a better understanding of the complex root canal anatomy, which ultimately enables dentists to better explore the root canal system and clean, shape and obturate it more efficiently. The present case report contributes to our knowledge of the anatomical variability of the mandibular first molar.

Acknowledgements

Not applicable.

Funding

No funding was received.

Availability of data anad materials

The datasets used and/or analyzed during the present study are available from the corresponding author on reasonable request.

Authors' contributions

ML and YZ contributed to the study design. ML, PS, YQ and KP collected the presurgical and intrasurgical clinical data. ML, YZ, PS, YQ and KP participated in the postsurgical data acquisition and interpretation and were involved in drafting the manuscript. KP supervised the research and critically revised the manuscript for important intellectual content. ML and KP confirm the authenticity of all the raw data. All authors read and approved the final manuscript as submitted and agree to be accountable for all aspects of the work.

Ethics approval and consent to participate

The present study was approved by the Medical Ethics Committee of the Affiliated Hospital of Qingdao University (Qingdao, China; approval no. QYFYWZLL27005).

Patient consent for publication

Written informed consent was obtained from the patient for the publication of the case report.

Competing interests

The authors declare that they have no competing interests.

References

1. Wolcott J, Ishley D, Kennedy W, Johnson S, Minnich S and Meyers J: A 5 yr clinical investigation of second mesiobuccal canals in endodontically treated and retreated maxillary molars. J Endod 31: 262-264 , 2005.
2. Albuquerque S, Kottoor J and Hammo M: Endodontic and clinical considerations in the management of variable anatomy in mandibular premolars: A literature review. Biomed Res Int 2014: 512574, 2014.
3. Fabra-Campos H: Three canals in the mesial root of mandibular first permanent molars: A clinical study. Int Endod J 22: 39-43, 1989.
4. Gulabivala K, Opasanon A, Ng YL and Alavi A: Root and canal morphology of Thai mandibular molars. Int Endod J 35: 56-62, 2002.
5. Moor RJGD, Deroose CAJG and Calberson FLG: The radix entomolaris in mandibular first molars: An endodontic challenge. Int Endod J 37: 789-799, 2004.
6. Ricucci D, Rôças IN, Alves FRF, Loghin S and Siqueira JF Jr: Apically extruded sealers: Fate and influence on treatment outcome J Endod 42: 243-249, 2016.
7. Ramachandran VS, Shankari V, Rathakrishnan M, Chandrasegaran V and Kumaraguru K: Management of three rooted mandibular first molar with six canals: A case report. Cureus 11: e6280, 2019.
8. Jabali AH: Middle Mesial and Middle Distal canals in mandibular first molar. J Contemp Dent Pract 19: 233-236, 2018.
9. Vineet A, Sonali K and Dhwani B: Rare case of a mandibular first molar with seven canals confirmed by cone beam computed tomography and its endodontic management. Int J Health Sci (Qassim) 12: 91-93, 2018.
10. Kamble AP, Pawar RR, Mattigatti S, Mangala TM and Makandar S: Cone-beam computed tomography as advanced diagnostic aid in endodontic treatment of molars with multiple canals: Two case reports. J Conserv Dent 20: 273-277, 2017.
11. Banode AM, Gade V, Patil S and Gade J: Endodontic management of mandibular first molar with seven canals using cone-beam computed tomography. Contemp Clin Dent 7: 255-257, 2016.
12. Acharya N, Singh A, Samant PS and Gautam V: Endodontic management of radix paramolaris with six canals: A clinical case report. Kathmandu Univ Med J (KUMJ) 11: 338-341, 2015.
13. Martins JNR and Anderson C: Endodontic treatment of the mandibular first molar with six roots canals-two case reports and literature review. J Clin Diagn Res 9: ZD06-ZD08, 2015.
14. Maniglia-Ferreira C, de Almeida Gomes F and Sousa BC: Management of six root canals in mandibular first molar. Case Rep Med 2015: 827070, 2015.
15. Baziar H, Daneshvar F, Mohammadi A and Jafarzadeh H: Endodontic management of a mandibular first molar with four canals in a distal root by using cone-beam computed tomography: A case report. J Oral Maxillofac Res 5: e5, 2014.
16. Sinha N, Singh B, Langaliya A, Mirdha N, Huda I and Jain A: Cone beam computed topographic evaluation and endodontic management of a rare mandibular first molar with four distal canals. Case Rep Dent 2014: 306943, 2014.
17. Hasan M, Rahman M and Saad N: Mandibular first molar with six root canals: A rare entity. BMJ Case Rep 2014: bcr2014205253, 2014.
18. Martins JNR: Endodontic treatment of a maxillary first molar with seven root canals confirmed with cone beam computer tomography-case report. J Clin Diagn Res 8: ZD13-ZD15, 2014.
19. Alves FRF, Rôças IN, Almeida BM, Neves MAS, Zoffoli J and Siqueira JF: Quantitative molecular and culture analyses of bacterial elimination in oval-shaped root canals by a single-file instrumentation technique. Int Endod J 45: 871-877, 2012.
20. Gupta S, Jaiswal S and Arora R: Endodontic management of permanent mandibular left first molar with six root canals. Contemp Clin Dent 3: S130-S133, 2012.
21. Ryan JL, Bowles WR, Baisden MK and McClanahan SB: Mandibular first molar with six separate canals. J Endod 37: 878-880, 2011.
22. Aminsobhani M, Shokouhinejad N, Ghabraei S, Bolhari B and Ghorbanzadeh A: Retreatment of a 6-canalled mandibular first molar with four mesial canals: A case report. Iran Endod J 5: 138-140, 2010.
23. Kılıç, Y, Karataşlıoğlu E and Kaval ME: The effect of root canal preparation size and taper of middle mesial canals on fracture resistance of the mandibular molar teeth: An in vitro study. J Endod 47: 1467-1471, 2021.
24. Plotino G, Özyürek T, Grande NM and Gündoğar M: Influence of size and taper of basic root canal preparation on root canal cleanliness: A scanning electron microscopy study. Int Endod J 52: 343-351, 2018.
25. Keleş A, Keskin C, Karataşlıoğlu E, Kishen A and Versiani MA: Middle Mesial canal preparation enhances the risk of fracture in mesial root of mandibular molars. J Endod 46: 1323-1329, 2020.
26. Patel S, Durack C, Abella F, Roig M, Shemesh H, Lambrechts P and Lemberg K: European Society of Endodontology position statement: The use of CBCT in endodontics. Int Endod J 47: 502-504, 2014.
27. Chogle S, Zuaitar M, Sarkis R, Saadoun M, Mecham A and Zhao Y: The recommendation of cone-beam computed tomography and its effect on endodontic diagnosis and treatment planning. J Endod 46: 162-168, 2019.
28. Yoshioka T, Kobayashi C and Suda H: Detection rate of root canal orifices with a microscope. J Endod 28: 452-453, 2002.
29. Wu D, Shi W, Wu J, Wu Y, Liu W and Zhu Q: The clinical treatment of complicated root canal therapy with the aid of a dental operating microscope. Int Dent J 61: 261-266, 2011.