Protective effect of cerium oxide on testicular function and oxidative stress after torsion/detorsion in adult male rats

SULEYMAN YESIL[1], CAGRI OZDEMIR[2], MUSTAFA ARSLAN[2,3], AYSE CAKIR GUNDOGDU[4], MUSTAFA KAVUTCU[5] and ALI ATAN[1]

Departments of [1]Urology and [2]Anesthesiology and Reanimation, Medical Faculty; [3]Life Sciences Application and Research Center, Gazi University, 06510 Ankara; [4]Department of Histology and Embryology, Medical Faculty, Kutahya Health Sciences University, 43050 Kutahya; [5]Department of Medical Biochemistry, Medical Faculty, Gazi University, 06510 Ankara, Turkey

Received April 18, 2022; Accepted August 17, 2022

DOI: 10.3892/etm.2022.11700

Abstract. Testicular torsion (T)/detorsion (D) can cause testicular injury due to the rotation of the spermatic cord and its vessels, therefore it represents an urological emergency that is surgically treated. Oxidative damage occurs in the testis and distant organs because of the overproduction of free radicals and overexpression of proinflammatory cytokines by reperfusion after surgery. Cerium oxide (CeO_2) nanoparticles, a material also known as nanoceria, have regenerative antioxidant properties on oxidative stress. The present study aimed to investigate the effects of nanoceria on testis tissues in testicular T/D in rats. A total of 24 rats were equally and randomly divided into four groups: Control, CeO_2, T/D and CeO2-T/D groups. Left inguinoscrotal incision was performed in the control group. In the CeO_2 group, 0.5 mg/kg CeO_2 was given intraperitoneally 30 min before inguinoscrotal incision. In the T/D group, unilateral testicular T/D was performed through an inguinoscrotal incision and rotating the left testis 720˚ clockwise, which was then left ischemic for 120 min, followed by 120 min of reperfusion. In the CeO_2-T/D group, 0.5 mg/kg CeO_2 was given intraperitoneally 30 min before testicular T/D. At the end of the experiment, testis tissues were removed for histopathological and biochemical examinations. The samples were histologically examined, Glutathione-s transferase (GST), catalase (CAT), paraoxonase (PON) activities and malondialdehyde (MDA) levels were measured via biochemical analysis methods, while the expression levels of p53, Bax and Bcl-2 were detected using immunohistochemistry. The present results revealed statistically significant inter-group differences in PON, CAT and GST activities and MDA levels. GST, CAT and PON activities were significantly higher, whereas MDA levels in the CeO_2-T/D group were significantly lower compared with those in the T/D group. The T/D group had increased Bax and decreased Bcl-2 expression levels in their seminiferous tubules compared with the control and CeO_2 groups. CeO_2 treatment led to downregulation of Bax and upregulation of Bcl-2. The expression of p53 was high in the T/D group compared with that in the control and CeO2 groups, and was upregulated in all germinal cells. However, compared with that in the T/D group, p53 expression was significantly decreased in the CeO_2-T/D group. The testicular injury score significantly increased in the CeO_2-T/D group compared with the control and CeO_2 groups. Rats in the CeO_2-T/D group demonstrated significantly milder tissue lesions compared with those in T/D group. The present findings indicated that nanoceria may protect testis in rats against the harmful effects of T/D. Further studies are required to evaluate how CeO_2 reduces oxidative stress and cell death in testis tissue that underwent T/D-related injury.

Correspondence to: Dr Mustafa Arslan, Department of Anesthesiology and Reanimation, Medical Faculty, Gazi University, 29 Besevler Road, 06510 Ankara, Turkey
E-mail: mustarslan@gmail.com

Key words: cerium oxide, torsion/detorsion, testis, caspase 3, Bax, p53, malondialdehyde, catalase

Introduction

Testicular injury due to the rotation of the spermatic cord and its vessels caused by testicular torsion (T)/detorsion (D) represents an urological emergency (1). Diagnosis and management of TT is a challenge for physicians (2). Due to the presence of the various clinical conditions that are covered in the definitive diagnosis of the disease, detailed anamnesis and physical examination are very important for the correct diagnosis of TT. A previous study demonstrated that hemorrhagic infarction may occur within 2 h from the testicular torsion, while irreversible damage is likely to occur after 6 h (3). Therefore, time of the diagnosis and management for T/D is very important to save a viable and functional testis. Testicular salvage rate has been reported to be 90-100% in 6 h, ~50% in 12 h and >10% in 24 h after D (4,5).

Testicular T/D is responsible for testicular damage and necrosis due firstly to ischemic (I) injury and secondly to reperfusion (R) injury after D (6). Post-D I/R injury occurs when blood circulation is restarted after acute ischemia (7,8). Testicular reperfusion after testicular D causes more serious

damage compared with ischemia (9). Oxidative stress is a key factor for testicular damage after I/R injury due to the excessive production of reactive oxygen species (ROS) including superoxide anions, hydrogen peroxide, nitric oxide and hypochlorous acid (10,11). Previous studies indicate that the increase in ROS and irreversible damage are associated with an increase in intracellular calcium (12,13). Oxidative stress is caused by an imbalance between the oxidative and antioxidative systems and is responsible for a decrease in cell viability, which is ultimately caused by lipid peroxidation in the cell membrane, protein denaturation and DNA damage (11). Antioxidants control the autoxidation by interrupting the propagation of free radicals or by inhibiting the formation of free radicals via different mechanisms. These compounds help in scavenging the species that initiate the peroxidation, breaking the autoxidative chain reaction, quenching $O_2^{\bullet-}$, and preventing the formation of peroxides (14). The primary source of ROS is considered to be the leukocytes infiltrating into the testicular tissue (15). Spermatozoa are also considered to be a further source of ROS (15).

Nanotechnology is currently employed as a tool to explore the darkest avenues of medical sciences in several ways, such as in imaging (16), sensing (17), targeted drug delivery (18), gene delivery systems (19) and artificial implants (20). The new age drugs are nanoparticles of polymers, metals or ceramics, which can combat conditions such as cancer (21) and fight human pathogens such as bacteria. One of the most promising metal oxide nanoparticles in biological systems is engineered cerium oxide (CeO_2) nanoparticles, also known as nanoceria. Nanoceria have regenerative antioxidant properties in oxidative stress. Additionally, nanoceria reduce inflammation and the autoimmune response (22). The antioxidant properties of nanoceria are based on its activity as ROS scavengers that originate due to the presence of cerium ions in two different oxidation states, Ce^{3+} and Ce^{4+} (23). These antioxidant activities, based on the ratio between Ce^{3+} and Ce^{4+} on the surface of cerium oxide nanoparticles, are associated with superoxide dismutase mimetic activities, catalase mimetic activities and nitric oxide and hydroxyl scavenging properties (24-27).

The present study aimed to investigate the effect of cerium oxide on pathological and biochemical markers from testicular tissue after I/R injury in a testicular T and D model, based on the anti-inflammatory and antioxidant effects previously emphasized.

Materials and methods

Animals and experimental protocol. A total of 24 Wistar albino, male rats (12 months old, weighing 250-300 g) were used in the present study, supplied by Gazi University Experimental Animals Research Center (Ankara, Turkey), which was approved by the Gazi University Ethics Committee (approval no. G.U.ET-19-059). Rats were kept in a temperature-controlled (21±1˚C) and humidity-controlled (45-55%) room, which was maintained on a 12/12 reversed light cycle. Animals were fed with a standard pellet and allowed to drink water *ad libitum*. All the experimental procedures were performed according to the guide for the care and use of laboratory animals. Before each experimental procedures, anesthesia was induced via intraperitoneal (i.p.) injection of ketamine hydrochloride (50 mg/kg; Ketalar; Parke-Davis Eczacibasi; Pfizer, Inc.) and xylazine hydrochloride 2% (20 mg/kg; Alfazyne; Ege Vet). During the surgical procedure, rats were maintained under anesthesia via repetitive injections of 20 $mg.kg^{-1}$ ketamine in case of a positive reaction to surgical stress or intermittent tail pinch. During the surgical procedure rats were placed on a heating pad in order to maintain a constant body temperature. Animals were equally and randomly divided into the follwing four groups: Control, CeO_2, T/D and CeO_2-T/D groups.

Control group rats were only subjected to midline laparotomy. CeO_2 group rats underwent surgical left inguinoscrotal incision and cerium oxide was given via i.p. injection (0.5 mg/kg) 30 min before the incision period.

In the T/D group, following left inguinoscrotal incision, animals underwent unilateral testicular T by 720˚ clockwise rotation of the left testis that was subsequently fixed within the hemiscrotum using a 4/0 atraumatic silk suture. After 120 min of ischemia, rats underwent a spermatic cord D procedure that was followed by reperfusion for 120 min. Sodium heparin (500 IU/kg) was administered through the peripheral vein in the tail for the maintenance of reperfusion after occlusion.

In the T/D + CeO_2 group, cerium oxide (Sigma Aldrich; Merck KGaA) was given (i.p 0.5 $mg.kg^{-1}$) 30 min prior to the ischemic procedure. Following left inguinoscrotal incision, animals underwent unilateral testicular T by 720˚ clockwise rotation of the left testis that was subsequently fixed within the hemiscrotum using a 4/0 atraumatic silk suture. After 120 min, rats underwent spermatic cord D procedure that was followed by reperfusion for 120 min. Sodium heparin (500 IU/kg) was administered through the peripheral vein in the tail for the maintenance of reperfusion after occlusion.

Following reperfusion, blood samples were collected from the abdominal aorta. Subsequently, rats were anesthesized using ketamine (100 mg/kg) and xylazine (10 mg/kg) i.p. injection and sacrified by taking intracardiac blood with an injector. After heartbeat and respiration ceased, these were monitored for further 2 min to confirm death. Testicular tissue samples were obtained for subsequent biochemical and histopathological analyses.

Histopathological analysis. Testicular tissue samples were fixed in 10% neutral formaldehyde for 48 h at room temperature (RT), dehydrated and embedded in paraffin. Cross-sections of 4-μm thickness were sliced from the paraffin blocks using a microtome (Thermo Fisher Scientific, Inc.). The sections were deparaffinized in xylenes using three changes for 10 min each at RT and rehydrated in a descending ethanol series. Tissue specimens were stained with H&E for 10 min at RT and examined using a Nikon Eclipse 80i light microscope (Nikon Corporation). Histopathological changes in the testicular specimens were evaluated according to a four-level grading system proposed by Cosentino *et al* (28) (Table I). Spermatogenesis was quantified based on the profile of the cells that existed along the seminiferous tubules. A total of 50 seminiferous tubules were evaluated in each specimen and graded 1-10 according to Johnsen's scoring system (Table II) (29). Additionally, diameters (μm) of 50 randomly selected circular seminiferous tubules per specimen were measured and the mean seminiferous tubular diameter was calculated.

Immunohistochemistry. The paraffin embedded sections were deparaffinized and rehydrated in a descending alcohol series. For heat-induced antigen retrieval, the sections were placed in

Table I. Cosentino's *et al* (17) classification of testicular damage.

Score	Features
Grade 1	Normal testicular structure with an orderly arrangement of germinal cells
Grade 2	Less orderly, non-cohesive germinal cells and closely packed seminiferous tubules
Grade 3	Disordered sloughed germinal cells with shrunken pyknotic nuclei and impaired borders of the seminiferous tubules
Grade 4	Seminiferous tubules tightly surrounded by coagulative necrosis of germinal cells

Table II. Johnsen scoring system (18).

Score	Features
10	Complete spermatogenesis with several spermatozoa and regular tubules
9	Slightly impaired spermatogenesis with several late spermatids and disorganized germinal epithelium
8	Less than five spermatozoa per tubule with a few late spermatids
7	No spermatozoa and late spermatids, several early spermatids
6	No spermatozoa and late spermatids, few early spermatids
5	No spermatozoa or spermatids, several spermatocytes
4	No spermatozoa or spermatids, few spermatocytes
3	Only spermatogonia
2	No germinal cells, Sertoli cells only
1	No seminiferous epithelium

citrate buffer (pH 6.0) and boiled 3 times for 5 min each using a microwave oven at 700 W. Endogenous peroxidase activity was blocked with 3% H_2O_2 and the epitopes were stabilized using serum blocking solution (Ultra V Block) for 5 min at RT (Thermo Fisher Scientific, Inc.). Sections were then incubated overnight at 4˚C with PBS containing primary antibodies against Bax (1:100; cat. no. E-AB-33819; Elabscience Biotechnology, Inc.), Bcl-2 (1:100; cat. no. E-AB-60012; Elabscience Biotechnology, Inc.), caspase-3 (1:100; cat. no. E-AB-63602; Elabscience Biotechnology, Inc.) and p53 (1:100; cat. no. E-AB-60866; Elabscience Biotechnology, Inc.). Following incubation with primary antibody, the sections were incubated with biotinylated goat anti-polyvalent secondary antibody and streptavidin peroxidase (cat. no. TP-125-HL; Thermo Fisher Scientific, Inc.) for 10 min each at RT. PBS was used to wash the sections between each step. The binding sites of antibody were visualized using 3,3'-diaminobenzidine (Thermo Fisher Scientific, Inc.). The sections were counterstained with Harris's hematoxylin for 30 sec at RT, evaluated under a Nikon Eclipse 80i light microscope (magnification, x100; Nikon Corporation). ImageJ analysis software (version 1.52; National Institutes of Health) was used to assess staining intensity of the antibodies in testis tissues (30). Average signal levels in 20 seminiferous tubules in each tissue were measured.

Biochemical evaluations. Testicular tissues were washed with cold NaCl solution (0.154 M) to discard blood contamination and then homogenized in a Diax 900 (Heidolph Instruments GmbH and Co KG) at 1,000 rpm for ~3 min. After centrifugation at 10,000 x g for ~60 min at 4˚C, the upper clear supernatant was subjected to further analysis.

Malondialdehyde (MDA) levels were measured using the spectrophotometric thiobarbituric acid reactive substances method developed by Van Ye *et al* (31) and Hodges *et al* (32) that is based on the reactivity towards thiobarbituric acid. MDA reacts with thiobarbituric acid at 90-100˚C and produces a pink dye that has an absorption maximum at 532 nm wavelength. To ensure protein precipitation, the sample was mixed at room temperature with cold 20% (w/v) trichloroacetic acid and the precipitate was then centrifuged for 10 min at 1,207 x g at room temperature. An aliquot of the supernatant was then placed into an equal volume of 0.6% (w/vol) thiobarbituric acid in a boiling water bath for 30 min. Following cooling, sample and blank absorbance were read at 532 nm wavelength and the results expressed as nmol/mg protein, based on a graph where 1,1,3,3-tetramethoxypropane was used as MDA standard.

Catalase (CAT) activity was measured using the method developed by Aebi (33) that is based on the measurement of absorbance decrease due to H_2O_2 consumption at 240 nm. The serum paraoxonase-1 (PON-1) activity was measured based on the hydrolysis rate of paraoxon (MilliporeSigma) that was measured by monitoring the increase of absorbance at 405 nm wavelength at 25˚C. The basal assay mixture included 1.0 mM paraoxon and 1.0 mM CaCl2 in Tris/HCl buffer (pH 8.0; 100 mM). The definition of 1 unit of paraoxonase activity was taken as 1 mmol of p-nitrophenol formed per min (34).

Glutathione S-transferases (GST) activity was measured using the method described by Habig *et al* (35). The GST activity method is based on the measurement of absorbance increase at 340 nm wavelenght due to the reduction of of 2,4-dinitrophenyl-β-D-glucopyranoside (DNPG). The PON activity was measured with the method based on the

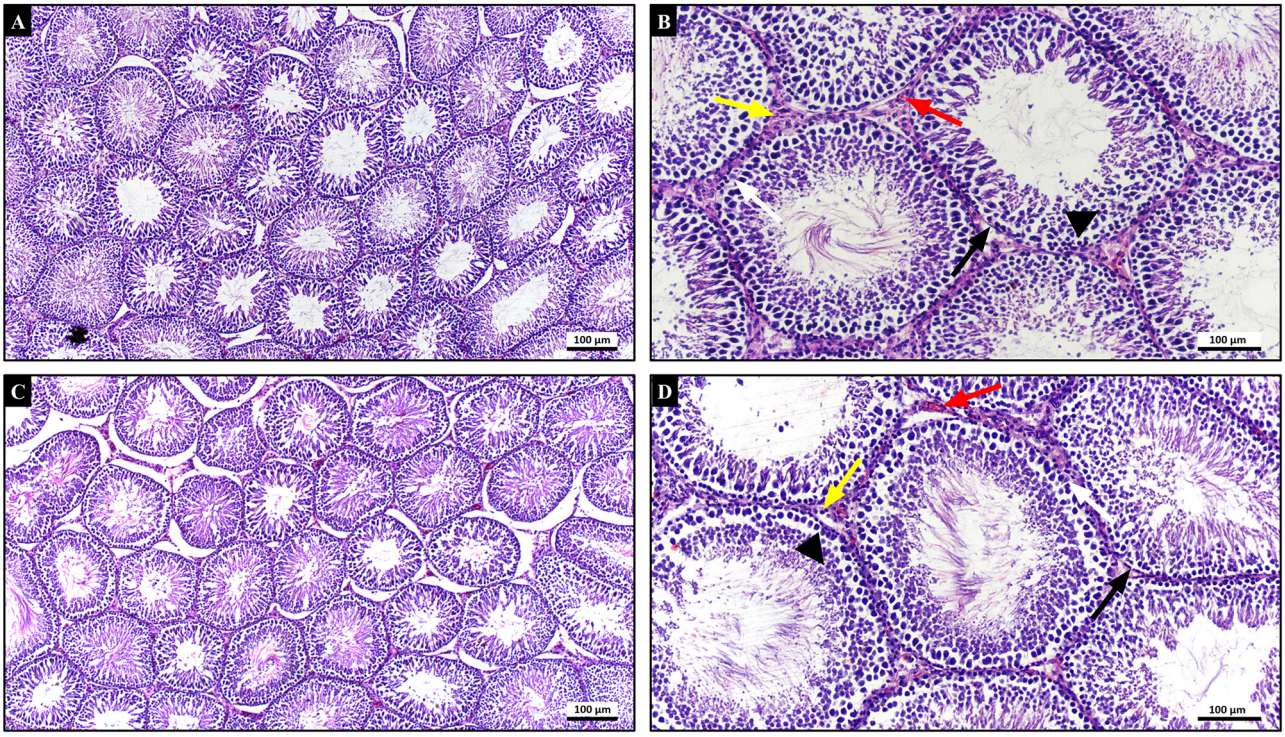

Figure 1. Representative photomicrographs of H&E stained testicular sections. (A and B) Control and (C and D) CeO_2 groups showing regular seminiferous tubule morphology with orderly arranged germinal cells (arrowheads) between Sertoli cells (white arrows) resting on intact basement membrane (black arrows). Tubules are separated by normal interstitial tissue containing Leydig cells (yellow arrows) located around blood vessels (red arrows). Scale bars, 100 μm. H&E, hematoxylin and eosin.

p-nitrophenol formation in the presence of PON, in which paraoxon was used as a substrate. For the analysis, the p-nitrophenol was measured, and formed with paraoxon (diethyl p-nitrophenyl phosphate, 1 mM) in 50 mM glycine/NaOH (pH 10.5) containing 2 mM $CaCl_2$ at 25˚C and 412 nm. The molar extinction coefficient of p-nitrophenol (e=18.290 M/cm) was used in the calculation of the PON enzyme activity. The results were expressed in IU/mg protein. Chemicals were purchased from MilliporeSigma.

Statistical analysis. SPSS statistical software, version 24.0 (IBM Corp.) was used for statistical analyses. The distribution of data was analysed with the Shapiro-Wilk test and Q-Q plot test. The results were analysed using the Kruskal-Wallis test followed by Dunn's test or one-way ANOVA followed by Tukey's test. All quantitative data are expressed as means±standard deviation. P<0.05 was considered to indicate a statistically significant difference.

Results

Histopathological findings. In the histopathological examination of testicular tissues of both control (Fig. 1A and B) and CeO_2 (Fig. 1C and D) groups, seminiferous tubules bound by basement membrane had normal morphology. Developing germinal cells arranged in orderly layers and Sertoli cells with their normal appearance were lining the seminiferous tubules. Leydig cells and blood vessels in interstitial connective tissue displayed their normal histological structure. Therefore, these two groups had a grade 1 testicular damage with a total score of 1. Rats in the T/D group had severe testicular degenerative changes characterized by loss of cohesion of germinal cells, sloughed germinal cells within the seminiferous tubules and coagulative necrosis with loss of seminiferous tubule epithelium (Fig. 2). Boundaries of some tubules were unclear and germinal cells were dispersed. Haemorrhage and oedema were prominent in the interstitial area. In the T/D + CeO_2 group, seminiferous tubules were relatively intact and germinal cells were more cohesive compared with those in the T/D group. In some tubules, degenerated sloughed germinal cells and multinucleated giant cells were present. Tubular atrophy decreased and only a few tubules displayed irregularities in boundaries. Haemorrhage and vascular oedema were also decreased in comparison with that in the T/D group (Fig. 3). The testicular injury Cosentino's score was significantly increased in the T/D group (3.51±0.15) compared with the control (1.05±0.06) and CeO_2 group (1.03±0.04) (P<0.0001; Fig. 4A). Rats in the T/D + CeO_2 (2.36±0.31) group demonstrated significantly milder tissue lesions compared with those in T/D group (P<0.0001; Fig. 4A) and close to normal appearance was observed. These findings indicate that CeO_2 treatment ameliorates testicular injury caused by T/D.

The results of Johnsen's scoring demonstrated that spermatogenesis was normal in both control (9.33±0.71) and CeO_2 groups (9.17±0.83) (Fig. 4B). In the T/D group, the Johnsen's score (6.98±1.07) decreased significantly compared with the control and CeO_2 groups (P<0.0001; Fig. 4B). A significant increase in Johnsen's score was observed in the T/D + CeO_2 group (8.05±0.92) compared with the T/D group (P<0.0001; Fig. 4B). This suggests that CeO_2 helps to maintain spermatogenesis activity at testicular T/D.

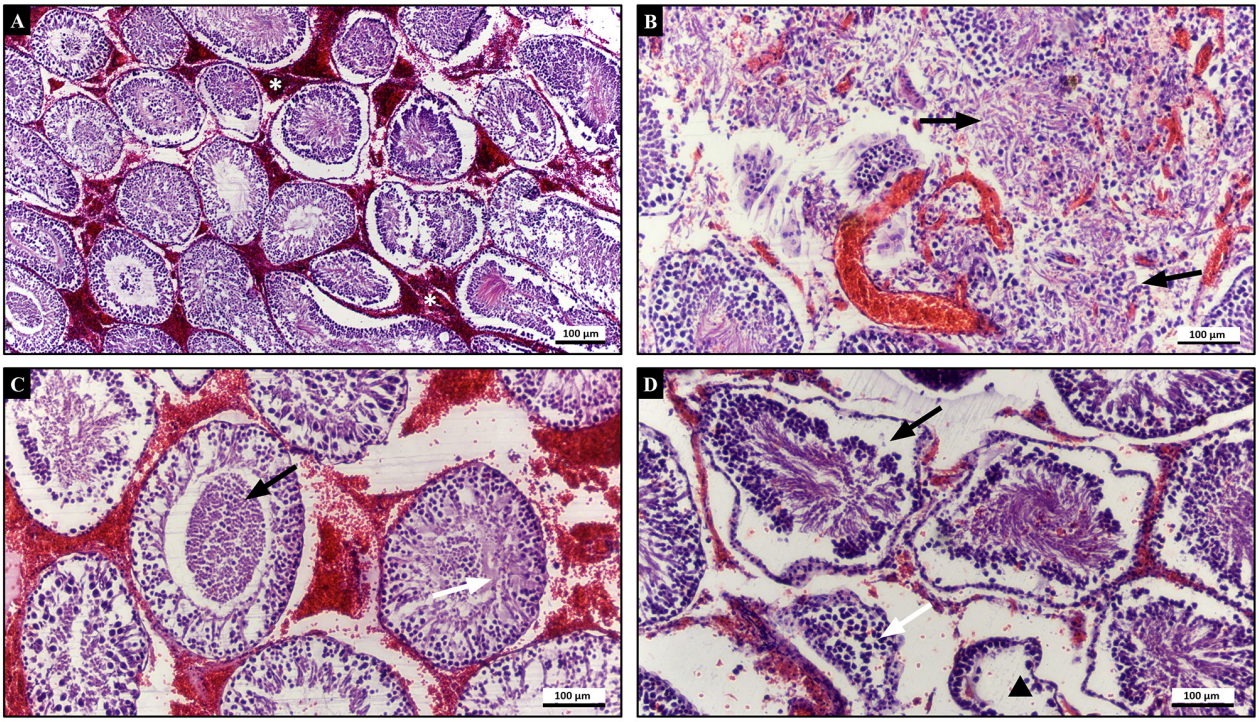

Figure 2. Representative photomicrographs of H&E stained testicular sections of T/D group. (A) Haemorrhage and oedema (asterisk) in the interstitial area. (B) Indistinctive impaired borders of the seminiferous tubules (black arrows). (C) Disordered sloughed germinal cells with shrunken pyknotic nuclei (black arrow) and hyalinization of the seminiferous tubules (white arrow). (D) Detachment of the germinal cells from the basement membrane (black arrow), shrunken tubules (white arrow) and atrophy of germinal epithelium (arrowhead). Scale bars, 100 μm. T, torsion; D, detorsion. H&E. hematoxylin and eosin.

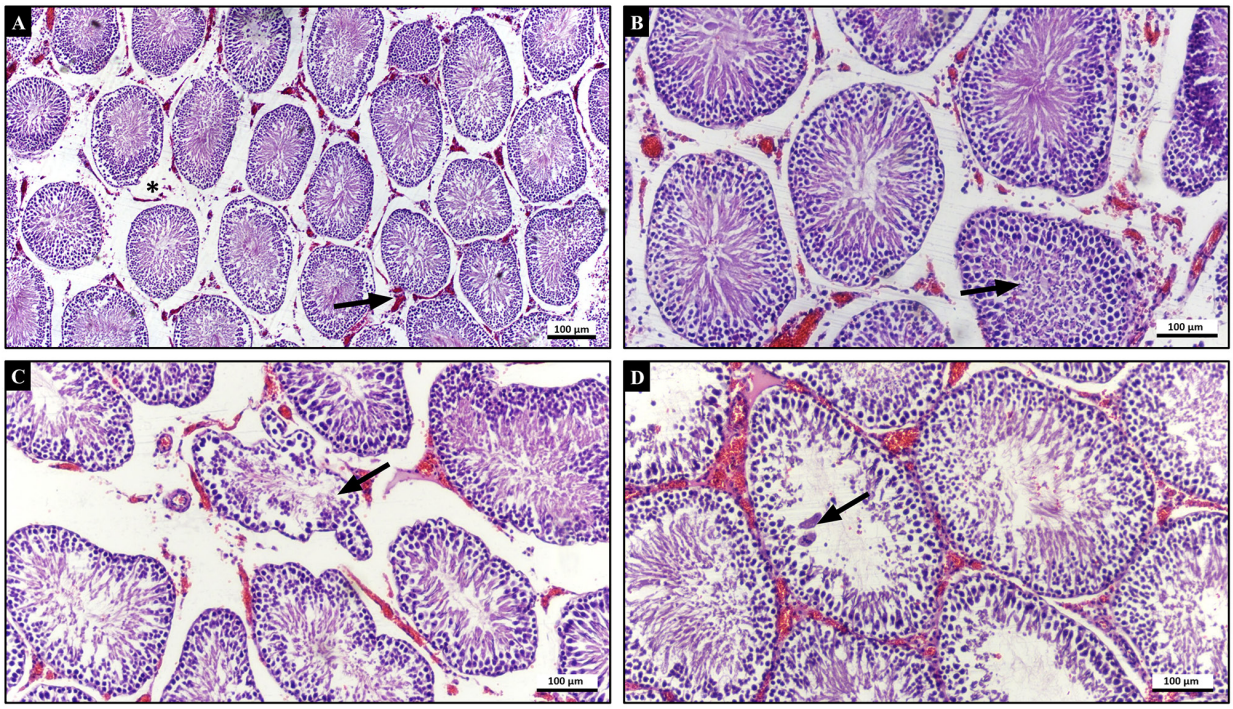

Figure 3. Representative photomicrographs of H&E stained testicular sections of T/D + CeO_2 group. (A) Intact seminiferous tubules with cohesive germinal cells attached to the basement membrane and regressed haemorrhage (arrow). (B) Tubules displaying sloughed germinal cells (arrow). (C) degenerated germinal cells (arrow). (D) Multinucleated giant cells (arrow). Scale bars, 100 μm. T, torsion; D, detorsion; H&E, hematoxylin and eosin.

When seminiferous tubular diameter measurements were evaluated among the groups, a significant decrease was revealed in T/D group (289.21±25.68) compared with the control (329.05±32.36) and CeO_2 (327.06±33.88) groups ($P<0.0001$; Fig. 4C). In the T/D + CeO_2 group tubule diameter increased significantly (308.52±28.60) compared to the

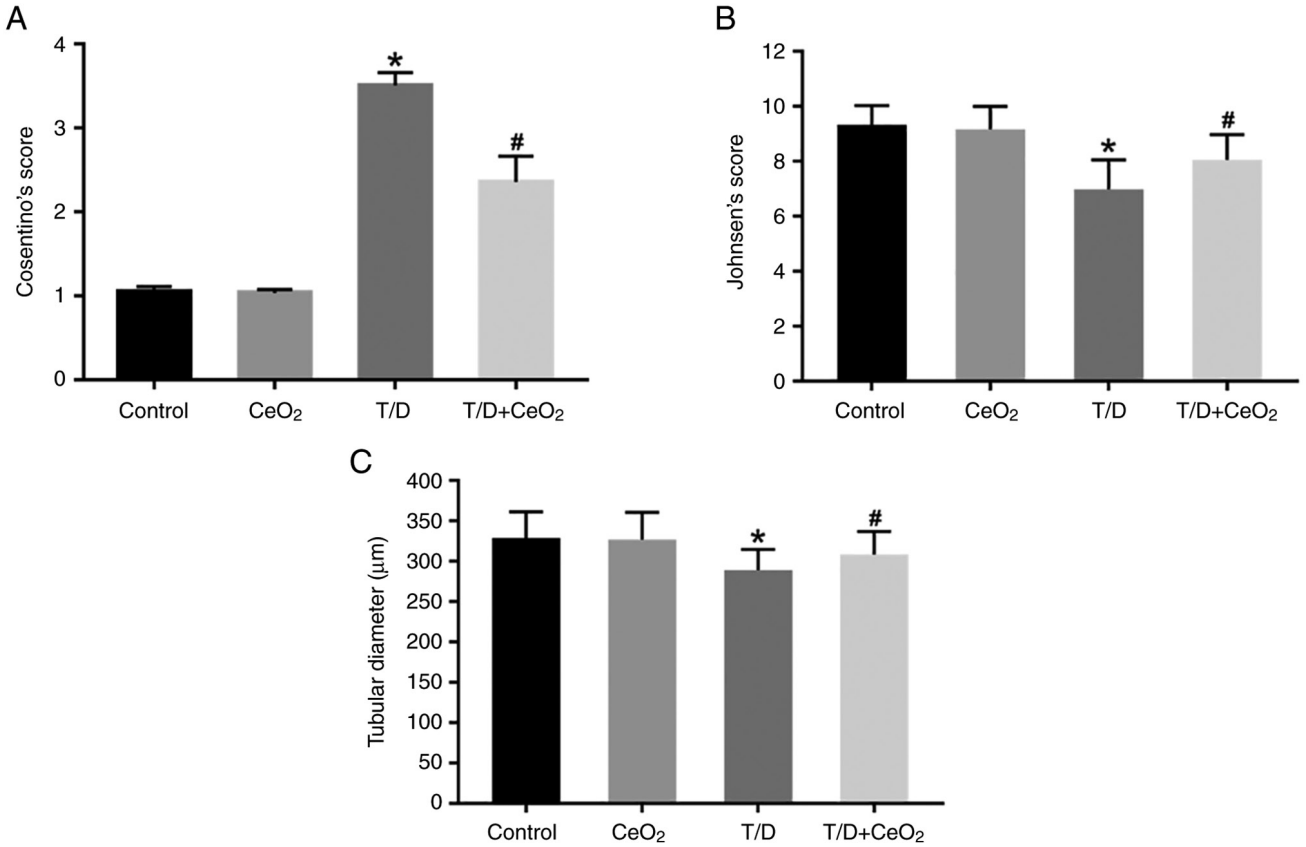

Figure 4. Quantitative evaluation of tubular damage. Comparisons among groups in terms of (A) Cosentino's score, (B) Johnsen's score and (C) seminiferous tubule diameter indicate that CeO_2 treatment reduced the T/D related tissue lesions in rat testis. *P<0.0001 vs. control group and CeO_2 group. #P<0.0001 vs. T/D group. T, torsion; D, detorsion; CeO_2, Cerium oxide.

Table III. Comparison of staining intensity of the apoptosis-related proteins between groups.

Protein	Control (n=6)	CeO_2 (n=6)	T/D (n=6)	T/D + CeO_2 (n=6)	Multiple comparison	P-value
Bax	24.61±3.67	21.81±3.21[a,b]	128.68±7.27[a]	65.99±6.39[a,b]	Control vs. CeO_2	0.0026
					Control vs. T/D	<0.0001
					Control vs. T/D + CeO_2	<0.0001
					T/D vs. CeO_2	<0.0001
					T/D vs. T/D + CeO2	<0.0001
Bcl-2	117.77±8.01	107.59±12.32[a,b]	32.20±4.43[a]	63.16±6.21[a,b]	Control vs. CeO_2	0.0001
					Control vs. T/D	<0.0001
					Control vs. T/D+CeO_2	<0.0001
					T/D vs. CeO_2	<0.0001
					T/D vs. T/D+ CeO2	<0.0001
Caspase-3	19.34±2.27	21.81±2.80[b]	78.07±5.45[a]	35.60±3.39[a,b]	Control vs. CeO_2	0.1098
					Control vs. T/D	<0.0001
					Control vs. T/D+CeO_2	<0.0001
					T/D vs. CeO_2	<0.0001
					T/D vs. T/D+ CeO2	<0.0001
p53	36.97±4.77	35.42±4.45[a,b]	104.75±4.63[a]	80.79±6.18[a,b]	Control vs. CeO_2	<0.0001
					Control vs. T/D	<0.0001
					Control vs. T/D+CeO_2	<0.0001
					T/D vs. CeO_2	<0.0001
					T/D vs. T/D+ CeO2	<0.0001

Values are expressed as mean ± standard deviation. [a]Statistically different from the control group (P<0.05). [b]Statistically different from the T/D group (P<0.05). CeO_2, cerium oxide; T, torsion; D, detorsion.

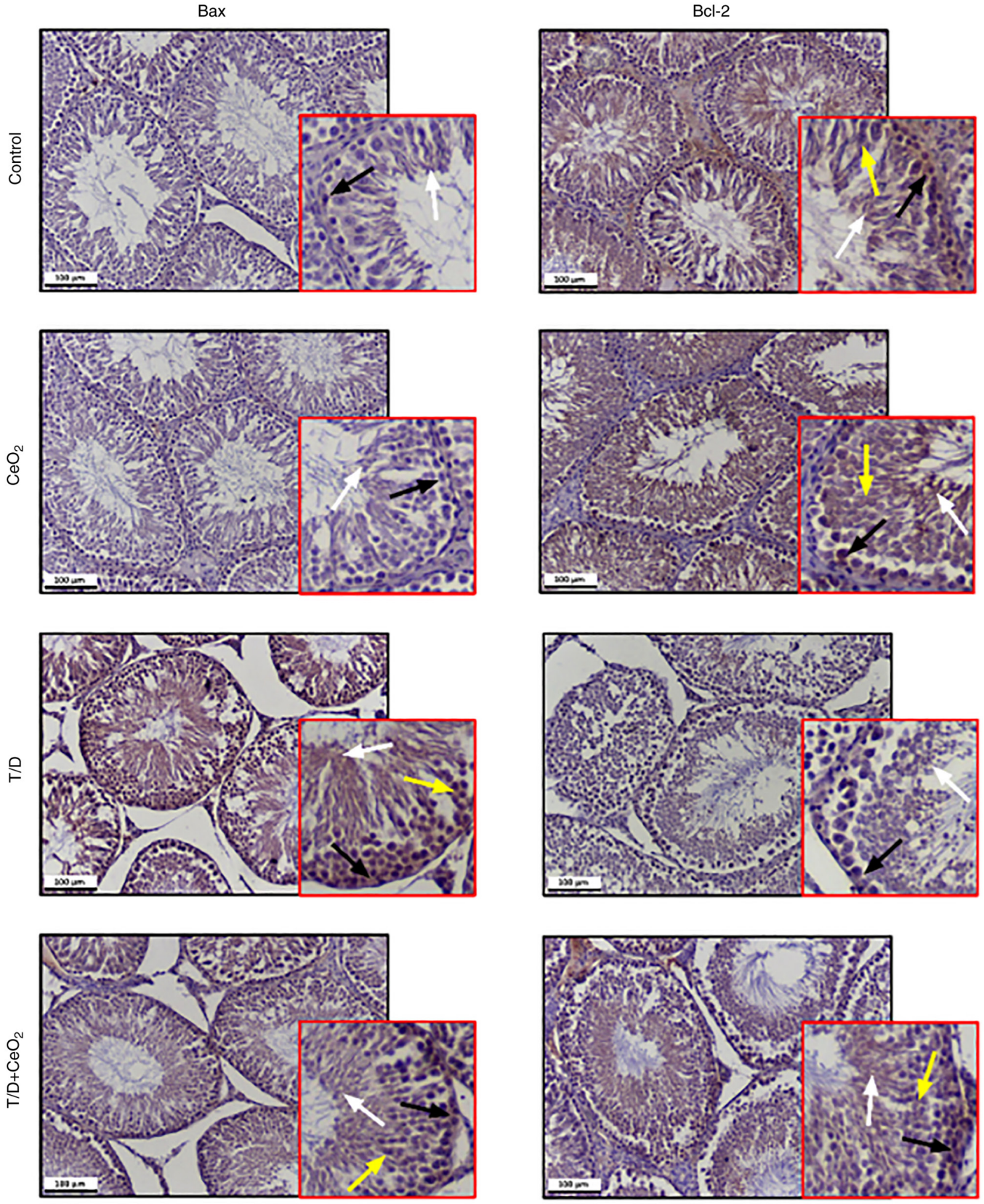

Figure 5. Immunohistochemical analysis of Bax and Bcl-2 proteins in testicular tissue. T/D group shows higher Bax and lower Bcl-2 protein expression compared with the control and CeO_2 treated group. T/D + CeO_2 group shows lower Bax expression and higher Bcl-2 protein expression compared with the T/D group. Black, yellow and white arrows indicate the Bax- and Bcl-2-positive spermatogonia, spermatocytes and spermatozoa, respectively. Scale bars, 100 μm. T, torsion; D, detorsion; CeO_2, Cerium oxide.

Table IV. MDA level and CAT, GST and PON-1 enzyme activities.

Features	Control (n=6)	CeO_2 (n=6)	T/D (n=6)	T/D + CeO_2 (n=6)	Multiple Comparison	P-value
MDA, nmol/mg protein	3.98±1.03	4.10±0.48[a]	7.06±2.82[b]	4.31±0.82[a]	Control vs. CeO_2	0.894
					Control vs. T/D	0.003
					Control vs. T/D + CeO_2	0.720
					T/D vs. CeO_2	0.004
					T/D vs. T/D + CeO_2	0.007
CAT, IU/mg	238.04±43.40	299.19±65.49[a]	1,201.68±243.47[b]	642.18±117.14[a]	Control vs. CeO_2	0.762
					Control vs. T/D	<0.0001
					Control vs. T/D + CeO_2	0.056
					T/D vs. CeO_2	<0.0001
					T/D vs. T/D + CeO2	0.011
GST, mIU/mg	36.66±8.73	38.36±4.52	45.65±8.09[b]	35.28±2.75[a]	Control vs. CeO_2	0.657
					Control vs. T/D	0.027
					Control vs. T/D + CeO_2	0.719
					T/D vs. CeO_2	0.067
					T/D vs. T/D + CeO2	0.012
PON-1, U/mg	3.06±0.77	2.72±0.51[a]	1.03±0.25[b]	2.15±0.56	Control vs. CeO_2	0.659
					Control vs. T/D	0.011
					Control vs. T/D + CeO_2	0.243
					T/D vs. CeO_2	0.029
					T/D vs. T/D + CeO2	0.171

Values are expressed as mean ± standard deviation. [a]Statistically different from the T/D group (P<0.05). [b]Statistically different from the control group (P<0.05). CeO_2, cerium oxide; T, torsion; D, detorsion; MDA, malondialdehyde; CAT, catalase; GST, Glutathione S-transferases; PON-1, serum paraoxonase-1.

T/D group (P<0.0001; Fig. 4C), indicating that CeO_2 retains the diameter of the seminiferous tubules, which are the sites where spermatogenesis takes place.

Immunohistochemical expression of apoptosis-related proteins. Immunohistochemical analysis of the Bax/Bcl-2 expression demonstrated that rats in the control and CeO_2 groups had low Bax expression in a few spermatogonia and spermatozoa and high Bcl-2 expression in all germinal cells including spermatogonia, spermatocytes, spermatids and spermatozoa (Fig. 5). The T/D group demonstrated increased Bax and decreased Bcl-2 expression levels in their seminiferous tubules compared with the control and CeO_2 groups (Fig. 5). Significant downregulation of Bax and upregulation of Bcl-2 was observed in the T/D + CeO_2 group compared to the T/D group (Table III). Moreover, very low expression levels of caspase 3 were observed in some spermatogonial cells of both control and CeO_2 groups (Fig. 6). The expression of caspase-3 throughout the seminiferous tubules was increased in the T/D group compared with the control and CeO_2 groups, while it was reduced in the T/D + CeO_2 group compared with the T/D group (Fig. 6). The expression of p53 was upregulated in all germinal cells in the T/D group compared with the control and CeO_2 groups that displayed low expression. The T/D + CeO_2 group demonstrated a significant decrease in the p53 expression level compared with the T/D group (Fig. 6). Together, these findings suggest that CeO_2 is able to suppress the T/D-induced apoptotic pathway. Table III shows statistical comparison of the expression levels of apoptosis proteins between groups.

Biochemical analysis. MDA level was significantly increased in the T/D group compared with the control (P=0.003) and CeO_2 (P=0.004) groups in the testicular tissue (Table IV). A significantly decrease in the MDA level was observed in the T/D + CeO_2 group compared with T/D group (P=0.007; Table IV).

The CAT enzyme activity in the T/D group was significantly higher compared with that in the control and CeO_2 groups (P<0.0001; Table IV). A significant decrease in CAT enzyme activity was observed in the T/D + CeO_2 group compared with T/D group (P=0.011; Table IV).

The PON-1 enzyme activity in the T/D group was significantly lower compared with that in the control (P=0.011) and CeO_2 (P=0.029) groups (Table IV).

GST enzyme activity was revealed to be significantly increased in the T/D group compared with the control group in the testicular tissue (P=0.027). A significant decrease in GST enzyme activity was observed in the T/D + CeO_2 group compared with T/D group (P=0.012; Table IV).

Discussion

Testicular T can produce germ cell damage, resulting in subfertility or infertility (36). In the present study, I/R damage was the main pathological pathway and the present study aimed to

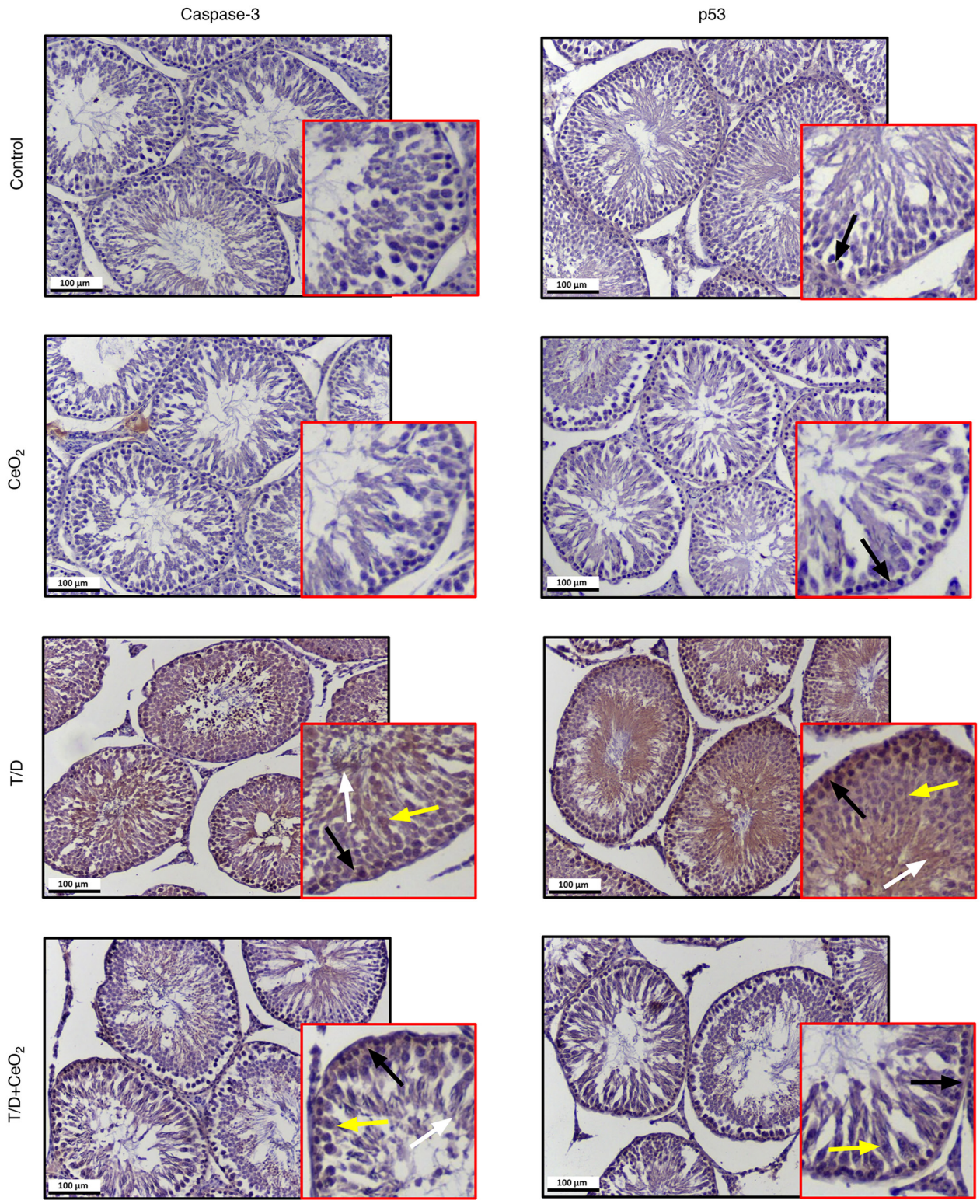

Figure 6. Immunohistochemical analysis of caspase-3 and p53 proteins in testicular tissue. T/D group shows higher caspase-3 and p53 protein expression compared with the control and CeO_2 groups. T/D + CeO_2 group shows caspase-3 and p53 expression in respect to the T/D group. Black, yellow and white arrows in the enlarged micrographs indicate the caspase-3- and p53-positive spermatogonia, spermatocytes and spermatozoa, respectively. Scale bars, 100 μm. T, torsion; D, detorsion; CeO_2, Cerium oxide.

investigate possible treatments for I/R. Some important pathological processes in damage formation are anoxia, increased intracellular Ca^{2+} concentration, leukocyte migration, increase in proinflammatory cytokines and oxidative stress caused by ROS (37,38). The balance between oxidative stress and antioxidant defence is disturbed and a seriesof events that can cause tissue damage are triggered (39,40). It has been reported that the activities of various antioxidant enzymes such as superoxide dismutase (SOD), glutathione peroxidase and CAT increase during I/R injury (41). Additional damage pathways

are apoptosis and programmed cell death (42,43). Oxidative stress has been associated with apoptosis in different cell types, such as germ cells, Sertoli cells and spermatogenic cells (44). Indeed, apoptosis of damaged germ cells is a common response to different noxious stimuli, thereby protecting the next generation of germ cells from the damaged cell population (45-47). Several antioxidants such as N-acetylcysteine, growth factors, carnitine, resveratrol, melatonin, vitamin E have been studied to reduce reperfusion injury (48-50). In the present study, the protective effect of nanoceria with antioxidant and antiapoptotic activity against I/R damage in rat testicles was investigated.

Nanotechnology is making striking developments in different areas of human life (51). Nanoceria is a nanoparticle that has been studied in different oxidative stress models of the testes and has been reported to reduce cell and tissue damage due to its antioxidant properties (25,52). It has been reported that nanoceria reduce tissue damage in lower limbs and liver ischemia reperfusion models with its antioxidant effect (53,54). There are studies reporting that cerium exerts protective and antioxidative effects on testicular tissue in oxidative stress (44,52,55). Nanoceria has been reported to show multienzymatic and mimetic activities, including superoxide oxidase, catalase and oxidase activities (56). Nonetheless, studies on male reproductive system in rats and mice have demonstrated toxicity, disturbing or disrupting the normal activity and function (55-57). These negative effects may be caused by excessively high dose of nanocera, as well as its shape, size, surface charge and the agglomeration state (58-61).

In the present study, nanoceria was injected in rats because of the very low absorption of nanoparticles by inhalation or oral administration (62). The dose of nanoceria is an important factor. The therapeutic efficacy of 0.5 mg/kg used in the present study has been demonstrated in other experimental models (53,63-65). Ozbal *et al* (66) reported that 2 h ischaemia and 2 h reperfusion of the testis causes testicular damage in rats, such as degenerative changes in testis tissue, loss of germinal cells maturation, interstitial oedema and disorganization in the seminiferous tubule. In the present study, statistically significant changes were observed in biochemical markers in the T/D group compared with the control group. MDA level, CAT and GST activities in testicular tissue were revealed to be significantly higher in the T/D group compared with the control group. Significant decreases were observed in these three parameters in the T/D + CeO_2 group compared with the T/D group. PON-1 enzyme activity was significantly decreased in the T/D group compared with the control group. Although there was a relative increase in the T/D + CeO_2 group compared with the T/D group, this was not statistically significant. Post-damage oxidative stress and antioxidant defence markers may differ between studies.

Although SOD and CAT enzymes, which are in the antioxidant enzyme group, generally show similar trends in previous I/R studies, there are also studies with contradictory results. Islekel *et al* (67) reported that SOD activity decreased while CAT activity increased in a brain ischemia reperfusion model. This can be explained by the transient substrate induction proposed by Stanimirovic *et al* (68) in a study with Mongolian gerbils. Free radicals produced by ischemia and reperfusion in the present study may not be enough to affect the three-dimensional structure of CAT, which is normally retained in peroxisomes. A small amount of radicals that are not scavenged by other antioxidant enzymes may diffuse to peroxisomes and cause changes in the enzyme structure, leading to greater accessibility of the enzyme to the substrate molecule and an increase in enzyme activity. It has been reported that I/R damaged tissues have significantly higher antioxidant enzyme activities and MDA levels compared with the control (69,70). A previous study reported an increase in the activities antioxidant enzymes, while a different study reported that their activities decreased depending on the degree of I/R damage in the testicular tissue (71,72). However, other studies have indicated that lipid peroxidation products increase in I/R damaged testes (73,74). Moreover, experimental studies on I/R injury have indicated that antioxidants reduce short-term damage in testicular T (75,76). In general. these previous studies have shown that the applied model is successful in creating oxidative stress and nanoceria can reduce this stress.

Several biomarkers have been identified to accurately assess the apoptotic process (77). Bax, bcl-2, caspase-3 and p-53 protein are the most frequently evaluated markers because of their important roles in the apoptotic pathway. Membrane destabilization resulting from lipid peroxidation causes mitochondrial cytochrome *c* to be released into the cytoplasm (41). The released cytochrome *c* facilitates the formation of apoptosomes. This apoptosome activates initiator caspase-9 and then effector caspase-3, and apoptosis occurs (78). Among the changes resulting from ischemic insult in the different parenchymateous organs, ROS formation and possible apoptotic changes have been the subject of previous studies (11,12).

Apoptosis is an active form of cell death considered to occur in adult tissues in a wide range of physiological settings such as metamorphosis, tissue removal and several other conditions (79). The mechanism of apoptosis mainly consists of two core pathways involved in inducing apoptosis, namely the extrinsic pathway and the intrinsic pathway. Both of these apoptotic pathways may lead to the same result (80,81). In relation to testicular functions, apoptosis of damaged testicular germ cells is a common response to various testicular toxicants such as ischemic insult, varicocele, toxic agents and radiation, therefore protecting the next generations of germ cells from the damaged cell population (82). Several biomarkers have been evaluated for their prognostic value in the apoptotic process and they have been correlated with histological alterations. The overexpression of proteins that regulate apoptosis, including Bcl-2 and p53, is a useful predictor of histologic alterations in various pathologies (83). The p53 gene is regarded as a major tumour-suppressor gene and mutations in the this gene may result in an altered protein expression that has lost its suppressive effect (84). Specific cytoplasmic Bcl-2 antagonizes ischemia-induced apoptotic pathways by inhibiting the release of cytochrome *c* from the mitochondria (85). In response to DNA damage, p53 mediates the cell cycle, as well as apoptosis (86). Therefore, as the regulatory proteins involved in the apoptotic pathway, the expression levels of Bcl-2 and p53 in testicular tissue undergoing a possible ischemic period provides a rational point of investigation.

Another important gene involved in these specific alterations is Bax (87). The expression of this gene is regulated by the tumour suppressor p53 and has been indicated to be involved in p53-mediated apoptosis (88). In the present study,

the immunohistochemical analysis of the apoptotic pathway demonstrated that rats in the control and CeO_2 groups had low Bax expression and high Bcl-2 expression in their germinal cells. The T/D group demonstrated increased Bax and decreased Bcl-2 expression levels in the seminiferous tubules compared with the control and CeO_2 groups. CeO_2 treatment led to downregulation of Bax and upregulation of Bcl-2. Low expression of caspase 3, an important protease activated during apoptosis (89), was observed in spermatogonial cells in both the control and CeO_2 groups compared with the T/D group. The increased caspase-3 expression along with the seminiferous tubules in the T/D group was significantly decreased after CeO_2 treatment in T/D+CeO_2 group. Expression of apoptosis-inducing p53 was upregulated in all germinal cells in the T/D group compared with the control and CeO_2 groups. Rats treated with CeO_2 following T/D demonstrated a significant reduction in p53 expression levels compared with the T/D group. Treatment with CeO_2 reduced the number of apoptotic cells and immune reactivity. The present results indicated that CeO_2 treatment provided positive results in reducing apoptosis, which was similar to studies in which the apoptosis cascade is initiated in different ways such as via toxicity, hypoxia, cytotoxicity, ionizing radiation and DNA damage (90,91).

In the histopathological evaluation, rats in the T/D group had severe testicular degenerative changes characterized by loss of cohesion in germinal cells, shedding of germinal cells within the seminiferous tubules and coagulative necrosis. Testicular injury score was significantly increased in this group compared with the control and CeO_2 groups. Rats in the T/D + CeO_2 group demonstrated milder tissue lesions compared with the T/D group and a near-normal appearance was observed. Seminiferous tubules were relatively intact and germinal cells are more adherent. Germinal cells with degenerated shells and multinucleated giant cells were present in some tubules. Tubular atrophy was decreased and marginal irregularities were observed in only a few tubules. Haemorrhage and vascular oedema were also reduced. Johnsen's scoring results demonstrated that spermatogenesis was normal in both the control and CeO_2 groups, while in the T/D group this was significantly decreased compared with the control and CeO_2 groups. A significant increase was observed in the Johnsen's score in the T/D + CeO_2 group compared with the T/D group. Histopathological results and Johnson's scores are consistent with with the studies from Saleh *et al* (52) and Mousavi *et al* (91).

In the present study CeO_2 significantly reduced testicular damage after testicular T/D and increased the Johnsen's score in histopathological examination. The increased MDA levels, SOD and GST activities along with decreased PON-1 activities in testicular tissues may reflect cellular oxidative stress or an involvement of these enzymes in compensatory mechanisms. CeO_2 treatment significantly reduced the expression of caspase-3 and p53 in the seminiferous tubules. In the biochemical analysis, a significant decrease in MDA level and CAT activity, along with a significant decrease in GST enzyme activity, were detected after CeO_2 treatment. The present results demonstrated that CeO_2 had a positive effect after testicular T/D.

Acknowledgements

Not applicable.

Funding

No funding was received.

Availability of data and materials

The datasets used and/or analyzed during the current study are available from the corresponding author on reasonable request.

Authors' contributions

AA, SY and MK were responsible for designing the study, and analyzing and interpreting the data. CO performed the study in the laboratory in accordance with the methodology. MA was responsible for the acquisition, analysis and interpretation of the data. MA and SY confirm the authenticity of all the raw data. ACG and MK provided scientific and technical assistance to the experiments, and critically revised the article for important intellectual content. SY collected samples and was responsible for the execution of the project. ACG was responsible for the cellular and molecular experiments. All authors read and approved the final manuscript.

Ethics approval and consent to participate

Ethical approval for the study was obtained from Gazi University Experimental Animals Ethics Committee (Ankara, Turkey; approval no. G.U.ET-19-059).

Patient consent for publication

Not applicable.

Competing interests

The authors declare that they have no competing interests.

References

1. Sharp VJ, Kieran K and Arlen AM: Testicular torsion: Diagnosis, evaluation, and management. American Family Physician 88: 835-840, 2013.
2. Selbst SM, Friedman MJ and Singh SB: Epidemiology and etiology of malpractice lawsuits involving children in US emergency departments and urgent care centers. Pediatr Emerg Care 21: 165-169, 2005.
3. Bo X, Wang P, Nie Y, Li R, Lu J and Wang H: Protective effect of hypothermia and vitamin E on spermatogenic function after reduction of testicular torsion in rats. Exp Ther Med 20: 796-801, 2020.
4. Ringdahl E and Teague L: Testicular torsion. Am Fam Physician 74: 1739-1743, 2006.
5. Pogorelić Z, Mustapić K, Jukić M, Todorić J, Mrklić I, Meššrović J, Jurić I and Furlan D: Management of acute scrotum in children: A 25-year single center experience on 558 pediatric patients. Can J Urol 23: 8594-8601, 2016.
6. Celik E, Oguzturk H, Sahin N, Turtay MG, Oguz F and Ciftci O: Protective effects of hesperidin in experimental testicular ischemia/reperfusion injury in rats. Arch Med Sci 12: 928-934, 2016.
7. Minutoli L, Antonuccio P, Polito F, Bitto A, Fiumara T, Squadrito F, Nicotina PA, Arena S, Marini H, Romeo C and Altavilla D: Involvement of mitogen-activated protein kinases (MAPKs) during testicular ischemia-reperfusion injury in nuclear factor-kappaB knock-out mice. Life Sci 81: 413-242, 2007.
8. Akbas H, Ozden M, Kanko M, Maral H, Bulbul S, Yavuz S, Ozker E and Berki T: Protective antioxidant effects of carvedilol in a rat model of ischaemia-reperfusion injury. J Int Med Res 33: 528-536, 2005.

9. Unsal A, Eroglu M, Avci A, Cimentepe E, Guven C, Derya Balbay M and Durak I: Protective role of natural antioxidant supplementation on testicular tissue after testicular torsion and detorsion. Scand J Urol Nephrol 40: 17-22, 2006.
10. Chi KK, Zhang WH, Wang GC, Chen Z, He W, Wang SG, Cui Y, Lu P, Wang XJ and Chen H: Comparison of intraperitoneal and intraepididymal quercetin for the prevention of testicular torsion/detorsion-induced injury. Urology 99: 106-111, 2017.
11. Filho DW, Torres MA, Bordin AL, Crezcynski-Pasa TB and Boveris A: Spermatic cord torsion, reactive oxygen and nitrogen species and ischemia-reperfusion injury. Mol Aspects Med 25: 199-210, 2004.
12. Nicoud IB, Knox CD, Jones CM, Anderson CD, Pierce JM, Belous AE, Earl TM and Chari RS: 2-APB protects against liver ischemia-reperfusion injury by reducing cellular and mitochondrial calcium uptake. Am J Physiol Gastrointest Liver Physiol 293: G623-G30, 2007.
13. Vercesi AE, Castilho RF, Kowaltowski AJ, de Oliveira HCF, de Souza-Pinto NC, Figueira TR and Busanello ENB: Mitochondrial calcium transport and the redox nature of the calcium-induced membrane permeability transition. Free Radic Biol Med 29: 1-24, 2018.
14. Gaschler MM and Stockwell B: Lipid peroxidation in cell death. Biochem Biophys Res Commun 482: 419-425, 2017.
15. Turner TT and Lysiak JJ: Oxidative stress: A common factor in testicular dysfunction. J Androl 29: 488-498, 2008.
16. Chan WC and Nie S: Quantum dot bioconjugates for ultra sensitive nonisotopic detection. Science 281: 2016-2018, 1998.
17. Vaseashta A and Dimova-Malinovska D: Nanostructured and nanoscale devices, sensors and detectors. Sci Technol Adv Mater 6: 312, 2005.
18. Langer R: Drugs on target. Science 293: 58-59, 2001.
19. Roy K, Mao HQ, Huang SK and Leong KW: Oral gene delivery with chitosan-DNA nanoparticles generates immunologic protection in a murine model of peanut allergy. Nat Med 5: 387, 1999.
20. Sachlos E, Gotora D and Czernuszka JT: Collagen scaffolds reinforced with biomimetic composite nano-sized carbonate-substituted hydroxyapatite crystals and shaped by rapid prototyping to contain internal microchannels. Tissue Eng 12: 2479-2487, 2006.
21. Farokhzad OC, Cheng J, Teply BA, Sherifi I, Jon S, Kantoff PW, Richie JP and Langer R: Targeted nanoparticle-aptamer bioconjugates for cancer chemotherapy in vivo. Proc Natl Acad Sci USA 103: 6315, 2006.
22. Kim J, Kim HY, Song SY, Go SH, Sohn HS, Baik S, Soh M, Kim K, Kim D, Kim HC, *et al*: Synergistic oxygen generation and reactive oxygen species scavenging by manganese ferrite/ceria co-decorated nanoparticles for rheumatoid arthritis treatment. ACS Nano 13: 3206-3217, 2019.
23. Celardo I, De Nicola M, Mandoli C, Pedersen JZ, Traversa E and Ghibelli L: Ce^{3}+ Ions determine redox-dependent anti-apoptotic effect of cerium oxide nanoparticles. ACS Nano 5: 4537-4549, 2011.
24. Heckert EG, Karakoti AS, Seal S and Self WT: The role of cerium redox state in the SOD mimetic activity of nanoceria. Biomaterials 29: 2705-2709, 2008.
25. Moridi H, Hosseini SA, Shateri H, Kheiripour N, Kaki A, Hatami M and Ranjbar A: Protective effect of cerium oxide nanoparticle on sperm quality and oxidative damage in malathion-induced testicular toxicity in rats: An experimental study. Int J Reprod Biomed 16: 261-266, 2018.
26. Shcherbakov AB, Reukov VV, Yakimansky AV, Krasnopeeva EL, Ivanova OS, Popov AL and Ivanov VK: CeO_2 nanoparticle-containing polymers for biomedical applications: A review. Polymers (Basel) 13: 924, 2021.
27. Singh S, Kumar U, Gittess D, Sakthivel TS, Babu B and Seal S: Cerium oxide nanomaterial with dual antioxidative scavenging potential: Synthesis and characterization. J Biomater Appl 36: 834-842, 2021.
28. Cosentino MJ, Nishida M, Rabinowitz R and Cockett AT: Histopathology of prepubertal rat testes subjected to various durations of spermatic cord torsion. J Androl 7: 23-31, 1986.
29. Johnsen SG: Testicular biopsy score count-a method for registration of spermatogenesis in human testes: Normal values and results in 335 hypogonadal males. Hormones 1: 2-25, 1970.
30. Crowe AR and Yue W: Semi-quantitative determination of protein expression using immunohistochemistry staining and analysis: An integrated protocol. Bio Protoc 9: e3465, 2019.
31. Van Ye TM, Roza AM, Pieper GM, Henderson J Jr, Johnson CP and Adams MB: Inhibition of intestinal lipid peroxidation does not minimize morphologic damage. J Surg Res 55: 553-558, 1993.
32. Hodges DM, DeLong JM, Forney CF and Prange RK: Improving the thiobarbituric acid reactive substances assay for estimating lipid peroxidation in plant tissues containing anthocyanin and other interfering compounds. Planta 207: 604–611, 1999.
33. Aebi H: Catalase. In: H.U.Bergmeyer (Ed): Methods of Enzymatic Analysis, Academic Press, New York and London, pp673-677, 1974.
34. Brites FD, Verona J, Schreier LE, Fruchart JC, Castro GR and Wikinski RL: Paraoxonase 1 and platelet-activating factor acetylhydrolase activities in patients with low hdl-cholesterol levels with or without primary hypertriglyceridemia. Arch Med Res 35: 235-240, 2004.
35. Habig WH, Pabst MJ and Jakoby WB: Glutathione S-transferases. The first enzymatic step in mercapturic acid formation. J Biol Chem 249: 7130-7139, 1974.
36. Bodur A, Alver A, Kahraman C, Altay DU and İnce İ: Investigation of N-acetylcysteine on contralateral testis tissue injury by experimental testicular torsion: Long-term effect. Am J Emerg Med 34: 1069-1074, 2016.
37. Mallick IH, Yang W, Winslet MC and Seifalian AM: Ischemia-reperfusion injury of the intestine and protective strategies against injury. Dig Dis Sci 49: 1359-1377, 2004.
38. Ustün H, Akgül KT, Ayyildiz A, Yağmurdur H, Nuhoğlu B, Karagüzel E, Oğüş E and Germiyanoğlu C: Effect of phospodiesterase 5 inhibitors on apoptosis and nitric oxide synthases in testis torsion: An experimental study. Pediatr Surg Int 24: 205-211, 2008.
39. Kazez A, Demirbağ M, Ustündağ B, Ozercan IH and Sağlam M: The role of melatonin in prevention of intestinal ischemia-reperfusion injury in rats. J Pediatr Surg 35: 1444-1448, 2000.
40. Ates B, Yilmaz I, Geckil H, Iraz M, Birincioglu M and Fiskin K: Protective role of melatonin given either before ischemia or prior to reperfusion on intestinal ischemia-reperfusion damage. J Pineal Res 37: 149-152, 2004.
41. Elahi MM, Kong YX and Matata BM: Oxidative stress as a mediator of cardiovascular disease. Oxid Med Cell Longev 2: 259-269, 2009.
42. McCord JM: Oxygen-derived free radicals in postischemic tissue injury. N Engl J Med 312: 159-163, 1985.
43. Su LJ, Zhang JH, Gomez H, Murugan R, Hong X, Xu D, Jiang F and Peng ZY: Reactive oxygen species-induced lipid peroxidation in apoptosis, autophagy, and ferroptosis. Oxid Med Cell Longev 2019: 5080843, 2019.
44. Kasahara E, Sato EF, Miyoshi M, Konaka R, Hiramoto K, Sasaki J, Tokuda M, Nakano Y and Inoue M: Role of oxidative stress in germ cell apoptosis induced by di(2-ethylhexyl) phthalate. Biochem J 365: 849-56, 2002.
45. Lin WW, Lamb DJ, Wheeler TM, Abrams J, Lipshultz LI and Kim ED: Apoptotic frequency is increased in spermatogenic maturation arrest and hypospermatogenic states. J Urol 158: 1791-1793, 1997.
46. Shin JH, Mori C and Shiota K: Involvement of germ cell apoptosis in the induction of testicular toxicity following hydroxyurea treatment. Toxicol Appl Pharmacol 155: 139-149, 1999.
47. Tesarik J, Greco E, Cohen-Bacrie P and Mendoza C: Germ cell apoptosis in men with complete and incomplete spermiogenesis failure. Mol Hum Reprod 4: 757-762, 1998.
48. Payabvash S, Salmasi AH, Kiumehr S, Tavangar SM, Nourbakhsh B, Faghihi SH and Dehpour AR: Salutary effects of N-acetylcysteine on apoptotic damage in a rat model of testicular torsion. Urol Int 79: 248-254, 2007.
49. Suwalsky M, F Villena and Gallardo MJ: In vitro protective effects of resveratrol against oxidative damage in human erythrocytes. Biochim Biophys Acta 1848: 76-82, 2015.
50. Espino J, Bejarano I, Ortiz A, Lozano GM, García JF, Pariente JA and Rodríguez AB: Melatonin as a potential tool against oxidative damage and apoptosis in ejaculated human spermatozoa. Fertil Steril 94: 1915-1957, 2010.
51. Ranjbar A, Firozian F, Soleimani Asl S, Ghasemi H, Taheri Azandariani M, Larki A, Hosseini A and Naserabadi A: Nitrosative DNA damage after sub-chronic exposure to silver nanoparticle induces stress nephrotoxicity in rat kidney. Toxin Rev 37: 327-333, 2017.
52. Saleh H, Nassar AMK, Noreldin AE, Samak D, Elshony N, Wasef L, Elewa YHA, Hassan SMA, Saati AA, Hetta HF, *et al*: Chemo-protective potential of cerium oxide nanoparticles against fipronil-induced oxidative stress, apoptosis, inflammation and reproductive dysfunction in male white albino rats. Molecules 25: 3479, 2020.

53. Tuncay A, Sivgin V, Ozdemirkan A, Sezen SC, Boyunaga H, Kucuk A, Gunes I and Arslan M: The effect of cerium oxide on lung tissue in lower extremity ischemia reperfusion injury in sevoflurane administered rats. Int J Nanomedicine 15: 7481-7489, 2020.
54. Ni D, Wei H, Chen W, Bao Q, Rosenkrans ZT, Barnhart TE, Ferreira CA, Wang Y, Yao H, Sun T, *et al*: Ceria nanoparticles meet hepatic Ischemia-reperfusion injury: The perfect imperfection. Adv Mater 31: e1902956, 2019.
55. Artimani T, Amiri I, Soleimani Asl S, Saidijam M, Hasanvand D and Afshar S: Amelioration of diabetes-induced testicular and sperm damage in rats by cerium oxide nanoparticle treatment. Andrologia 50: e13089, 2018.
56. Charbgoo F, Ahmad MB and Darroudi M: Cerium oxide nanoparticles: Green synthesis and biological applications. Int J Nanomedicine 12: 1401-1413, 2017.
57. Adebayo OA, Akinloye O and Adaramoye OA: Cerium oxide nanoparticle elicits oxidative stress, endocrine imbalance and lowers sperm characteristics in testes of balb/c mice. Andrologia: 50, 2018 doi: 10.1111/and.12920.
58. Alpaslan E, Geilich BM, Yazici H and Webster TJ: pH-Controlled cerium oxide nanoparticle inhibition of both gram-positive and gram-negative bacteria growth. Sci Rep 7: 45859, 2017.
59. Kalyanaraman V, Naveen SV, Mohana N, Balaje RM, Navaneethakrishnan KR, Brabu B, Murugan SS and Kumaravel TS: Biocompatibility studies on cerium oxide nanoparticles-combined study for local effects, systemic toxicity and genotoxicity via implantation route. Toxicol Res (Camb) 8: 25-37, 2019.
60. Karakoti AS, Singh S, Kumar A, Malinska M, Kuchibhatla SV, Wozniak K, Self WT and Seal S: PEGylated nanoceria as radical scavenger with tunable redox chemistry. J Am Chem Soc 131: 14144-14145, 2009.
61. Yang X, Pan H, Wang, P and Zhao FJ: Particle-specific toxicity and bioavailability of cerium oxide (CeO_2) nanoparticles to Arabidopsis thaliana. J Hazard Mater 322: 292-300, 2017.
62. Ganji M, Osman H, Karimi J, Hosseini SA, Moridi H, Hosseini A, Ahmadimoghaddam D and Ranjbar A: Experimental study of cerium oxide nanoparticles (CeNP) against malathion induced lung oxidative toxic stress in rats. Iranian J Pharmacol Ther 15: 1-7, 2017.
63. Tatar T, Polat Y, Comu FM, Kartal H, Arslan M and Kucuk A: Effect of cerium oxide on erythrocyte deformability in rat lower extremity ischemia reperfusion injury. Bratisl Lek Listy 119: 441-443, 2018.
64. Hegazy MA, Maklad HM, Samy DM, Abdelmonsif DA, El Sabaa BM and Elnozahy FY: Cerium oxide nanoparticles could ameliorate behavioral and neurochemical impairments in 6-hydroxydopamine induced Parkinson's disease in rats. Neurochem Int 108: 361-371, 2017.
65. Manne NDPK, Arvapalli R, Graffeo VA, Bandarupalli VVK, Shokuhfar T, Patel S, Rice KM, Ginjupalli GK and Blough ER: Prophylactic treatment with cerium oxide nanoparticles attenuate hepatic ischemia reperfusion injury in sprague dawley rats. Cell Physiol Biochem 42: 1837-1846, 2017.
66. Ozbal S, Ergur BU, Erbil G, Tekmen I, Bagrıyanık A and Cavdar Z: The effects of α-lipoic acid against testicular ischemia-reperfusion injury in Rats. ScientificWorldJournal 2012: 489248, 2012.
67. Işlekel S, Işlekel H, Güner G and Ozdamar N: Alterations in superoxide dismutase, glutathione peroxidase and catalase activities in experimental cerebral ischemia-reperfusion. Res Exp Med (Berl) 199: 167-176, 1999.
68. Stanimirovic DB, Micic DV, Markovic M, Spatz M and Mrsulja BB: 'Therapeutic window' for multiple drug treatment of experimental cerebral ischemia in gerbils. Neurochem Res 19: 189-194, 1994.
69. Koltuksuz U, Ozen S, Uz E, Aydinç M, Karaman A, Gültek A, Akyol O, Gürsoy MH and Aydin E: Caffeic acid phenethyl ester prevents intestinal reperfusion injury in rats. J Pediatr Surg 34: 1458-1462, 1999.
70. Yildiz Y, Serter M, Ek RO, Ergin K, Cecen S, Demir EM and Yenisey C: Protective effects of caffeic acid phenethyl ester on intestinal ischemia-reperfusion injury. Dig Dis Sci 54: 738-744, 2009.
71. Erdemir F, Parlaktas BS, Ozyurt H, Boztepe O, Atis O and Sahin S: Antioxidant effect of melatonin in systemic circulation of rats after unilateral testicular torsion. Turk J Med Sci 38: 1-6, 2008.
72. Wei SM, Yan ZZ and Zhou J: Protective effect of rutin on testicular ischemia-reperfusion injury. J Pediatr Surg 46: 1419-1424, 2011.
73. Akgür FM, Kilinç K and Aktuğ T: Reperfusion injury after detorsion of unilateral testicular torsion. Urol Res 21: 395-399, 1993.
74. Gökçe A, Oktar S, Koc A, Gonenci R, Yalcinkaya F, Yonden Z and Duru M: Protective effect of thymoquinone in experimental testicular torsion. Urol Int 85: 461-465, 2010.
75. Blank ML, O'Neill PJ, Steigman CK, Cobb LM, Wilde RA, Havenstein PJ and Chaudry IH: Reperfusion injury following testicular torsion and detorsion in prepubertal rats. Urol Res 21: 389-393, 1993.
76. Prillaman HM and Turner TT: Rescue of testicular function after acute experimental torsion. J Urol 157: 340-345, 1997.
77. Ward TH, Cummings J, Dean E, Greystoke A, Hou JM, Backen A, Ranson M and Dive C: Biomarkers of apoptosis. Br J Cancer 99: 841-846, 2008.
78. Porter AG and Jänicke RU: Emerging roles of caspase-3 in apoptosis. Cell Death Differ 6: 99-104, 1999.
79. Ishizuya-Oka A, Hasebe T and Shi YB: Apoptosis in amphibian organs during metamorphosis. Apoptosis 15: 350-364, 2010.
80. Elmore S: Apoptosis: A review of programmed cell death. Toxicol Pathol 35: 495-516, 2007.
81. Goldar S, Khaniani MS, Derakhshan SM and Baradaran B: Molecular mechanisms of apoptosis and roles in cancer development and treatment. Asian Pac J Cancer Prev 16: 2129-2144, 2015.
82. Bejarano I, Rodríguez AB and Pariente JA: Apoptosis is a demanding selective tool during the development of fetal male germ cells. Front Cell Dev Biol 6: 65, 2018.
83. Jairajpuri ZS, Ghai R, Saluja S, Kapur S and Bhowmik KT: Expression of apoptosis related and proliferative proteins in malignant lympho-proliferative disorders. Iran J Pathol 12: 231-240, 2007.
84. Shi Y, Norberg E and Vakifahmetoglu-Norberg H: Mutant p53 as a regulator and target of autophagy. Front Oncol 10: 607149, 2021.
85. Scorrano L and Korsmeyer SJ: Mechanisms of cytochrome c release by proapoptotic BCL-2 family members. Biochem Biophys Res Commun 304: 437-444, 2003.
86. Chen X, Ko LJ, Jayaraman L and Prives C: p53 levels, functional domains, and DNA damage determine the extent of the apoptotic response of tumor cells. Genes Dev 10: 2438-2451, 1996.
87. Misao J, Hayakawa Y, Ohno M, Kato S, Fujiwara T and Fujiwara H: Expression of bcl-2 protein, an inhibitor of apoptosis, and Bax, an accelerator of apoptosis, in ventricular myocytes of human hearts with myocardial infarction. Circulation 94: 1506-1512, 1996.
88. Chipuk JE, Kuwana T, Bouchier-Hayes L, Droin NM, Newmeyer DD, Schuler M and Green DR: Direct activation of Bax by p53 mediates mitochondrial membrane permeabilization and apoptosis. Science 303: 1010-1014, 2004.
89. Kumi-Diaka J and Butler A: Caspase-3 protease activation during the process of genistein-induced apoptosis in TM_4 testicular cells. Biol Cell 92: 115-124, 2000.
90. Kolli MB, Manne NDPK, Para R, Nalabotu SK, Nandyala G, Shokuhfar T, He K, Hamlekhan A, Ma JY, Wehner PS, *et al*: Cerium oxide nanoparticles attenuate monocrotaline induced right ventricular hypertrophy following pulmonary arterial hypertension. Biomaterials 35: 9951-9962, 2014.
91. Mousavi A, Gharzi A, Gholami M, Beyranvand F and Takesh M: The therapeutic effect of cerium oxide nanoparticle on ischaemia/reperfusion injury in rat testis. Andrologia 53: e14231, 2021.