Identification of a novel ANK1 mutation in a Chinese family with hereditary spherocytosis: A case report

XIAONING ZHU[1*], MENGYUN PENG[1*], YUE YIN[1], YURONG ZHANG[1], DING ZHENG[1], ZHAOXUAN PENG[1], JUN CHENG[2], SONG YANG[2] and JING WANG[1]

[1]Department of Hepatobiliary Disease, The Affiliated Traditional Chinese Medicine Hospital of Southwest Medical University, Luzhou, Sichuan 646000; [2]Center of Liver Diseases, Beijing Ditan Hospital, Capital Medical University, Beijing 100020, P.R. China

Received August 4, 2022; Accepted October 25, 2022

DOI: 10.3892/etm.2022.11704

Abstract. The present study describes the clinical profile and ankyrin 1 (ANK1) mutation status of a Chinese family with hereditary spherocytosis (HS). A young male patient (proband) was diagnosed with HS after presenting with anaemia and jaundice. The Coombs test was negative and spherocytes were found in peripheral blood smears. Magnetic resonance imaging showed splenomegaly and splenic iron depositions. The red blood cell osmotic fragility test was positive. The eosin-5'-maleimide binding test showed reduced mean channel fluorescence. Whole-exome sequencing revealed a novel ANK1 mutation (c.4707G>A), resulting in a nonsense mutation (p.Trp1569*). The patient's father, paternal aunt and paternal grandmother exhibited comparable clinical symptoms and Sanger sequencing confirmed the same mutation in these family members. To the best of our knowledge, an HS pedigree with this novel ANK1 nonsense mutation has not been previously reported. At the same time, the unique clinical presentation of this pedigree helps our understanding of the heterogeneity of clinical manifestations of HS.

Correspondence to: Professor Jing Wang, Department of Hepatobiliary Disease, The Affiliated Traditional Chinese Medicine Hospital of Southwest Medical University, 182 Chunhui Road, Longmatan, Luzhou, Sichuan 646000, P.R. China
E-mail: lywj68@126.com

Professor Song Yang, Center of Liver Diseases, Beijing Ditan Hospital, Capital Medical University, 8 Jingshun East Street, Chaoyang, Beijing 100020, P.R. China
E-mail: sduyangsong@163.com

*Contributed equally

Key words: hereditary spherocytosis, ankyrin 1, whole-exome sequencing, anemia, splenomegaly

Introduction

Hereditary spherocytosis (HS), an inherited condition characterized by the presence of spherocytes in peripheral blood smears, is the most prevalent cause of haemolytic anaemia (1,2). Although HS is a global disease, its incidence has increased in Northern Europe to ~1 in 2,000 cases (3). In East Asia, research from Korea and Japan has revealed that HS is the most common congenital haemolytic anaemia (4,5). The predicted prevalence in China is 1.27 per 100,000 for men and 1.49 per 100,000 for women (6). Currently, known mutant genes include ankyrin 1 (ANK1), spectrin α erythrocytic 1 (SPTA1), spectrin β erythrocytic (SPTB), solute carrier family 4 member 1 (SLC4A1) and erythrocyte membrane protein band 4.2 (EPB42), which encode the erythrocyte membrane proteins ankyrin, spectrin, band 3 and band 4.2, respectively. Mutations in these genes lead to abnormalities or malfunctions of their respective proteins (1,7-9). Approximately 90% of the cases of HS are inherited as autosomal dominant due to mutations in ANK1, SPTB and SLC4A1. A further 10% of the cases of HS are inherited as autosomal recessive due to mutations in SPTA1 and EPB42 (10).

HS has a heterogeneous clinical manifestation, ranging from asymptomatic compensated haemolysis to transfusion dependence (1,11-13). The diagnostic foundation for this condition is a negative Coombs test, the presence of spherocytes and anaemia with a positive family history. Therapy is directed at preventing or minimizing the effects of chronic haemolysis and anaemia. Although there is no treatment for erythrocyte membrane abnormalities, available options include folic acid and erythropoietin supplements, as well as blood transfusions, splenectomy and cholecystectomy, depending on individual disease severity (7,14,15).

As a diagnostic tool, whole-exome sequencing based on next-generation sequencing technology has considerably contributed to the discovery of novel mutations that cause Mendelian diseases (16-18). A previous study reported a novel ANK1 c.4276C>T (p.R1426*) nonsense mutation identified by NGS in a patient with HS. However, Sanger sequencing confirmed that neither the parents or younger brother carried this mutation (19). Thus, to the best of our knowledge, reports of

Table I. Blood test results of the patient and the family members.

Characteristic	Reference range	Patient	Father	Aunt	Grandmother
Red blood cells, n ($x10^{12}$/l)	4.30-5.80	4.03	3.56	3.67	1.90
Hemoglobin, g/l	130-175	139	124	117	64
Mean corpuscular volume, fl	82-100	101.20	103.90	91.90	106.70
MHC, pg	27-34	34.40	34.70	31.90	33.60
MHC concentration, g/l	316-354	340	334	347	315
Reticulocytes, %	0.90-2.20	8.94	9.92	8.87	11.01
Osmotic fragility	(-)	↑	↑	NA	↑
Spherocytosis	(-)	(+)	(+)	NA	(+)
Eosin-5'-maleimide, %	100	87.91	85.94	87.59	96.30
Coombs test	(-)	(-)	(-)	NA	(-)
Iron, μmol/l	10.60-36.70	19	47.50	NA	33.60
Ferritin, ng/ml	25-280	322.43	>1,000	NA	891.42
Serum total bilirubin, μmol/l	0-23	96.10	69.90	26.80	29.40
Direct bilirubin, μmol/l	0-7	11.50	21	8.40	11.10
Indirect bilirubin, μmol/l	0-20	84.60	48.90	18.40	18.30
Unbound iron-binding capacity, μmol/l	34-48	29.80	6.70	NA	7.10
Total iron-binding capacity, μmol/l	50-77	48.80	54.20	NA	40.70

MCH, mean corpuscular haemoglobin; NA, not applicable; ↑, increased.

such mutations, particularly mutations within the ANK1 gene, and their clinical characteristics in families with HS, are rare. The present case report describes the identification of an HS pedigree with a novel ANK1 mutation using next-generation sequencing technology, thereby expanding the spectrum of ANK1 mutations. Moreover, the related literature is reviewed.

Case report

A 24-year-old male patient (proband) was hospitalized in July 2021 at the Affiliated Traditional Chinese Medicine Hospital of Southwest Medical University (Luzhou, China), with a 12-year history of unexplained anaemia and recurrent jaundice. A physical examination showed pale conjunctiva and an enlarged spleen. The patient had no history of any other diseases. Moreover, no history of smoking, drinking or drug use was reported, and the parents were not consanguineous. However, the patient's father, paternal aunt and paternal grandmother reported a similar medical history of anaemia and jaundice.

For investigating the cause of anaemia, tests for whole blood cell count, liver function, serum iron, serum ferritin, transferrin saturation, red blood cell osmotic fragility and eosin-5'-maleimide (EMA) binding, as well as the Coombs test, were performed on the patient, the patient's father and the paternal grandmother, while tests for whole blood cell count, liver function and EMA binding were performed on the paternal aunt (Table I). The patient, father and paternal aunt had compensated anaemia with an elevated reticulocyte ratio. The test results of the patient and family members showed a negative Coombs test, increased red blood cell osmotic fragility and decreased mean channel fluorescence levels in the EMA binding test.

The patient underwent a bone marrow aspiration and bone marrow smear. The patient and family members underwent a peripheral blood smear test. The bone marrow and peripheral blood smears were performed using Wright's staining. Buffered Wright stain was added for 5 min to fix and stain the specimen, and then the slides were left to stand for 5 min after adding an equal amount of ultrapure water, all at room temperature. The slides were then washed, blotted and assessed via light microscopy. The results of the bone marrow smear and peripheral blood smear were analysed by experienced physicians in the Department of Pathology of The Affiliated Traditional Chinese Medicine Hospital of Southwest Medical University. Spherocytes were found in the peripheral blood smears (Fig. 1). All other causes of anaemia were excluded via bone marrow aspiration.

Abdominal magnetic resonance imaging (MRI) of the patient (Fig. 2) and father revealed splenomegaly and iron deposition in the spleen. A blood sample from the patient was sent to Guangzhou KingMed Diagnostics Group Co., Ltd., for whole-exome sequencing to identify possible mutations. Genomic DNA collection and whole-exome sequencing were performed according to the manufacturer's instructions as previously described (20). A novel mutation in ANK1, c.4707G>A (p.Trp1569*), was identified in the patient. The genetic pedigree map and sequencing results for the analysed family members are shown in Fig. 3. The heterozygous mutation was verified by Sanger sequencing at Guangzhou KingMed Diagnostics Group Co., Ltd. (Fig. 3), which showed an overlap of signals for G/A and C/T at position 4707 of the ANK1 gene in the chromatograms of the forward and reverse sequencing results, respectively. Furthermore, Sanger sequencing also confirmed that the mutation was present in the patient's father, aunt and grandmother (data not shown). The

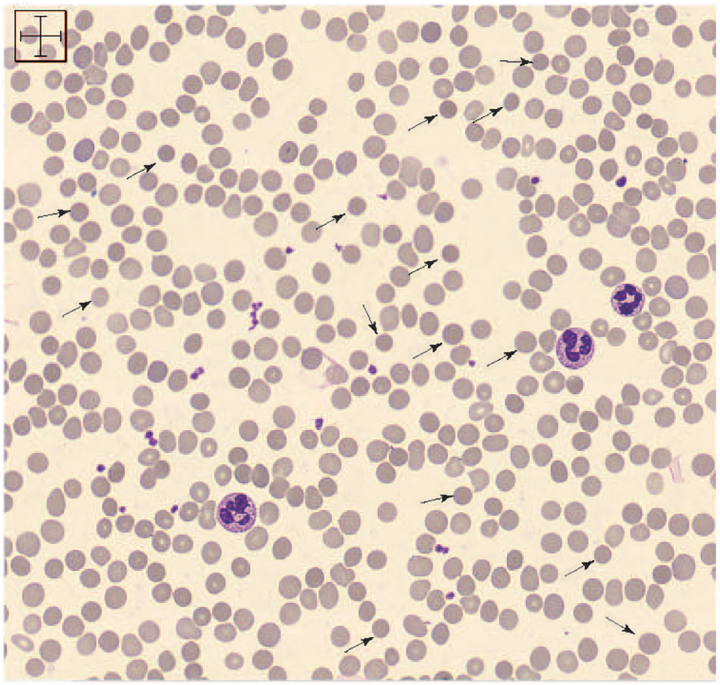

Figure 1. Morphological analysis of erythrocytes. Spherocytes (arrows) are visible in the patient's peripheral blood smear (Wright's stain; x1,000 magnification).

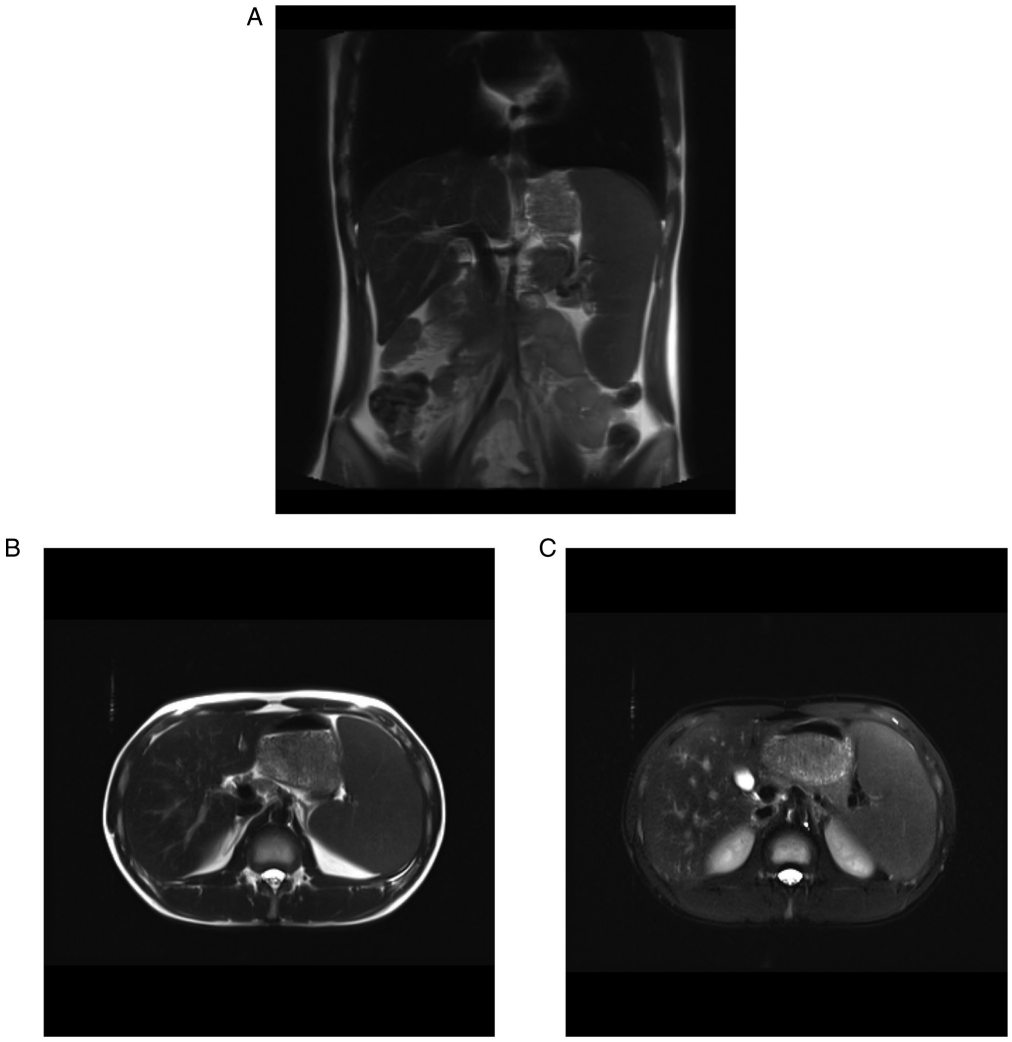

Figure 2. MRI scans of the proband patient. (A) MRI scan of the patient revealing an enlarged spleen. (B) T2 MRI scan and (C) selective partial inversion recovery sequences revealing reduced signal intensity in the spleen, suggesting iron deposition. MRI, magnetic resonance imaging.

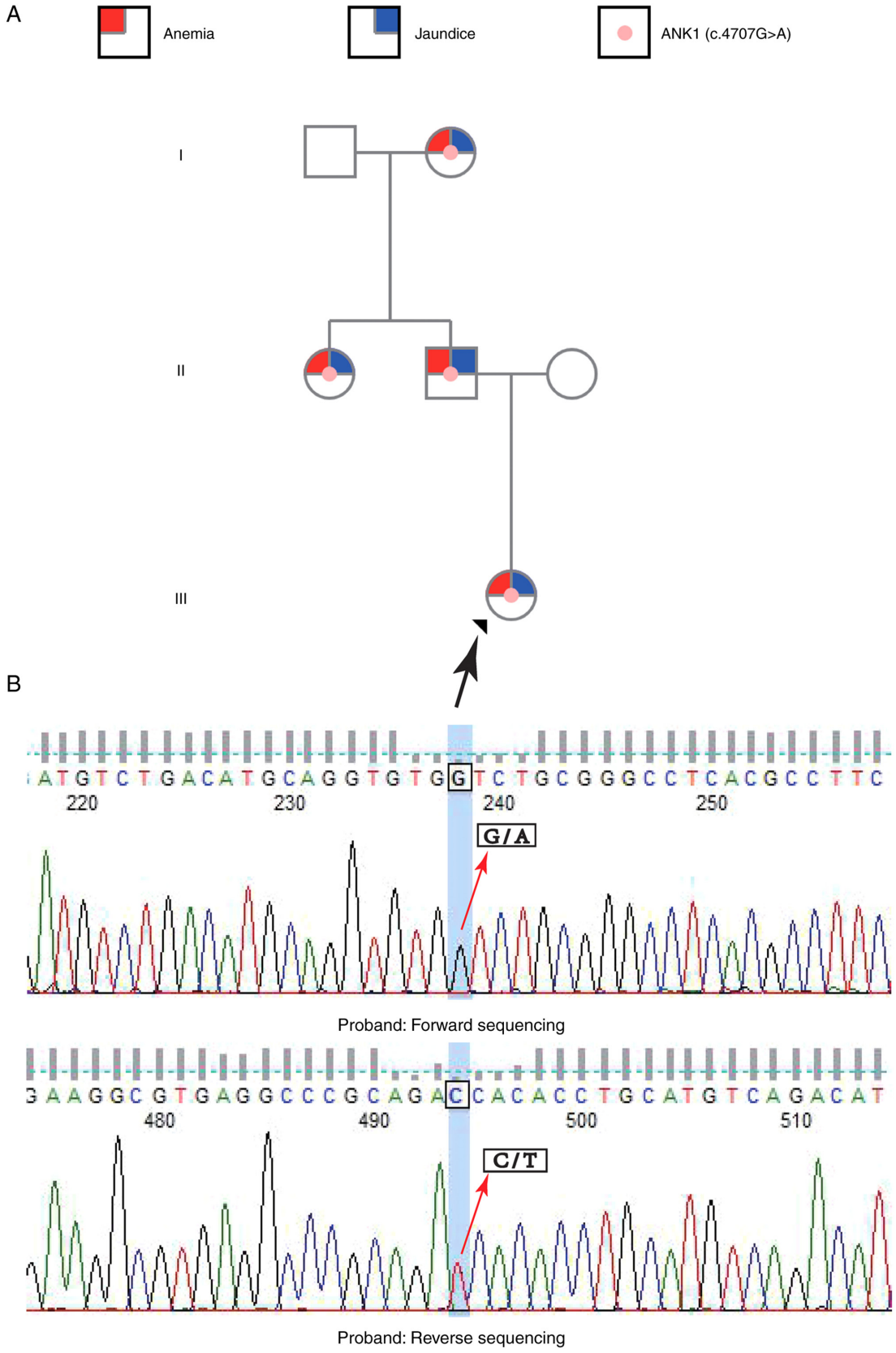

Figure 3. Genetic pedigree map. (A) A dominant inheritance mode is noted in all three family generations (I, II and III) with similar clinical signs. (B) ANK1 gene sequencing results showing the c.4707G>A mutation (G at position 4707 of the ANK1 gene is replaced by A). ANK1, ankyrin 1.

c.4707G>A (p.Trp1569*) mutation produced a truncated ANK1 protein, thereby impairing ANK1 function. This variation was not found in four major databases [Human Gene Mutation Database (https://digitalinsights.qiagen.com/products-overview/clinical-insights-portfolio/human-gene-mutation-database/), ESP6500siv2(https://esp.gs.washington.edu/drupal/), 1000

Genomes (https://www.internationalgenome.org/) and dbSNP147 (https://www.ncbi.nlm.nih.gov/snp/)] and was not identified in the patient's mother or grandfather upon Sanger sequencing (data not shown).

All affected family members are currently undergoing regular follow-ups every 3-6 months. Folic acid supplementation and blood transfusion are administered when necessary. Neither the patient nor the affected family members have received a splenectomy.

Discussion

The present study describes an HS pedigree with four family members involved. According to related guidelines (21,22), whole-exome sequencing was performed in the patient and a novel ANK1 mutation, c.4707G>A (p.Trp1569*), was identified. In recent years, an increasing number of novel mutations related to HS have been identified with second-generation sequencing (23). Moreover, second-generation sequencing has become an affordable and accessible test for diagnosing HS, as genetic sequencing costs have decreased significantly.

The genotypes and protein phenotypes of HS vary widely, with ANK1 mutations accounting for 35-65% of cases in Northern Europe, which is similar to the prevalence of ANK1 mutations in the Korean population (ANK1 mutations result in 66.66% of cases) (24,25). By contrast, most cases of HS in the Japanese population are due to mutations in EPB42 (45%), whereas in China, ANK1 and SPTB have been reported as the most commonly mutated genes, each being present in 45% of patients (5,26). Thus, deficiencies in ankyrin alone or ankyrin and spectrin combined, caused by mutations in ANK1 or ANK1 and SPTB, respectively, are the major causes of HS in China. The present report identified a novel HS-related mutation in ANK1.

Ankyrin is the main protein responsible for coupling the erythrocyte plasma membrane and the underlying cytoskeleton; it interacts with spectrin to maintain the biconcave disc shape of these cells, allowing them to undergo reversible deformation while traversing the microvasculature without changing the surface area (27). ANK1 mutations are responsible for the change from the biconcave disc shape to the spherical shape. This limits erythrocyte deformability and triggers mechanical rupture haemolysis in capillary network-rich organs such as the liver and spleen. The ANK1 gene is localized to 8P11.21 and contains 49 exons that encode three major structural domains, including the N-terminal binding, central spectral binding and C-terminal regulatory domains, of which the C-terminal regulatory domain is the most mutable (28). Recent studies have found that ANK1 mutations in Chinese patients with HS are mainly observed in the N-terminal membrane protein-binding domain, the two ZU5 domains, the UPA domain and the death domain, with clinical manifestations of different types of ANK1 mutations appearing in other structural domains being random (29,30). The mutation in ANK1 identified in the current study was a rare nonsense mutation located in the gene sequence encoding the C-terminal regulatory domain, resulting in autosomal dominant inheritance, which led to the development of clinical symptoms in three generations of the family.

Studies have shown that clinical manifestations of HS might be related to the ANK1 mutation site. Mutations in the central spectral binding domain of ANK1 reportedly elicit more severe anaemia and higher rates of erythrocyte deformation. Variants affecting the death domain are associated with a low mean corpuscular volume (MCV) and a low mean corpuscular haemoglobin (MCH) level (25,29). However, even the same ANK1 mutations may result in heterogeneous disease severity in different pedigrees (7,10). As a novel truncated mutation discovered at the end of the C-terminal regulatory domain, to the best of our knowledge, there is almost no information about its related clinical manifestations. As for truncated mutations at the end of the C-terminal regulatory domain, Wang *et al* (19) reported an ANK1 c.4276C>T (p.R1426*) nonsense mutation at the C-terminal regulatory domain in a patient with HS. However, Sanger sequencing confirmed that none of the other family members carried this mutation. To date, the present study is the first pedigree report of an ANK1 truncated mutation at the end of the C-terminal regulatory domain with multiple patients involved. Most individuals in the present patient's family had compensated anaemia, indicating mild HS and potentially explaining their normal MCV, MCH, and MCH concentration (MCHC) levels, which are typically reduced in patients with HS. Additionally, several studies have shown normal or increased MCHC level in patients with HS (29,31,32).

Multiple episodes of haemolysis may cause excessive iron deposition in the spleen of adult patients with HS. Therefore, these events must be differentiated from other iron overload diseases, such as hereditary hemochromatosis (33). In the present case, abdominal MRI showed spleen iron deposition in the patient and the father, which is seldom reported in patients with HS. As bone marrow aspiration and whole exosome sequencing excluded other iron overload causes, it was considered that the iron deposition in the spleen of the patient and the father was caused by chronic haemolytic anaemia.

Osmotic gradient ektacytometry is a robust measurement for diagnosing HS (34). However, it is not widely available for the clinical diagnosis of HS in mainland China. Therefore, the combination of EMA testing and second-generation sequencing is recommended in the Chinese and South Korean guidelines for HS diagnosis (21,22). In the present case, EMA testing and second-generation sequencing helped to diagnose HS.

In conclusion, the present study reported an HS pedigree with a novel ANK1 mutation and unique clinical manifestation. Affordable and accessible second-generation sequencing helped to diagnose HS and discover a novel HS-related mutation. Individuals in this pedigree showed a mild clinical manifestation, which might be related to the novel truncated mutation at the end of the C-terminal regulatory domain of ANK1. This novel mutation pedigree expands the mutation spectrum of ANK1-related HS. Further studies are warranted to show the pathogenesis of this novel c.4707G>A (p.Trp1569*) mutation for HS.

Acknowledgements

Not applicable.

Funding

The whole-exome and Sanger sequencing analysis were supported by funding from the National Traditional Chinese Medicine Clinical Research Base Construction Unit of The Affiliated Traditional Chinese Medicine Hospital of Southwest Medical University [grant no. (2020) 33], the Luzhou 'Jiucheng Talents-Scientific and Technological Innovation Team' [grant no. (2021) 162] and the Scientific Research Team Cultivation Project of the Affiliated Traditional Chinese Medicine Hospital of Southwest Medical University [grant no. (2022) 68, 2022-CXTD-04].

Availability of data and materials

The datasets generated and/or analysed during the current study are available in the NCBI Sequence Read Archive repository (https://dataview.ncbi.nlm.nih.gov/object/PRJNA884085?reviewer=5isvljlpqtfr33fnpmdl3bjcq0) under the accession no. SRR21700253.

Authors' contributions

JW, SY, JC and XZ designed the study. XZ and MP collected the data. XZ drafted the manuscript. YY, YZ and DZ analyzed and interpreted the genetic data. MP and ZP followed up with the patient and analyzed the clinical data. JW, SY and JC revised the manuscript. JW and XZ confirm the authenticity of all the raw data. All authors read and approved the final manuscript.

Ethics approval and consent to participate

The present study was approved by the Ethics Committee of The Affiliated Traditional Chinese Medicine Hospital of Southwest Medical University (approval no. KY2022010). The study was conducted in accordance with the Declaration of Helsinki. Written informed consent was obtained from all individuals involved in the study.

Patient consent for publication

Written informed consent was obtained for the publication of clinical data and genetic analysis data, including the addition of genetic information to the NCBI repository.

Competing interests

The authors declare that they have no competing interests.

References

1. Perrotta S, Gallagher PG and Mohandas N: Hereditary spherocytosis. Lancet 372: 1411-1426, 2008.
2. Zamora EA and Schaefer CA: Hereditary spherocytosis. In: StatPearls [Internet]. StatPearls Publishing, Treasure Island, FL, 2022.
3. King MJ, Garçon L, Hoyer JD, Iolascon A, Picard V, Stewart G, Bianchi P, Lee SH and Zanella A; International Council for Standardization in Haematology: ICSH guidelines for the laboratory diagnosis of nonimmune hereditary red cell membrane disorders. Int J Lab Hematol 37: 304-325, 2015.
4. Shim YJ, Jung HL, Shin HY, Kang HJ, Choi JY, Hah JO, Lee JM, Lim YT, Yang EJ, Baek HJ, *et al*: Epidemiological study of hereditary hemolytic anemia in the Korean pediatric population during 1997-2016: A nationwide retrospective cohort study. J Korean Med Sci 35: e279, 2020.
5. Yawata Y, Kanzaki A, Yawata A, Doerfler W, Ozcan R and Eber SW: Characteristic features of the genotype and phenotype of hereditary spherocytosis in the Japanese population. Int J Hematol 71: 118-135, 2000.
6. Wang C, Cui Y, Li Y, Liu X and Han J: A systematic review of hereditary spherocytosis reported in Chinese biomedical journals from 1978 to 2013 and estimation of the prevalence of the disease using a disease model. Intractable Rare Dis Res 4: 76-81, 2015.
7. Bolton-Maggs PH, Langer JC, Iolascon A, Tittensor P and King MJ; General Haematology Task Force of the British Committee for Standards in Haematology: Guidelines for the diagnosis and management of hereditary spherocytosis-2011 update. Br J Haematol 156: 37-49, 2012.
8. Delaunay J: The molecular basis of hereditary red cell membrane disorders. Blood Rev 21: 1-20, 2007.
9. Narla J and Mohandas N: Red cell membrane disorders. Int J Lab Hematol 39 (Suppl 1): S47-S52, 2017.
10. Tole S, Dhir P, Pugi J, Drury LJ, Butchart S, Fantauzzi M, Langer JC, Baker JM, Blanchette VS, Kirby-Allen M and Carcao MD: Genotype-phenotype correlation in children with hereditary spherocytosis. Br J Haematol 191: 486-496, 2020.
11. Eber SW, Armbrust R and Schröter W: Variable clinical severity of hereditary spherocytosis: Relation to erythrocytic spectrin concentration, osmotic fragility, and autohemolysis. J Pediatr 117: 409-416, 1990.
12. Friedman EW, Williams JC and Van Hook L: Hereditary spherocytosis in the elderly. Am J Med 84 (3 Pt 1): 513-516, 1988.
13. Whitfield CF, Follweiler JB, Lopresti-Morrow L and Miller BA: Deficiency of alpha-spectrin synthesis in burst-forming units-erythroid in lethal hereditary spherocytosis. Blood 78: 3043-3051, 1991.
14. Abdullah F, Zhang Y, Camp M, Rossberg MI, Bathurst MA, Colombani PM, Casella JF, Nabaweesi R and Chang DC: Splenectomy in hereditary spherocytosis: Review of 1,657 patients and application of the pediatric quality indicators. Pediatr Blood Cancer 52: 834-837, 2009.
15. Alizai NK, Richards EM and Stringer MD: Is cholecystectomy really an indication for concomitant splenectomy in mild hereditary spherocytosis? Arch Dis Child 95: 596-599, 2010.
16. Biesecker LG and Green RC: Diagnostic clinical genome and exome sequencing. N Engl J Med 370: 2418-2425, 2014.
17. Rabbani B, Mahdieh N, Hosomichi K, Nakaoka H and Inoue I: Next-generation sequencing: Impact of exome sequencing in characterizing Mendelian disorders. J Hum Genet 57: 621-632, 2012.
18. Yang Y, Muzny DM, Xia F, Niu Z, Person R, Ding Y, Ward P, Braxton A, Wang M, Buhay C, *et al*: Molecular findings among patients referred for clinical whole-exome sequencing. JAMA 312: 1870-1879, 2014.
19. Wang X, Yi B, Mu K, Shen N, Zhu Y, Hu Q and Lu Y: Identification of a novel de novo ANK1 R1426* nonsense mutation in a Chinese family with hereditary spherocytosis by NGS. Oncotarget 8: 96791-96797, 2017.
20. Wei Y, He Y and Guo X: Clinical phenotype and genetic analysis of twins with congenital coagulation factor V deficiency. J Pediatr Hematol Oncol 44: e482-e486, 2022.
21. Kim Y, Park J and Kim M: Diagnostic approaches for inherited hemolytic anemia in the genetic era. Blood Res 52: 84-94, 2017.
22. Xue J, He Q, Xie XJ, Su AL and Cao SB: A clinical and experimental study of adult hereditary spherocytosis in the Chinese population. Kaohsiung J Med Sci 36: 552-560, 2020.
23. Wang R, Yang S, Xu M, Huang J, Liu H, Gu W and Zhang X: Exome sequencing confirms molecular diagnoses in 38 Chinese families with hereditary spherocytosis. Sci China Life Sci 61: 947-953, 2018.
24. Eber SW, Gonzalez JM, Lux ML, Scarpa AL, Tse WT, Dornwell M, Herbers J, Kugler W, Ozcan R, Pekrun A, *et al*: Ankyrin-1 mutations are a major cause of dominant and recessive hereditary spherocytosis. Nat Genet 13: 214-218, 1996.
25. Park J, Jeong DC, Yoo J, Jang W, Chae H, Kim J, Kwon A, Choi H, Lee JW, Chung NG, *et al*: Mutational characteristics of ANK1 and SPTB genes in hereditary spherocytosis. Clin Genet 90: 69-78, 2016.

26. Qin L, Nie Y, Zhang H, Chen L, Zhang D, Lin Y and Ru K: Identification of new mutations in patients with hereditary spherocytosis by next-generation sequencing. J Hum Genet 65: 427-434, 2020.
27. Salomao M, Zhang X, Yang Y, Lee S, Hartwig JH, Chasis JA, Mohandas N and An X: Protein 4.1R-dependent multiprotein complex: New insights into the structural organization of the red blood cell membrane. Proc Natl Acad Sci USA 105: 8026-8031, 2008.
28. Lux SE, John KM and Bennett V: Analysis of cDNA for human erythrocyte ankyrin indicates a repeated structure with homology to tissue-differentiation and cell-cycle control proteins. Nature 344: 36-42, 1990.
29. Wang X, Zhang A, Huang M, Chen L, Hu Q, Lu Y and Cheng L: Genetic and clinical characteristics of patients with hereditary spherocytosis in Hubei Province of China. Front Genet 11: 953, 2020.
30. Wang D, Song L, Shen L, Zhang K, Lv Y, Gao M, Ma J, Wan Y, Gai Z and Liu Y: Mutational characteristics of causative genes in Chinese hereditary spherocytosis patients: A report on fourteen cases and a review of the literature. Front Pharmacol 12: 644352, 2021.
31. Aggarwal A, Jamwal M, Sharma P, Sachdeva MUS, Bansal D, Malhotra P and Das R: Deciphering molecular heterogeneity of Indian families with hereditary spherocytosis using targeted next-generation sequencing: First South Asian study. Br J Haematol 188: 784-795, 2020.
32. Michaels LA, Cohen AR, Zhao H, Raphael RI and Manno CS: Screening for hereditary spherocytosis by use of automated erythrocyte indexes. J Pediatr 130: 957-960, 1997.
33. Kowdley KV, Brown KE, Ahn J and Sundaram V: ACG clinical guideline: Hereditary hemochromatosis. Am J Gastroenterol 114: 1202-1218, 2019.
34. Llaudet-Planas E, Vives-Corrons JL, Rizzuto V, Gómez-Ramírez P, Sevilla Navarro J, Coll Sibina MT, García-Bernal M, Ruiz Llobet A, Badell I, Velasco-Puyó P, *et al*: Osmotic gradient ektacytometry: A valuable screening test for hereditary spherocytosis and other red blood cell membrane disorders. Int J Lab Hematol 40: 94-102, 2018.