Animal models for the study of intracranial hematomas (Review)

WELLINGSON SILVA PAIVA[1,2], EMANUELE ZIPPO[1], CAROLINA MIRANDA[3], SÉRGIO BRASIL[1,2], DANIEL AUGUSTIN GODOY[4], ALMIR FERREIRA DE ANDRADE[1,2], IURI NEVILLE[1], GUSTAVO CARTAXO PATRIOTA[5], RENAN DOMINGUES[3] and MANOEL JACOBSEN TEIXEIRA[1,2]

[1]Department of Neurology, Division of Neurosurgery, School of Medicine, University of São Paulo, 05403000 São Paulo; [2]Medical Research Laboratory 62, Department of Neurology, School of Medicine, University of São Paulo, 05403000 São Paulo; [3]Neurology Center, Samaritan Hospital, 01232010 São Paulo, Brazil; [4]Department of Intensive Care, Neurointensive Care Unit, Pasteur Hospital, 4700 Catamarca, Argentina; [5]Department of Neurosurgery, Humberto Lucena Hospital, 58031090 João Pessoa, Brazil

Received July 22, 2022; Accepted September 26, 2022

DOI: 10.3892/etm.2022.11719

Abstract. Intracranial hematomas (ICH) are a frequent condition in neurosurgical and neurological practices, with several mechanisms of primary and secondary injury. Experimental research has been fundamental for the understanding of the pathophysiology implicated with ICH and the development of therapeutic interventions. To date, a variety of different animal approaches have been described that consider, for example, the ICH evolutive phase, molecular implications and hemodynamic changes. Therefore, choosing a test protocol should consider the scope of each particular study. The present review summarized investigational protocols in experimental research on the subject of ICH. With this subject, injection of autologous blood or bacterial collagenase, inflation of intracranial balloon and avulsion of cerebral vessels were the models identified. Rodents (mice) and swine were the most frequent species used. These different models allowed improvements on the understanding of intracranial hypertension establishment, neuroinflammation, immunology, brain hemodynamics and served to the development of therapeutic strategies.

Contents

Correspondence to: Dr Sérgio Brasil, Department of Neurology, Division of Neurosurgery, School of Medicine, University of São Paulo, 255 Enéas Aguiar Street, 05403 São Paulo, Brazil
E-mail: sbrasil@usp.br

Key words: experimental animal models, intracranial hematoma, intracranial pressure, intracranial hypertension, cerebral hemodynamics

1. Introduction

In neurosurgical setting, intracranial hematomas (ICH) are a frequent condition with acute intracranial expansive effect (1), that lead to secondary injuries and complications, such as intracranial hypertension (IHT) (2,3), which may become the cause of death for these patients (4). In the last decades, spontaneous ICH prevalence has remained stable, with an average of 24.6 cases per 100,000 inhabitants per year in developed countries (5). Systemic arterial hypertension is the most important risk factor for non-traumatic bleeding, especially among subjects no adherent to antihypertensive treatment (4). Other causes for intracranial hemorrhages are aneurism rupture, arteriovenous malformation, vasculitis, coagulopathies, venous thrombosis, cocaine use, amyloid angiopathy and hemorrhagic complications after ischemic stroke thrombolysis (4).

ICH may present with a wide variety of signs and symptoms depending on the location and severity of the bleeding. Patients can be asymptomatic or have mild local deficits, whereas others present with IHT syndromes and complete loss of consciousness (4). Spontaneous ICH has an overall mortality rate of 50% after 30 days (6,7), and approximately half of deaths occur within the first 24 h of the initial bleeding (8). The functional prognosis for survivors is poor, and only 20% of patients are expected to be functionally independent at 6 months (9).

ICH may promote cerebral hemodynamic impairment with a shift from aerobic to anaerobic metabolism that leads to: i) Lactate and free radicals accumulation (10); ii) activation of inflammatory cascades (interleukin 1β and tumor necrosis factor) promoted by the complement, microglia, macrophages and neutrophils (11); iii) immune responses (and systemic

immunosuppression) that contribute to blood-brain barrier impairment; and iv) additional swelling of the brain tissue, leading to IHT, which adds even more damage to the brain tissue (11,12).

When therapeutic strategies such as hypertonic saline or mannitol infusions, hyperventilation and mild hypothermia fail to control IHT, the spreading ischemia may contribute to brain death unless an emergency neurosurgical procedure as decompressive craniectomy is performed (13). Therefore, animal experimentation and testing remains an important tool to improve understanding of the different pathophysiological mechanisms of injury in order to investigate the techniques of intervention and neuroprotection improvement. Currently, to the best of our knowledge, the available literature has few models of experimental ICH in animals, which are characterized by heterogeneity and varied methodology. The aim of the present review was to discuss the main animal models for ICH investigation, emphasizing the advantages and disadvantages of each method.

2. Methods

The present comprehensive review included experimental original studies published in English. Reviews were assessed to build the body of evidence. The present study's aim was to identify relevant studies on animal models of ICH. The search was effectuated in October 2021 and updated in May 2022 through the electronic databases PubMed/MEDLINE (https://pubmed.ncbi.nlm.nih.gov/), Google Scholar (https://scholar.google.com.br/), LILACS (https://lilacs.bvsalud.org/en/) and EMBASE (https://www.embase.com/landing?status=grey), by two investigators (WSP and SB). The following terms were applied to identify potential eligible articles: 'Animal model' OR 'experimental model' AND 'intracranial hematoma' OR 'cerebral hematoma' AND 'intracranial hypertension', and were then selected by title and abstract. In addition, a manual search was done using the reference lists of included studies to identify others relevant papers, as the 'Related Articles' tool for the selection of additional relevant articles. Inclusion criteria included experimental studies of any animal species with the purpose of assessing the effects of hematomas and/or intracranial hypertension over the brain. Exclusion criteria comprised of experimental interventional studies for the assessment of systemic effects of ICH and studies not published in English. The funneling process for selection of studies is presented in Fig. 1.

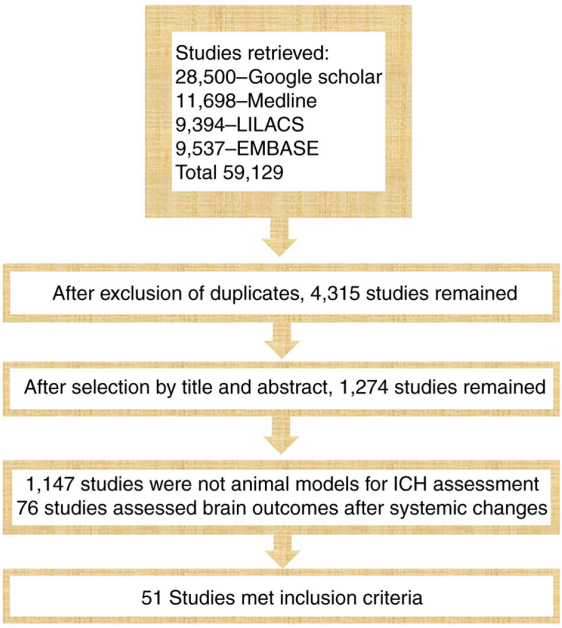

Figure 1. Manuscript search and selection funneling.

3. Models

Regarding the animals used for modeling ICH, the following different species were used: Mice or rats (14-33), pigs (34-40), dogs (41-43), monkeys (44), sheep (45), cats (46) and rabbits (47,48). The majority of studies (63%) utilized rats, whereas the model most used is autologous blood intracranial injection (51%). The assessment of neuroinflammation cascades was the outcome studied in 26% of the studies. Fig. 2 summarizes the representation of each animal type, model and outcomes assessed in reproducing intracranial hematomas.

Although each model recreates the fundamentals of human hematoma with good precision, they differ in ways that influence outcome. The present study described the technique details of ICH induction and compared the technical and pathological advantages and disadvantages of the existing models (Table I). Each model is presented in further detail bellow.

Intracerebral injection of autologous blood. Blood injection models allow the observation of hemolysis-induced toxicity assessment, as the following immune-inflammatory responses (49). This model also allows the assessment of interventions to reduce swelling, hematoma expansion and the IHT effects on brain hemodynamics (49). Experimental models of brain hematomas have been described since the 1960's, and typically involve the intracerebral injection of autologous blood, which is a simple and effective technique for the production of brain parenchymal hematoma (50). This type of model has been developed for larger animals (cats, dogs, pigs, sheep and monkeys) (36,37,41-43,45,49,51,52) through the injection of blood in the frontal lobe or basal ganglia. There are several variations within studies, such as blood source, the amount of blood injected and depth of injection. Whisnant *et al* (43) induced an intracerebral collection in dogs by infusing venous blood in the deep white matter. Sussman *et al* (41), by contrast, injected arterial blood superficially into the right frontal lobe (0.5 cm beneath the cortex) in dogs. A similar technique was presented by Wagner *et al* in 1996, 1998 and 1999 (49,50), who produced lobar hematomas in pigs by infusions of arterial blood into right frontal white matter.

For smaller animals (rats and mice) blood is injected into the caudate nucleus in the majority of studies (53-60). Yang *et al* (53) injected autologous blood into the caudate nuclei of rats in order to study the formation and resolution of brain edema. As an alternative for basal ganglia, Bullock *et al* (61) injected autologous blood into the lateral ventricles to compare the consequences of contained and uncontained hemorrhage. They also evaluated the impact of the intracerebral collection on the IHT.

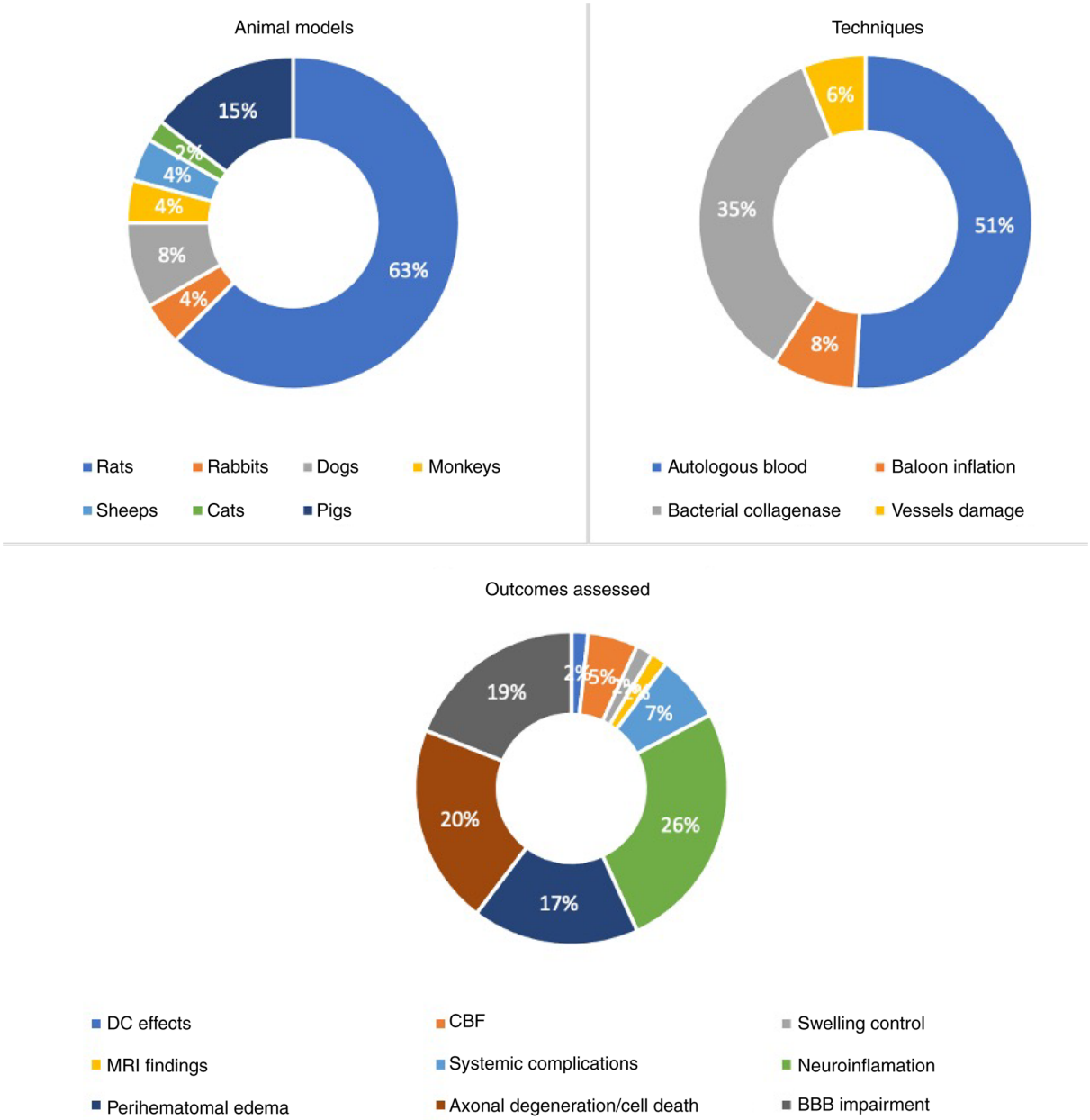

Figure 2. Models, animals and outcomes assessed after an intracranial hematoma simulation.

The autologous injection of blood method has a major advantage, which is allowing the production of hematomas with homogeneous volumes. It also mimics the rapid accumulation of blood noted to occur in the clinical setting (62). However, it does not reproduce the rupture of blood vessel present in human brain hematomas and can lead to intraventricular hemorrhage and/or subarachnoid hemorrhage by ruptures in the ventricular and subdural spaces (50). Moreover, there is a risk for the infused blood to back flow along the needle track (62). Nevertheless, it can be used for the study of biochemical and pathophysiological effects in patients with acute ICH and IHT as it permits the infused blood volume to be controlled, enabling the generation of hematomas sizes and mass effects (45).

Autologous blood injection allows the observation of hematoma capsule formation at the boundary tissue around the blood clot (53). It is composed by a necrotic layer of brain tissue, fibrin deposits, secondary capillary hemorrhages and white matter vacuolation in the first week (42), up to 1 cm from the ICH site. Impregnation of metalloproteinases and oxidative stress induced by ischemia contribute to these hemorrhagic phenomena and disruption of the blood-brain barrier (BBB) (63). Microglia and astrocytes seem to be more resistant to ICH effects, otherwise, neurons and axons are more sensitive to hypoxic-ischemic changes (45). At 3 days after ICH, red blood cell (RBC) morphology is significantly changed to spheric, with complement system activation responsible for RBC lysis following phagocytosis by macrophages and microglia (37).

The blood injection model was developed as a single intracerebral injection (64), but often produces inconsistent results due to the backflow of blood through the needle in rats (53). To minimize this complication, a dual-injection method has been developed, in which a small amount of blood is injected

Table I. Comparison of intracranial hematomas modeling techniques.

Model	Advantages	Disadvantages
Autologous blood injection	Reproducible	Does not mimic rupture of blood vessels
	Homogeneous volumes	Does not allow to evaluate rebleeding
	Clinically relevant comparison	
Bacterial collagenase	Represent hematoma expansion	Overestimate inflammatory reaction
	Produces vasogenic edema	Neurotoxic effects
Cerebral blood vessels damage	Reproduces blood toxicity	Promotes ischemia
Intracranial balloon inflation	Reliable mass effect	Does not reproduce blood toxicity

immediately above the target area of the brain, followed by a second injection of blood into the basal ganglia (64). The clot of the first injection prevents backflow along the needle (64). This model was first applied by Deinsberger in 1996 (65), and since then has been used in numerous studies with small animals (66-69). The double injection model mimics a hematoma developing rapidly but does not induce real rupture of cerebral blood vessels (62). A major advantage of this method is that it helps to prevent the backflow of blood into the subarachnoid space (62). However, it is not a spontaneous hemorrhage and does not mimic vessel rupture and, therefore, it does not allow researchers to evaluate rebleeding.

Bacterial collagenase model. Bacterial collagenase is a protease that damages the extracellular matrix around the brain capillaries, weakening them and causing rupture of the vessel and consequent extravasation of blood (64). This model produces spontaneous intracerebral bleeding, which develops over several hours, as shown in ~30% of patients with ICH (65). It is considered appropriate for studying hematoma expansion and vasogenic edema, anticoagulation, axonal degeneration, iron-induced apoptosis, endothelial disturbances and BBB impairment, in addition to systemic complications following brain aggression (62,64,70).

The injection of bacterial collagenase in the basal ganglia, leading to the breakdown of the basement membrane of blood vessels was first introduced in the early 1990s using mice (71,72) and has been widely used ever since (21,73-77). Collagenases spread and penetrate into the brain parenchyma instead of remaining on the site of infusion; therefore, although the pathophysiologic mechanisms of injury are the same of those disclosed in the section of autologous blood infusion, they seem to be enhanced in this model (76).

Adjustments to procedural parameters have been seen between multiple studies. The majority of authors inject bacterial collagenase type IV (78), but some have adopted bacterial type VI (71), VII S (17,79-81) or XI (38) collagenase. The infusion period also varies, ranging from 2 to 16 min (71,78,80). This technique is preferably used in small animals (rats and mice). Mun-Bryce *et al* (38) was one of the few to try this model in larger animals by injecting collagenase into the primary somatosensory cortex of swine. It is considered a simple and reproducible method since it evokes a dose-dependent hemorrhage size and can be used in multiple species. As it can mimic hematoma expansion and vasogenic edema (51,70,82), it is commonly used to investigate the mechanisms of increased bruising and for developing treatments that affect cerebral homeostasis (23,83,84).

Using this model, it is possible to imitate vessel rupture and represent hematoma expansion. It allows to assess long term outcomes. Even though it evokes an inflammatory response earlier and for a prolonged period (when compared with the blood injection model), it seems that the inflammatory reaction is too severe and is different from the observed in the human brain (85,86). Furthermore, extensive bleeding resulting from the intracerebral injection of collagenase may produce an unplanned ischemic brain injury (87). As expected from the above, this technique leads to significantly increased severe neurological deficits with poorer recovery compared with blood infusion (88).

Cerebral blood vessels damage model. In this model, rats have their cortical veins exposed via a craniotomy and damaged using a curved needle, resulting in cortical hemorrhages (89,90). This model has been very little used in the recent research as it has a large variability of brain injury created due to ischemic infarction, which limits the reliability of the experimental results (85). Xue and Del Bigio (90) compared the three models and observed that the relative magnitude of the inflammatory phenomena, molecular and cellular changes may differ between the models, although within similar patterns. These authors described damaged DNA neurons and CD8α immunoreactive lymphocytes to be maximal at 3 days after injury, but because the microglial/macrophage reaction peaked early between 3 to 7 days and persisted for weeks, dying neurons were seen in small quantities after 21 to 28 days. Neutrophils were substantially lower in this cortical vessel avulsion model compared with the blood and collagenases infusion models (90)

Alternative to this procedure is rupturing the vessels using a laser in order to produce microbleeds and assess coagulation outcomes (91). Zhou *et al* (86) induced an intracerebral hematoma by puncturing the middle cerebral artery. This procedure has been performed in 12 dogs under the ultrasound guidance with a high success rate. The main limitations of this model are that it can only be performed using an open bone window, which can underestimate the effects of intracranial hypertension and, as discussed above, it seems to produce a less severe histological damage.

Intracranial balloon model. Sinar *et al* (16) developed a model with micro balloon insertion in rats as a way to study the effects

of a mass leading to IHT. A micro balloon 25 Fr mounted on a needle was inserted into the right caudate nucleus through a burr hole in the skull of the animal. The micro balloon was inflated to 0.05 ml over a period of 20 sec and maintained for 10 min after intervention was inflated and deflated. At the end of the study, the authors examined the histology of the brain, intracranial pressure (ICP) and cerebral blood flow. They found the micro balloon model to be successful in producing an effective brain injury, causing a reduction in cerebral blood flow and an ICP increase at the site of injury. The main advantage of the balloon model according to Alharbi *et al* (92) is that it imitates the mass effect of an acute cerebral hematoma in humans.

Andrade *et al* (93) also evaluated the variation on intracranial pressure and showed that this method reliably leads to IHT. The present study describes below the hands-on experience of the authors of this review, with previously unpublished information and images (Figs. 3-5). It was submitted to and approved by the Institutional Animal Care and Use Committee of the School of Medicine at the University of São Paulo (USP) (approval no. 019/14; being developed according to the recommendations of the National Council for the Control of Animal Experimentation and the Ethics Committee on Animal Use.

Piglets were separated into 3 groups: First group with mild intracranial hypertension, a second group with severe intracranial hypertension and for the third group a cerebral rebleeding model. Prior to surgery, the animals fasted for 12 h but had free access to water. Intramuscular ketamine was co-administered at a dose of 15 mg/kg and xylazine at a dose of 2 mg/kg as a preanesthetic. Once intravenous (IV) access was obtained, anesthesia was induced with propofol at a dose of 5 mg/kg. The animals also received an initial IV volume of 20 ml/kg physiological saline (NaCl 0.9%) to compensate for volume loss due to fasting, and fluid support was continued throughout at a rate of 5 ml/kg/h. Anesthesia was maintained with IV propofol. In this protocol, ICP, direct brain oxygen pressure and results of transcranial Doppler exams were performed (Fig. 3). To induce IHT, a balloon 8Fr was used (Fig. 4) in piglets (average weight, 20 kg). The injury caused by balloon produces IHT with local expansion (Fig. 5).

Studies for ultrasound assessment of the optic nerve sheath diameter (34,94) and transcranial Doppler pulsatility index (35) have taken advantage of this method because of sudden IHT development. Thus, the balloon model appears to be sufficient for generating oscillations in intracranial pressure measurements as well as for causing an impact on cerebral hemodynamic conditions and valuable for studying the effects of mechanical damage to the brain tissue (43). Although it's an easily reproducible method, it has numerous limitations as follows: i) Does not reproduce blood toxicity in the brain parenchyma, this could be the reason for a lesser degree of ischemia in this model compared with the injection of an equivalent volume of blood; ii) does not promote blood brain barrier disruption: and iii) is not able to induce edema formation (16).

4. Experimental studies in small animals

Rodents are the pillar of modeling in ICH (16,72). They were first used as modeling for brain hematomas by Bullock *et al* in 1984 (61), where ICH was induced by femoral artery

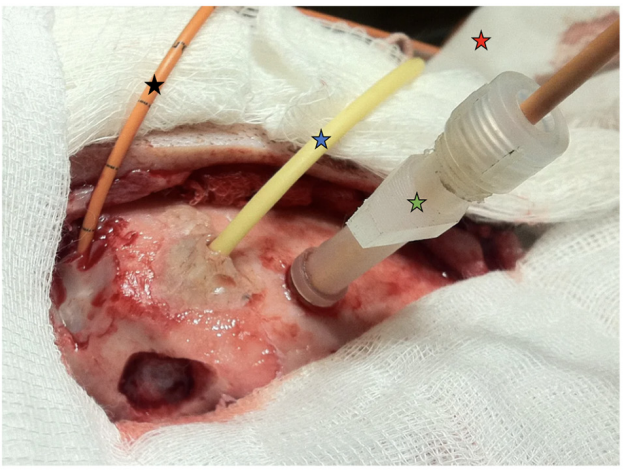

Figure 3. Piglet surgery model with instrumentation implanted in the skull. Black star, ICP monitor with external ventricular drain; blue star, intracranial balloon; red star, transcranial Doppler probe; green star, intraparenchymal probe for ICP, brain oximetry and temperature monitoring. ICP, intracranial pressure.

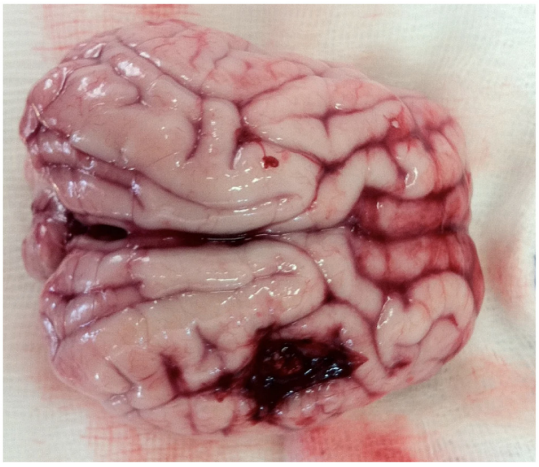

Figure 4. Piglet brain after experiment with cortical injury produced by the intracranial balloon.

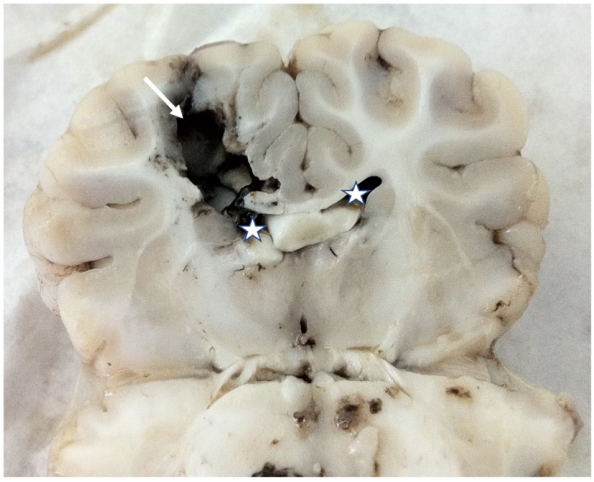

Figure 5. Piglet brain sagittal section after surgery. The balloon inflation produces injury by intracranial hypertension with local expansion, but not much adjacent injury. The arrow shows brain injury caused by the balloon inflation. The white stars mark the lateral ventricles of the animal.

cannulation, which provides blood at arterial pressures directly to the brain. Ever since, these animals have been used for different experimental models of brain hematoma, such as autologous blood injection, bacterial collagenase and cerebral balloons (70,93-96).

There are numerous advantages of using mice and rats as models for ICH, such as the excellent cost effectiveness (70), accurate paradigms for testing and outcomes (95) and an extensive sample of reagents for immunohistochemistry and molecular biology (96). Moreover, the availability of transgenic systems in the mouse allows for genetic studies on ICH and its mechanisms of lesion (96). The main disadvantage of rodents is the small size of the brain, which limits the clot volume that can be created and complicate its use in surgical studies (70,96). Furthermore, the lack of brain gyrus and the small amount of white matter limits the correlation with the human brain.

5. Experimental studies in developed brain gyri animals

Piglets have well developed white matter, a relatively low cost and no major difficulties with protective animal societies, being an excellent species for ICH studies (93). The possibility of using hematoma volumes 20 to 30 times higher in this model compared with rodent species also allows the test of hematoma removal (surgery simulation) in addition to providing the rebleeding simulation (93). Shi *et al* (97) described the balloon technique in the subcortical white matter, instead of blood injected into the gray matter or the basal ganglia. The use of this method turns obtaining a more uniform and reproducible hematoma volume possible, facilitating the extrapolation of information to humans, especially because of the greater volume of white matter found in larger animals and the developing edema adjacent to the hematoma.. This model is clinically relevant since the ICP information can be extrapolated from models to clinical treatment.

Wagner *et al* (49) developed a lobar hemorrhage model in pigs, where 1.7 ml of autologous arterial blood is slowly injected in the frontal white matter using an infusion pump. The slow injection reduces the likelihood of ventricular rupture or leakage of blood along the needle path. Compared with rapid infusions at high pressures, this method seems to reproduce more reliably deep hematomas in humans, which usually arise from bleeding of small parenchymal arteries (49). Küker *et al* (98) described a model injecting 0.5 to 2.0 ml of blood with a venous blood reservoir into the previous frontal lobe bruising to study the characteristics using magnetic resonance imaging. In another study (39), the authors modified this model into a double injection procedure (with a main injection of 2 to 3 ml of autologous venous blood reservoir) to better prevent post-injection reflux. The use of pigs is still a useful model of intracranial hypertension due to the presence of cortical gyri, which makes the model more similar to the human brain compared with murine models (99). Infusion of autologous blood in the piglet model has been used to investigate the ICP, cerebral blood flow, development of edema, brain metabolism, transcription factor and gene expression for inflammatory activation (96,99,100). It has also been used to study the possibility of surgical hematomas (101) and clot lysis induced by tissue plasminogen activator (102). It has also been used to test the effects of brain injury induced inhibition of heme oxygenase (14) and iron chelators deferoxamine (103). While the use of autologous blood allows the evaluation of the biochemical effects of blood on neurons, these models do not evaluate in a simple and direct way the effects of surgery for the removal of hematomas.

Piglets are also used in models of collagenase injection. Mun-Bryce *et al* (38) described a 10 ml collagenase pump infusion for 20 to 30 min in the right somatosensory cortex. This study examined the excitability of the tissue around the hematoma and evaluated the results of brain injury using magnetic resonance imaging and magnetoencephalography. The use of collagenase does not address the clinically relevant phenomenon of vasogenic edema associated with cerebral hematoma and so does not offer the ideal conditions for studies on intracranial pressure (102). However, collagenase levels in the pig model are much higher compared with those found in human brain injury, making it difficult to derive any correlation to clinical information (103).

Based on classical studies with a balloon, Shi *et al* (97) published an experimental model using a pediatric urinary catheter inflated with saline to achieve anatomical space and then infusing autologous blood. However, the analyses of cerebral hemodynamics were not carried out and its variables only evaluated the clinical condition of the animals days after the surgical procedure that simulated a deep intracerebral hematoma. Another study in pigs (104) was intended to simulate a diffuse intracerebral injury with the method of acceleration and rapid deceleration compared with a control group. In this study ICP values were analyzed; however, it is a model that cannot reverse brain damage by surgical procedure and also does not apply to intracerebral hematoma models.

6. Controlling and sham

A few studies compared the index population with appropriate controls (56,57,94,104). Some studies report the control group to be composed by intact animals, the comparison of different infusions as autologous blood or collagenase, and even the reproduction of ICH with the exclusive insertion of an intracranial canula without any intervention (77,88,93,103). The present review observed that using a sham group is not a common practice in this regard but used more often for the assessment of immune-inflammatory factors and cerebral blood flow, in the autologous blood infusion and balloon inflation models (16). Hua *et al* (56), for example, aimed to assess edema reduction and the inhibition of complement factors induced by autologous blood injection in rats by comparing groups with and without the addition of N-acetyl heparin after ICH. Xi *et al* (57) infused the same amount of saline in contrast to different preparations of red blood cells in order to assess brain swelling and the brain blood barrier permeability, also in rats. With distinction from the models described, Azevedo *et al* (94) assessed ultrasound of the optic nerve sheath (ONSD) in piglets to observe these animals ONSD standard values and its variation according to different anesthetics infusion. These values also served as references to non-invasive screening for ICH simulation; whereas Friess *et al* (104) evaluated neurological multimodal monitoring (ICP, oximetry and microdialysis) in

randomized pigs with no-impact rotational traumatic brain injury and no injured instrumented (the same techniques) sham.

7. Limitations

The difficulties in transferring information from experimental models to clinical settings derive from specific aspects of each species, as well as limitations of the models and methods. For the most part, experiments use younger animals with greater functional reserve and hemodynamics. Moreover, rodents disclose an outstanding capacity of regeneration and rehabilitation that is not comparable with humans (11). The complex pathophysiology of brain hematomas involving vascular injury as well as apoptosis and molecular aspects involved hinder the translation of information. The majority of studies are conducted in murine models and there are important differences in cerebral hemodynamic changes on the acute phase of intracranial hypertension for these animals compared to humans. Regarding the studies, a wide methodologic heterogeneity for injury inducing was found, likewise, appropriate controlled study designs are lacking since a few studies used suitable controls to evaluate their endpoints.

8. Conclusions

Animal models have the potential to enhance our understanding of the pathophysiology and treatment of intracranial hypertension and brain hematomas, being essential to develop and evaluate new therapeutic strategies in preclinical settings. To decide which is the best model for each research, some points must be considered: The purpose of each model, the primary outcome of the study, considering whether hematoma is in the acute or chronic phase and molecular vs. hemodynamic analysis.

Acknowledgements

Not applicable.

Funding

No funding was received.

Availability of data and materials

The datasets used and/or analyzed during the current study are available from the corresponding author on reasonable request.

Authors' contributions

WSP, SB and IN conceptualized and planned the execution of the study, collected references and prepared the manuscript. GCP, EZ, DAG, AFDA and MJT collected and compiled data and prepared the manuscript. SB, CM and RD performed manuscript review and online search. WSP, AFDA and SB confirm the authenticity of all the raw data. All authors have read and approved the final manuscript.

Ethics approval and consent to participate

This study was approved by the Institutional Animal Care and Use Committee of the School of Medicine at the University of São Paulo (USP) (approval no. 019/14; being developed according to the recommendations of the National Council for the Control of Animal Experimentation and the Ethics Committee on Animal Use.

Patient consent for publication

Not applicable.

Competing interests

The authors declare that they have no competing interests.

Authors' information

Dr Sérgio Brasil, ORCID 0000-0003-2397-9947.

References

1. Bor-Seng-Shu E, Kita WS, Figueiredo EG, Paiva WS, Fonoff ET, Teixeira MJ and Panerai RB: Cerebral hemodynamics: Concepts of clinical importance. Arq Neuropsiquiatr 70: 352-356, 2012.
2. Andrade AF, Paiva WS, Amorim RL, Figueiredo EG, Almeida AN, Brock RS, Bor-Seng-Shu E and Teixeira MJ: Continuous ventricular cerebrospinal fluid drainage with intracranial pressure monitoring for management of posttraumatic diffuse brain swelling. Arq Neuropsiquiatr 69: 79-84, 2011.
3. Paiva WS, de Andrade AF, de Amorim RL, Muniz RK, Paganelli PM, Bernardo LS, Figueiredo EG and Teixeira MJ: The prognosis of the traumatic subarachnoid hemorrhage: A prospective report of 121 patients. Int Surg 95: 172-176, 2010.
4. Qureshi AI, Tuhrim S, Broderick JP, Batjer HH, Hondo H and Hanley DF: Spontaneous intracerebral hemorrhage. N Engl J Med 344: 1450-1460, 2001.
5. van Asch CJ, Luitse MJ, Rinkel GJ, van der Tweel I, Algra A and Klijn CJ: Incidence, case fatality, and functional outcome of intracerebral haemorrhage over time, according to age, sex, and ethnic origin: A systematic review and meta-analysis. Lancet Neurol 9: 167-176, 2010.
6. Broderick JP, Brott TG, Duldner JE, Tomsick T and Huster G: Volume of intracerebral hemorrhage. A powerful and easy-to-use predictor of 30-day mortality. Stroke 24: 987-993, 1993.
7. Fogelholm R, Murros K, Rissanen A and Avikainen S: Long term survival after primary intracerebral haemorrhage: A retrospective population based study. J Neurol Neurosurg Psychiatry 76: 1534-1538, 2005.
8. Hemphill JCI III, Bonovich DC, Besmertis L, Manley GT and Johnston SC: The ICH score: A simple, reliable grading scale for intracerebral hemorrhage. Stroke 32: 891-897, 2001.
9. Broderick J, Connolly S, Feldmann E, Hanley D, Kase C, Krieger D, Mayberg M, Morgenstern L, Ogilvy CS, Vespa P, *et al*: Guidelines for the management of spontaneous intracerebral hemorrhage in adults: 2007 Update: A guideline from the American heart association/American stroke association stroke council, high blood pressure research council, and the quality of care and outcomes in research interdisciplinary working group. Stroke 38: 2001-2023, 2007.
10. Brasil S, Paiva WS, de Carvalho Nogueira R, Macedo Salinet A and Teixeira MJ: Letter to the editor. Decompressive craniectomy in TBI: What is beyond static evaluations in terms of prognosis? J Neurosurg 129: 845-847, 2018.
11. Zille M, Farr TD, Keep RF, Römer C, Xi G and Boltze J: Novel targets, treatments, and advanced models for intracerebral haemorrhage. EBioMedicine 76: 103880, 2022.
12. Godoy DA, Núñez-Patiño RA, Zorrilla-Vaca A, Ziai WC and Hemphill JC III: Intracranial hypertension after spontaneous intracerebral hemorrhage: A systematic review and meta-analysis of prevalence and mortality rate. Neurocrit Care 31: 176-187, 2019.

13. Brasil S, Bor-Seng-Shu E, de-Lima-Oliveira M, Taccone FS, Gattás G, Nunes DM, Gomes de Oliveira RA, Martins Tomazini B, Tierno PF, Becker RA, *et al*: Computed tomography angiography accuracy in brain death diagnosis. J Neurosurg: Sep 27, 2019 (Epub ahead of print).
14. Wagner KR, Hua Y, de Courten-Myers GM, Broderick JP, Nishimura RN, Lu SY and Dwyer BE: Tin-mesoporphyrin, a potent heme oxygenase inhibitor, for treatment of intracerebral hemorrhage: In vivo and in vitro studies. Cell Mol Biol (Noisy-le-grand) 46: 597-608, 2000.
15. Goulay R, Naveau M, Gaberel T, Vivien D and Parcq J: Optimized tPA: A non-neurotoxic fibrinolytic agent for the drainage of intracerebral hemorrhages. J Cereb Blood Flow Metab 38: 1180-1189, 2018.
16. Sinar EJ, Mendelow AD, Graham DI and Teasdale GM: Experimental intracerebral hemorrhage: Effects of a temporary mass lesion. J Neurosurg 66: 568-576, 1987.
17. Fang Y, Tian Y, Huang Q, Wan Y, Xu L, Wang W, Pan D, Zhu S and Xie M: Deficiency of TREK-1 potassium channel exacerbates blood-brain barrier damage and neuroinflammation after intracerebral hemorrhage in mice. J Neuroinflammation 16: 96, 2019.
18. Kane PJ, Modha P, Strachan RD, Cook S, Chambers IR, Clayton CB and Mendelow AD: The effect of immunosuppression on the development of cerebral oedema in an experimental model of intracerebral haemorrhage: Whole body and regional irradiation. J Neurol Neurosurg Psychiatry 55: 781-786, 1992.
19. Fei X, Dou YN, Wang L, Wu X, Huan Y, Wu S, He X, Lv W, Wei J and Fei Z: Homer1 promotes the conversion of A1 astrocytes to A2 astrocytes and improves the recovery of transgenic mice after intracerebral hemorrhage. J Neuroinflammation 19: 67, 2022.
20. Mello TG, Rosado-de-Castro PH, Vasques JF, Pinhão C, Santos TM, de Lima RR, Foerster BU, Paiva FF, Mendez-Otero R and Pimentel-Coelho PM: Hyperacute transplantation of umbilical cord mesenchymal stromal cells in a model of severe intracerebral hemorrhage. Future Sci OA 8: FSO793, 2022.
21. Wang G, Li T, Duan SN, Dong L, Sun XG and Xue F: PPAR-γ promotes hematoma clearance through haptoglobin-hemoglobin-CD163 in a rat model of intracerebral hemorrhage. Behav Neurol 2018: 7646104, 2018.
22. Xu J, Chen Z, Yu F, Liu H, Ma C, Xie D, Hu X, Leak RK, Chou SHY, Stetler RA, *et al*: IL-4/STAT6 signaling facilitates innate hematoma resolution and neurological recovery after hemorrhagic stroke in mice. Proc Natl Acad Sci USA 117: 32679-32690, 2020.
23. Jing C, Bian L, Wang M, Keep RF, Xi G and Hua Y: Enhancement of hematoma clearance with CD47 blocking antibody in experimental intracerebral hemorrhage. Stroke 50: 1539-1547, 2019.
24. Zhao X, Ting SM, Liu CH, Sun G, Kruzel M, Roy-O'Reilly M and Aronowski J: Neutrophil polarization by IL-27 as a therapeutic target for intracerebral hemorrhage. Nat Commun 8: 602, 2017.
25. Fu X, Zhou G, Zhuang J, Xu C, Zhou H, Peng Y, Cao Y, Zeng H, Li J, Yan F, *et al*: White matter injury after intracerebral hemorrhage. Front Neurol 12: 562090, 2021.
26. Xu F, Shen G, Su Z, He Z and Yuan L: Glibenclamide ameliorates the disrupted blood-brain barrier in experimental intracerebral hemorrhage by inhibiting the activation of NLRP3 inflammasome. Brain Behav 9: e01254, 2019.
27. Tschoe C, Bushnell CD, Duncan PW, Alexander-Miller MA and Wolfe SQ: Neuroinflammation after intracerebral hemorrhage and potential therapeutic targets. J Stroke 22: 29-46, 2020.
28. Yang Y, Chen X, Feng Z, Cai X, Zhu X, Cao M, Yang L, Chen Y, Wang Y and Feng H: MEC17-induced α-tubulin acetylation restores mitochondrial transport function and alleviates axonal injury after intracerebral hemorrhage in mice. J Neurochem 160: 51-63, 2022.
29. Zhu W, Gao Y, Chang CF, Wan JR, Zhu SS and Wang J: Correction: Mouse models of intracerebral hemorrhage in ventricle, cortex, and hippocampus by injections of autologous blood or collagenase. PLoS One 16: e0261640, 2021.
30. Liesz A, Middelhoff M, Zhou W, Karcher S, Illanes S and Veltkamp R: Comparison of humoral neuroinflammation and adhesion molecule expression in two models of experimental intracerebral hemorrhage. Exp Transl Stroke Med 3: 11, 2011.
31. Hijioka M, Anan J, Matsushita H, Ishibashi H, Kurauchi Y, Hisatsune A, Seki T and Katsuki H: Axonal dysfunction in internal capsule is closely associated with early motor deficits after intracerebral hemorrhage in mice. Neurosci Res 106: 38-46, 2016.
32. Bahader GA, Nash KM, Almarghalani DA, Alhadidi Q, McInerney MF and Shah ZA: Type-I diabetes aggravates post-hemorrhagic stroke cognitive impairment by augmenting oxidative stress and neuroinflammation in mice. Neurochem Int 149: 105151, 2021.
33. Zheng J, Shi L, Liang F, Xu W, Li T, Gao L, Sun Z, Yu J and Zhang J: Sirt3 ameliorates oxidative stress and mitochondrial dysfunction after intracerebral hemorrhage in diabetic rats. Front Neurosci 12: 414, 2018.
34. Jeng BCP, de Andrade AF, Brasil S, Bor-Seng-Shu E, Belon AR, Robertis M, de-Lima-Oliveira M, Rubiano AM, Godoy DA, Teixeira MJ and Paiva WS: Estimation of intracranial pressure by ultrasound of the optic nerve sheath in an animal model of intracranial hypertension. J Clin Neurosci 86: 174-179, 2021.
35. Soares MS, Andrade AF, Brasil S, DE-Lima-Oliveira M, Belon AR, Bor-Seng-Shu E, Nogueira RC, Godoy DA and Paiva WS: Evaluation of cerebral hemodynamics by transcranial Doppler ultrasonography and its correlation with intracranial pressure in an animal model of intracranial hypertension. Arq Neuropsiquiatr 80: 344-352, 2022.
36. Liu R, Cao S, Hua Y, Keep RF, Huang Y and Xi G: CD163 expression in neurons after experimental intracerebral hemorrhage. Stroke 48: 1369-1375, 2017.
37. Cao S, Zheng M, Hua Y, Chen G, Keep RF and Xi G: Hematoma changes during clot resolution after experimental intracerebral hemorrhage. Stroke 47: 1626-1631, 2016.
38. Mun-Bryce S, Wilkerson AC, Papuashvili N and Okada YC: Recurring episodes of spreading depression are spontaneously elicited by an intracerebral hemorrhage in the swine. Brain Res 888: 248-255, 2001.
39. Rohde V, Rohde I, Thiex R, Ince A, Jung A, Dückers G, Gröschel K, Röttger C, Küker W, Müller HD and Gilsbach JM: Fibrinolysis therapy achieved with tissue plasminogen activator and aspiration of the liquefied clot after experimental intracerebral hemorrhage: Rapid reduction in hematoma volume but intensification of delayed edema formation. J Neurosurg 97: 954-962, 2002.
40. Xie Q, Gu Y, Hua Y, Liu W, Keep RF and Xi G: Deferoxamine attenuates white matter injury in a piglet intracerebral hemorrhage model. Stroke 45: 290-292, 2014.
41. Sussman BJ, Barber JB and Goald H: Experimental intracerebral hematoma. Reduction of oxygen tension in brain and cerebrospinal fluid. J Neurosurg 41: 177-186, 1974.
42. Takasugi S, Ueda S and Matsumoto K: Chronological changes in spontaneous intracerebral hematoma-an experimental and clinical study. Stroke 16: 651-658, 1985.
43. Whisnant JP, Sayre GP and Millikan CH: Experimental Intracerebral Hematoma. Arch Neurol 9: 586-592, 1963.
44. Symon L, Pasztor E, Branston NM and Dorsch NW: Effect of supratentorial space-occupying lesions on regional intracranial pressure and local cerebral blood flow: An experimental study in baboons. J Neurol Neurosurg Psychiatry 37: 617-626, 1974.
45. Boltze J, Ferrara F, Hainsworth AH, Bridges LR, Zille M, Lobsien D, Barthel H, McLeod DD, Gräßer F, Pietsch S, *et al*: Lesional and perilesional tissue characterization by automated image processing in a novel gyrencephalic animal model of peracute intracerebral hemorrhage. J Cereb Blood Flow Metab 39: 2521-2535, 2019.
46. Lin X, Tang Y, Sun B, Hou Z, Meng H, Li Z, Liu Q and Liu S: Cerebral glucose metabolism: Influence on perihematomal edema formation after intracerebral hemorrhage in cat models. Acta Radiol 51: 549-554, 2010.
47. Kaufman HH, Pruessner JL, Bernstein DP, Borit A, Ostrow PT and Cahall DL: A rabbit model of intracerebral hematoma. Acta Neuropathol 65: 318-321, 1985.
48. Zhang C, Qian X, Zheng J, Ai P, Cao X, Pan X, Chen T and Wang Y: Controlled decompression alleviates brain injury via attenuating oxidative damage and neuroinflammation in acute intracranial hypertension. Biomed Res Int 2022: 1936691, 2022.
49. Wagner KR, Xi G, Hua Y, Kleinholz M, de Courten-Myers GM, Myers RE, Broderick JP and Brott TG: Lobar intracerebral hemorrhage model in pigs: Rapid edema development in perihematomal white matter. Stroke 27: 490-497, 1996.
50. Wagner KR, Xi G, Hua Y, Kleinholz M, de Courten-Myers GM and Myers RE: Early metabolic alterations in edematous perihematomal brain regions following experimental intracerebral hemorrhage. J Neurosurg 88: 1058-1065, 1998.

51. Chen J, Koduri S, Dai S, Toyota Y, Hua Y, Chaudhary N, Pandey AS, Keep RF and Xi G: Intra-hematomal white matter tracts act as a scaffold for macrophage infiltration after intracerebral hemorrhage. Transl Stroke Res 12: 858-865, 2021.
52. MacLellan CL, Silasi G, Auriat AM and Colbourne F: Rodent models of intracerebral hemorrhage. Stroke 41 (Suppl 10): S95-S98, 2010.
53. Yang GY, Betz AL, Chenevert TL, Brunberg JA and Hoff JT: Experimental intracerebral hemorrhage: Relationship between brain edema, blood flow, and blood-brain barrier permeability in rats. J Neurosurg 81: 93-102, 1994.
54. Xi G, Keep RF and Hoff JT: Erythrocytes and delayed brain edema formation following intracerebral hemorrhage in rats. J Neurosurg 89: 991-996, 1998.
55. Xi G, Wagner KR, Keep RF, Hua Y, de Courten-Myers GM, Broderick JP, Brott TG and Hoff JT: Role of blood clot formation on early edema development after experimental intracerebral hemorrhage. Stroke 29: 2580-2586, 1998.
56. Hua Y, Xi G, Keep RF and Hoff JT: Complement activation in the brain after experimental intracerebral hemorrhage. J Neurosurg 92: 1016-1022, 2000.
57. Xi G, Hua Y, Bhasin RR, Ennis SR, Keep RF and Hoff JT: Mechanisms of edema formation after intracerebral hemorrhage: Effects of extravasated red blood cells on blood flow and blood-brain barrier integrity. Stroke 32: 2932-2938, 2001.
58. Belayev L, Saul I, Curbelo K, Busto R, Belayev A, Zhang Y, Riyamongkol P, Zhao W and Ginsberg MD: Experimental intracerebral hemorrhage in the mouse: Histological, behavioral, and hemodynamic characterization of a double-injection model. Stroke 34: 2221-2227, 2003.
59. Nakamura T, Keep RF, Hua Y, Schallert T, Hoff JT and Xi G: Deferoxamine-induced attenuation of brain edema and neurological deficits in a rat model of intracerebral hemorrhage. J Neurosurg 100: 672-678, 2004.
60. Liu L, Wang S, Xu R, Zheng J, Tang J, Tang X and Zhang D: Experimental intracerebral haemorrhage: Description of a semi-coagulated autologous blood model in rats. Neurol Res 37: 874-879, 2015.
61. Bullock R, Mendelow AD, Teasdale GM and Graham DI: Intracranial haemorrhage induced at arterial pressure in the rat. Part 1: Description of technique, ICP changes and neuropathological findings. Neurol Res 6: 184-188, 1984.
62. Manaenko A, Chen H, Zhang JH and Tang J: Comparison of different preclinical models of intracerebral hemorrhage. Acta Neurochir Suppl 111: 9-14, 2011.
63. Wakisaka Y, Chu Y, Miller JD, Rosenberg GA and Heistad DD: Spontaneous intracerebral hemorrhage during acute and chronic hypertension in mice. J Cereb Blood Flow Metab 30: 56-69, 2010.
64. Bai Q, Sheng Z, Liu Y, Zhang R, Yong VW and Xue M: Intracerebral haemorrhage: From clinical settings to animal models. Stroke Vasc Neurol 5: 388-395, 2020.
65. Deinsberger W, Vogel J, Kuschinsky W, Auer LM and Böker DK: Experimental intracerebral hemorrhage: Description of a double injection model in rats. Neurol Res 18: 475-477, 1996.
66. Deinsberger W, Hartmann M, Vogel J, Jansen O, Kuschinsky W, Sartor K and Böker DK: Local fibrinolysis and aspiration of intracerebral hematomas in rats. An experimental study using MR monitoring. Neurol Res 20: 349-352, 1998.
67. Orakcioglu B, Becker K, Sakowitz OW, Herweh C, Köhrmann M, Huttner HB, Steiner T, Unterberg A and Schellinger PD: MRI of the perihemorrhagic zone in a rat ICH model: Effect of hematoma evacuation. Neurocrit Care 8: 448-455, 2008.
68. Orakcioglu B, Becker K, Sakowitz OW, Unterberg A and Schellinger PD: Serial diffusion and perfusion MRI analysis of the perihemorrhagic zone in a rat ICH model. Acta Neurochir Suppl 103: 15-18, 2008.
69. Deng S, Feng S, Wang W, Zhao F and Gong Y: Biomarker and drug target discovery using quantitative proteomics post-intracerebral hemorrhage stroke in the rat brain. J Mol Neurosci 66: 639-648, 2018.
70. James ML, Warner DS and Laskowitz DT: Preclinical models of intracerebral hemorrhage: A translational perspective. Neurocrit Care 9: 139-152, 2008.
71. Rosenberg GA, Mun-Bryce S, Wesley M and Kornfeld M: Collagenase-induced intracerebral hemorrhage in rats. Stroke 21: 801-807, 1990.
72. Clark W, Gunion-Rinker L, Lessov N and Hazel K: Citicoline treatment for experimental intracerebral hemorrhage in mice. Stroke 29: 2136-2140, 1998.
73. Wang J, Wang G, Yi J, Xu Y, Duan S, Li T, Sun XG and Dong L: The effect of monascin on hematoma clearance and edema after intracerebral hemorrhage in rats. Brain Res Bull 134: 24-29, 2017.
74. Fu P, Liu J, Bai Q, Sun X, Yao Z, Liu L, Wu C and Wang G: Long-term outcomes of monascin-a novel dual peroxisome proliferator-activated receptor γ/nuclear factor-erythroid 2 related factor-2 agonist in experimental intracerebral hemorrhage. Ther Adv Neurol Disord: May 14, 2020.
75. Wasserman JK, Yang H and Schlichter LC: Glial responses, neuron death and lesion resolution after intracerebral hemorrhage in young vs aged rats. Eur J Neurosci 28: 1316-1328, 2008.
76. Liddle L, Reinders R, South S, Blacker D, Knuckey N, Colbourne F and Meloni B: Poly-arginine-18 peptides do not exacerbate bleeding, or improve functional outcomes following collagenase-induced intracerebral hemorrhage in the rat. PLoS One 14: e0224870, 2019.
77. Akhter M, Qin T, Fischer P, Sadeghian H, Kim HH, Whalen MJ, Goldstein JN and Ayata C: Rho-kinase inhibitors do not expand hematoma volume in acute experimental intracerebral hemorrhage. Ann Clin Transl Neurol 5: 769-776, 2018.
78. Lee ST, Chu K, Sinn DI, Jung KH, Kim EH, Kim SJ, Kim JM, Ko SY, Kim M and Roh JK: Erythropoietin reduces perihematomal inflammation and cell death with eNOS and STAT3 activations in experimental intracerebral hemorrhage. J Neurochem 96: 1728-1739, 2006.
79. Wu CH, Shyue SK, Hung TH, Wen S, Lin CC, Chang CF and Chen SF: Genetic deletion or pharmacological inhibition of soluble epoxide hydrolase reduces brain damage and attenuates neuroinflammation after intracerebral hemorrhage. J Neuroinflammation 14: 230, 2017.
80. Kinoshita K, Ohtomo R, Takase H, Hamanaka G, Chung KK, Lok J, Katsuki H and Arai K: Different responses after intracerebral hemorrhage between young and early middle-aged mice. Neurosci Lett 735: 135249, 2020.
81. Li W, Chopp M, Zacharek A, Yang W, Chen Z, Landschoot-Ward J, Venkat P and Chen J: SUMO1 deficiency exacerbates neurological and cardiac dysfunction after intracerebral hemorrhage in aged mice. Transl Stroke Res 12: 631-642, 2021.
82. Kirkman MA, Allan SM and Parry-Jones AR: Experimental intracerebral hemorrhage: Avoiding pitfalls in translational research. J Cereb Blood Flow Metab 31: 2135-2151, 2011.
83. Chang CC, Huang KH, Hsu SP, Lee YG, Sue YM and Juan SH: Simvastatin reduces the carcinogenic effect of 3-methylcholanthrene in renal epithelial cells through histone deacetylase 1 inhibition and RhoA reactivation. Sci Rep 9: 4606, 2019.
84. Wang M, Hua Y, Keep RF, Wan S, Novakovic N and Xi G: Complement inhibition attenuates early erythrolysis in the hematoma and brain injury in aged rats. Stroke 50: 1859-1868, 2019.
85. Strbian D, Durukan A and Tatlisumak T: Rodent models of hemorrhagic stroke. Curr Pharm Des 14: 352-358, 2008.
86. Zhou X, Chen L, Feng C, Li B, Tang J, Liu A, Lv F and Li T: Establishing an animal model of intracerebral hemorrhage under the guidance of ultrasound. Ultrasound Med Biol 39: 2116-2122, 2013.
87. Lei B, Sheng H, Wang H, Lascola CD, Warner DS, Laskowitz DT and James ML: Intrastriatal injection of autologous blood or clostridial collagenase as murine models of intracerebral hemorrhage. J Vis Exp: 51439, 2014.
88. MacLellan CL, Silasi G, Poon CC, Edmundson CL, Buist R, Peeling J and Colbourne F: Intracerebral hemorrhage models in rat: Comparing collagenase to blood infusion. J Cereb Blood Flow Metab 28: 516-525, 2008.
89. Funnell WR, Maysinger D and Cuello AC: Three-dimensional reconstruction and quantitative evaluation of devascularizing cortical lesions in the rat. J Neurosci Methods 35: 147-156, 1990.
90. Xue M and Del Bigio MR: Comparison of brain cell death and inflammatory reaction in three models of intracerebral hemorrhage in adult rats. J Stroke Cerebrovasc Dis 12: 152-159, 2003.
91. Lauer A, Cianchetti FA, Van Cott EM, Schlunk F, Schulz E, Pfeilschifter W, Steinmetz H, Schaffer CB, Lo EH and Foerch C: Anticoagulation with the oral direct thrombin inhibitor dabigatran does not enlarge hematoma volume in experimental intracerebral hemorrhage. Circulation 124: 1654-1662, 2011.
92. Alharbi BM, Tso MK and Macdonald RL: Animal models of spontaneous intracerebral hemorrhage. Neurol Res 38: 448-455, 2016.

93. Andrade AF, Soares MS, Patriota GC, Belon AR, Paiva WS, Bor-Seng-Shu E, Oliveira Mde L, Nascimento CN, Noleto GS, Alves Junior AC, *et al*: Experimental model of intracranial hypertension with continuous multiparametric monitoring in swine. Arq Neuropsiquiatr 71: 802-806, 2013.
94. Azevedo MR, de-Lima-Oliveira M, Belon AR, Brasil S, Teixeira MJ, Paiva WS and Bor-Seng-Shu E: Assessing ultrasonographic optic nerve sheath diameter in animal model with anesthesia regimens. Acta Cir Bras 37: e370308, 2022.
95. Wagner T, Fregni F, Fecteau S, Grodzinsky A, Zahn M and Pascual-Leone A: Transcranial direct current stimulation: A computer-based human model study. Neuroimage 35: 1113-1124, 2007.
96. Wagner KR: Modeling intracerebral hemorrhage: Glutamate, nuclear factor-kappa B signaling and cytokines. Stroke 38 (2 Suppl): S753-S758, 2007.
97. Shi Y, Li Z, Zhang S, Xie M, Meng X, Xu J, Liu N and Tang Z: Establishing a model of supratentorial hemorrhage in the piglet. Tohoku J Exp Med 220: 33-40, 2010.
98. Küker W, Thiex R, Rohde I, Rohde V and Thron A: Experimental acute intracerebral hemorrhage. Value of MR sequences for a safe diagnosis at 1.5 and 0.5 T. Acta Radiol 41: 544-552, 2000.
99. Wagner KR, Packard BA, Hall CL, Smulian AG, Linke MJ, De Courten-Myers GM, Packard LM and Hall NC: Protein oxidation and heme oxygenase-1 induction in porcine white matter following intracerebral infusions of whole blood or plasma. Dev Neurosci 24: 154-160, 2002.
100. Wagner KR, Sharp FR, Ardizzone TD, Lu A and Clark JF: Heme and iron metabolism: Role in cerebral hemorrhage. J Cereb Blood Flow Metab 23: 629-652, 2003.
101. Zuccarello M, Andaluz N and Wagner KR: Minimally invasive therapy for intracerebral hematomas. Neurosurg Clin N Am 13: 349-354, 2002.
102. Wagner KR, Xi G, Hua Y, Zuccarello M, de Courten-Myers GM, Broderick JP and Brott TG: Ultra-early clot aspiration after lysis with tissue plasminogen activator in a porcine model of intracerebral hemorrhage: Edema reduction and blood-brain barrier protection. J Neurosurg 90: 491-498, 1999.
103. Gu Y, Hua Y, Keep RF, Morgenstern LB and Xi G: Deferoxamine reduces intracerebral hematoma-induced iron accumulation and neuronal death in piglets. Stroke 40: 2241-2243, 2009.
104. Friess SH, Ralston J, Eucker SA, Helfaer MA, Smith C and Margulies SS: Neurocritical care monitoring correlates with neuropathology in a swine model of pediatric traumatic brain injury. Neurosurgery 69: 1139-1147, 2011.