Optic neuropathy associated with acute pancreatitis: A case report

HANA CHYLOVA[1], ZORA DUBSKA[2], MARTIN KYNCL[1], MARTIN FUS[1] and JÁN LEŠTÁK[1]

[1]Department of Natural Sciences, Faculty of Biomedical Engineering, Czech Technical University in Prague, 27201 Kladno; [2]Department of Ophthalmology, First Faculty of Medicine, Charles University and General University Hospital in Prague, 12108 Prague, Czech Republic

Received October 3, 2022; Accepted November 10, 2022

DOI: 10.3892/etm.2022.11757

Abstract. The present article describes a case of a 24-year-old patient who suffered from acute pancreatitis. The patient simultaneously developed visual acuity loss and changes in the visual field. When examined, the finding was physiological, including the fundoscopy. Neither fluorescein angiography or optical coherence tomography demonstrated any retinal abnormalities; electroretinography was physiological as well. The visual evoked potentials (VEP) showed abnormalities in amplitudes. Patient's visual field was reduced to 40°. The follow-up examination 13 months after the first symptoms proved a progression of changes in the visual field and prolonged latency of P100 peak in VEP. The retinal nerve fibre layer stayed unchanged, but the vessel density on the optic nerve head decreased. Magnetic resonance brain imaging showed non-specific subcortical and paraventricular focuses in the white matter of both hemispheres. There were no other abnormalities detected by magnetic resonance imaging. Neurological examination was normal. In conclusion, the present study verified this decrease of visual functions as a lesion in the visual pathway using VEP, which was also confirmed by magnetic resonance brain imaging.

Introduction

Purtscher's retinopathy, also known as 'angiopathia retinae traumatica', first described by Otmar Purtscher in 1910, is a traumatic angiopathy caused mostly by thoracal or cranial trauma. The most common retinal symptoms are bilateral ischaemic lesions (cottonwool spots or Purtscher Flecken) and retinal haemorrhages (dot-like, preretinal or flame-shaped) (1). Laboratory and clinical observations have shown that microparticles involved in the pathogenesis of Purtscher's retinopathy lead to occlusion of small arterioles. These microparticles may be composed of aggregated leukocytes or fibrin clots. The phenomenon of intravascular coagulation is well known after trauma or acute pancreatitis. Purtscher's retinopathy is associated with both conditions (2). Besides these causes, many other triggers can cause these changes in the retina (3).

A rare complication of bilateral vision loss has been described in a young alcoholic with acute pancreatitis and was verified as Purtscher's retinopathy (4). This finding can develop even several months after acute pancreatitis (5). We were interested in the case of a young patient, who suffered from an acute pancreatitis with visual impairment, which was not caused by Purtscher's retinopathy, but probably by bilateral ischaemic neuropathy. Therefore, we present this case report, which has not to date been reported in the literature.

Case report

A young woman (born 1996), otherwise healthy, consumed wine daily at a dose of approximately 500 ml per day (because of personal problems). Due to abdominal pain and collapse, she was admitted to the intensive care unit of a regional hospital in Czech Republic, where she was diagnosed with acute pancreatitis. During the hospitalization, vision was impaired, and she described 'disappearing around the subject'. On the first ophthalmological examination, the distance visual acuity was 0.3 and near 0.3 particularly. There was a fragmented foveolar reflex in fundoscopy, but otherwise the findings were normal. The macular OCT scan was also normal. Perimetric examination showed concentric constriction to 40 degrees.

Purtscher's retinopathy was suspected, but the ocular findings excluded this suspicion. The CT scan of the brain showed no abnormalities.

On examination at the clinical site in September 2021, visual acuity was 1.0 particularly. The patient reported subjectively blurred outlines of the letters. The colour vision was impaired, but after prolonged concentration she was able to read the Velhagen charts correctly. Ocular findings including biomicroscopy and fundus fluorescence angiography were in the physiological range and intraocular pressure was 13/13 mmHg. As part of this medical follow-up, systemic blood examinations were performed with the following results: Blood count (CBC), blood coagulation index, erythrocyte sedimentation rate (ESR), and so on, would give a better

Correspondence to: Dr Ján Lešták, Department of Natural Sciences, Faculty of Biomedical Engineering, Czech Technical University in Prague, 3105 Sitna Square, no. 2, 27201 Kladno, Czech Republic
E-mail: lestak@seznam.cz

Key words: ischemic optic neuropathy, acute pancreatitis, lesion in visual pathway, magnetic resonance imaging, visual evoked potentials

demonstrate of the disease), were normal except for C-reactive protein (above the upper limit of normal, see Table I).

The patient was recommended treatment with B vitamin (milgamma N 1 amp. i.m. 3 times per week). Apart from this recommended medication, the patient was taking velaxin for depression in the long term.

In November 2021, the examination was extended with electroretinography (pattern electroretinogram), which showed normal retinal response in both eyes. The visual evoked potential examination (PVEP) with 1-degree square stimulation showed a small decrease in both A1 and A2 amplitudes (10 and 9.2 uV), without any prolonged latency of the P100 ms peak. When smaller squares were used (15 min), responses were significantly reduced (4.5 and 6 uV). P100 peak latency was still not prolonged (6). The examination was performed with the Roland Consult electrophysiological diagnostic system (Germany) according to the ISCEV methodology. The size of the stimulation field was 41x31 angular degrees.

A perimetric examination, which was performed with the Medmont M700 (Australia), fast threshold program in the range of 0-30 degrees, also proved a progression of defects (Fig. 1).

At the follow-up examination 13 months after the onset of visual impairment, the distance visual acuity (VA) was 0.8 and the near VA was 0.6. Intraocular pressure was 12/12 mmHg. Colour vision examination was normal again with careful concentration. Fundoscopy showed slight pigment abnormalities in the foveal area and mild perifoveal brightening on the left eye. The findings were otherwise normal. Perimetric examination showed a progression of changes (Fig. 1).

The pattern electroretinogram (PERG)-according to ISCEV method (using DTC contact electrodes, reference electrode was placed on the skin near the ipsilateral outer canthus of each eye, the size of the stimulating area was 15 degrees, the reversal rate of the squares equal to 0.8 degrees and the contrast equal to 80%) was bilaterally normal (Fig. 2). The PVEP with 1 degree squares stimulation showed borderline amplitudes (12.5 and 10 uV), with a prolongation of the P100 peak latency to 121 ms on the right and 129 ms on the left eye. Using smaller squares (15 min), the responses were borderline on the right (12.3 uV) and significantly reduced on the left (3.6 uV). P100 peak latencies were prolonged to 130 ms on the right and 124 ms on the left eye.

Retinal nerve fibre layer (RNFL) was 131 μm on the right and 127 μm on the left eye. The vessel density was also normal. The examination was performed on the Avanti RTVue XR by Optovue (USA), see results in Fig. 3.

At the follow-up examination 13 months after the onset of visual impairment, RNFL was 131 and 124 μm, but there was a decrease of approximately 10% in all values in vessel density (Fig. 3).

The MRI examination (Fig. 4) was performed in November 2021 on an Achieva dStream TX SERIES 3T machine (Philips HealthCare, Best, Nederland) with a 32-channel SENSE RF head coil. The imaging protocol included T2 mDIXON coronal and axial sequences (TR/TE 3,000/80ms), 3D FLAIR (TR/TE 4,800/269ms), T2 3D DRIVE (TR/TE 2,000/240ms), Turbo Field Echo (TFE) T1 3D sequence (TR/TE 7/3ms), VenBold (TR/TE 15/21) and DWI (TR/TE 3,616/79ms).

The aetiology seemed to be post-inflammatory, because of numerous small focuses of non-specific gliosis in the white matter of both cerebral hemispheres. A follow-up MRI scan 13 months after the onset of the disorder demonstrated also nonspecific focuses in the white matter of both cerebral hemispheres subcortically and paraventricularly bilaterally in stationary number and location as in the November 2021 scan.

Table I. Blood analysis results.

Blood parameter	Acronym	Results	Reference interval	Units
Leukocytes	WBC	5.57	4.00-10.00	10^9/l
Erythrocytes	RBC	4.12	3.8-5.20	10^{12}/l
Haemoglobin	HGB	124	120-160	g/l
Haematocrit	HCT	0.395	0.350-0.470	1
Thrombocytes	PLT	298	150-400	10^9/l
Neutrophils	NE	59.9	45.0-70.0	%
Lymphocytes	LY	29.3	20.0-45.0	%
Monocytes	MO	9.5	2.0-12.0	%
Eosinophils	EO	0.9	0.0-5.0	%
Basophils	BA	0.4	0.0-2.0	%
C-Reactive protein[a]	CBC	5.3	<5.0	mg/l

[a]Parameter out of reference interval.

Neurological examinations over time (the last one in August 2022) showed no abnormalities.

We concluded the finding as bilateral optic neuropathy, probably of ischaemic origin. With the atrophy of the damaged optic nerve fibres, there was a prolongation of VEP latency and a decrease in VD over time.

The patient's current status as of October 2022 corresponds to uncorrected distance visual acuity of 0.8 partially, and 0.6 for uncorrected near visual acuity (in decimal values).

Discussion

Coagulation abnormalities can present with a spectrum of findings, from isolated intravascular thrombosis to severe disseminated intravascular coagulation. Purtscher's retinopathy, caused by microembolisation in choroidal and retinal arterioles, should be included among the various systemic manifestations of acute pancreatitis. Such visual disturbance may be a rare systemic manifestation of acute pancreatitis that has not been associated with a severe or complicated clinical course. There is no targeted treatment of these ocular complications, so the outcome therefore depends on the resolution of the primary pancreatic disease (7).

The course of the optic nerve can be divided into intraorbital, intracanalicular and intracranial sections. The blood supply to these different parts of the nerve is provided by many arterial branches, therefore an ischaemia of the posterior optic nerve may not be caused by occlusion of a single artery. The intraorbital segment is supplied by both the peripheral centripetal vascular system from the pial plexus and the axial centrifugal vascular system composed of branches of the central retinal artery (8).

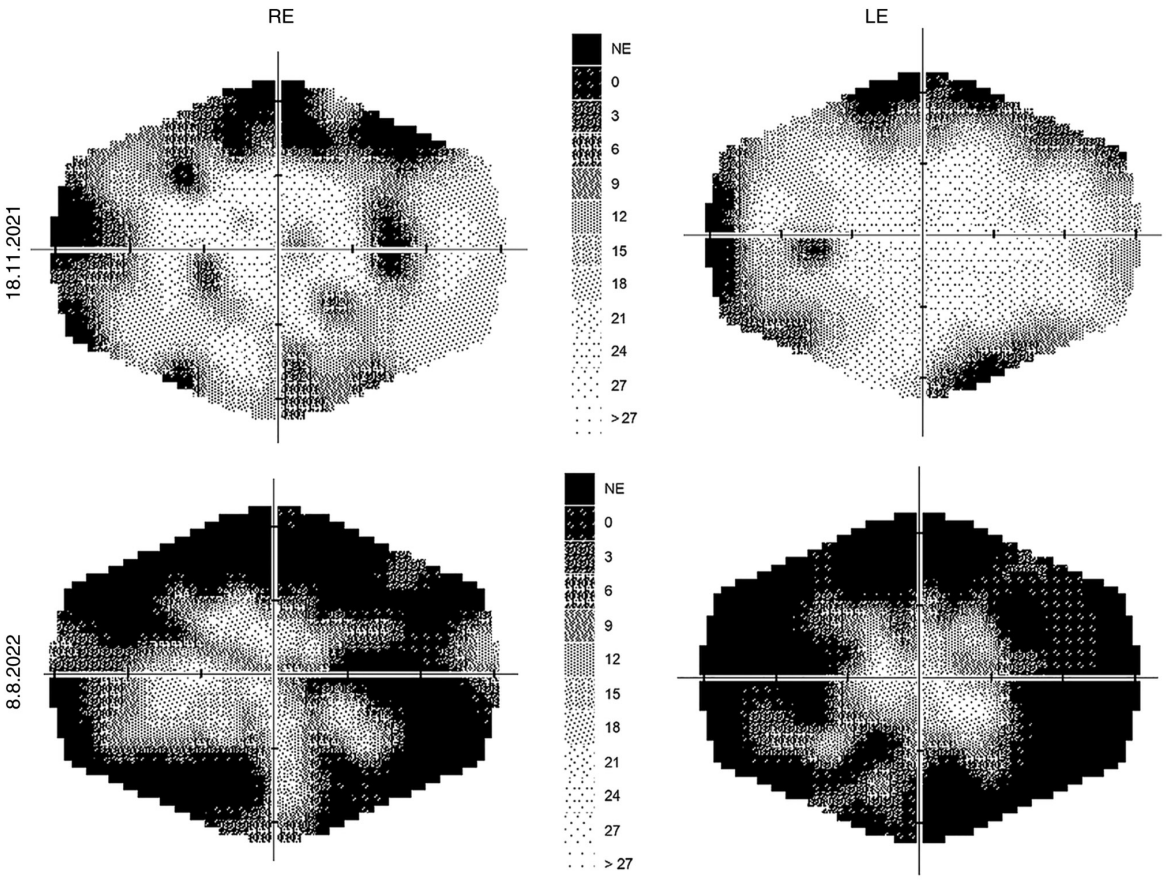

Figure 1. Reduction of central part of the visual field from November 2021 (above), and its progression from August 2022 (below). RE, right eye; LE, left eye.

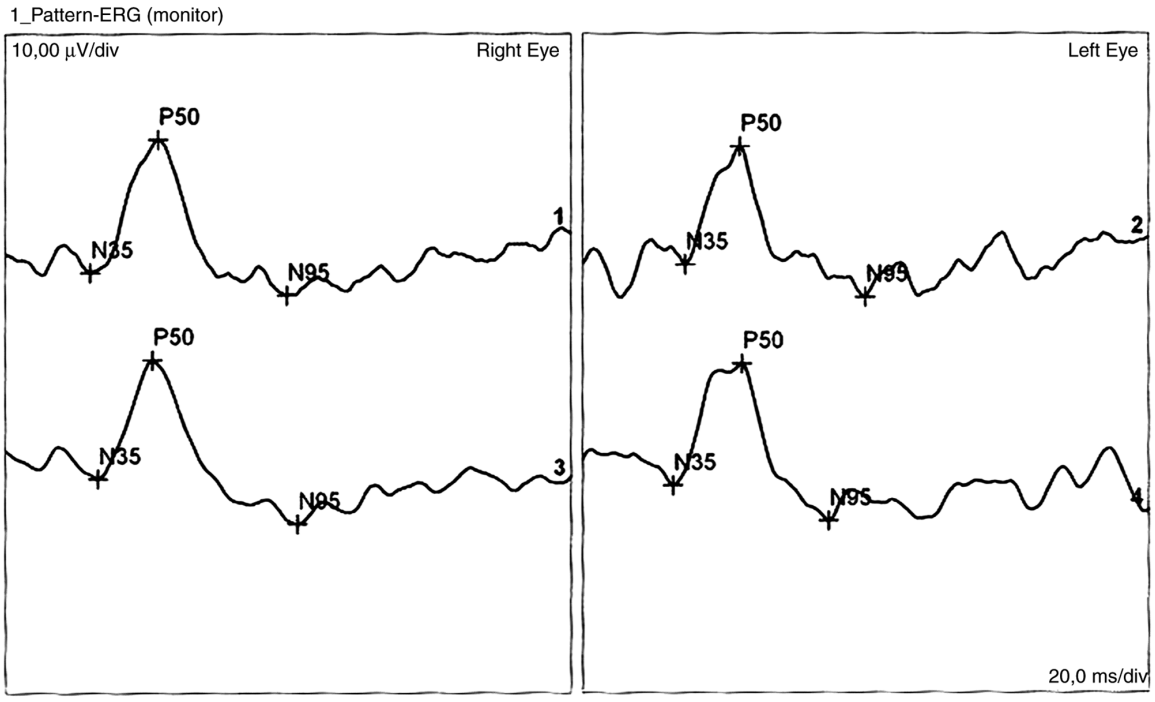

Normals	25–45	40–60	85–105	1 µV-8 µV	2 µV-10 µV
Channel	N35 [ms]	P50 [ms]	N95 [ms]	N35-P50	P50-N95
1 R-1 48 min	27.1	48.6	89.5	12.2 µV	14.2 µV
3 R-1 48 min	29.6	46.8	93.0	10.8 µV	15 µV
2 L-2 48 min	32.8	50.0	89.8	10.8 µV	13.8 µV
4 L-2 48 min	28.9	50.7	78.2 (l)	11.1 µV	14.4 µV

Figure 2. Report of Pattern. ERG, electroretinography examination.

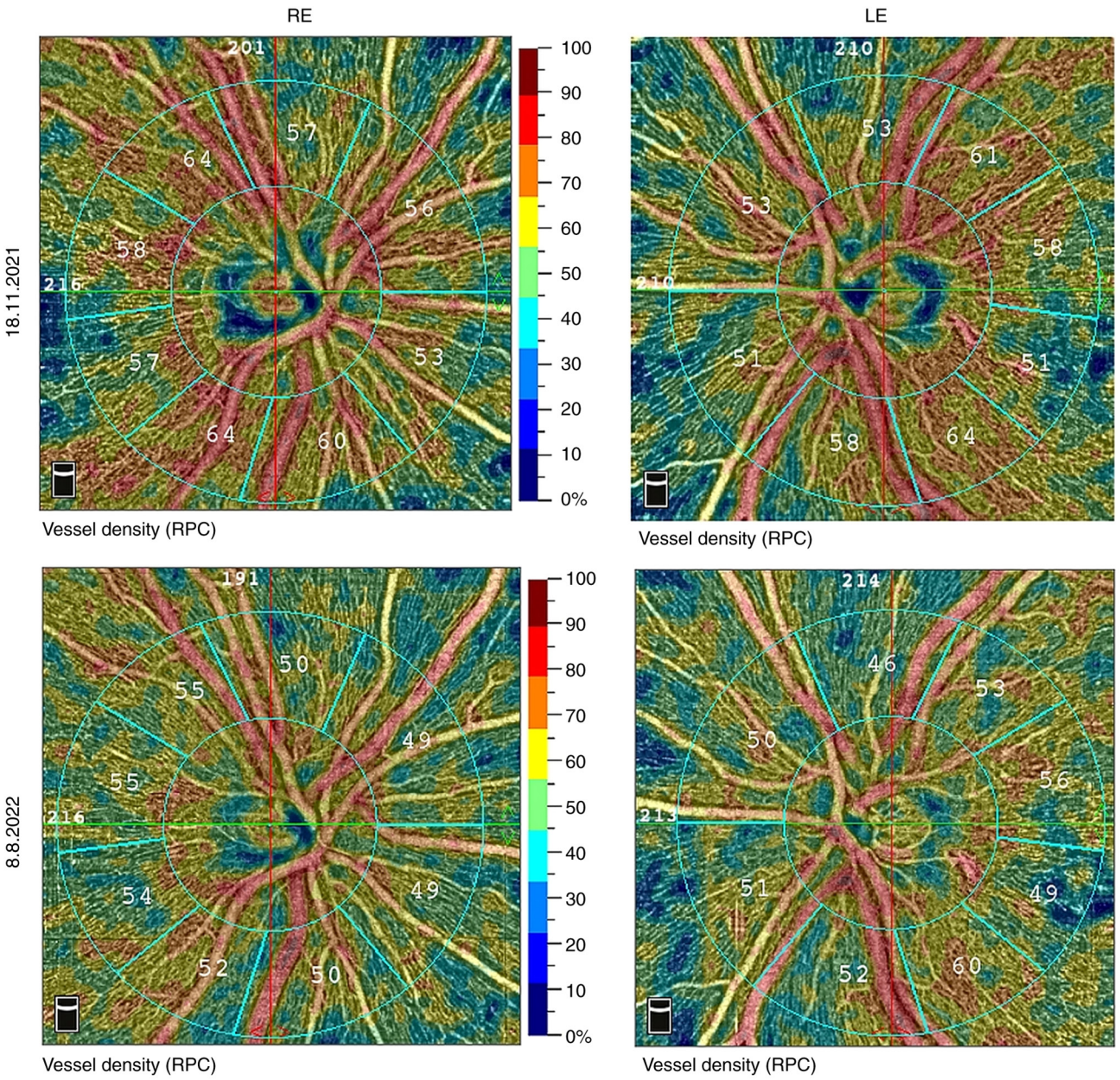

Figure 3. Vessel density of RPC in November 2021 (above) and its decline in August 2022 (below). RE, right eye; LE, left eye; RPC, radial peripapillary capillaries.

Manifestation of non-arteritic posterior ischaemic neuropathy (PION) is rare and usually arises from a small vessel disease. It is associated with multifactorial systemic diseases such as diabetes mellitus, hypertension, atherosclerosis or other causes (carotid artery dissection, carotid cavernous fistula) (9), migraine (8,10,11), associated with haemodialysis (8,12), or head injury (8). Perioperative conditions can also be the cause (13-18).

However, histopathological findings of PION may vary between patients, and the lack of accurate data is also due to only sporadic case reports in the available literature. It has been reported that the optic nerve can be spared in either the peripheral or central segment, but there are also cases of complete loss of the axons with total optic nerve infarction. This variability is due to the different routes of vascular supply from the central retinal artery, as mentioned above. Specifically, ischaemia involving centrifugal vascular systems spares the central portion of the nerve, whereas ischaemia involving centripetal vascular supply systems spares the peripheral portion of the nerve. The latter case of ischaemia is more common in both arteritic and non-arteritic PION (8).

In non-arteritic PION, visual acuity ranges from 20/25 or better in 17 % of patients, 20/40 or better in 20 % and 20/200 or worse in 69 % 18. Central visual field defects are common in both arteritic and non-arteritic PION (7).

In cases of acute ischaemic injury to the posterior part of the optic nerve, cytotoxic oedema occurs and results in water molecules accumulating intracellularly from the extracellular space, restricting diffusion across the cell membrane. Thus, ischaemia of the pial branches supplying the periphery, or

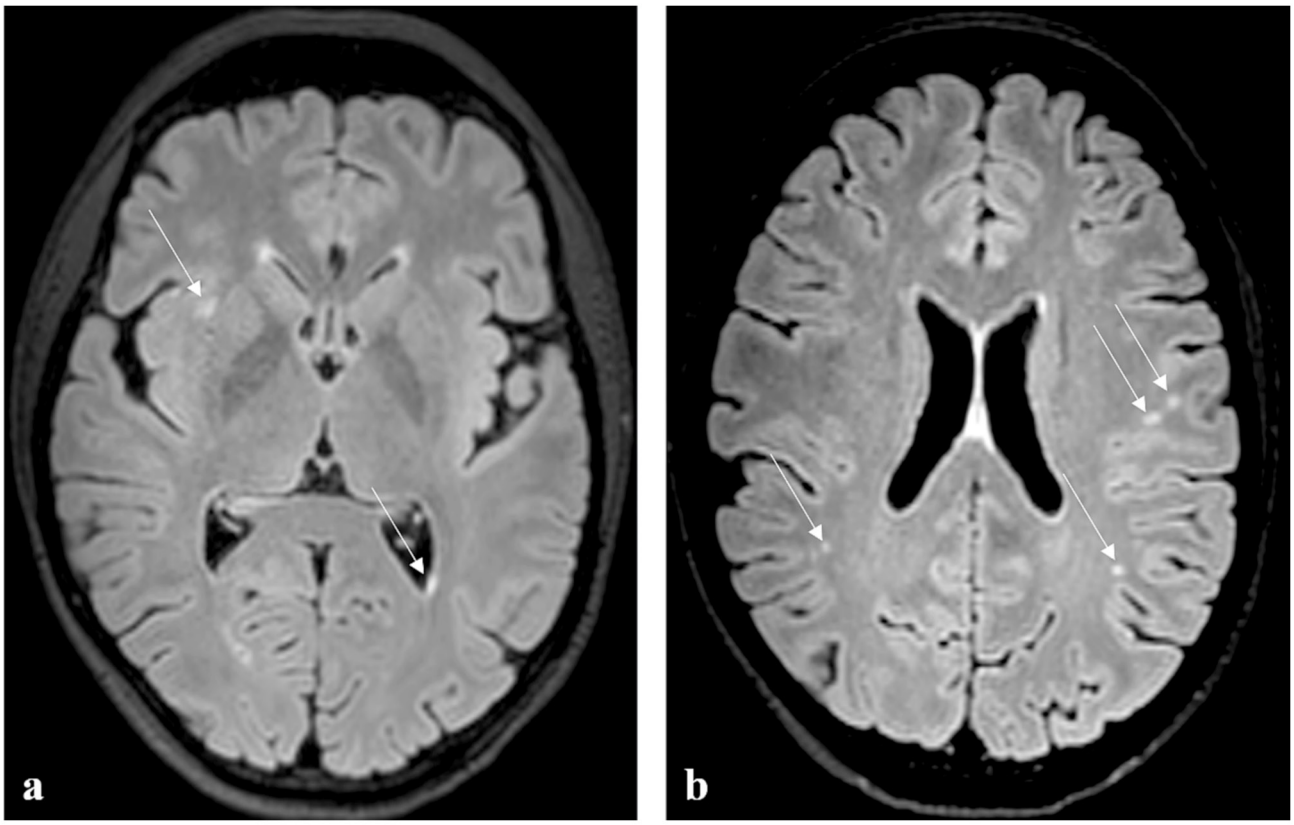

Figure 4. Magnetic resonance imaging, 3D FLAIR, axial reconstruction (TR/TE 4,800/269 ms). Small focuses of non-specific gliosis in the white matter of both cerebral hemispheres. (a) Hyperintense FLAIR foci in paraventricular region on the left and in the insular region on the right (arrows). (b) Multiple punctate foci of gliosis in the subcortical white matter (arrows). FLAIR, fluid-attenuated inversion recovery.

of the central retinal artery supplying the centre, could both be theoretically determined using DWI, but only a few cases have been reported diagnosing PION successfully in this manner (19).

Our patient, therefore, could have suffered an ischaemia of the intracranial part of the peripheral and possibly central part of the visual pathway. This ischaemia could also be induced by inflammatory products in pancreatitis. That is what the brain MRI results showed.

The fundoscopy findings showing normal RNFL and VD values, and pathological VEP support this hypothesis. Subsequent follow-up examination showed prolonged P100 peak latency in VEP and decreased VD values. These findings may be indicative of ongoing atrophy in the visual pathway.

In conclusion, posterior ischaemic neuropathy is a relatively rare disease. Its association with acute pancreatitis has not yet been described in the literature. Therefore, it is important to consider this neuro-ophthalmological abnormality in patients with acute pancreatitis.

Acknowledgements

Not applicable.

Funding

No funding was received.

Availability of data and materials

The datasets used and/or analysed during the current study are available from the corresponding author on reasonable request.

Authors' contributions

HC conceptualized and designed the study, and is lead author of the manuscript. ZD, MK, MF and JL implemented clinical investigations and outcome assessment, and share co-authorship of the manuscript. All authors have read and approved the final manuscript. HC and JL confirm the authenticity of all the raw data.

Ethics approval and consent to participate

The present case report was performed according to the Declaration of Helsinki and was approved by the Internal Ethics Committee of the Ophthalmology Clinic JL (Prague, Czech Republic). All data used were anonymized.

Patient consent for publication

All details, medical records, figures, medical history or test results were used with the written informed consent for publication from the patient.

Competing interests

The authors declare that they have no competing interests.

References

1. Purtscher O: Angiopathia retinae traumatica. Lymphorrhagien des Augengrundes. Albrecht von Graefe Arch Ophth 82: 347-371, 1912.
2. Behrens-Baumann W, Scheurer G and Schroer H: Pathogenesis of Purtscher's retinopathy. An experimental study. Graefes Arch Clin Exp Ophthalmol 230: 286-291, 1992.
3. Tripathy K and Patel BC: Purtscher retinopathy. In: StatPearls [Internet]. StatPearls Publishing, Treasure Island, FL, 2022.
4. Suárez Crespo JF, de Teresa Galván FJ, Sánchez Rico C, González Galilea A, Pinel Julián LM, Espinosa Aguilar MD and López de Hierro Ruiz M: Purtscher's retinopathy and acute alcoholic pancreatitis. Rev Esp Enferm Dig 885: 513-515, 1996 (In Spanish).
5. Sharma AG, Kazim NA, Eliott D, Houghton O and Abrams GW: Purtscher's retinopathy that occurred 6 months before acute pancreatitis. Am J Ophthalmol 141: 205-207, 2006.
6. Lešták J, Nutterová E, Pitrová Š, Krejčová H, Bartošová L and Forgáčová V: High tension versus normal tension glaucoma. A comparison of structural and functional examinations. J Clinic Exp Ophthalmol S: 5, 2012.
7. Campo SM, Gasparri V, Catarinelli G and Sepe M: Acute pancreatitis with Purtscher's retinopathy: Case report and review of the literature. Dig Liver Dis 32: 729-732, 2000.
8. Hayreh SS: Posterior ischaemic optic neuropathy: Clinical features, pathogenesis, and management. Eye (Lond) 18: 1188-1206, 2004.
9. Oh DJ, Chhadva P, Kanu LN, Liu CY and Macintosh PW: Sudden-onset blindness from a spontaneous carotid-cavernous fistula with secondary central retinal artery occlusion and posterior ischemic optic neuropathy. Neuroophthalmology 43: 107-113, 2018.
10. Lee AG, Brazis PW and Miller NR: Posterior ischemic optic neuropathy associated with migraine. Headache 36: 506-510, 1996.
11. Foroozan R, Marx DP and Evans RW: Posterior ischemic optic neuropathy associated with migraine. Headache 48: 1135-1139, 2008.
12. Buono LM, Foroozan R, Savino PJ, Danesh-Meyer HV and Stanescu D: Posterior ischemic optic neuropathy after hemodialysis. Ophthalmology 110: 1216-1218, 2003.
13. Buono LM and Foroozan R: Perioperative posterior ischemic optic neuropathy: Review of the literature. Surv Ophthalmol 50: 15-26, 2005.
14. Weber ED, Colyer MH, Lesser RL and Subramanian PS: Posterior ischemic optic neuropathy after minimally invasive prostatectomy. J Neuroophthalmol 27: 285-287, 2007.
15. Eli IM, Kim RB, Kilburg C, Pecha TJ, Couldwell WT and Menacho ST: Postoperative posterior ischemic optic neuropathy after left far-lateral craniectomy for resection of craniocervical meningioma. World Neurosurg 114: 339-343, 2018.
16. Levinson B and Reddy S: Posterior ischemic optic neuropathy after extensive spine surgery: A case report and review of the literature. AANA J 87: 37-42, 2019.
17. Oliver JD, Kobets AJ, Judy BF and Cohen AR: Posterior ischemic optic neuropathy following supine craniotomy for epidural abscess in a child. Childs Nerv Syst 37: 2657-2660, 2021.
18. Hayreh SS: Ischemic optic neuropathy. Prog Retin Eye Res 28: 34-62, 2009.
19. Maramattom BV, Sundar S, Thomas D and Panikar D: Postoperative posterior ischemic optic neuropathy (PION) following right pterional meningioma surgery. Ann Indian Acad Neurol 19: 374-376, 2016.