TopClosure® tension-relief system improves clinical outcomes of patients with breast cancer undergoing mastectomy

HUAJUN FAN[1*], HAIZHEN JIA[2*], ZHANYONG ZHU[1], YUEQIANG ZHAO[1] and MOSHENG YU[1]

[1]Department of Plastic Surgery, Renmin Hospital of Wuhan University, Wuhan, Hubei 430060; [2]Cardiovascular Department, Tianyou Hospital Affiliated To Wuhan University of Science and Technology, Wuhan, Hubei 430064, P.R. China

Received July 27, 2022; Accepted November 15, 2022

DOI: 10.3892/etm.2022.11769

Abstract. The present randomized controlled study aimed to investigate the effects of TopClosure® tension-relief system (TRS) on patients with breast cancer undergoing mastectomy. A total of 402 female patients with breast cancer who came to the Renmin Hospital of Wuhan University between March 2014 and June 2018 were involved in the present study. All patients receiving mastectomy were randomly divided into the TRS group (n=201) and the control group (n=201). Serum levels of high-sensitivity C-reactive protein, TNF-α, IL-6 and procalcitonin were measured using ELISA. Vancouver Scar Scale was recorded at 2 weeks and 1-3 and 6 months following the operation. The 36-Item Health Survey Scales were performed for all patients at 1 month after surgery. The TRS reduced the incidence of flap necrosis, infection and the duration of hospital stay. In addition, the TRS was found to attenuate inflammation and improve scar outcomes as well as the quality of life. It was concluded that the TRS could significantly improve the clinical outcomes.

Introduction

Breast cancer is one of the commonest female malignancy worldwide, accounting for 25% of female cancer cases (1). The morbidity of breast cancer is up to 11.6%, with mortality of 6.6% across the world (2). Patients with high tumor stage have rather poor prognosis. In recent years, more and more patients with breast cancer in early stage have been diagnosed by breast cancer screening (3). Consequently, surgery can be one of the options for them.

Correspondence to: Dr Mosheng Yu, Department of Plastic Surgery, Renmin Hospital of Wuhan University, 238 Jiefang Street, Wuchang, Wuhan, Hubei 430060, P.R. China
E-mail: MoshengYU2019@163.com

*Contributed equally

Key words: tension-relief system, breast cancer, mastectomy, clinical outcomes, inflammation

Mastectomy is the commonest surgical procedure for patients with breast cancer in China (4). A variety of complications, such as skin flap necrosis, wound dehiscence, inferior quality scarring, and infection, may be triggered by tissue resection with high tension wound closure, excessive wound gap and defects in surgery. In some cases, a skin graft or flap mobilization can be used if the surgical wound cannot be primarily closed (5). TopClosure® tension-relief system (TRS) is a simple and practical system for skin stretching and wound closure-secure. For patient undergoing valgus cystectomy, TRS is a useful method to repair the large abdominal defect in abdominal reconstruction with shorter operative duration and hospital stay. TRS can clearly improve wound aesthetics (6). TRS shows high efficacy for the closure of moderate and large scalp defects and serves as a topical tension-relief platform for tension sutures (6). TRS can reduce local complications, shorten hospital stay and reduce donor site morbidity (7). However, few studies report the effect of TRS application on patients with breast cancer undergoing mastectomy.

The present study was a randomized controlled study to investigate the effect of TRS on clinical outcomes and prognosis for patients with breast cancer undergoing mastectomy. The results showed that application of TRS could significantly improve the clinical outcomes, attenuated inflammation and improve wound aesthetics.

Materials and methods

Patients. The present study enrolled 402 female patients diagnosed with breast cancer, who underwent mastectomy without reconstruction between March 2014 and June 2018. The inclusion criteria were: i) All the patients were diagnosed as breast cancer by histopathological examination; ii) breast cancer was diagnosed for the first time and identified as primary breast cancer; iii) none of the patients received any chemotherapy or radio-therapy before the study and iv) patients were without serious cardiovascular diseases, renal, or liver dysfunctions. The following patients were excluded: i) Patients with other primary malignant tumors or metastatic breast cancer and ii) patients who had received prior breast surgery. Cancer stage was evaluated according to the 8th edition of American Joint Committee on Cancer (AJCC) Cancer Staging Manual (8). The present study was approved by the Ethics Committee of Renmin Hospital of Wuhan University

(approval number WHRMH-214-019A). Written informed consent was obtained from all participants.

All patients received mastectomy and were randomly divided into two groups, TRS group and control group (n=201 for each group) using a computer-generated list by Rv. Uniform formula using SPSS software (SPSS Inc.). Patients in TRS group used a Tension-relief System (TopClosure®, IVT Medical Ltd.) for wound closure and patients in control group received primary suture closure after mastectomy.

TopClosure® TRS. After mastectomy, attachment plates were placed ~3-5 cm away from wound edges, rendered firmly adherent to the skin on both sides and secured to the skin-by-skin staples (Weck; Teleflex Incorporated.). Wound edges were approximated by stress relaxation through tension sutures (Ethicon, Inc.) as previously described elsewhere (9). A strap was then tightened gradually to finalize immediate primary closure of the wound. Drains were placed in the axilla or under the flap. Definite need for closure with skin graft or flap was considered technically as a failure.

All patients were managed according to a standard protocol. Drains were removed once daily with drainage <50 ml. Patients were discharged if drains were removed without signs of wound or systemic complication requiring in-hospital treatment.

Measurement of inflammatory factors and white blood cell count. Serum levels of high-sensitivity C-reactive protein (hs-CRP), TNF-α, IL-6 and procalcitonin (PTC) were detected using ELISA. Commercial ELISA kits used were as follows: hs-CRP (cat. no. MBS3800421; range ~1-16 mg/l; MyBioSource, Inc.), TNF-α (cat. no. ab181421; range ~15.63-1,000 pg/ml), IL-6 (cat. no. ab178013; range ~7.8-500 pg/ml) and PTC (cat. no. ab221828; range ~6.25-400 pg/ml; all from Abcam). White blood cell count was detected using a Coulter automatic blood cell analyzer DxH800 (Beckman Coulter, Inc.).

Vancouver scar scale (VSS) and 36-item health survey scales. The present study used VSS to measure the scar conditions of the patients. The 36-Item Health Survey Scales (10) were used for measurement of quality of life.

The VSS provides a numerical score of the worst portion of a scar to describe scar quality, rating characteristics of pigmentation, vascularity, pliability and height (11). Higher score of VSS generally indicates worse condition for scaring. The 36-Item Health Survey Scales is usually used for evaluating quality of life (12). The 36-Item Health Survey Scales contains eight parameters, including physical function, role-physical, pain, general health, emotional well-being, role-emotional, social function and energy/fatigue. Higher score in each parameter suggests improved quality of life.

Data collection. Demographic and clinical data included age, body mass index, tumor stage, complications, side of operation, pathological type, tension of skin flap closure, hospital length of stay, flap necrosis, total volume of aspirate and the incidence of infection and subcutaneous liquid accumulation. VSS score was recorded at 2 weeks and 1-3 and 6 months following surgery, respectively. The 36-Item Health Survey Scales were

Table I. Baseline characteristics of all patients.

Characteristic	TRS group n=201	Control group n=201	P-value
Age, year	45.22±8.67	44.65±7.69	0.488
BMI, kg/m^2	24.05±2.49	23.88±1.94	0.422
Hypertension, n (%)	28 (13.93)	26 (12.94)	0.770
Diabetes, n (%)	18 (8.96)	20 (9.95)	0.865
Side of operation			
Left, n (%)	113 (56.22)	96 (47.76)	0.110
Right, n (%)	88 (43.78)	105 (52.24)	
TNM stage, n (%)			
I	35 (17.41)	40 (19.90)	0.792
II	126 (62.69)	124 (61.69)	
III	40 (19.90)	37 (18.41)	
Pathological type, n (%)			
Invasive ductal carcinoma	151 (75.12)	159 (79.10)	0.598
Invasive lobular carcinoma	34 (16.92)	30 (14.93)	
Mucinous adenocarcinoma	16 (7.96)	12 (5.97)	
Tumor diameter, n (%)			
>2 cm	155 (77.11)	141 (70.15)	
≤2 cm	46 (22.89)	60 (29.85)	
Skin flap closure			
LTW, n (%)	109 (54.23)	121 (60.20)	0.267
HTW, n (%)	92 (45.77)	80 (39.80)	

LTW, low-tension closure wound; HTW, high-tension closure wound.

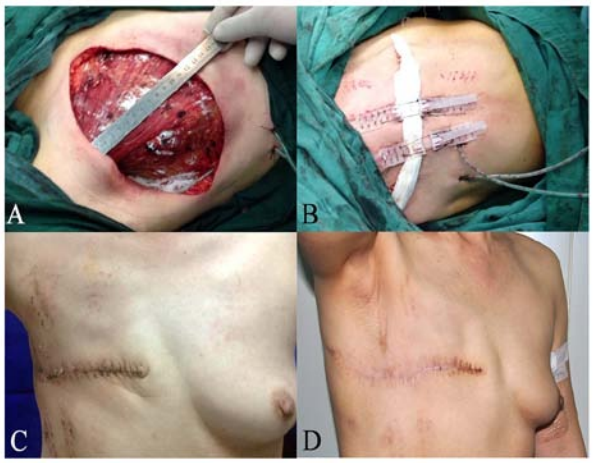

Figure 1. A 46-year-old patient received modified radical mastectomy due to ductal breast cancer. (A) A high-tension flap with 12 cm wide wound gap. (B) Direct primary closure was achieved by cycling of stress-relaxation by tension sutures over the TopClosure® tension-relief system. (C) At 12 days after surgery. (D) At six months after surgery.

Table II. Comparison of inflammatory factors between the two groups.

Inflammatory factor	TRS group, n=201	Control group, n=201	P-value
WBC, x10^9/l	8.96±2.35	10.32±2.51	<0.001
hs-CRP, mg/l	1.05±0.16	1.13±0.25	<0.001
TNF-α, pg/ml	103.97±20.79	128.75±34.74	<0.001
IL-6, pg/ml	294.05±61.54	354.02±91.43	<0.001
PTC, ng/ml	163.73±80.79	168.37±65.24	0.526

WBC, white blood cells; hs-CRP, high-sensitivity C-reactive protein; PTC, procalcitonin.

Table III. Comparison of clinic outcomes between two groups.

	TRS group n=201	Control group n=201	P-value
Flap necrosis, n (%)	0 (0)	28 (13.93)	<0.001
Seroma formation, n (%)	38 (18.91)	43 (21.39)	0.619
Total volume of aspirate, ml	378±72.87	384.69±77.87	0.485
Infection, n (%)	8 (3.98)	30 (14.92)	<0.001
Hospital length of stay, days	11.17±2.05	13.22±3.18	<0.001

TRS, tension-relief system.

Table IV. Comparison for 36-Item Health Survey Scales between two groups.

Parameters	TRS group n=201	Control group n=201	P-value
Physical function	55.12±18.07	49.58±13.47	0.001
Role-physical	40.55±26.88	38.06±27.73	0.362
Pain	44.84±15.93	47.30±18.24	0.149
General health	37.75±12.60	34.05±14.93	0.008
Emotional well-being	50.31±19.11	44.22±15.10	<0.001
Role-emotional	33.67±27.69	34.49±26.95	0.761
Social function	39.30±25.04	35.88±24.18	0.164
Energy/fatigue	68.81±18.52	65.60±18.59	0.084

TRS, tension-relief system.

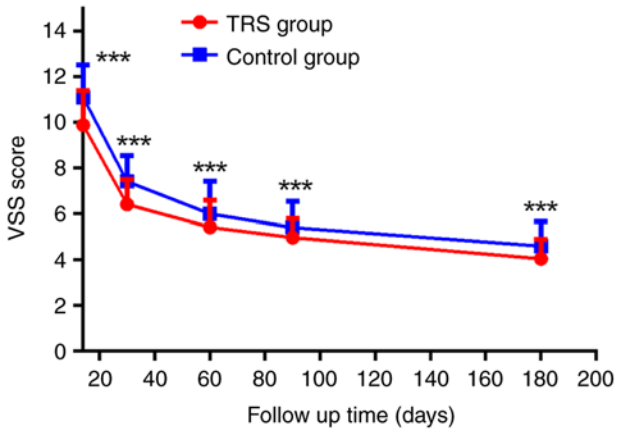

Figure 2. Dynamic change of VSS score in the two groups. VSS score was detected at 14, 30, 60, 90 and 180 days following surgery. ***P<0.001. VSS, Vancouver Scar Scale; TRS, tension-relief system.

performed for all patients at 1 month following surgery. Once mastectomy was completed, the margin gap created was assessed intraoperatively (Fig. 1A-D). Patients with margin gaps <4 cm were considered as having a low-tension closure wound closure whereas patients with margin gaps >4 cm were considered as having a high-tension wound closure. All the patients were followed up for 6 months.

Statistical analysis. Statistical analysis was performed using SPSS 18.0 (SPSS, Inc.). Normally distributed data were expressed by mean ± standard deviation, while non-normally distributed data were expressed by median (range). Comparison between two groups was made using the Student's t-test or Mann-Whitney U test. Comparison among three or more groups was conducted using one-way analysis of variance followed by Tukey post hoc test. The rates were compared by χ^2 test. P<0.05 was considered to indicate a statistically significant difference.

Results

The baseline characteristics of the two groups. The present study enrolled 402 patients with breast cancer undergoing mastectomy. The mean age was 43.7±6.89 years. The baseline characteristics of all patients are listed in Table I. Patients in the TRS group had higher ratio of skin flap closure with low-tension than the control group. There were no significant differences for the other basic characteristics between the two groups. Fig. 1A-D showed the process of wound healing for a 46-year-old patient undergoing modified radical mastectomy with TopClosure® TRS application.

TopClosure® TRS attenuates inflammatory response in postoperative patients with breast cancer. Serum levels of hs-CRP, TNF-α, IL-6 and PTC and white blood cells (WBC) were detected 2 weeks following surgery. The results showed that the levels of WBC, hs-CRP, TNF-α and IL-6 in TRS group were evidently lower compared with the control group (Table II). No significant difference was observed for serum PTC contents between the two groups. This suggested that TRS application clearly attenuated inflammation in patients with breast cancer following surgery.

TopClosure® TRS improves the clinical outcomes of postoperative patients with breast cancer. The clinical outcomes were analyzed for patients with breast cancer following surgery. As shown in Table III, compared with the

controls, TRS application significantly reduced the incidence of flap necrosis (0/201; 0%) and infection (8/201; 3.98%) as well as the duration of hospital stay (10.62±1.52 days). The findings indicated TRS application markedly improved clinical outcomes for patients with breast cancer following surgery.

TopClosure® TRS improves quality of life and decreases severity of scarring. In order to evaluate the quality of life, a survey of 36-Item Health Survey Scales was conducted for all patients at 1 month following surgery. The result revealed that patients receiving TRS treatment had higher scores of physical function, emotional well-being and general health (Table IV). The VSS scores were recorded at 2 weeks and 1-3 and 6 months following surgery. As shown in Fig. 2, VSS score of patients in TRS group was significantly lower than the controls, suggesting improved wound healing. These results suggested that TRS application notably improved qulaity life and the scar outcomes.

Discussion

Skin flap necrosis is a common complication of mastectomy affecting ~3-32% of patients (13-15). In order to avoid skin flap necrosis, accelerate wound healing and to shorten hospital stay, the application of skin-stretching devices has been described in various studies (16-18). In the present study, TRS skin stretching together with secure wound closure device were used to treat the surgical wounds of mastectomy. It was observed that TRS notably improved the clinical outcomes and quality of life as well as decreasing the severity of scarring and inflamation. Consequently, TRS might be a potential skin-stretching device for patients with breast cancer during mastectomy.

In the present study, no skin flap necrosis was observed in TRS group. This might be attributed to the novel characteristics of the TRS. Reportedly, two malleable attachment plates (APs) in TRS can be flexibly fixed to wound margins. Primary wound closure can be achieved by stress relaxation through tension sutures without injuring the underlying skin. The plates serve as a tension-relief platform, shielding the skin from direct damage of the tension sutures, reducing modified radical mastectomy flap tension, especially in cases of high-tension flaps. Moreover, the flap is tightly fixed to the chest after fixation and stretch of the APs. Thus, eliminating dead space and promoting angiogenesis (19-21). Hence, incidence of flap necrosis is reduced. Furthermore, the device can also be used for immediate or delayed primary closure of large wounds by stress relaxation during surgery (7,22). By contrast, conventional (relaxation-suturing) tension suturing induces high and non-uniform tension on the flap margins, resulting in local ischemia, necrosis, scarring and wound dehiscence. Due to the expected high-tension closure and high rate of recurrence, primary closure is not suitable for large skin defects. Therefore, TRS has become a promising option for skin stretching and wound closure-secure for trauma and oncologic surgery.

Emerging evidence illustrates that TRS serves as substitute for skin grafts, tissue expanders and flap (23). The TRS significantly restrained blood loss and reduced donor site morbidity, as well as improving wound aesthetics and minimizing the risk for future reconstructive procedure in a 3-day-old female infant undergoing surgical resection of the giant scalp hemangioma (24). The same results can be found in some other cases. For instance, a case study on a 36-year-old man receiving surgical resection of the keloid showed that primary closure with TRS contributed to simplified surgical procedures and reduced the operative time (25). Meanwhile, TRS contributes to cosmetic improvements of scarring and decreases the probability of future reconstructive procedures of anterior chest wall (25). Ashkenazi *et al* (26) found that a large skin defect treated with TRS could avoid extending the scope of surgery with skin grafting or flaps, as well as reducing possibility of donor site morbidity. In addition, TRS exhibits the potential for immediate primary closure of high-tension mastectomy wounds (26). For the closure of extensive wounds, TRS reduces the incidence of major complications, such as wound dehiscence or infections; moreover, all healed wounds were stable in one-year follow-up (27).

However, the application of TRS is only illustrated in few case reports. The present study conducted a randomized controlled study to investigate the effect of TRS on breast surgery for patients with breast cancer. The results showed that TRS reduced the incidence of flap necrosis and infection, shortened hospital stay, improved wound aesthetics and the quality of life. These findings were consistent with the above previous studies (24-27). Surgery may trigger acute inflammatory response, which shows close association with the clinical outcomes. Lee *et al* (28) reveals that postoperative inflammation was an important risk factor for the mortality of patients with breast cancer. The present study noted that TRS application decreased inflammation following surgery. Thus, it was hypothesized that it might affect the prognosis in a long term, which needs further investigation in the future.

The present study also had some limitations. One concern about the findings is that the sample size was too small. In addition, the data were collected from one single center instead of multicenter.

In conclusion, skin stretching and secure wound closure was effectively achieved by the TRS with primary closure. TRS significantly improved clinical outcomes and the quality of life for patients with breast cancer, as well as suppressing postoperative inflammation and infections. TRS might be a novel potential skin-stretching device for mastectomy.

Acknowledgements

Not applicable.

Funding

No funding was received.

Availability of data and material

The datasets used and/or analyzed during the current study are available from the corresponding author on reasonable request.

Authors' contributions

MY and HF conducted most of the experiments and HF wrote the manuscript; HJ and ZZ conducted the experiments and YZ analyzed the data, MY designed the study and revised the manuscript. MY and HF confirm the authenticity of all the raw data. All authors read and approved the final manuscript.

Ethics approval and consent to participate

The present study was approved by the Ethics Committee of Renmin Hospital of Wuhan University (approval number WHRMH-214-019A).

Patient consent for publication

Not applicable.

Competing interests

The authors declare that they have no competing interests.

References

1. DeSantis CE, Bray F, Ferlay J, Lortet-Tieulent J, Anderson BO and Jemal A: International variation in female breast cancer incidence and mortality rates. Cancer Epidemiol Biomarkers Prev 24: 1495-1506, 2015.
2. Ghoncheh M, Pournamdar Z and Salehiniya H: Incidence and mortality and epidemiology of breast cancer in the world. Asian Pac J Cancer Prev 17 (S3): S43-S46, 2016.
3. Bleyer A, Baines C and Miller AB: Impact of screening mammography on breast cancer mortality. Int J Cancer 138: 2003-2012, 2016.
4. He ZY, Tong Q, Wu SG, Li FY, Lin HX and Guan XX: A comparison of quality of life and satisfaction of women with early-stage breast cancer treated with breast conserving therapy vs. mastectomy in southern China. Support Care Cancer 20: 2441-2449, 2012.
5. Jagsi R, Jiang J, Momoh AO, Alderman A, Giordano SH, Buchholz TA, Pierce LJ, Kronowitz SJ and Smith BD: Complications after mastectomy and immediate breast reconstruction for breast cancer: A claims-based analysis. Ann Surg 263: 219-227, 2016.
6. Olshinka A, Ad-El D, Kalish E, Shay T and Yaacobi DS: Closure of challenging pediatric scalp wounds by a tension-relief system. J Craniofac Surg 32: e650-e652, 2021.
7. Topaz M, Carmel NN, Topaz G and Zilinsky I: A substitute for skin grafts, flaps, or internal tissue expanders in scalp defects following tumor ablative surgery. J Drugs Dermatol 13: 48-55, 2014.
8. Edge SB and Compton CC: The American joint committee on cancer: The 7th edition of the AJCC cancer staging manual and the future of TNM. Ann Surg Oncol 17: 1471-1474, 2010.
9. Topaz M, Carmel NN, Silberman A, Li MS and Li YZ: The TopClosure® 3S system, for skin stretching and a secure wound closure. Eur J Plast Surg 35: 533-543, 2012.
10. Zhao H, Wu Y, Tao Y, Zhou C, De Vrieze T, Li X and Chen L: Psychometric validation of the Chinese version of the lymphedema functioning, disability, and health questionnaire for upper limb lymphedema in patients with breast cancer-related lymphedema. Cancer Nurs 45: 70-82, 2022.
11. Finlay V, Burrows S, Burmaz M, Yawary H, Lee J, Edgar DW and Wood FM: Increased burn healing time is associated with higher Vancouver scar scale score. Scars Burn Heal 3: 2059513117696324, 2017.
12. Lins-Kusterer L, Valdelamar J, Aguiar CVN, Menezes MS, Netto EM and Brites C: Validity and reliability of the 36-item short form health survey questionnaire version 2 among people living with HIV in Brazil. Braz J Infect Dis 23: 313-321, 2019.
13. Zhou DX and Duan GX: Causes of skin flap necrosis after breast cancer surgery and preventive measures. Chin J Gen Pract 9: 1718-1719, 2011 (In Chinese).
14. Reintgen C, Leavitt A, Pace E, Molas-Pierson J and Mast BA: Risk factor analysis for mastectomy skin flap necrosis: Implications for intraoperative vascular analysis. Ann Plast Surg 76 (Suppl 4): S336-S339, 2016.
15. Larson DL, Basir Z and Bruce T: Is oncologic safety compatible with a predictably viable mastectomy skin flap? Plast Reconstr Surg 127: 27-33, 2011.
16. Santiago GF, Bograd B, Basile PL, Howard RT, Fleming M and Valerio IL: Soft tissue injury management with a continuous external tissue expander. Ann Plast Surg 69: 418-421, 2012.
17. Laurence VG, Martin JB and Wirth GA: External tissue expanders as adjunct therapy in closing difficult wounds. J Plast Reconstr Aesthet Surg 65: e297-e299, 2012.
18. Senchenkov A: The use of continuous external tissue expander for direct closure of anterolateral thigh free flap donor sites. J Plast Reconstr Aesthet Surg 67: 1766-1767, 2014.
19. Shyu KG, Chang ML, Wang BW, Kuan P and Chang H: Cyclical mechanical stretching increases the expression of vascular endothelial growth factor in rat vascular smooth muscle cells. J Formos Med Assoc 100: 741-747, 2001.
20. Chang H, Shyu KG, Wang BW and Kuan P: Regulation of hypoxia-inducible factor-1alpha by cyclical mechanical stretch in rat vascular smooth muscle cells. Clin Sci (Lond) 105: 447-456, 2003.
21. Komorowski AL, Zanini V, Regolo L, Carolei A, Wysocki WM and Costa A: Necrotic complications after nipple- and areola-sparing mastectomy. World J Surg 30: 1410-1413, 2006.
22. Topaz M, Carmel NN, Topaz G, Li M and Li YZ: Stress-relaxation and tension relief system for immediate primary closure of large and huge soft tissue defects: An old-new concept: New concept for direct closure of large defects. Medicine (Baltimore) 93: e234, 2014.
23. Zhu Z, Tong Y, Wu T, Zhao Y, Yu M and Topaz M: TopClosure® tension-relief system for immediate primary abdominal defect repair in an adult patient with bladder exstrophy. J Int Med Res 48: 300060519891266, 2020.
24. Zhu Z, Yang X, Zhao Y, Fan H, Yu M and Topaz M: Early surgical management of large scalp infantile hemangioma using the TopClosure® tension-relief system. Medicine (Baltimore) 94: e2128, 2015.
25. Zhu Z, Zhao Y, Yu M and Topaz M: A skin stretch system for the immediately closing of the large skin defects of the anterior chest wall following large keloid excision. Eur J Plast Surg 41: 609-612, 2018.
26. Ashkenazi I, Olsha O and Topaz M: Relaxation systems of the skin for the closure of large mammary defects. Cir Esp (Engl Ed) 98: 154-157, 2020 (In English, Spanish).
27. Choke A, Goh TL, Kang GC and Tan BK: Delayed primary closure of extensive wounds using the TopClosure system and topical negative pressure therapy. J Plast Reconstr Aesthet Surg 70: 968-970, 2017.
28. Lee SK, Choi MY, Bae SY, Lee JH, Lee HC, Kil WH, Lee JE, Kim SW and Nam SJ: Immediate postoperative inflammation is an important prognostic factor in breast cancer. Oncology 88: 337-344, 2015.