Late-onset white cord syndrome following anterior cervical discectomy and fusion: A case report

CHANG-ZHEN LEI[1], DAO-JUN GONG[1] and YANG-FAN ZHOU[2]

[1]Department of Surgery, Jinhua Hospital of Zhejiang University; [2]Department of Orthopedics, Pan'an County Hospital of Traditional Chinese Medicine, Jinhua, Zhejiang 321000, P.R. China

Received June 27, 2022; Accepted November 21, 2022

DOI: 10.3892/etm.2022.11770

Abstract. White cord syndrome refers to an emerging neurological dysfunction occurring after spinal decompression surgery with hyperenhancing changes on T2-weighted magnetic resonance imaging (T2WI). The pathophysiological mechanism is hypothesized to be an ischemia-reperfusion injury following chronic ischemic spinal cord decompression. A 54-year-old man was admitted to Jinhua Municipal Central Hospital with complaints of numbness and weakness in the extremities and swelling in the neck. MRI showed degeneration and herniation of the C4-C7 intervertebral discs. The patient underwent anterior cervical corpectomy and fusion (ACCF). On the 7th postoperative day, the patient reappeared with weakness of the limbs. Physical examination revealed paralysis. Emergency MRI suggested T2 high signal myelopathy and emergency surgery was performed following the diagnosis of white cord syndrome. Following the operation, the patient's neurological system gradually improved. The motor ability and sensory function of the extremities recovered at 7-month follow-up. Spine surgeons should be aware of this serious complication. The present case serves to provide experience for clinical treatment and diagnosis and encourage research into its pathophysiology.

Introduction

Cervical spondylotic myelopathy (CSM) is primarily caused by chronic compression or insufficient blood supply to the cervical spinal cord due to cervical disc herniation, spinal stenosis or instability (1). Clinical manifestations include sensory, motor, reflex and defecation dysfunction of the spinal nerves. If the disease is allowed to progress, it may cause complications such as paralysis and death (2,3). To the best of our knowledge, there is currently no evidence that indicates the optimal treatment for patients with CSM and decompression surgery remains the most effective long-term treatment for this disease (3). Anterior cervical corpectomy and fusion (ACCF) is a commonly used surgical method for CSM with good clinical results (1). Neurological deficits leading to paralysis or paraplegia are rare; however, there remains a serious potential postoperative complication. White cord syndrome (WCS) is hypothesized to be a reperfusion injury following sudden decompression of compressed spinal cord segments. The blood supply to the affected area is notably increased, which leads to direct blood trauma or subsequent injury caused by oxygen free radicals (4,5). Postoperative MRI shows typical sagittal T2-weighted magnetic resonance imaging (T2WI) intramedullary high signal changes (6). It is a rare cause of acute onset severe neurological deficit following cervical decompression. However, WCS is a diagnosis of exclusion. Medically induced technical trauma, postoperative hematoma, implant misalignment or dislocation need to be excluded before WCS diagnosis (6).

Case presentation

A 54-year-old man was admitted to Jinhua Municipal Central Hospital (Jinhua, China) in March 2021 with complaints of numbness and weakness in limbs and swelling in the neck. His myelopathic neurological examinations were negative. Physical examination determined that the strength in his limbs was normal. The preoperative cervical MRI scan showed degeneration and herniation of the C4-C7 discs (Fig. 1). He was diagnosed with CSM. Following routine preoperative preparation, ACCF C4-C7 surgery was performed. The cord was decompressed by removing the C4-7 disc material. The interbody cages were inserted into the C4-7 disc space and the plate was fixed on the C4-7 body anterior surface. X-ray imaging displayed satisfactory positioning of the pedicle screws. Following surgery, the patient's motor and sensory impairments gradually improved. However, on the 7th postoperative day, the patient was unable to move his legs and arms. Physical examination revealed upper limb strength of 3/5 and leg strength of 3/5 according to the Medical Research Council scale (7). Emergency MRI demonstrated T2 high intramedullary signal at C5-C6 level (Fig. 2). He was diagnosed with WCS and high dose methylprednisolone (80 mg, intravenously twice/day) combined with mannitol (250 ml, intravenously

Correspondence to: Professor Dao-Jun Gong, Department of Surgery, Jinhua Hospital of Zhejiang University, 351 Ming Yue Street, Jinhua, Zhejiang 321000, P.R. China
E-mail: gdj7104@163.com

Key words: white cord syndrome, cervical, anterior, paralysis

twice/day) and neurotrophic drug mecobalamin (0.5 mg, orally three times/day) were administered. However, symptoms did not improve and posterior cervical decompression surgery was performed 11 days after the initial ACCF operation. The second postoperative cervical MRI scan suggested that T2 high signal intensity had faded (Fig. 3). The patient recovered well postoperatively. On day 5 post-surgery, the patient was treated with hyperbaric oxygen therapy to decrease spinal cord edema and improve reperfusion injury (8). On the 10th day after the second surgery, the patient's muscle strength in the limbs recovered to grade 4/5 and the strength in the legs recovered to grade 5/5. The patient was discharged to an inpatient rehabilitation center. The patient's neurological function had not deteriorated at the 7-month postoperative follow-up.

Discussion

There are multiple reasons for paralysis following cervical spine surgery, including spinal cord compression due to poor implantation or hematoma formation, edema and ischemia-reperfusion injury (9). Preoperative MRI can clarify the site and type of cervical disc herniation and the extent of damage to the spinal cord and nerve roots. It provides a reference for the diagnosis, choice of treatment and prognosis of cervical spondylosis (10). Postoperative MRI can exclude WCS if it detects extramedullary hematoma, residual exogenous spinal cord compression, intraoperative spinal cord injury or postoperative graft displacement (6). WCS is a rare surgical complication that is characterized by spinal cord ischemic-reperfusion injury following anterior or posterior cervical decompression (5). It is characterized by an increased intramedullary cord signal on postoperative T2WI scan (9). In the chronically compressed ischemic spinal cord, the blood-spinal cord barrier is destroyed and exposed to a large blood supply following decompression surgery (11). This triggers an inflammatory cascade and the release of oxygen free radicals that leads to neuronal membrane damage (12). Surgical techniques and drug interventions, such as methylprednisolone, have been shown to decrease ischemic spinal cord injury (5). Potent antioxidants also serve a role in the treatment of spinal cord ischemia-reperfusion injury (13).

Chin *et al* (5) first proposed the concept of WCS in 2013 and highlighted the increased intramedullary signal in the postoperative T2WI scan. It was reported that a patient developed quadriplegia following C4-C6 anterior cervical discectomy and fusion surgery and was immediately given more extensive decompression and steroid therapy. The patient's condition partially improved. Subsequently, WCS received increasing attention. Vinodh *et al* (14) reported that a 51-year-old woman diagnosed with a metastatic intraspinal tumor developed WCS following posterior cervical laminectomy and tumor resection and fusion. Zhang *et al* (9) reported three cases of transient paralysis within 4 h after ACCF. All three patients received high-dose methylprednisolone treatment. Symptoms were resolved in two of the patients however, the third continued to show incomplete quadriplegia. The surgeon decided to perform C3-C6 laminoplasty to provide additional decompression. The second postoperative MRI showed a decrease in both the intrinsic cord edema and high

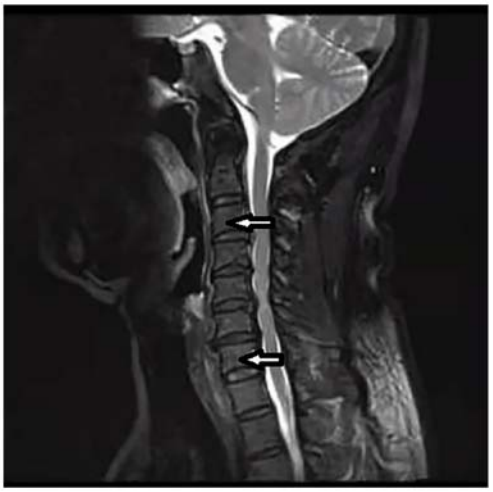

Figure 1. Preoperative MRI scans revealed that C4-C7 disc (white arrow) degeneration with herniation.

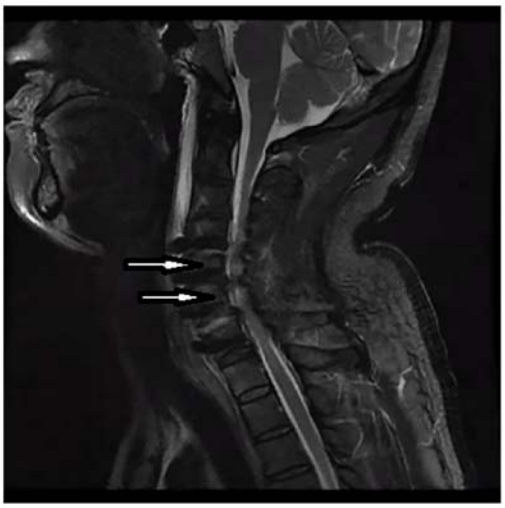

Figure 2. First post-operative, sagittal T2-weighted MRI scan demonstrated a signal of abnormally high intensity in the spinal cord at C5-C6 (white arrow) level.

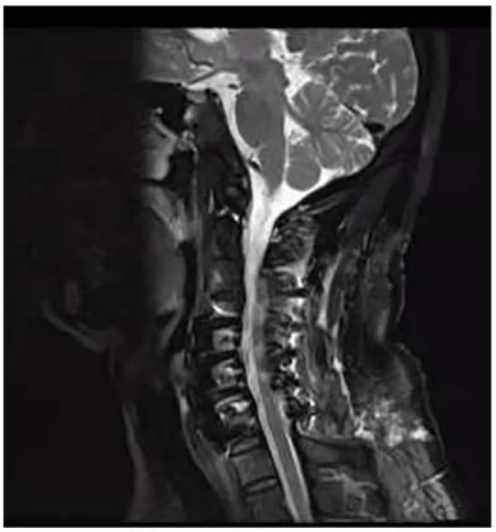

Figure 3. Second postoperative, MRI scans suggested that T2 high signal intensity had faded.

intramedullary cord signal. After one week, the patient's nerve function was fully restored. Sepulveda *et al* (15) reported the first case of WCS in a pediatric patient. A 12-year-old child underwent posterior cervical decompression surgery and fenestration of arachnoid cyst. On the 4th postoperative day, the patient developed monoplegia of the right arm and had a favorable clinical response to high-dose steroids. With rehabilitation treatment, the mobility of the right arm began to improve. More than ten cases have been reported in the literature and all cases of WCS were managed with high doses of steroids (4,5,9,11,12,14,15). In the present case report, high intramedullary signal was observed on postoperative sagittal T2WI scans, suggesting potential spinal cord edema. However, there is still debate regarding the clinical relevance of high signal intensity on T2WI (10). Localized spinal cord edema, nerve cell demyelination and cystic degeneration of the spinal cord may contribute to high signal intensity on T2WI. In previous case reports, the neurological deficit occurred intraoperatively or 24 h postoperatively, whereas in the present case the deficit first manifested 7 days postoperatively. It was hypothesized that this late-onset of WCS was caused by subacute reperfusion due to endothelial injury and atherosclerosis.

Although the incidence of WCS is low, clinicians should be aware of this potentially harmful complication. Once paralysis occurs, early diagnosis and intervention are essential to restoring spinal function. High-dose methylprednisolone is the first step in intervention. Additional surgery is dependent on the efficacy of the drug. In addition, it is recommended that surgeons include this complication in written consent before spinal surgery.

The insufficient number of cases limits the identification of specific WCS risk factors. Further research is required to investigate the exact mechanism of WCS to establish timely treatment or prevention of this rare but destructive complication.

Acknowledgements

Not applicable.

Funding

No funding was received.

Availability of data and materials

All data generated and/or analyzed during the present study are included in this published article.

Authors' contributions

CZL designed the study, collected clinical data and drafted the manuscript. DJG and YFZ designed the study and critically revised the manuscript. CZL, YFZ and DJG confirm the authenticity of all the raw data. All authors have read and approved the final manuscript.

Ethics approval and consent to participate

The study was conducted according to the guidelines of the Declaration of Helsinki and approved by the Ethics Committee of Jinhua Municipal Central Hospital (approval no. 2021-213). Written informed consent was provided by the patient.

Patient consent for publication

Not applicable.

Competing interests

The authors declare that they have no competing interests.

References

1. Badhiwala JH, Ahuja CS, Akbar MA, Witiw CD, Nassiri F, Furlan JC, Curt A, Wilson JR and Fehlings MG: Degenerative cervical myelopathy-update and future directions. Nat Rev Neurol 16: 108-124, 2020.
2. Tetreault LA, Karadimas S, Wilson JR, Arnold PM, Kurpad S, Dettori JR and Fehlings MG: The natural history of degenerative cervical myelopathy and the rate of hospitalization following spinal cord injury: An updated systematic review. Global Spine J 7 (Suppl 3): 28S-34S, 2017.
3. Tu J, Vargas Castillo J, Das A and Diwan AD: Degenerative cervical myelopathy: Insights into its pathobiology and molecular mechanisms. J Clin Med 10: 1214, 2021.
4. Antwi P, Grant R, Kuzmik G and Abbed K: 'White cord syndrome' of acute hemiparesis after posterior cervical decompression and fusion for chronic cervical stenosis. World Neurosurg 113: 33-36, 2018.
5. Chin KR, Seale J and Cumming V: 'White cord syndrome' of acute tetraplegia after anterior cervical decompression and fusion for chronic spinal cord compression: A case report. Case Rep Orthop 2013: 697918, 2013.
6. Epstein NE: Reperfusion injury (RPI)/white cord syndrome (WCS) due to cervical spine surgery: A diagnosis of exclusion. Surg Neurol Int 11: 320, 2020.
7. Vanpee G, Hermans G, Segers J and Gosselink R. Assessment of limb muscle strength in critically ill patients: A systematic review. Crit Care Med 42: 701-711, 2014.
8. Brugniaux JV, Coombs GB, Barak OF, Dujic Z, Sekhon MS and Ainslie PN: Highs and lows of hyperoxia: Physiological, performance, and clinical aspects. Am J Physiol Regul Integr Comp Physiol 315: R1-R27, 2018.
9. Zhang JD, Xia Q, Ji N, Liu YC, Han Y and Ning SL: Transient paralysis shortly after anterior cervical corpectomy and fusion. Orthop Surg 5: 23-28, 2013.
10. Zileli M, Borkar SA, Sinha S, Reinas R, Alves ÓL, Kim SH, Pawar S, Murali B and Parthiban J: Cervical spondylotic myelopathy: Natural course and the value of diagnostic techniques-WFNS spine committee recommendations. Neurospine 16: 386-402, 2019.
11. Busack CD and Eagleton BE: White cord syndrome causing transient tetraplegia after posterior decompression and fusion. Ochsner J 20: 334-338, 2020.
12. Wiginton J IV, Brazdzionis J, Mohrdar C, Sweiss R and Lawandy S: Spinal cord reperfusion injury: Case report, review of the literature, and future treatment strategies. Cureus 11: e5279, 2019.
13. Shirley R, Ord ENJ and Work LM: Oxidative stress and the use of antioxidants in stroke. Antioxidants (Basel) 3: 472-501, 2014.
14. Vinodh VP, Rajapathy SK, Sellamuthu P and Kandasamy R: White cord syndrome: A devastating complication of spinal decompression surgery. Surg Neurol Int 9: 136, 2018.
15. Sepulveda F, Carballo L, Carnevale M and Yañez P: White cord syndrome in a pediatric patient: A case report and review. Radiol Case Rep 15: 2343-2347, 2020.