SPANDIDOS PUBLICATIONS

EXPERIMENTAL AND THERAPEUTIC MEDICINE 25: 73, 2023

Synchronous mucinous metaplasia and neoplasia of the female genital tract (SMMN-FGT): A case report and literature review

HONGLIANG XU[1], YONG CHEN[1], SHUGUANG ZHOU[2], CAIXIA ZHAO[1], QIN WANG[1], MAN TANG[1], WEIQIN ZHANG[1] and HEPING ZHANG[1]

Departments of [1]Pathology and [2]Gynecology, Anhui Province Maternity and Child Health Hospital, Anhui Medical University, Hefei, Anhui 230000, P.R. China

Received July 20, 2022; Accepted November 29, 2022

DOI: 10.3892/etm.2022.11772

Abstract. The present study reported a case of Synchronous Mucinous Metaplasia and Neoplasia of the Female Genital Tract (SMMN-FGT), which occurred in a 47-year-old woman. The patient complained of pelvic mass during a physical examination a month ago. Ultrasound examination found an anechoic spot in the left ovary and several anechoic spots were detected in the cervix. The patient underwent left adnexectomy and the left ovarian frozen section revealed a mucinous borderline tumor. Total abdominal hysterectomy and right salpingo-oophorectomy were subsequently performed. Microscopically, multifocal mucinous lesions were involved in the female genital tract, including bilateral ovarian mucinous borderline tumor, cervical and endometrial mucinous adenocarcinoma and the bilateral fallopian tube epithelium showed mucinous metaplasia. Immunohistochemistry revealed that the tumor cells of the ovary, cervix and endometrium expressed MUC6, exhibiting features of gastric-type differentiation. The Ki-67 proliferative index was ~10-70%. Cumulative evidence established SMMN-FGT as the final histopathological diagnosis with International Federation of Gynecology and Obstetrics stage I. Following surgery, the patient received a course of pelvic radiotherapy and survived for 16 months.

Introduction

Synchronous Mucinous Metaplasia and Neoplasia of the Female Genital Tract (SMMN-FGT) is a multifocal mucinous lesion that occurs simultaneously in the female genital tract and was first described by Mikami *et al* (1). SMMN-FGT rarely occurs; ~35 cases have been reported in the literature (1-11). SMMN-FGT demonstrates a spectrum of morphological features, ranging from metaplasia without nuclear or architectural abnormalities to invasive mucinous adenocarcinoma, including minimal deviation adenocarcinoma (MDA) of the cervix and usually with gastric differentiation. Whether the disease process is the multifocal independent occurrence or the widespread dispersal from a single lesion is still controversial. The present study reported the clinical data, histological morphology and immunohistochemistry of this case and is expected to provide a further reference for the clinicopathological characteristics of the disease and the basis for its diagnosis and treatment.

Case study

The patient was a 47-year-old married woman who complained of a pelvic mass during a physical examination a month ago (February, 2021). The preoperative transvaginal ultrasound displayed multiple inhomogeneous hypoechoic echoes without obvious blood flow signals in the uterine myometrium (the largest one on the right uterine wall, which occludes the right ovary; Fig. 1A and B). There was a 52x52x33 mm well-circumscribed anechoic spot in the left ovary without an obvious blood flow signal (Fig. 1C). Several anechoic spots were detected in the cervix, with a maximum diameter of 8 mm. The endometrium measured ~5 mm in thickness. Cervical liquid-based cytology (Thinprep cytologic test, TCT) was negative for intraepithelial lesions or malignant lesions and the high-risk HPV test was negative. The patient underwent left adnexectomy; a frozen section of the left ovarian revealed a mucinous borderline tumor. The patient underwent a rapid cytological examination of the peritoneal washing fluid and no tumor cells were found. Intraoperative examination of the appendix and other digestive tract organs showed no obvious abnormality. Total abdominal hysterectomy and bilateral salpingo-oophorectomy were subsequently performed.

Gross presentation. The removed bilateral ovaries were measured 50x45x25 mm (left) and 32x20x15 mm (right) (grossly view of the specimen) in size and were multicystic tumors without conspicuous papillae in the cyst wall. The uterus body measured ~100x45x25 mm in size. Multiple grey-white nodules were in the intramural and subserosa of the uterus with

Correspondence to: Dr Heping Zhang, Department of Pathology, Anhui Province Maternity and Child Health Hospital, 15 Yimin Street, Luyang, Hefei, Anhui 230000 P.R. China
E-mail: 6036195@qq.com

Key words: female genital tumors, adenocarcinoma, mucinous

a diameter of 2-48 mm. The thickness of the endometrium was 2-5 mm. The cervical canal was measured ~35 mm in length and 3 0 mm in diameter, with multiple cervical cystic lesions scattered in the endocervix. The bilateral fallopian tubes were grossly unremarkable.

Microscopic examination. Bilateral ovarian tumors have similar histological features and contain multiple cysts lined by gastric-type mucinous epithelium showing variable degrees of stratification, tufting and villous or slender filiform papillae. Tumor cells are generally low-grade nuclear atypia. Mitotic activity is predominantly present in crypts and less prominent on the luminal surface (Fig. 2A). The bilateral fallopian tube mucosal epithelium showed focal mucinous metaplasia (Fig. 2B).

The cervical lesion in the internal cervical canal displayed a well-differentiated mucinous adenocarcinoma with focal superficial invasion and is surrounded by lobular endocervical glandular hyperplasia (LEGH; Fig. 2C). The tumor was confined to the cervix without vascular invasion and did not invade beyond the lower uterus. The tumor cells with abundant clear pale eosinophilic cytoplasm and distinct cell borders. The cytoplasm contained neutral mucins, which stained pale pinkish-red. (Fig. 2D).

The mucinous endometrial tumor showed a nodular expansive growth pattern and invaded the superficial myometrium (3/15 mm) without vascular invasion (Fig. 2E). It had similar morphological features to the cervical tumor, such as abundant cytoplasm containing mucins and atypical mitoses were present but inconspicuous (Fig. 2F). The background endometrium displayed hyperplasia.

Immunohistochemical findings. Immunohistochemically, ovarian tumor cells expressed MUC6, CK7, PAX8 (Fig. 3A-C), a Ki-67 proliferation index of ~70% (Fig. 3D) and were negative for ER, PR, CDX-2, CK20 (data not shown). Cervical tumor cells expressed MUC6 (Fig. 3E), were negative for P16 and P53 (Fig. 3F and G) and had a Ki-67 proliferation index of ~50% (Fig. 3H). Endometrial tumor cells expressed MUC6 (Fig. 3I), were negative for ER, PR (Fig. 3J and K), P16 and P53 (data not shown) and the Ki-67 proliferation index was ~10% (Fig. 3L).

The patient underwent gastroscopy and colonoscopy following surgery and no gastrointestinal lesions were found. Combined with the clinical visualization, histological features and immunohistochemical results, the primary diagnosis was ascertained as SMMN-FGT by the International Federation of Gynecology and Obstetrics stage I (12), including mucinous borderline tumor (MBT) of the bilateral ovaries, gastric-type cervical adenocarcinoma (GCA), endometrial mucinous adenocarcinoma and fallopian tubes epithelium mucinous metaplasia. The secondary diagnosis was multiple uterine leiomyomas. The patient was been referred to a course of pelvic radiotherapy followed surgery. The follow-up showed that the patient was alive and disease-free at 16 months after surgery.

Discussion

Mucinous lesions that occur in two or more sites of the female genital tract simultaneously, including the cervix, endometrium, ovary, or fallopian tube, are rare. Occasionally, the involvement of the urethral orifice and peritoneum has also been reported (2). These rare mucinous lesions are termed SMMN-FGT. The distinguishing feature of SMMN-FGT is that all tumors co-occur and exhibit features of gastric-type differentiation, such as expression of MUC6 and/or HIK-1083. Most of the cervix lesions are GCA which is usually called MDA when it is extremely well-differentiated. The 5th WHO Classification of female genital tract tumors (13) classifies it as HPV-independent adenocarcinoma due to its different pathogenesis from traditional cervical adenocarcinoma. Some patients are also accompanied by Peutz-Jeghers syndrome (14). Molecular genetics may be related to the mutation of STK11 (15) and KRAS (16).

To the best of the authors' knowledge, ~35 cases of SMMN-FGT have been reported in the literature (Table I) (1-11). The age of the patients ranged from 33-83 years (mean, 51 years old). The clinical manifestations of SMMN-FGT are not exclusive. Most patients complained of irregular vaginal bleeding, vaginal discharge, or abdominal discomfort; some patients exhibit atypical glandular cells on cervical cytology. The patient in the present study was a middle-aged woman diagnosed with a pelvic mass by physical examination but without other symptoms. The negative cytology result may be that the materials could not be effectively collected because of the mucinous lesions confined to the internal cervical canal. In addition, in traditional cervical cancer screening (cervical cytology combined with HPV test) it is easy to miss the lesions because it is HPV-independent.

Among the described cases, 23 cases showed gastric-type cervical mucinous adenocarcinoma and three cases without cervical mucinous lesions. 15 cases of endometrial lesions manifested as mucinous adenocarcinoma, nine cases were mucinous metaplasia and eight showed occasional villoglandular growth associated with LEGH. A total of 12 cases of fallopian tube lesions were mucinous metaplasia, five cases were mucinous carcinomas and four cases were mucinous borderline tumors. A total of seven cases of the ovarian lesions were mucinous borderline tumors, eight were mucinous cystadenoma and three were ovarian mucinous carcinoma. Among the 35 cases, 21 cases involved three sites of the female genital tracts and 10 cases involved four sites. In the patient in the present study, mucinous lesions involved four sites of the genital tracts, including the cervix, endometrium, bilateral ovaries and fallopian tubes. The cervix and endometrium were gastric-type adenocarcinomas, bilateral ovaries were MBT and bilateral fallopian tube epithelium were mucinous metaplasia.

The primary differential diagnosis of SMMN-FGT is metastatic ovarian mucinous adenocarcinoma. Notably, Metastatic ovarian mucinous adenocarcinoma closely resembles primary or mucinous borderline tumors and requires close macroscopic and microscopic observations combined with clinical information for accurate identification. The features of metastatic ovarian mucinous adenocarcinoma from cervical cancer were described by Young and Scully (17) including i) The ovarian tumor may metastasize from cervical cancer if the ovarian and cervical cancer occur at a similar time; ii) tumors are usually present in bilateral ovaries, iii) tumor implants visible on the surface of the ovary, iv) cervical and ovarian tumors have similar histological features, v) Cervical tumor usually infiltrates deep myometrium, vi) cervical tumor widely

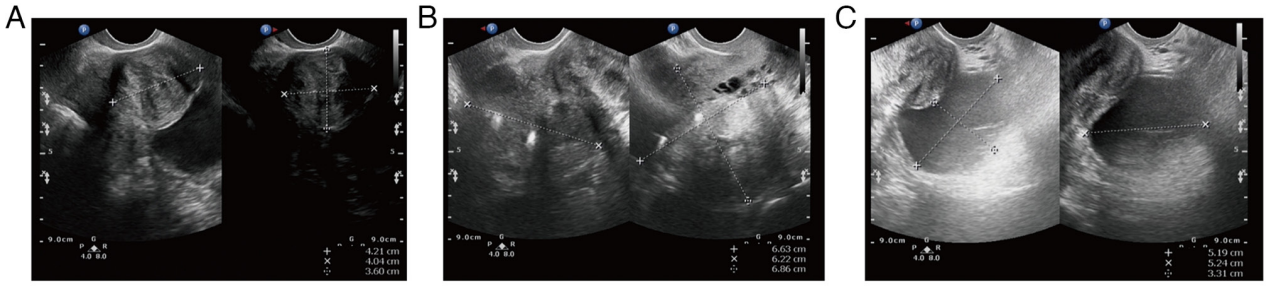

Figure 1. Ultrasound images. (A) Multiple inhomogeneous hypoechoic echoes without obvious blood flow signals between the uterine muscle. (B) The uterus was measured ~69x66x62 mm. (C) A 52x52x33 mm anechoic area is visible in the left ovary without an unmistakable blood flow signal.

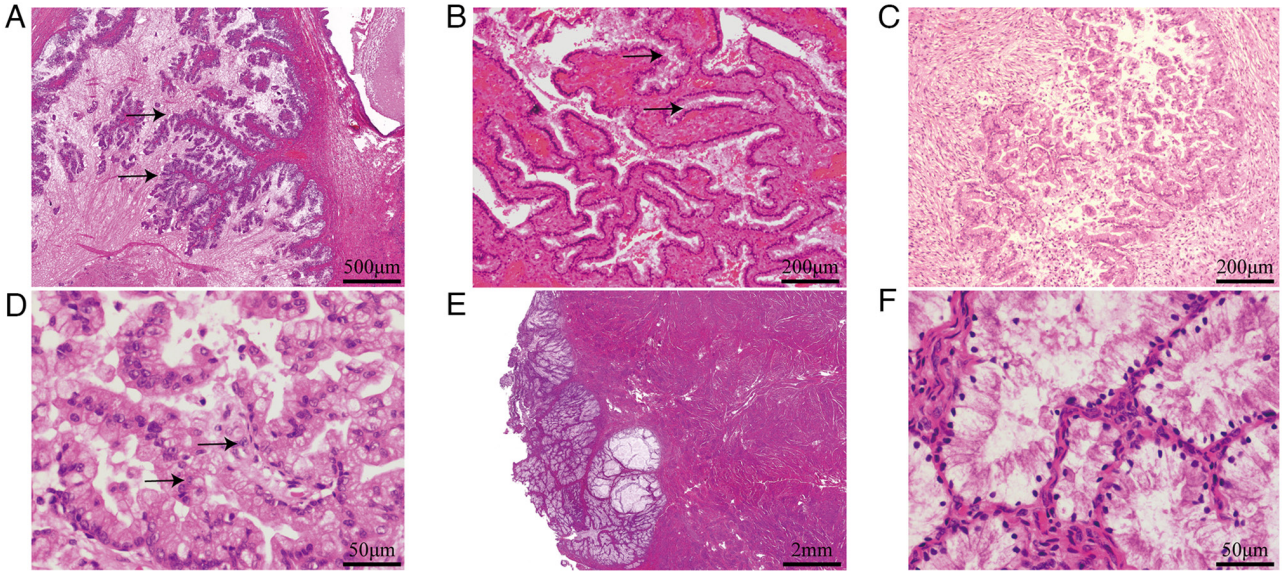

Figure 2. Histological features of tumors of each genital tract. (A) The ovarian tumor showed a mucinous tumor with abundant cytoplasm and pale-staining, focal papillary growth (black arrows) and mild nuclear atypia (magnification, x100). (B) Fallopian tubes showed focal mucinous metaplasia of the epithelium without atypia (black arrows; magnification: x100). (C) Cervical tumor was a well-differentiated mucinous tumor with superficial invasive growth (magnification, x100). (D) Cervical tumor cells are rich in mucus, with mild nuclear atypia and rare mitoses (black arrows; magnification, x400). (E) Endometrial mucinous neoplasm with nodular expansile infiltrative growth (magnification, x20). (F) Endometrial tumor cells with a small nucleus and gastric-type differentiation (magnification, x400). Hematoxylin and eosin staining.

spread, vii) tumor invades lymph nodes and blood vessels and viii) deficiency of mucous metaplasia of the fallopian tubes or endometrial lining. Moreover, well-differentiated mucinous adenocarcinoma of the digestive tract, such as well-differentiated mucinous adenocarcinoma of the gallbladder, metastases to the cervix and ovary, possesses similar morphological features to cervical MDA and ovarian mucinous cystadenoma. In the present case, the mucinous tumors existed on cervical, bilateral ovaries and endometrium with similar histological characteristics, but the lower uterine segment, ovarian surface and blood vessels were without tumor invasion, which demonstrated the ovarian tumor was not metastasized from the cervical tumor. Moreover, the endometrial and cervical tumors were limited to the superficial myometrium. Combined with the clinical features, imaging findings, histology and immunohistochemistry, the ovarian, endometrial and cervical tumor occurred simultaneously. Cumulative evidence established SMMN-FGT as the final histopathological diagnosis.

Treatment of SMMN-FGT is usually based on the stage of the co-existing adenocarcinoma. Total abdominal hysterectomy (TAO) and bilateral salpingo-oophorectomy (BSO) are sufficient for early staging. Most of the 22 reported cases were treated with TAO and BSO. Some patients received adjuvant radiotherapy and chemotherapy after surgery. The prognosis of patients is mainly related to the staging of the most severe lesions (1). One patient died 62 months after surgery because the lesions invaded the vaginal wall and reoccurred 9 months after surgery. The follow-up of other patients ranged from 2-102 months and they survived disease-free. In the present case, the patient underwent a rapid cytological examination of the peritoneal washing fluid during the operation and the results showed that no tumor cells were found. The appearance of the resected tumor was limited to the ovary and the surface of the ovary was smooth and no tumor was observed. Therefore, no omentectomy was performed during the clinical operation, but this may also be where treatment is inadequate. Finally, the patient underwent TAO, BSO and a course of radiotherapy following surgery. The patient was disease-free 16 months following the completion of the therapy.

Table I. Clinical and pathological features of 35 patients with SMMN-FGT.

Author, year	Case	Age	Symptoms	Cervix	Endometrium	Tube	Ovary	Remarks	FIGO	Treatment	Follow-up	(Refs.)
Giles *et al*, 1994	1	48	Irregular vaginal bleeding	Mucinous adenocarcinoma	Papillary mucinous adenocarcinoma	Mucinous carcinoma *in situ*	Invasive mucinous adenocarcinoma, mucinous cystadenoma	N/A	N/A	TAH + BSO + RT	Disease-free survival (9 months)	(8)
Jackson-York *et al*, 1992	2	48	Irregular vaginal bleeding	Papillary mucinous adenocarcinoma, AIS	Normal	Papillary mucinous carcinoma (left)	Metastatic adenocarcinoma (left)	N/A	N/A	TAH + BSO	N/A	(7)
Anjarwalla *et al*, 2007	3	65	Urinary incontinence 18 months	Cervical agenesis	Mucinous metaplasia	Pseudopyloric metaplasia	Atypical mucinous epithelium (left)	Entire genital epithelial surface replaced by müllerian epithelial	N/A	TAH + BSO	Disease-free survival (20 months)	(9)
Nagahama *et al*, 2013	4	52	Increased vaginal discharge	LEGH	Mucinous metaplasia	Normal	Normal	Peritoneal cytology revealed several mucin-containing epithelial clusters	N/A	TAH + BSO, paclitaxel-carboplatin 5 courses	N/A	(3)
Mangili *et al*, 2004	5	41	Left adnexal mass, abdominal pain	MDA	Simplex hyperplasia with a component of clear cell metaplasia	Mucinous metaplasia	MBT (left)	PJS	N/A	TAH + BSO	Disease-free survival (21 months)	(6)
Ikeda *et al*, 2015	6	73	AVD, lower abdominal pain	Mucinous adenocarcinoma	Mucinous adenocarcinoma	Normal	MBT	External urethral meatus neoplasm	N/A	TAH + BSO, partial omentectomy, appendectomy and mesenteric and external urethral meatus neoplasm resection, chemotherapy	Lung metastases were found after 6 months	(2)

Table I. Continued.

Author, year	Case	Age	Symptoms	Cervix	Endometrium	Tube	Ovary	Remarks	FIGO	Treatment	Follow-up	(Refs.)
Lu *et al*, 2019	7	57	AVD	GCA	Mucinous metaplasia	MBT (left)	Normal	HPV 16 positive	N/A	TAH + BSO	N/A	(4)
Xu *et al*, 2021	8	44	Abdominal mass	Gastric-type mucinous hyperplasia	Mucinous metaplasia	Normal	Mucinous cystadenoma	KRAS G13D mutation	N/A	TAH + right salpingo-oophorectomy	N/A	(10)
Gu *et al*, 2018	9	37-70 Average 54	AVD, abdominal mass	Gastric-type mucinous hyperplasia	LEGH	Mucinous metaplasia (right)	Mucinous cystadenom a (left)	N/A	N/A	TAH + BSO	Disease-free survival (2-34 months) without relapse	(5)
	10		AVD	AIS, LEGH, ALEGH	AIS, LEGH, ALEGH	Normal	Mucinous cystadenoma	N/A	N/A	TAH + BSO		
	11		AVD	GCA	Gastric-type adenocarcinoma, mucinous metaplasia, MDA	Mucinous metaplasia (right)	Normal	Normal	N/A	TAH + BSO + PEL, RT, chemotherapy		
	12		Abdominal mass	GCA, LEGH, ALEGH	LEGH, ALEGH	Mucinous metaplasia (left)	Mucinous cystadenoma	N/A	N/A	TAH + BSO, chemotherapy		
	13		AVD	GCA, MDA	Gastric-type adenocarcinoma, mucinous metaplasia, MDA	Mucinous metaplasia (right)	Normal	Tumor invades lymph nodes and blood vessels	N/A	TAH + BSO + PEL + PAN, RT, chemotherapy		
	14		AVD	GCA, MDA	Gastric-type adenocarcinoma, mucinous metaplasia, MDA	AIS (left)	Normal	Vagina invading	N/A	TAH + BSO + PEL, RT, chemotherapy		
	15		AVD	AIS, LEGH, ALEGH	AIS, LEGH, ALEGH	Mucinous cystadenoma (right)	Normal	N/A	N/A	TAH + BSO		

Table I. Continued.

Author, year	Case	Age	Symptoms	Cervix	Endometrium	Tube	Ovary	Remarks	FIGO	Treatment	Follow-up	(Refs.)
Mikami *et al*, 2009	16	47	AGC on Pap smears	MDA, AIS, LEGH	Mucinous adenocarcinoma, mucinous metaplasia	Mucinous cystadenoma	Normal	Peritoneal washing positive	IA	TAH + BSO	Disease-freel surviva (36 months)	(1)
	17	60	Abdominal pain	MDA, AIS, LEGH	Mucinous metaplasia, LEGH	MBT	MBT	N/A	IA	TAH + BSO	Disease-free survival (37 months)	
	18	65	AGC on Pap smears	MDA, AIS, LEGH	Mucinous metaplasia	Mucinous metaplasia	Normal	Peritoneal washing positive	IA	TAH + BSO, chemotherapy	Disease-free survival (102 months)	
	19	62	AGC on Pap smears	MDA, AIS, LEGH	Mucinous adenocarcinoma, mucinous metaplasia	MBT	Normal	Vagina invading	IIA	TAH + BSO + PEL + PAN, chemotherapy	Died after 62 months	
	20	39	AGC on Pap smears	AIS, LEGH	Mucinous adenocarcinoma, mucinous metaplasia	Normal	Normal	N/A	NA	TAH + BSO + PEL, chemotherapy	Disease-free survival (13 months)	
	21	83	Ovarian cyst	Normal	Mucinous metaplasia, LEGH	MBT	MBT	Peritoneal washing positive	IC	TAH + BSO	Disease-free survival (25 months)	
Chen *et al*, 2022	22	56	AVD	Cervicitis	ALEGH	Mucinous metaplasia (right)	Mucinous metaplasia (left)	N/A	N/A	TAH + BSO	Disease-free survival (80 months)	(11)
	23	37	AVD	ALEGH, GCA *in situ*	Mucious metaplasia	Gastric adenomatous metaplasia (left)	Mucinous cystadenoma	N/A	N/A	TAO + BSO	Disease-free survival (75 months)	
	24	41	AVD, Ovarian cyst	GCA	Gastric-type adenocarcinoma	Normal	Mucinous cystadenoma	N/A	N/A	TAO + BSO	Disease-free survival (64 months)	
	25	36	AGC on Pap smears	MDA	MDA	Mucinous carcinoma (right)	Mucinous carcinoma (right)	Vaginal wall (+), Parametrium (+)	N/A	RH + RSO + BPLND + OMT + AE	Disease-free survival (60 months)	
	26	49	Ovarian cyst	ALEGH, GCA	Gastric-type adenocarcinoma	Gastric-type adenocarcinoma (left)	MBT (left)	N/A	N/A	TAH + LSO	Disease-free survival (52 months)	

Table I. Continued.

Author, year	Case	Age	Symptoms	Cervix	Endometrium	Tube	Ovary	Remarks	FIGO	Treatment	Follow-up	(Refs.)
	27	54	AVD	GCA	Gastric-type adenocarcinoma	Mucinous metaplasia (Gastric type, right)	Brenner tumor (right)	N/A	N/A	TAH + BSO + EPH + BPLND + PALND	Died after 36 months	
	28	33	AVB	LEGH	Mucinous metaplasia, gastric-type	Mucinous metaplasia, gastric-type	Reserved, not checked	N/A	N/A	TAH + BS	Disease-free survival (43 months)	
	29	46	Ovarian cyst	ALEGH	ALEGH	Normal	Mucinous cystadenoma (right)	N/A	N/A	TAH + RSO	Disease-free survival (42 months)	
	30	46	AVD	MDA	MDA	Normal	MBT (left)	N/A	N/A	TAH + BSO	Disease-free survival (36 months)	
	31	39	AVD	LEGH	Mucinous metaplasia, Gastric-type	Normal	Reserved, not checked	N/A	N/A	TAH + BS + BBO	Disease-free survival (36 months)	
	32	51	Ovarian cyst	LEGH, ALEGH	LEGH	LEGH (right)	Mucinous cystadenoma (right)	N/A	N/A	TAH + RSO	Disease-free survival (33 months)	
	33	37	AVB	LEGH	LEGH	Normal	Reserved, not checked	N/A	N/A	TAH + BS	Disease-free survival (29 months)	
	34	52	AVD/AVB	GCA	Mucinous metaplasia	Mucinous metaplasia (left)	Normal	Vaginal wall (+)	N/A	RH + BSO + BPLND	Disease-free survival (14 months)	
Hongliang *et al*, 2022	35	47	Abdominal mass	GCA	Mucinous adenocarcinoma	Mucinous metaplasia	MBT	N/A	IA	TAH + BSO, RT	Disease-free survival (16 months)	Present case

AVD, abnormal vaginal drainage; AVB, abnormal vaginal bleeding; AGC, atypical glandular cell; GCA, gastric-type cervical adenocarcinoma; AIS, adenocarcinoma *in situ*; LEGH, lobular endocervical glandular hyperplasia; ALEGH, atypical lobular endocervical glandular hyperplasia; MDA, minimal deviation adenocarcinoma; MBT, mucinous borderline tumor; TAH, total abdominal hysterectomy; BSO, bilateral salpingo-oophorectomy; PEL, pelvic lymphadenectomy, PAN, para-aortic lymphadenectomy; RT, radiotherapy; RH, radical hysterectomy; RSO, right salpingo-oophorectomy; PALND, para-aortic lymph node dissection; OMT, omentectomy; AE, appendectomy; LSO, left salpingo-oophorectomy; EPH, extensive parametrial hysterectomy; BPLND, bilateral pelvic lymph node dissection; BS, bilateral salpingectomy; glands; BBO, biopsy of both ovaries; N/A, not available.

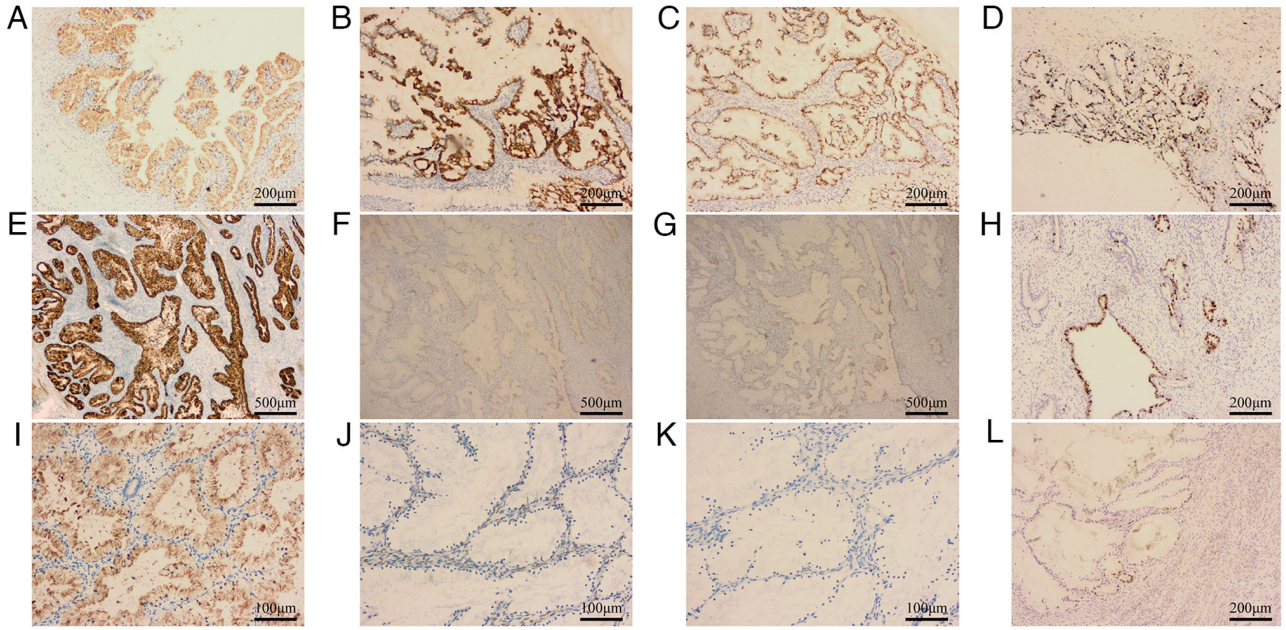

Figure 3. Immunoprofiling of tumor cells. Ovarian tumors positive for (A) MUC6, (B) CK7, (C) PAX-8, (D) Ki-67 proliferation index was ~70% (magnification, x100). Cervical tumors positive for (E) MUC6, (F) negative for P16 and (G) P53 (magnification, x40), (H) Ki-67 proliferation index was ~50% (magnification, x100). Endometrial tumors positive for (I) MUC6, negative for (J) ER and (K) PR (magnification, x200). (L) Ki-67 proliferation index was ~10% (magnification, x100).

The present study reported a case of SMMN-FGT that occurred in a 47-year-old woman, including the clinical symptoms, ultrasound display, gross appearance, microscopic examination and immunohistochemical findings. However, there are some limitations to the present study. First, the images of an MRI or CT scan on the pelvis before surgery were not taken as the preoperative clinical diagnosis was of a benign ovarian cyst. In addition, the tumors of the cervix and endometrium were inconspicuous, so the present study collected a large number of cervical and endometrial tissues for diagnosis, only to find superficial tumor lesions and that the gross specimen was damaged, so the present study lacked an image displaying the gross characteristics of this rare tumor.

The present study presented a case of SMMN-FGT, which existed in the cervix, endometrium and bilateral annex. Immunohistochemistry showed that the tumor cells were positive for gastric-type marker MUC6. Further studies are of great significance to characterize clinical features of this rare disease for differential diagnosis and effective therapy.

Acknowledgements

Not applicable.

Funding

The present study was supported by Anhui Medical University Funding Project (grant no. 2020xkj066).

Availability of data and materials

The datasets used and/or analyzed during the current study are available from the corresponding author on reasonable request.

Authors' contributions

HX contributed to the original conception of the study, data analyses and wrote the manuscript. YC acquired hematoxylin and eosin staining, immunohistochemical and ultrasound images. SZ performed the surgery and contributed to the acquisition of data. CZ and QW provided pathological diagnosis. MT performed tissue specimen collection. WZ prepared hematoxylin and eosin and immunohistochemical sections. HZ performed the analysis of the data and revised the manuscript. All authors read and approved the final manuscript. HX and YC confirmed the authenticity of all the raw data.

Ethics approval and consent to participate

Ethics approval was obtained from the Ethics Committee of Anhui Medical University (approval no. 81220058) and Anhui Province Maternity and Child Health Hospital (approval no. YYLL2022-2020xkj066-11-1.0).

Patient consent for publication

Written informed consent for publication was obtained from patient, including the patient's data and images.

Competing interests

The authors declare that they have no competing interests.

References

1. Mikami Y, Kiyokawa T, Sasajima Y, Teramoto N, Wakasa T, Wakasa K and Hata S: Reappraisal of synchronous and multifocal mucinous lesions of the female genital tract: A close association with gastric metaplasia. Histopathology 54: 184-191, 2009.

2. Ikeda Y, Yasuda M, Kato T, Yano Y, Kurosaki A and Hasegawa K: Synchronous mucinous metaplasia and neoplasia of the female genital tract with external urethral meatus neoplasm: A case report. Gynecol Oncol Rep 12: 27-30, 2015.
3. Nagahama K, Yamanaka S, Nakayama T, Tokinaga A, Asai-Sato M, Miyagi E, Tanaka R and Furuya M: A case of synchronous mucinous metaplasia and neoplasia of the female genital tract without an STK11 or KRAS mutation. Gynecol Oncol Case Rep 5: 4-5, 2013.
4. Lu J, Gao L, Yu H, Xia L, Guo X and Zheng F: A patient from Zhejiang, China, with synchronous mucinous metaplasia and neoplasms of the female genital tract: A case report. J Obstet Gynaecol Res 45: 1382-1385, 2019.
5. Gu WY, Tao X, Zhang LL, Wang L, Zhou XR and Ning Y: Synchronous mucinous metaplasia and neoplasia of the female genital tract. Zhonghua Bing Li Xue Za Zhi 47: 845-850, 2018 (In Chinese).
6. Mangili G, Taccagni G, Garavaglia E, Carnelli M and Montoli S: An unusual admixture of neoplastic and metaplastic lesions of the female genital tract in the Peutz-Jeghers Syndrome. Gynecol Oncol 92: 337-342, 2004.
7. Jackson-York GL and Ramzy I: Synchronous papillary mucinous adenocarcinoma of the endocervix and fallopian tubes. Int J Gynecol Pathol 11: 63-67, 1992.
8. Giles A, Yoon J and Lindley R: Multifocal mucinous neoplasia of the female genital system. Histopathology 25: 281-283, 1994.
9. Anjarwalla S, Rollason TP, Rooney N and Hirschowitz L: Atypical mucinous metaplasia and intraepithelial neoplasia of the female genital tract-a case report and review of the literature. Int J Gynecol Cancer 17: 1147-1150, 2007.
10. Xu ZY, Wu J, Song XX, Meng G and Gui ZH: A case of Synchronous Mucinous Metaplasia and Neoplasia of the Female Genital Tract with KRAS gene mutation. Chin J Clin and Experiment Pathol 37: 1147-1148, 2021 (In Chinese).
11. Chen M, Li J-J, Tao X, Zhu C-Q, Dong X-H, Yao L-Q and Li Q: Clinical analysis of 14 cases of synchronous mucinous metaplasia and neoplasia of the female genital tract. Fudan Univ J Med Sci 49: 402-410, 2022.
12. Bhatla N and Denny L: FIGO cancer report 2018. Int J Gynaecol Obstet 143 (Suppl 2): S2-S3, 2018.
13. Lokuhetty D, White VA and Watanabe R: Female genital Tumours. In: WHO Classification of Tumours. Vol 4. 5th Edition. Internal Agency for Research on Cancer (IARC), Lyon, 2020.
14. Banno K, Kisu I, Yanokura M, Masuda K, Ueki A, Kobayashi Y, Hirasawa A and Aoki D: Hereditary gynecological tumors associated with Peutz-Jeghers syndrome (Review). Oncol Lett 6: 1184-1188, 2013.
15. Kuragaki C, Enomoto T, Ueno Y, Sun H, Fujita M, Nakashima R, Ueda Y, Wada H, Murata Y, Toki T, *et al*: Mutations in the STK11 gene characterize minimal deviation adenocarcinoma of the uterine cervix. Lab Invest 83: 35-45, 2003.
16. Yoo SH, Park BH, Choi J, Yoo J, Lee SW, Kim YM and Kim KR: Papillary mucinous metaplasia of the endometrium as a possible precursor of endometrial mucinous adenocarcinoma. Mod Pathol 25: 1496-1507, 2012.
17. Young RH and Scully RE: Mucinous ovarian tumors associated with mucinous adenocarcinomas of the cervix. A clinicopathological analysis of 16 cases. Int J Gynecol Pathol 7: 99-111, 1988.