De novo 3q13.13q21.2 interstitial deletion and paternal 12p13.3 microdeletion in a fetus with dysplasia of the corpus callosum and ventriculomegaly: A case report

FRANCESCO LIBOTTE[1*], MARCO FABIANI[1*], KATIA MARGIOTTI[1], LORENA SONIA CARPINETO[1], FRANCESCA MONACO[1], RAFFAELLA RAFFIO[1], ALVARO MESORACA[1] and CLAUDIO GIORLANDINO[1,2]

[1]Human Genetics Laboratory; [2]Department of Prenatal Diagnosis, Fetal-Maternal Medical Centre, ALTAMEDICA, 00198 Rome, Italy

Received September 21, 2022; Accepted November 30, 2022

DOI: 10.3892/etm.2023.11799

Abstract. Chromosome 3q syndrome is a well-known genetic condition caused by interstitial deletion in the long arm of chromosome 3. The phenotype of this syndrome is variable and the great variability in the extent of these deletions leads to a wide spectrum of clinical manifestations. Terminal 12p deletion represents one of the rarest subtelomeric imbalances; patients with distal monosomy 12p present different phenotypes ranging from muscular hypotonia to autism spectrum disorders. The present study reported a prenatal diagnosis of a male fetus presenting ultrasound evidence of corpus callosum dysplasia and ventriculomegaly showing a 3q13q21.2 deletion and a 12p13.33 microdeletion paternally inherited. Among several features previously attributed to the terminal deletion of 3q, corpus callosum dysplasia and ventriculomegaly have rarely been reported together. As the 12p13.33 microdeletion in the father was associated only with muscular hypotonia and joint laxity, the involvement of terminal 12p deletions in the clinical features of the fetus was not possible to verify during the prenatal period. The present case report may provide a reference for prenatal diagnosis and genetic counseling in patients who present 3q13q21.2 deletions and 12p13.33 microdeletion.

Introduction

Concomitant presence of two simultaneous genomic losses is a rare event and in most such cases it is difficult to attribute the symptoms to one of the two affected genomic regions. 3q deletion syndrome is a genomic disorder characterized by a great variability of phenotypes associated to the extension of deletion. The clinical features of 3q deletion syndrome range from intellectual disability, motor developmental delay, congenital heart disease, renal and gastrointestinal malformations, autism, congenital hypothyroidism, epilepsy and brain anomalies (1,2). The corpus callosum is the primary commissural region of the brain consisting of white matter tracts connecting cerebral hemispheres. Its primary function is to integrate and transfer information from cerebral hemispheres to process sensory, motor, and high-level cognitive signals (3).

Agenesis or dysplasia of the corpus callosum is a brain malformation with variable clinical expression reported in many syndromes with predominantly genetic etiologies. Dysplasia and dysgenesis of the corpus callosum are nonspecific descriptions that imply defective development of the corpus callosum. The term dysplasia is applied when the morphology of the corpus callosum is altered as a congenital trait. For instance, the corpus callosum may be hump-shaped, kinked, or a striped corpus callosum that lacks an anatomically distinct genu and splenium (4,5). Agenesis of corpus callosum is characterized by a complete absence of corpus callosum. Agenesis and dysplasia of the corpus callosum have an incidence of 0.5 to 70 in 10,000 individuals, and their prevalence in children with developmental disabilities is about 230 in 10,000 (2.3%) (6). Corpus callosum defects are frequently associated with other fetal malformations, as ventriculomegaly often reported in fetuses with agenesis or dysplasia of the corpus callosum (7,8). Fetal ventriculomegaly, defined as dilation of the cerebral ventricles, is a common cerebral anomaly often detected with prenatal ultrasound scan with a prevalence of 0.3 to 1.5 per 1,000 live births (9). This condition is typically categorized as mild (10-12 mm), moderate (13-15 mm) or severe (>15) ventriculomegaly (10,11). Fetus with severe ventriculomegaly is known to have a poor prognosis in accordance with survival and neurodevelopment outcome. However, the prognosis for infants with mild-to-moderate ventriculomegaly is widely variable, which makes genetic counseling challenging in clinical practice (12). Terminal 12p deletion, instead, represents one of the rarest subtelomeric imbalances (13). Refereed

Correspondence to: Dr Katia Margiotti, Human Genetics Laboratory, ALTAMEDICA, 45 Viale Liegi, 00198 Rome, Italy
E-mail: katia.margiotti@artemisia.it

*Contributed equally

Key words: 3q13.13q21.2 deletion, 12p13.3 microdeletion, prenatal diagnosis, aCGH, karyotype, cytogenetic, ventriculomegaly, corpus callosum dysplasia, muscular hypotonia, 3q-syndrome

clinical features of constitutional deletions involving the terminal band of the short arm of chromosome 12 (12p13.3) depends on variation in deletion size, and can involves growth retardation, schizophrenia, microcephaly, dysmorphic facial features, muscular hypotonia, and other congenital abnormalities (13). In this case report we present a prenatal diagnosis of a fetus with novel interstitial deletion of 12.87 Mb at chromosome region 3q13q21.2 and paternal inherited microdeletion of 1.2 Mb at chromosome region 12p13.3 presenting a corpus callosum dysplasia and a mild ventriculomegaly at fetal ultrasound scan. This case report is expected to provide a further reference for clinicians to identify complex syndromes in prenatal period.

Case report

Patient. A 35-years-old pregnant woman secundigravida, without a remarkable family history, come in our medical center with a suspicion of a corpus callosum defect after a first ultrasound scan at 22 weeks. Then, we performed a second ultrasound scan confirming the presence of dysplasia of corpus callosum (Fig. 1A and B) and a mild unilateral ventriculomegaly (Fig. 1C). Afterwards the woman underwent amniocentesis at 23 weeks of gestation to investigate the presence of chromosomal abnormalities. Corpus callosum dysplasia was diagnosed visualizing the morphology and dimension of corpus callosum by a trans-abdominal ultrasound scan. The corpus callosum appears subtle and thin, in particular the body and the splenium were not present, whereas the genu was present but appears thin. The prenatal ultrasound showed a normal femur length of 39 mm and normal length (290 mm). Measurements of the biparietal diameter and head circumference were 62 and 239 mm, respectively. Moreover, the sagittal ultrasound view shows also a flat forehead with a flattened facial profile (Fig. 1D). Parents were both healthy and non-consanguineous, despite the father referred a mild muscle hypotonia, several episodes of shoulder and hip dislocations, and generalized joint laxity. After genetic counselling, considering the relevant ultrasound clinical features and the chromosomal aberrations, the couple decided to terminate the pregnancy without performing magnetic resonance imaging or neurosonography and it was not possible to perform the autopsy.

Methods. Amniotic fluid was collected at 23 weeks of gestation. Measurements of the biparietal diameter and head circumference were obtained from a transverse axial plane of the fetal head. The femur length was measured in a longitudinal scan. Cytogenetic analysis was performed on cultured amniocytes by G-banding according to standard procedures. At last, 16 metaphases were analyzed. Chromosome analysis of parental blood samples was performed using GTG-banding techniques on PHA-stimulated blood lymphocytes. Array comparative genomic hybridization (aCGH) analysis was performed on DNA from cultured amniocytes and DNA from parental blood to characterize the extent of deletion, using 44K platform (Agilent Technologies, Santa Clara, CA) as previously reported (8). Briefly 500 ng of the proband first and parents later with the relative sex-matched reference DNA were processed according to the manufacturer's protocol. Fluorescence was scanned in a dual-laser scanner (Innoscan 710, Agilent Technologies, Santa Clara, CA) and images were extracted and analyzed through Agilent Feature Extraction Software. The position of oligomers refers to the Human genome February 2009 (version GRCh37, hg19) assembly. For genes pLI (probability of loss intolerance) and %HI (haploinsufficiency rank) scores were retrieved from Decipher (https://www.deciphergenomics.org/). pLI score indicates the probability that a gene is intolerant to a Loss of Function (LoF) mutation. The higher the score, the more likely the gene is involved in a dominant disease, and the lower the pLI score, the more likely it is to indicate a recessive disease gene. Genes with high pLI scores (pLI≥0.9) are extremely LoF intolerant, whereby genes with low pLI scores (pLI≤0.1) are LoF tolerant. HI stays for Haploinsufficiency, wherein a single functional copy of a gene is insufficient to maintain normal function and is a major cause of dominant disease.

High ranks of %HI (e.g., 0-10%) indicate that a gene is more likely to exhibit haploinsufficiency, low ranks of %HI (e.g., 90-100%) suggest a gene is less likely to exhibit haploinsufficiency (14).

Findings. The result of fetal karyotype indicated a chromosomal structural anomaly. Specifically, a reduction in length of long arm of one chromosome 3 with an anomalous banding pattern involving bands q13.1 and q21 (Fig. 2). To investigate the breaking points of chromosomal deletion aCGH analysis was performed using a 44K array platform. The result confirmed a fetal 12.87 Mb deletion in chromosomal band 3q13q21 arr [hg19] 3q13.13q21.2 (111162064_124034052) (Fig. 3A), detecting a further microdeletion of 1.2 Mb in chromosomal band 12p13.33, arr [hg19] 12p13.33 (100698_1327097) x1 not visible with standard karyotype (Fig. 3B). To investigate the origin of deletions, aCGH was performed on both parents. The results showed a paternal inherited origin of 12p13.33 microdeletion. Investigation for aforementioned 12.87 Mb deletion of 3q chromosome by DECIPHER database reveals 81 OMIM genes (Table SI), among those genes the highest rank of %HI (0-10%) scores were reported for 6 genes: LSAMP, ZBTB20, GSK3B, NAA50, CASR, GTF2E1. Whereas, genes with highest pLI scores (pLI≥0.9) are reported for 12 genes: USF3, KALRN, ARHGAP31, STXBP5L, ADCY5, KPNA1, LSAMP, ZBTB20, CD86, GSK3B, CD200, NECTIN3. About 1.23 Mb deletion of 12p chromosome by DECIPHER database reveals 9 OMIM genes (Table SII), among those genes the high %HI (0-10%) score was reported for only ERC1 gene, whereas, genes with rank pLI>0.9 were reported for 2 genes: KDM5A and WNK1. Additional DECIPHER analysis for 12p13.3 microdeletion revealed a total of 78 patients showing a complete overlapping for several pathogenic or likely pathogenic deletions. Among the 78 patients, 12 of them reported muscular hypotonia (Fig. 4A), with 2 of them reporting joint laxity as well (Fig. 4B), interestingly similar clinical features were referred by the father of the fetus during the genetic counseling. Furthermore, among the 78 patients showing a complete overlapping deletion with our case, we also found a patient (ID 395656) with ventriculomegaly and none with dysplasia of the corpus callosum. Additional insights about patient ID 395656 showed that it carried a 12p deletion of 10 Mb, ten-fold bigger if compared with the deletion of our case covering 225 gene, some of them like CCND2, PHC1

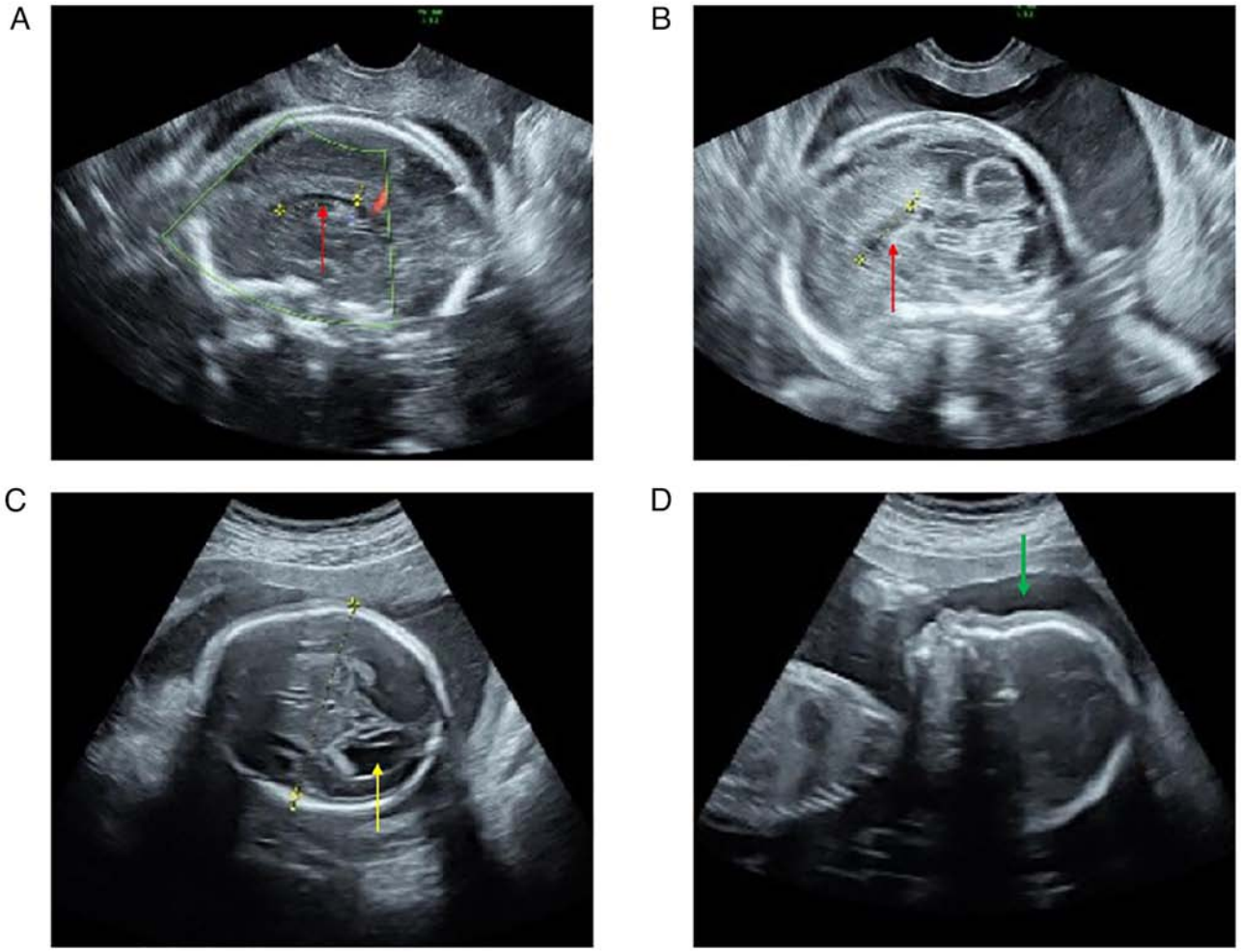

Figure 1. Ultrasound evidence of clinical features of fetus. (A) Red arrows show the corpus callosum dysplasia, which presents as thin. (B) Red arrows show the corpus callosum dysplasia, which is not clearly visible. (C) Axial view of fetal cerebral ventriculomegaly (yellow arrow). (D) Sagittal view of the fetal face shows a flat forehead and facial profile.

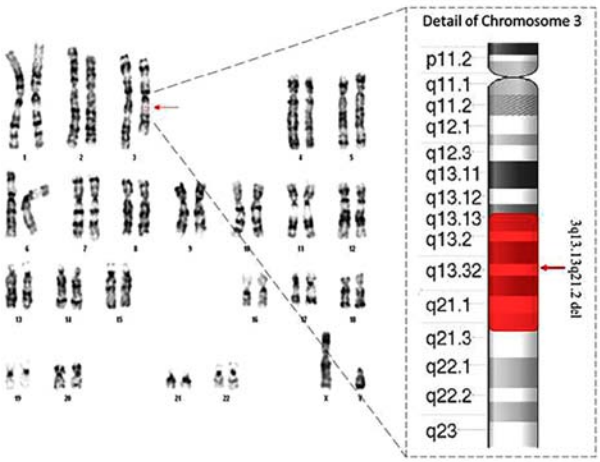

Figure 2. G-banded karyotype of fetus and relative ideogram showing the region of chromosome 3 harboring the 3q deletion.

and NTF3 gene, has been previously reported to be involved in brain formation (15-17). Since the involvement of a huge number of genes, many of them could most likely contribute to the ventriculomegaly phenotype of patient ID 395656. Moreover, we didn't find genes suggestive of any epigenetic effects in this region, nor imprinted genes has been reported on chromosome 12.

Discussion

The presented case is unique in harboring two specific deletions in 3q13.13q21.2 and 12p13.33. According to the literature search, there were no reports describing any case with interstitial deletion of the long arm of chromosome 3 and terminal microdeletion of the short arm of chromosome 12. Concomitant presences of two simultaneous genomic losses are rare and in most such cases it is difficult to attribute the symptoms to one of the two affected genomic regions, making genotype-phenotype correlation extremely difficult. Here, we report a prenatal diagnosis of a male fetus presenting ultrasounds evidence of corpus callosum dysplasia and ventriculomegaly showing a 3q13q21 deletion and 12p13.33 microdeletion. Litterature search for 3q13.13q21.2 deletion revealed previously described post natal cases showing several clinical phenotypes including skeletal malformations included scoliosis, lordosis, thoracic kyphosis, joint contractures, and peripheral malformations affecting the hands and feet, corpus callosum malformations,

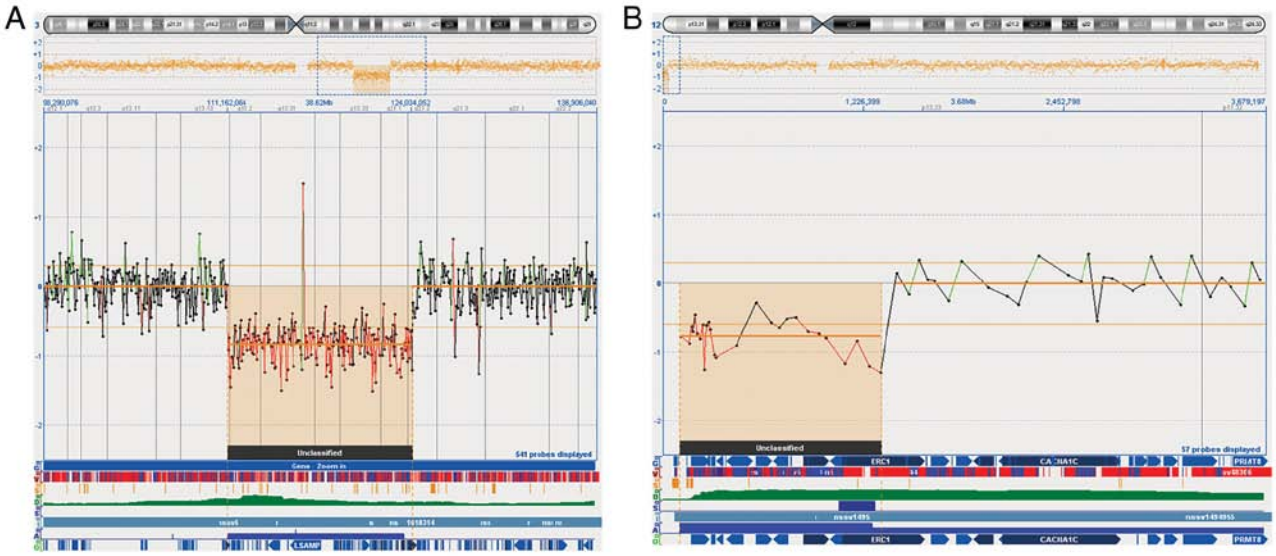

Figure 3. The scatter plot of the array comparative genomic hybridization of the fetus. (A) The deletion at the region 3q13.13q21.2 is estimated to be 12.87 Mb (from 111162064 to 124034052 kb) harboring 81 OMIM genes. (B) The deletion at the region 12p13.33 is estimated to be 1.23 Mb (from 100698 to 1327097 kb) harboring 16 OMIM genes. OMIM, Online Mendelian Inheritance in Man.

ventriculomegaly, alobar holoprosen-cephaly, skull malformations, autism, attention deficits and epilepsy (2). Molin *et al* (2), described an overlapping deletion of about 580 kb at 3q13.31 defined as shortest region of overlapping (SRO). Comparative phenotypic evaluation has showed that 5 patients among the 24 with SRO had agenesis of the corpus callosum and 3 patients presented ventriculomegaly, evoking the clinical features of the case presented in this study. This 580 kb segment includes four OMIM genes: DRD3, ZNF80, TIGIT, and ZBTB20. Among them, two genes, ZBTB20 and DRD3 were previsoly associated to brain development delay (2). ZBTB20 encodes a transcriptional repressor expressed in the cerebellum and corpus callosum (18) and it is a cell fate determinant for hippocampal neurons (19,20), whereas DRD3 encodes a dopamine receptor presents in the limbic system (21). Given their roles in neural development, haploinsufficiency of ZBTB20 and DRD3 genes may contribute to the corpus callosum and cerebellar malformations. However, as mentioned, proximal long arm of chromosome 3 is a gene dense region, hence, the involvement of a huge number of genes could most likely contribute to the complex phenotypic features of fetus development.

In this case we detected also a terminal 12p deletion reported as one of the rarest subtelomeric imbalance (13). Previous cases with terminal 12p deletion presented a phenotypic spectrum ranging from a normal development to development delay, facial dysmorphism and microcephaly (22,23). Comparative phenotypic evaluations of literature and databases has showed that most commonly reported clinical features are intellectual disability or development delay, microcephaly, muscular hypotonia, scoliosis and small for gestational age (24,25). Several genomic structural variations were detected in 12p13.3 region, not association with healthy individuals was found in literature for this 12p microdeletion (23). Searching for 12p13.3 microdeletion on DECIPHER database highlighted the presence of 3 genes wiht highest score for %HI (0-10%) and pLI (pLI≥0.9): KDM5A, WNK1, and ERC1 genes. KDM5A family have been strongly linked to a wide range of neurodevelopment disorders (26). ERC1 can potentially be accounted for the etiology of autism spectrum disorders (22,27,28). WNK kinases have a function in the nervous system, since whole genome exome sequencing identified variants in WNK1 in patients affected by Charcot-Marie-Tooth a form of autosomic recesive peripheral neuropathy (29). In 12p13.3 microdeletion of our case we detected a partial deletion (exons 1-11) of ERC1 gene sufficient to cause a non-production of ERC1 protein. Moreover, DECIPHER reaveled that among the 78 patients, showing an overalapping region, 12 of them reported muscular hypotonia (Fig. 4A), with 2 of these patients reported joint laxity (Fig. 4B), similar clinical features referred by the father of the fetus. Furthermore, among the 78 patients showing a complete overlapping deletion with our case, we found a patient with ventriculomegaly (ID 395656) and none with dysplasia of the corpus callosum. Despite all the mentioned literature regarding the 3q and 12p deletions we noticed that on NIH MedLine Plus website (https://medlineplus.gov/) does not report any information about the identified deletions. We recognize several limitations of the study. First of all, it was not possible to perform medical examination of the fetus after pregnancy termination. Moreover patients with abnormalities of the corpus callosum may have severe intellectual impairment such as cerebral palsy, hydrocephalus, spasticity, severe learning disabilities, autism or seizures, all features not verifiable in a prenatal period. Another limitation it was that the couple decided to terminate the pregnancy without performing magnetic resonance imaging or neurosonography, precluding a better clinical phenotype definition and the correlation with the detected chromosomal aberrations.

Although a phenotype-genotype association to specific genes is not possible, we have speculated a possible association considering the published literature referred to these chromosomal aberrations. Due to the complexity of involved chromosomal imbalances, specific 3q13.13q21.2 deletion might contribute to the corpus callosum and ventriculomegaly, while 12p13.33 deletion could lead to muscular hypotonia, and joint laxity observed

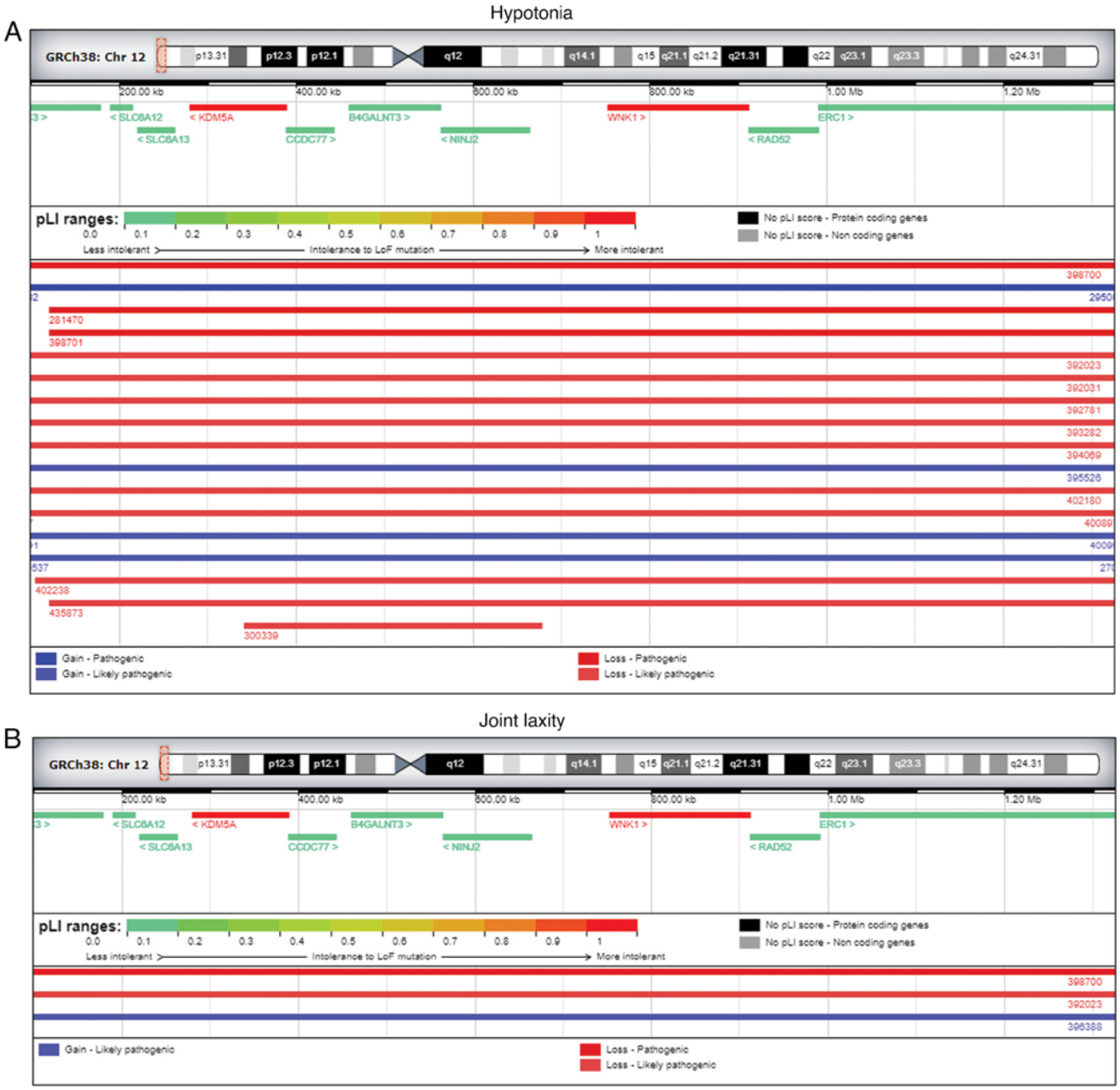

Figure 4. Coding genes and graphical representation of 12 chromosome region (12p13.33) involved in microdeletion. The deletion at 12p13.33 detected in our patient is represented by a red box on chromosome. 12p13.33 microdeletion in our patient overlapping pathogenic/likely pathogenic deletions (red bars) in other cases present in the Decipher database (https://decipher.sanger.ac.uk/) presenting (A) hypotonia or (B) joint laxity.

in the father of fetus. Remarkably this region contains ERC1 gene appearing as a strong candidate for the aforementioned clinical features, since it was previously reported to be associate with muscle organization (30), and DECIPHER analysis reveald ERC1 gene as the only gene in the 12p deleted region with %HI value under 10%, suggesting is strong haploinsufficiency status.

This case report is expected to provide a reference for clinicians facing with prenatal diagnosis and genetic counseling in pregnant women with diagnosis of 3q13q21.2 deletions or 12p13.33 microdeletion. Clinicians should consider 3q deletion syndrome when they are exploring a diagnosis of fetus with corpus callosum abnormalities or ventriculomegaly and the syndrome should be confirmed by cytogenetic karyotype together with aCHG analysis. Unfortunately, in prenatal period few data are collected regarding neurological development of the fetus and only pediatric neurologists can evaluate neurological features after birth.

An accurate characterization of the fetal chromosomal defects has implications in the couple decision regarding the continuing of the pregnancy or elective abortion and brings important information for the future reproductive options in order to give birth to a healthy baby.

Acknowledgements

Not applicable.

Funding

No funding was received.

Availability of data and materials

The datasets generated and/or analyzed during the current study are available in the ArrayExpress repository under the following accession number E-MTAB-12413 deposited at BioStudies platform (https://www.ebi.ac.uk/biostudies/arrayexpress/studies/E-MTAB-12413).

Authors' contributions

FL, KM, MF were involved in conceptualization and writing the original draft. LSC, RR and FM were involved in experiments. KM and MF performed data analysis. KM, MF and AM confirm the authenticity of all the raw data. AM and CG were involved in design, methodology and correction of the manuscript. All authors have read and approved the final manuscript.

Ethics approval and consent to participate

The present study was approved by the local ethical committee of Artemisia SPA (approval no. #2022-0054-001; June 01, 2022). The protocols used in this study adhere to the tenets of the Declaration of Helsinki.

Patient consent for publication

Written informed consent was obtained from subjects involved in the study.

Competing interests

All authors are full-time employees of Artemisia SPA. ALTAMEDICA is a branch of Artemisia SPA involved in Human Genetics and Fetal-Maternal Medical Sciences.

References

1. Ramieri V, Tarani L, Costantino F, Basile E, Liberati N, Rinna C, Cascone P and Colloridi F: Microdeletion 3q syndrome. J Craniofac Surg 22: 2124-2128, 2011.
2. Molin AM, Andrieux J, Koolen DA, Malan V, Carella M, Colleaux L, Cormier-Daire V, David A, de Leeuw N, Delobel B, *et al*: A novel microdeletion syndrome at 3q13.31 characterised by developmental delay, postnatal overgrowth, hypoplastic male genitals, and characteristic facial features. J Med Genet 49: 104-109, 2012.
3. Tanaka-Arakawa MM, Matsui M, Tanaka C, Uematsu A, Uda S, Miura K, Sakai T and Noguchi K: Developmental changes in the corpus callosum from infancy to early adulthood: A structural magnetic resonance imaging study. PLoS One 10: e0118760, 2015.
4. Hofman J, Hutny M, Sztuba K and Paprocka J: Corpus callosum agenesis: An insight into the etiology and spectrum of symptoms. Brain Sci 10: 625, 2020.
5. Hanna RM, Marsh SE, Swistun D, Al-Gazali L, Zaki MS, Abdel-Salam GM, Al-Tawari A, Bastaki L, Kayserili H, Rajab A, *et al*: Distinguishing 3 classes of corpus callosal abnormalities in consanguineous families. Neurology 76: 373-382, 2011.
6. Edwards TJ, Sherr EH, Barkovich AJ and Richards LJ: Clinical, genetic and imaging findings identify new causes for corpus callosum development syndromes. Brain 137: 1579-1613, 2014.
7. Raybaud C: The corpus callosum, the other great forebrain commissures, and the septum pellucidum: Anatomy, development, and malformation. Neuroradiology 52: 447-477, 2010.
8. Libotte F, Fabiani M, Margiotti K, Viola A, Mesoraca A and Giorlandino C: Prenatal diagnosis of combined maternal 4q interstitial deletion and paternal 15q microduplication. Genes (Basel) 12: 1626, 2021.
9. Pilu G and Hobbins JC: Sonography of fetal cerebrospinal anomalies. Prenat Diagn 22: 321-330, 2002.
10. Wang J, Zhang Z, Li Q, Zhu H, Lai Y, Luo W, Liu S, Wang H and Hu T: Prenatal diagnosis of chromosomal aberrations by chromosomal microarray analysis in foetuses with ventriculomegaly. Sci Rep 10: 20765, 2020.
11. Griffiths PD, Reeves MJ, Morris JE, Mason G, Russell SA, Paley MN and Whitby EH: A prospective study of fetuses with isolated ventriculomegaly investigated by antenatal sonography and in utero MR imaging. AJNR Am J Neuroradiol 31: 106-111, 2010.
12. Alluhaybi AA, Altuhaini K and Ahmad M: Fetal ventriculomegaly: A review of literature. Cureus 14: e22352, 2022.
13. Ravnan JB, Tepperberg JH, Papenhausen P, Lamb AN, Hedrick J, Eash D, Ledbetter DH and Martin CL: Subtelomere FISH analysis of 11 688 cases: An evaluation of the frequency and pattern of subtelomere rearrangements in individuals with developmental disabilities. J Med Genet 43: 478-489, 2006.
14. Firth HV, Richards SM, Bevan AP, Clayton S, Corpas M, Rajan D, Van Vooren S, Moreau Y, Pettett RM and Carter NP: DECIPHER: Database of chromosomal imbalance and phenotype in humans using ensembl resources. Am J Hum Genet 84: 524-533, 2009.
15. Mirzaa G, Parry DA, Fry AE, Giamanco KA, Schwartzentruber J, Vanstone M, Logan CV, Roberts N, Johnson CA, Singh S, et al: De novo CCND2 mutations leading to stabilization of cyclin D2 cause megalencephaly-polymicrogyria-polydactyly-hydrocephalus syndrome. Nat Genet 46: 510-515, 2014.
16. Ozcelik T, Rosenthal A and Francke U: Chromosomal mapping of brain-derived neurotrophic factor and neurotrophin-3 genes in man and mouse. Genomics 10: 569-575, 1991.
17. Awad S, Al-Dosari MS, Al-Yacoub N, Colak D, Salih MA, Alkuraya FS and Poizat C: Mutation in PHC1 implicates chromatin remodeling in primary microcephaly pathogenesis. Hum Mol Genet 22: 2200-2213, 2013.
18. Nagao M, Ogata T, Sawada Y and Gotoh Y: Zbtb20 promotes astrocytogenesis during neocortical development. Nat Commun 7: 11102, 2016.
19. Nielsen JV, Thomassen M, Mollgard K, Noraberg J and Jensen NA: Zbtb20 defines a hippocampal neuronal identity through direct repression of genes that control projection neuron development in the isocortex. Cereb Cortex 24: 1216-1229, 2014.
20. Xie Z, Ma X, Ji W, Zhou G, Lu Y, Xiang Z, Wang YX, Zhang L, Hu Y, Ding YQ and Zhang WJ: Zbtb20 is essential for the specification of CA1 field identity in the developing hippocampus. Proc Natl Acad Sci USA 107: 6510-6515, 2010.
21. Sokoloff P, Giros B, Martres MP, Bouthenet ML and Schwartz JC: Molecular cloning and characterization of a novel dopamine receptor (D3) as a target for neuroleptics. Nature 347: 146-151, 1990.
22. Leyser M, Dias BL, Coelho AL, Vasconcelos M and Nascimento OJ: 12p deletion spectrum syndrome: A new case report reinforces the evidence regarding the potential relationship to autism spectrum disorder and related developmental impairments. Mol Cytogenet 9: 75, 2016.
23. Fanizza I, Bertuzzo S, Beri S, Scalera E, Massagli A, Sali ME, Giorda R and Bonaglia MC: Genotype-phenotype relationship in a child with 2.3 Mb de novo interstitial 12p13.33-p13.32 deletion. Eur J Med Genet 57: 334-338, 2014.
24. Rincic M, Rados M, Kopic J, Krsnik Z and Liehr T: 7p21.3 together with a 12p13.32 deletion in a patient with microcephaly-does 12p13.32 locus possibly comprises a candidate gene region for microcephaly? Front Mol Neurosci 14: 613091, 2021.
25. Thevenon J, Callier P, Andrieux J, Delobel B, David A, Sukno S, Minot D, Mosca Anne L, Marle N, Sanlaville D, *et al*: 12p13.33 microdeletion including ELKS/ERC1, a new locus associated with childhood apraxia of speech. Eur J Hum Genet 21: 82-88, 2013.
26. El Hayek L, Tuncay IO, Nijem N, Russell J, Ludwig S, Kaur K, Li X, Anderton P, Tang M, Gerard A, *et al*: KDM5A mutations identified in autism spectrum disorder using forward genetics. Elife 9: e56883, 2020.
27. Silva IM, Rosenfeld J, Antoniuk SA, Raskin S and Sotomaior VS: A 1.5Mb terminal deletion of 12p associated with autism spectrum disorder. Gene 542: 83-86, 2014.

28. Han JY and Park J: Variable phenotypes of epilepsy, intellectual disability, and schizophrenia caused by 12p13.33-p13.32 terminal microdeletion in a korean family: A case report and literature review. Genes (Basel) 12: 1001, 2021.
29. Rodan AR and Jenny A: WNK kinases in development and disease. Curr Top Dev Biol 123: 1-47, 2017.
30. Luderman LN, Michaels MT, Levic DS and Knapik EW: Zebrafish Erc1b mediates motor innervation and organization of craniofacial muscles in control of jaw movement. Dev Dyn: Jun 16, 2022 (Epub Ahead of Print).

This work is licensed under a Creative Commons Attribution-NonCommercial-NoDerivatives 4.0 International (CC BY-NC-ND 4.0) License.