Vortex vein engorgement and different shapes of venous drainage systems in polypoid choroidal vasculopathy vs. age-related macular degeneration on indocyanine green angiography

CHEN-XI CAI, XIAO-MEI XIONG, TAO LI, BING-QIAN LIU, XIN-HUA HUANG, SHAN-SHAN YU, ZHEN-QIANG LIN, QIANG WANG, JIN-LI CUI, LIN LU and YING LIN

State Key Laboratory of Ophthalmology, Zhongshan Ophthalmic Centre, Sun Yat-sen University, Guangzhou, Guangdong 510060, P.R. China

Received August 29, 2022; Accepted February 2, 2023

DOI: 10.3892/etm.2023.11861

Abstract. There are differences in vortex vein engorgement and appearance in polypoid choroidal vasculopathy (PCV), age-related macular degeneration (AMD), and healthy eyes. The present study aimed to use indocyanine green angiography (ICGA) to find a simple, clinically meaningful method for evaluating the filling degree of vortex veins in various eye diseases. Participant clinical characteristics were recorded. The number of vortex veins (NVV), central vortex vein diameter (CVVD), mean root area of the vortex vein (MRAVV), mean diameter of the thickest peripheral branch (MDPTB), subfoveal choroidal thickness and percentage of vortex vein anastomosis (PVVA) were obtained by marking the vortex veins on ICGA. The proportion of subretinal haemorrhage and the numbers and types of vortex veins in each quadrant were counted separately. The CVVD and MDPTB were significantly increased in the PCV compared with those in the AMD group (P<0.05). The CVVD, MRAV, and PVVA were significantly increased in the PCV compared with those in the healthy group (P<0.05). The type IV vortex vein (complete with ampulla) proportion was the lowest while the type I (vortex vein absent) proportion was the highest in the PCV group (P<0.001). NVV in the inferior-temporal region was increased in the PCV compared with that in the AMD group (P=0.034). Subretinal haemorrhage occurred in the inferior temporal choroid in 47.62% of examined eyes in PCV group, and in the superior temporal choroid in 23.81% of the PCV group, with significant differences between the quadrants (P<0.001). Vortex vein engorgement and shape differed significantly between PCV, AMD and healthy eyes. The vortex vein branches in PCV eyes were significantly dilated in the posterior pole; moreover, the peripheral choroid and the lower proportion of type IV vortex veins may be pathognomonic for PCV.

Correspondence to: Professor Lin Lu or Professor Ying Lin, State Key Laboratory of Ophthalmology, Zhongshan Ophthalmic Centre, Sun Yat-sen University, 7 Jinsui Road, Tianhe, Guangzhou, Guangdong 510060, P.R. China
E-mail: liny83@sysu.edu.cn
E-mail: lulin@gzzoc.com

Abbreviations: AMD, age-related macular degeneration; CSC, central serous chorioretinopathy; CVD, choroidal vascular density; CVH, choroidal vascular hyperpermeability; DPTB, the diameter of the peripheral thickest branch; FFA, fundus fluorescein angiography; ICGA, indocyanine green angiography; NVV, number of vortex veins; OCT, optical coherence tomography; PCV, polypoid choroidal vasculopathy; PVVA, percentage of vortex vein anastomosis; MRAVV, mean root area of the vortex vein; SFCT, subfoveal choroidal thickness; VEGF, vascular endothelial growth factor

Key words: age-related macular degeneration, indocyanine green angiography, polypoid choroidal vasculopathy, venous drainage, vortex vein

Introduction

Owing to the high similarity in clinical manifestations and genetics between polypoid choroidal vasculopathy (PCV) and age-related macular degeneration (AMD), PCV was hypothesized to be an AMD subtype (1). However, unlike AMD, PCV is more common in people of colour and lesions occur outside the vascular arch or the nasal side of the optic disc, in addition to in the macula. AMD, on the other hand, is common in Caucasians, and the lesions are concentrated in the macula (2). The primary difference between the two diseases is response to intravitreal anti-vascular endothelial growth factor (anti-VEGF) drugs in patients with PCV patients is not as good as that in AMD patients (2-4). These findings suggest that the pathological mechanisms of PCV and AMD differ.

To improve the treatment efficacy for PCV and AMD, differences between the two diseases have been explored (2). The pathogenesis of both PCV and AMD is associated with choroidal vessels (2). A typical PCV subtype with choroidal thickness ≥257 μm has a significantly greater choroidal vascular area in the macular and foveal regions compared with that in typical AMD (5). The vortex vessels, located in the middle layer of the eyeball wall, drain the choroid. They are difficult to detect by direct observation but can be observed

more clearly with indocyanine green angiography (ICGA) than with other non-invasive techniques (6). However, research on vortex veins mostly transforms the ICGA image into binary image, and then manually segment the quadrants based on the position of the vortex vein to measure the brightness of each quadrant for research (7). The present study aimed to develop a method that is simpler and more suitable for clinical use and easier for evaluating vortex vein filling.

Moreover, the present study aimed to describe the differences in vortex vein engorgement and appearance between PCV, AMD and healthy people of the same age using ICGA to reveal differences in vortex vein anatomy between PCV and AMD.

Patients and methods

Patients. Patients orally agreed to the use of their data in the present study. Ethical approval for this retrospective study was obtained from the Institutional Review Board of the Zhongshan Ophthalmic Centre (approval no. 2022KYPJ173). In total, 180 participants(mean age, 64.12±8.87 years; range, 52-75 years) were recruited in this study, including 109 males and 71 females. All participants underwent ICGA (SPECTRALIS Diagnostic Imaging Platform; Heidelberg Engineering, Inc.) and optical coherence tomography (OCT) (SPECTRALIS® OCT; Heidelberg Engineering Inc.) between January 2018 and January 2022 at the Zhongshan Ophthalmic Centre, Guangzhou, China.

The present study included 63 patients with PCV, 50 with AMD and 67 healthy control group. Based on the results of fundus examination, OCT, fundus fluorescein angiography (FFA) and ICGA, age- and sex-matched patients were grouped based on diagnosis into PCV, AMD and healthy control group. Only one eye was included for patients diagnosed with bilateral PCV or AMD. In healthy participants, only the eye with the best-corrected visual acuity (>20/16) was included.

The following exclusion criteria were adopted: History of prior ocular surgery or trauma(excluded 15 PCV patients); severe vitreous haemorrhage that may affect imaging examination (excluded two PCV patients); any systemic disease that may affect blood flow, such as diabetes mellitus or hypertension (excluded one PCV patients and three AMD patients); central serous chorioretinopathy (CSC); primary glaucoma; optic neuritis; retinal vein occlusion; choroidal melanoma; retinal vasculitis; uveitis; an epiretinal membrane that may affect ocular circulation (excluded one PCV patients and five AMD patients) or moderate to high myopia (defined as a spherical equivalent refractive error in phakic eyes <-3.00 D) (excluded nine healthy participants).

We conducted another screening to exclude the cases who only received monocular ICGA and OCT examination and included 44 cases of unilateral PCV and 18 cases of unilateral AMD. The diseased eye was included in the PCV/AMD group, and the healthy fellow eye was included in the PCV/AMD fellow eye group.

Following intravenous injection of 5 ml 25 mg ICG (Dandong Yichuang Pharmaceutical Co., Ltd), ICGA images were recorded. Early-stage images (5 min after dye injection) were selected for analysis. The vortex veins were separated into four categories according to a previous method (8). The branches of type I vortex veins do not converge and pass directly through the sclera, whereas all branches of type IV (complete with ampulla) converge to form the ampulla, which is a complete vortex system. Type IV systems have a larger root area due to the dilated ampulla (8). The fundus was divided into four quadrants: Superior and inferior temporal and superior and inferior nasal. Patient characteristics, such as sex, age, number, location and type of vortex veins were recorded. The sketching tool of the retinal device was used to mark the root area and diameter of the thickest branch of each vortex vein (Fig. 1). The centre of a concentric circle was placed on the macula, the thickest vortex vein branch intersecting with the outermost circle was selected and its diameter was measured and stored as the central vortex vein diameter (CVVD). The ends of each vortex vein branch were connected with a smooth curve and the area enclosed by the curve was defined as the root area of the vortex vein (RAVV). The width of the thickest first-order branch of the vortex vein was defined as the diameter of the peripheral thickest branch (DPTB). The mean RAVV (MRAVV) and MDPTB were calculated. Vortex vein anastomosis was observed when vortex vein branches connected the two vortex vein systems on IGCA. The percentage of eyes with vortex vein anastomosis in each group was calculated and recorded as the percentage of vortex vein anastomosis (PVVA). Subfoveal choroidal thickness (SFCT) was measured using SPECTRALIS® OCT device. All labelling was performed separately by two experienced ophthalmologists (CXC and XMX) and the mean of the two measurements was used as the final data.

Statistical analysis. One-way ANOVA was used to compare differences in age, sex, number of vortex veins (NVV), CVVD, MRAVV, MDPTB, and SFCT between PCV, AMD and healthy controls, as well as to compare differences in the NVV between the four quadrants. When one-way ANOVA indicated a significant difference between PCV, AMD and healthy groups, the least-significant-difference test was used to perform pairwise comparisons. One-way ANOVA was used to compare PCV group differences in NVV, MRAVV, and MDPTB within each quadrant, followed by post hoc Tukey's test was used to perform pairwise comparisons. χ^2 test was used to compare the differences in the proportions of subretinal haemorrhages and four types of vortex veins in each quadrant of the PCV group and differences in the proportions of the four types of vortex veins and PVVA among the PCV, AMD and healthy controls. Paired t test was used to compare affected and healthy eyes in patients with PCV/AMD. Receiver operating characteristic (ROC) curve of the CVVD, MRAVV and MDPTB were drawn between polypoid choroidal vasculopathy and age-related macular degeneration group. Area under the curve (AUC) for CVVD distinguished between PCV and AMD. Data are presented as the mean ± standard deviation. We repeated the independent experiment twice. $P<0.05$ was considered to indicate a statistically significant difference. Statistical analysis was performed using SPSS for Windows (version 17.0; SPSS, Inc.).

Results

The present study included 180 participants, including 63 patients with PCV, 50 with AMD and 67 healthy

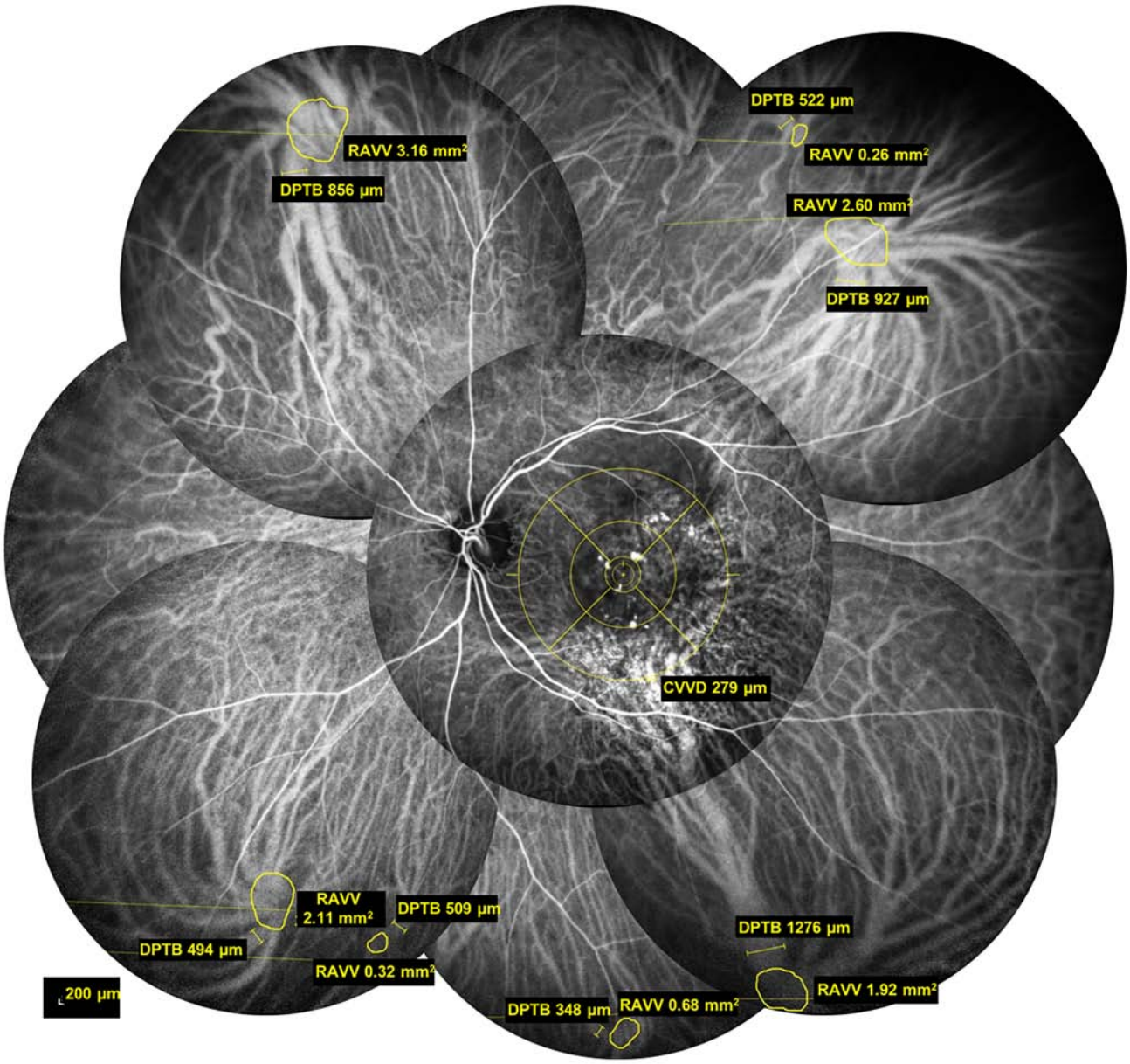

Figure 1. Indocyanine green angiography fundus image of a 66-year-old with polypoid choroidal vasculopathy. RAVV, CVVD and DPTB of the vortex veins are marked. RAVV, root area of the vortex vein; CVVD, central vortex vein diameter; DPTB, diameter of the peripheral thickest branch.

age-matched controls. There were no significant differences in sex or age between the three groups (P>0.05; data not shown). A total of 44 contralateral healthy eyes of patients with PCV were included in the PCV fellow eye group. A total of 18 contralateral healthy eyes of patients with AMD were included in the AMD fellow eye group.

Differences in NVV, CVVD, MRAVV, MDPTB, SFCT and PVVA were compared (Fig. 2). There were no significant differences in NVV and SFCT between the three groups (P>0.05; Fig. 2A and E). CVVD in the PCV group was significantly increased by 1.24-fold compared with that in the healthy control group and by 1.14-fold compared with that in the AMD group (P<0.05; Fig. 2B). MRAVV in the PCV group was significantly decreased compared with that in the healthy controls (P=0.004; Fig. 2C). MDPTB in the PCV group was significantly wider compared with that in the AMD group (P=0.013; Fig. 2D). PVVA in the PCV group was significantly increased compared with that in healthy controls (P=0.006; Fig. 2F).

PCV group showed the lowest proportion of type IV vortex veins (complete with ampulla), while the proportion of type I (absent) vortex veins was highest; this was significantly different between the PCV, AMD and healthy controls (P<0.001; Table I). NVV in the inferior temporal quadrant of the PCV group was increased compared with that in the AMD group (P=0.034) and NVV in the superior temporal and nasal and inferior nasal quadrants showed no significant differences between groups (P>0.05; Table II).

NVV, MRAVV and MDPTB of the PCV group were the largest in the inferior temporal region, with significant differences between quadrants (P<0.05; Fig. 3). The mean number of polyps in the PCV group was 3.37±3.47 (range, 0-15). In 15 eyes, polypoid lesions could not be observed due to severe subretinal haemorrhage on ICGA. Subretinal haemorrhage

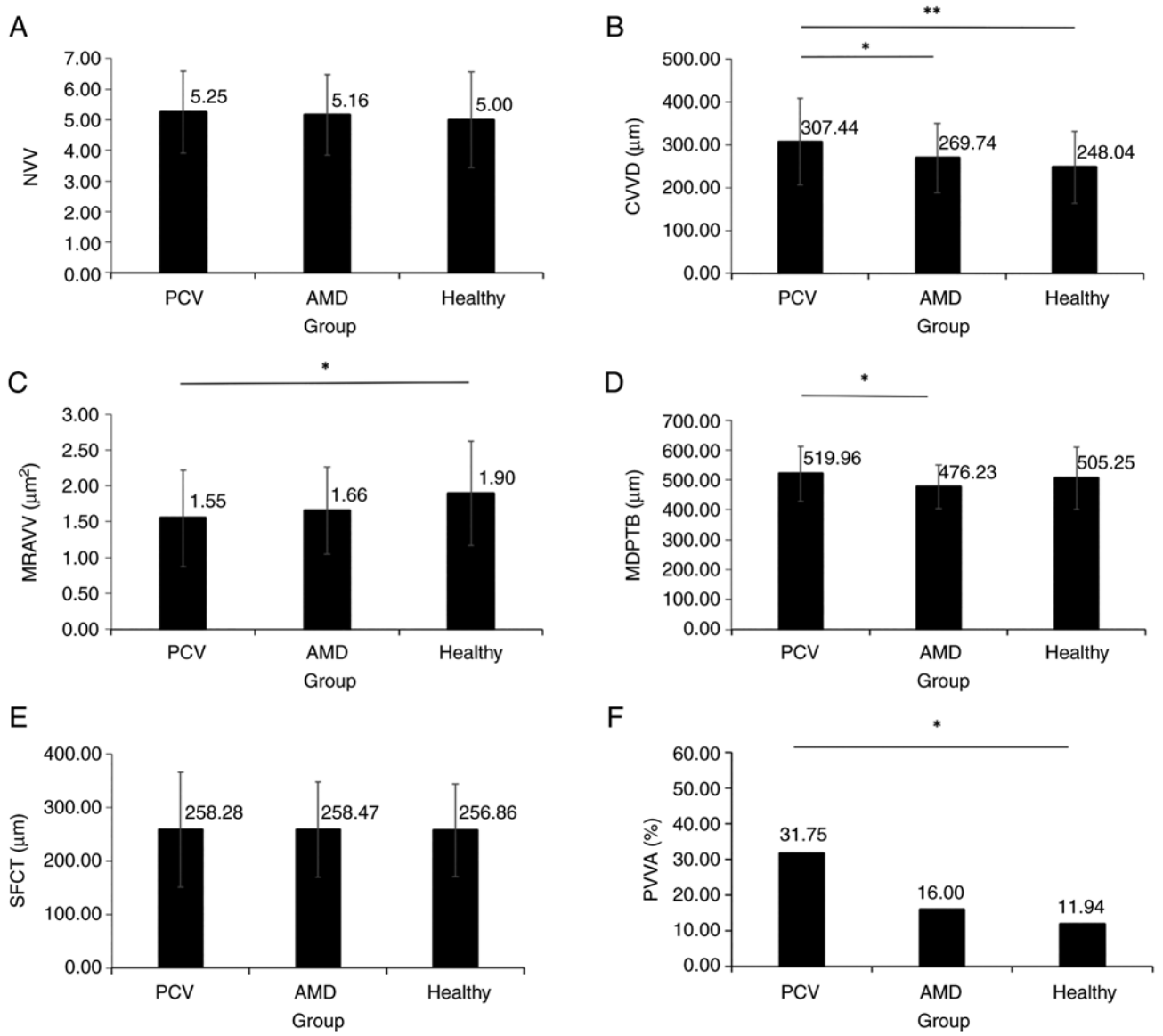

Figure 2. NVV, CVVD, MRAVV, MDPTB, SFCT and PVVA among PCV, AMD and healthy groups. (A) There were no significant differences in NVV between three groups. (B) CVVD of the PCV group is significantly wider than that of the AMD group and the healthy group. (C) MRAVV of the PCV group is significantly larger than that of the healthy group. (D) MDPTB of the PCV group is significantly wider than that of the AMD group. (E) There were no significant differences in SFCT between groups. (F) PVVA in the PCV group is significantly higher than that of the healthy group. NVV, number of vortex veins; CVVD, central vortex vein diameter; PCV, polypoid choroidal vasculopathy; AMD, age-related macular degeneration; MRAVV, mean root area of the vortex vein; MDPTB, mean diameter of the peripheral thickest branch; SFCT, subfoveal choroidal thickness; PVVA, percentage of the vortex vein anastomosis. (*P<0.05, **P<0.001).

was absent in 24 and present in 39 participants in the PCV group, all of which involved the posterior pole macular area. Subretinal haemorrhages involved both superior and inferior temporal regions in seven eyes, and the posterior pole and peripheral parts in two eyes. The proportion of type I vortex veins in the PCV group was significantly different between quadrants (P<0.001; Table III). Among the PCV participants, subretinal haemorrhage was observed in 47.62% of the inferior temporal and 23.81% in the superior temporal quadrants, with significant differences between the quadrants (P<0.001; Table III).

Considering that the area under the curve of CVVD was largest, with its' highest availability and clinical practicability, CVVD was selected as the indicator to reveal the difference between PCV and AMD. Cut-off value of CVVD is 252.5 μm and sensitivity, specificity and AUC of 88.3%, 54.0% and 0.70 respectively (Fig. S1). CVVD in the AMD group was significantly increased compared with that in the AMD fellow eye group (P=0.024; Table IV). Among the 18 participants with unilateral AMD, there were no significant differences in NVV, MRAVV, MDPTB, SFCT and PVVA between the affected and fellow eyes (P>0.05; Table IV). There were no significant differences in NVV, CVVD, MRAVV, MDPTB, SFCT and PVVA between the affected and fellow eyes in the PCV group (P>0.05; Table V).

Discussion

The present study aimed to identify differences in venous system drainage patterns between PCV, AMD and healthy

Table I. Distribution of vortex vein types in each group.

Characteristic	Group, n (%)			χ^2	P-value
	PCV, 63 (35.00)	AMD, 50 (27.78)	Healthy controls, 67 (37.22)		
Type I (vortex vein absent)	108 (25.96)	82 (15.05)	102 (14.43)	27.520	<0.001
Type II (incomplete)	115 (27.64)	177 (32.48)	194 (27.44)	4.380	0.112
Type III (complete)	110 (26.44)	165 (30.28)	201 (28.43)	1.706	0.426
Type IV (complete with ampulla)	83 (19.95)	121 (22.20)	210 (29.70)	16.319	<0.001
Total	416 (100.00)	545 (100.00)	707 (100.00)	-	-

PCV, polypoid choroidal vasculopathy; AMD, age-related macular degeneration.

Table II. Number of vortex veins in each quadrant.

Quadrant	Group, n (%)			F-value	P-value
	PCV, 63.00 (35.00)	AMD, 50.00 (27.78)	Healthy controls, 67.00 (37.22)		
Superior temporal	1.43±0.50	1.29±0.54	1.37±0.67	0.841	0.433
Inferior temporal	1.57±0.68	1.28±0.45	1.39±0.58	3.448	0.034
Superior nasal	1.31±0.50	1.36±0.63	1.21±0.54	1.062	0.348
Inferior nasal	1.24±0.43	1.28±0.50	1.09±0.56	2.261	0.107

PCV, polypoid choroidal vasculopathy; AMD, age-related macular degeneration.

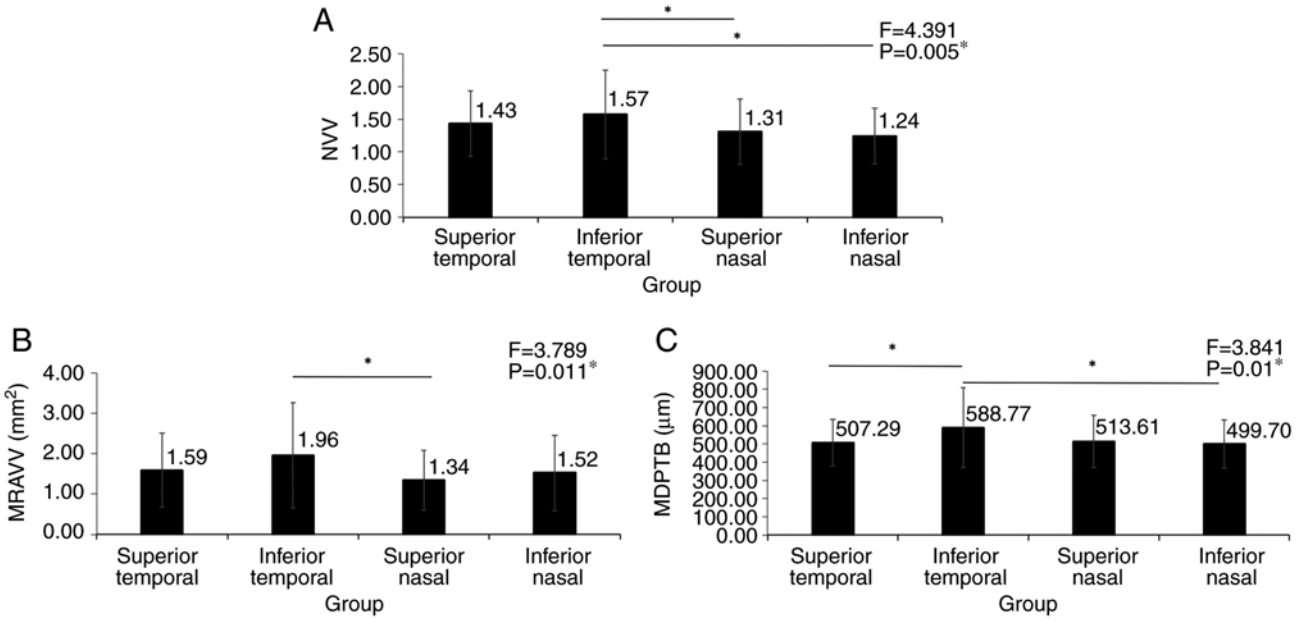

Figure 3. The differences in NVV, MRAVV and MDPTB of the vortex vein in the PCV group among four quadrants. There were significant differences in (A) NVV, (B) MRAVV and (C) MDPTB of the vortex vein in the polypoid choroidal vasculopathy group between the superior temporal, inferior temporal, superior nasal and inferior nasal quadrants. NVV, number of vortex veins; MRAVV, mean root area of the vortex vein; MDPTB. mean diameter of the peripheral thickest branch. *P<0.05.

eyes. The branches of the vortex veins in the PCV group were significantly expanded in the posterior pole and periphery compared with those in the AMD group because the CVVD and MDPTB were significantly increased in the PCV group. If the CVVD was >252.5 μm on ICGA, the diagnosis was more likely to be PCV than AMD, indicating that CVVD may serve as a point of differentiation between PCV and AMD. The dilation of the vortex vein was asymmetric in patients with PCV

Table III. Proportion of type of vortex veins (complete with ampulla) and subretinal haemorrhage in participants with polypoid choroidal vasculopathy in each quadrant.

	Quadrant, n (%)						
Characteristic	Superior temporal	Inferior temporal	Superior nasal	Inferior nasal	Total	χ^2	P-value
Type I (vortex vein absent)	42 (36.21)	33 (30.56)	14 (15.05)	19 (19.19)	116 (100.00)	23.847	<0.001
Type II (incomplete)	26 (24.07)	29 (26.85)	29 (26.85)	31 (28.70)	108 (100.00)	0.604	0.895
Type III (complete)	26 (27.96)	27 (29.03)	28 (30.11)	29 (31.18)	93 (100.00)	0.258	0.968
Type IV (complete with ampulla)	22 (18.97)	19 (17.59)	22 (23.66)	20 (20.20)	99 (100.00)	0.412	0.938
Subretinal haemorrhage	15 (23.81)	30 (47.62)	2 (3.17)	3 (4.76)	63 (100.00)	51.198	<0.001

Table IV. Differences in vortex veins between affected and fellow eye in patients with age-related macular degeneration.

	Groups, n (%)			
Parameter	Affected eye, 18 (10.00)	Fellow eye, 18 (10.00)	T-value	P-value
Number of vortex veins	5.16±1.39	5.11±1.52	0.136	0.893
Central vortex vein diameter, μm	305.53±109.37	249.79±82.35	2.464	0.024[a]
Mean root area of the vortex vein, mm^2	1.64±0.60	1.53±0.45	0.703	0.491
Mean diameter of the peripheral thickest branch, μm	475.22±63.00	479.36±69.57	-0.214	0.833
Subfoveal choroidal thickness, μm	256.00±107.74	268.36±127.26	-0.543	0.599
Vortex vein anastomosis, %	5.56	11.11	-0.566	0.579

[a]P<0.05.

Table V. Differences in vortex veins between affected and fellow eye in patients with polypoid choroidal vasculopathy.

	Group, n (%)			
Parameter	Affected eye, 44 (24.44)	Fellow eye, 44 (24.44)	T-value	P-value
Number of vortex veins	5.38±1.38	5.21±1.66	0.692	0.493
Central vortex vein diameter, μm	296.71±83.12	313.02±66.02	-1.217	0.230
Mean root area of the vortex vein, mm^2	1.47±0.62	1.57±0.72	-0.878	0.385
Mean diameter of the peripheral thickest branch, μm	506.30±88.95	518.93±102.88	-0.693	0.492
Subfoveal choroidal thickness, μm	257.46±109.22	252.68±77.83	0.319	0.752
Vortex vein anastomosis, %	27.27	22.73	0.628	0.533

and the inferior temporal vortex vein was more engorged. The appearance of the venous drainage system in patients with PCV was different from that in the healthy control group. Type IV vortex veins were least common, while type I veins were most common in PCV eyes; these may point to the anatomical basis for the pathogenesis of PCV.

Although typical PCV and AMD are not difficult to differentiate using colour fundus photography, OCT, FFA and ICGA (9), there are clinical cases that are difficult to distinguish, requiring new points of differentiation. The present results indicated that CVVD can be used to distinguish between PCV and AMD, with a cut-off value of 252.5 μm. Gupta *et al* (5) reported no significant differences in choroidal thickness and vascular area between patients with PCV and those with typical AMD after adjusting for age and hypertension. Luo *et al* (10) found that the choriocapillaris flow density of neovascular AMD fellow eyes is significantly decreased compared with that in PCV and control eyes. Takahashi *et al* (11) found no significant difference in SFCT between neovascular AMD and PCV but demonstrated that the ratio of the large choroidal vessel layer thickness to SFCT is significantly increased in eyes with PCV compared with that in eyes with typical neovascular AMD.

The present study indicated that PCV vortex vein branches were significantly dilated and compensatory vortex vein anastomosis was formed. The CVVD and PVVA of the PCV

group were significantly increased compared with that in healthy controls. PCV vortex vein branches were dilated at the posterior pole and peripheral choroid. PVVA in the PCV group was significantly increased compared with that in the healthy controls. Chung *et al* (12) found that PCV eyes are more prone to vortex venous congestion than normal eyes using ICGA, suggesting that vortex venous congestion may be associated with PCV pathogenesis. Choroidal hypertension causes secondary dilation of the vortex veins, which are compensatory anastomoses that decrease intraluminal pressure (13). If the disease progresses, the terminal blood vessels bulge locally and manifest as polypoid lesions (12,14). Qiu *et al* (15) found statistically significant differences in the proportion of diffuse collateral circulation between PCV, neovascular AMD, central serous chorioretinopathy (CSC) and healthy controls. During the progression of pachychoroid spectrum disease, hyperaemia of the vortex veins may gradually improve with the development of anastomosis between the superior and inferior vortex veins (16). Matsumoto *et al* (17) found that neovascular AMD patients with pachychoroid are significantly younger and include a higher proportion of males and increased SFCT and frequency of macular vortex vein anastomoses compared with patients with neovascular AMD without pachychoroid. Relative choroidal thickening resulting from enlargement of deep choroidal veins might be related to the mechanism of internal choroidal and retinal pigment epithelium damage (18,19). Intravitreal injection of anti-VEGF may also improve vision by decreasing the focus and macular edema. Ryu *et al* (20) found that choroidal vascular density (CVD) in PCV is correlated positively with choroidal thickness and choroidal hyperpermeability and that a thicker choroid and increased CVD are also associated with poor treatment response to anti-VEGF injections. Subfoveal choroidal watershed zones are associated with foveal PCV growth, suggesting that PCV arises because of aberrant choroidal circulation (2,21). Combined photodynamic therapy and intravitreal bevacizumab significantly thin the total choroid in patients with PCV after 3 months of treatment and an increase in pachy vessel diameter and choroidal vascularity has been observed in 31.33% of eyes with recurrence of PCV (22).

Here, patients with PCV not only had extended engorged vortex veins but also different appearances of venous drainage systems compared with those in healthy controls. The four types of vortex veins are illustrated in Figs. 4 and 5. Although vortex vein branches in the PCV group showed dilation in both the posterior pole and periphery, the MRAVV was significantly decreased compared with that in the healthy controls. The vortex root area depended not only on the degree of vortex dilatation but also on the appearance of the vein. In the present study, the proportion of type IV was the lowest while the proportion of type I drainage systems was the highest in the PCV group, which was significantly different between the three groups. This finding explains why the PCV group had the lowest MRAVV. The vortex ampulla and intrascleral portion of the vortex veins regulate the choroidal outflow site by flow resistance and may be involved in choroidal venous congestion (23,24). The non-expandable intrascleral route of vortex veins limits the upregulation of choroidal venous outflow (25). Although vortex veins converge, the effects on intraluminal pressure are different from pressure that arises when the veins

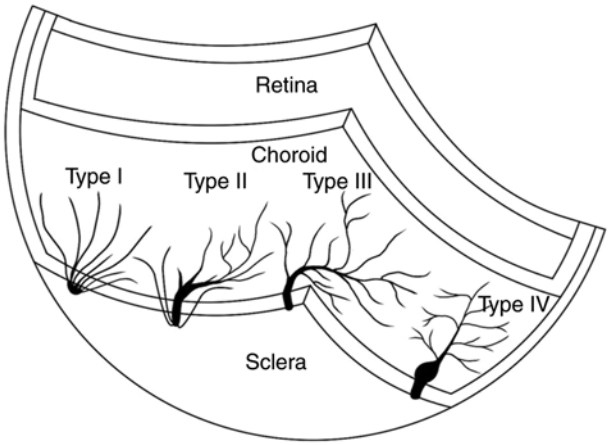

Figure 4. Types of vortex veins. In type I (vortex vein absent), tributaries pass directly through the sclera instead of forming vortex veins. In type II (incomplete), incomplete vortex veins arise where tributaries pass through the sclera together with the vortex veins. In type III (complete), complete vortex veins are seen, where all tributaries join and then pass through the sclera. In type IV (complete with ampulla), a complete system has formed, where all tributaries join the vortex veins to form an ampulla, which passes through the sclera.

first penetrate the sclera and after penetrating the sclera. The ampulla region of the vortex vein resembles a cistern, which relieves luminal pressure within the vortex vein. The vortex vein drains from the choroid to the outside of the eye through the sclera. The vortex vein segment passing through the sclera has poor diastolic ability, resulting in high luminal pressure of the vortex vein in the intrachoroidal segment. The ampullary region relieves high intraluminal pressure (13,26). The total number of vortex veins in patients with PCV was not significantly different compared with that in healthy controls, but the low proportion of type IV vortex veins and a high proportion of type I vortex veins, which would lead to increased intraluminal pressure in the vortex veins, may be related to the pathogenesis of PCV.

The present study found that choroidal vessels are asymmetric in each ocular quadrant and extended engorged vortex veins are more likely to occur in the inferior-temporal quadrant in PCV, which may be associated with the pathogenic mechanism underlying PCV. The inferior temporal NVV, MRAVV and MDPTB of the PCV group were significantly increased compared with those of the other groups and vortex veins were unevenly distributed among the four quadrants in the PCV group. Subretinal haemorrhage appeared in the inferior and the superior temporal quadrant in 47.62 and 23.81% of the patients in the PCV group, respectively, with significant differences between the quadrants in this group. Similar to the present study, Chung *et al* (12) found that vortex venous congestion in PCV eyes is most frequently distributed in the inferior, followed by the superior, temporal quadrant. This suggests that PCV lesions tend to occur in the inferior temporal region, which is closely related to the distribution of the vortex veins. In the PCV group, the proportion of type I vortex veins on the temporal side was significantly increased compared with that on the nasal side, with the highest proportion occurring in the superior temporal and the second highest in the inferior temporal region, which might be associated with

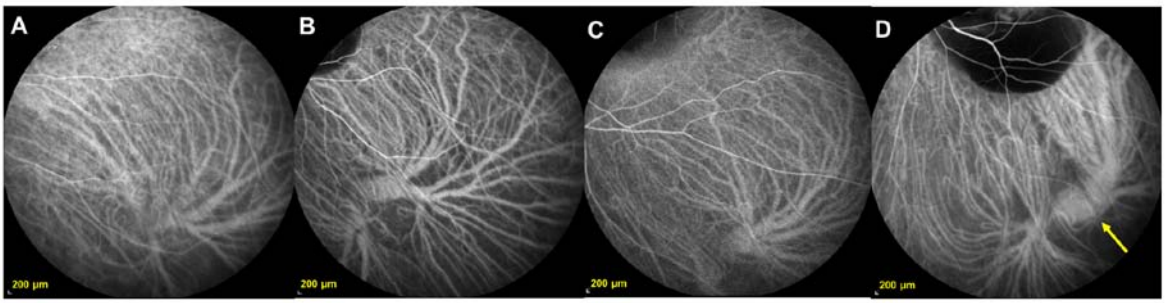

Figure 5. Indocyanine green angiography images of four types of vortex veins in the polypoid choroidal vasculopathy group. (A) Type I (vortex vein absent). (B) Type II (incomplete). (C) Type III (complete). (D) Type IV (complete with ampulla; yellow arrow).

the predominance of PCV bleeding in the inferior temporal region. Due to gravity, the inferior temporal vortex vein fills with more blood compared with the superior temporal vein. Therefore, submacular haemorrhage is more likely to occur in the inferior than in the superior temporal quadrant. Bacci *et al* (27) reported asymmetric choroidal drainage in the macula of 59% of pachychoroid eyes, with choroidal vascular hyperpermeability (CVH) and vortex venous anastomosis more prominent in areas with the greatest choroidal thickness. By comparing the brightness of each quadrant on ultra-widefield ICGA, Jung *et al* (7) found that the inferior temporal quadrant was significantly brighter than the superior nasal quadrant and eyes with CSC and thick choroidal pigment epitheliopathy showed asymmetric choroidal venous outflow. Imbalanced choroidal venous drainage and congestion of specific vortex vein systems may lead to choroidal venous insufficiency, characterized by regional choroidal thickening, CVH and remodelling of venous drainage pathways (27). The unbalanced expansion and congestion of vortex veins facilitate their remodelling to form anastomotic branches, thereby decreasing the local intraluminal pressure (13).

The present study compared vortex vein parameters in the affected and fellow eyes of patients with unilateral PCV and AMD. There were no significant differences in NVV, SFCT, MRAVV, MDPTB or PVVA between the affected and healthy fellow eyes. This suggested that in patients with PCV and AMD with unilateral onset, similar anatomical changes are present in the vortex veins of the affected and fellow eye; therefore, the healthy fellow eye may develop into an affected eye. Wu *et al* (28) found that 70% of fellow eyes of patients with unilateral PCV show CVH on ICGA. Yanagi *et al* (29) found that ~1/5 fellow eyes with unilateral neovascular AMD and PCV exhibit non-exudative neovascularization. CNV occurs in 9% of fellow eyes in individuals with unilateral PCV or aneurysmal type 1 neovascularization, usually retinal pigment epithelium and outer retinal abnormalities with pachy vessels (30). A study that followed patients with unilateral PCV and CNV for up to 5 years found that 17% of fellow eyes developed PCV or CNV (31).

In conclusion, the present study describes various parameters, such as the number, branch diameter, root area, location, type and anastomosis of vortex veins, in PCV, AMD and healthy control eyes, and proposed that CVVD, MRAVV and MDPTB are parameters that quantitatively evaluate these vessels. Moreover, it sheds light on the differences in the morphology and types of vortex veins in PCV, AMD, and healthy individuals. The branches of the vortex veins of the PCV were significantly dilated in the posterior pole and periphery, while lower proportion of type IV vortex veins may be pathognomonic for this condition. Based on the present findings, CVVD may be a key distinguishing point between AMD and PCV using ICGA. Patients with unilateral onset of PCV and AMD showed similar vortex vein anatomy in affected and healthy eyes, indicating the potential for the development of disease in the fellow eye. The present study provides a basis for further exploration of PCV pathogenesis based on vortex vein dilatation.

Acknowledgements

Not applicable.

Funding

The present study was supported by the Bethune·Lumitin Research Funding for the Young and Middle-aged Ophthalmologists (grant no. BJ-LM2021014J).

Availability of data and materials

The datasets used and/or analyzed during the current study are available from the corresponding author on reasonable request.

Authors' contributions

CXC, XMX, TL, BQL, XHH, SSY, ZQL, QW, JLC, LL and YL designed the study. CXC and XMX collected the patient data. CXC analysed data and wrote the manuscript. All authors revised and edited the manuscript. All authors have read and approved the final manuscript. CXC, LL and YL confirm the authenticity of all the raw data.

Ethics approval and consent to participate

Patients orally agreed to the use of their data in the present study. The study was approved by the Ethics Committee of the Zhongshan Ophthalmic Centre (approval no. 2022KYPJ173).

Patient consent for publication

Not applicable.

Competing interests

The authors declare that they have no competing interests.

References

1. Chen LJ: Genetic association of age-related macular degeneration and polypoidal choroidal vasculopathy. Asia Pac J Ophthalmol (Phila) 9: 104-109, 2020.
2. Wong CW, Yanagi Y, Lee WK, Ogura Y, Yeo I, Wong TY and Cheung CMG: Age-related macular degeneration and polypoidal choroidal vasculopathy in Asians. Prog Retin Eye Res 53: 107-139, 2016.
3. Cheung CMG, Lai TYY, Ruamviboonsuk P, Chen SJ, Chen Y, Freund KB, Gomi F, Koh AH, Lee WK and Wong TY: Polypoidal choroidal vasculopathy: Definition, pathogenesis, diagnosis, and management. Ophthalmology 125: 708-724,2018.
4. Díaz-Villamarín X, Blánquez-Martínez D, Pozo-Agundo A, Pérez-Gutiérrez AM, Muñoz-Ávila JI, Antúnez-Rodríguez A, Fernández-Gómez AE, García-Navas P, Martínez-González LJ and Dávila-Fajardo CL: Genetic variants affecting anti-VEGF drug response in polypoidal choroidal vasculopathy patients: A systematic review and meta-analysis. Genes (Basel) 11: 1335, 2020.
5. Gupta P, Ting DSW, Thakku SG, Wong TY, Cheng CY, Wong E, Mathur R, Wong D, Yeo I and Cheung CMG: Detailed characterization of choroidal morphologic and vascular features in age-related macular degeneration and polypoidal choroidal vasculopathy. Retina 37: 2269-2280, 2017.
6. Verma A, Bacci T, Sarraf D, Freund KB and Sadda SR: Vortex vein imaging: What can it tell us? Clin Ophthalmol 15: 3321-3331, 2021.
7. Jung JJ, Yu DJG, Ito K, Rofagha S, Lee SS and Hoang QV: Quantitative assessment of asymmetric choroidal outflow in pachychoroid eyes on ultra-widefield indocyanine green angiography. Invest Ophthalmol Vis Sci 61: 50, 2020.
8. Rutnin U: Fundus appearance in normal eyes. I. The choroid. Am J Ophthalmol 64: 821-839, 1967.
9. Laude A, Cackett PD, Vithana EN, Yeo IY, Wong D, Koh AH, Wong TY and Aung T: Polypoidal choroidal vasculopathy and neovascular age-related macular degeneration: Same or different disease? Prog Retin Eye Res 29: 19-29, 2010.
10. Luo M, Zhao X, Zhao N, Yuan M, Yang J, Dai R and Chen Y: Comparison of choriocapillary flow density between fellow eyes of polypoidal choroidal vasculopathy and neovascular age-related macular degeneration. BMC Ophthalmol 20: 162, 2020.
11. Takahashi Y, Koizumi H, Hasegawa T, Izumi T, Maruko I, Sonoda S, Sakamoto T and Iida T: Comparison of subfoveal choroidal structures in typical neovascular age-related macular degeneration and polypoidal choroidal vasculopathy. Jpn J Ophthalmol 62: 576-583, 2018.
12. Chung SE, Kang SW, Kim JH, Kim YT and Park DY: Engorgement of vortex vein and polypoidal choroidal vasculopathy. Retina 33: 834-840, 2013.
13. Kishi S and Matsumoto H: A new insight into pachychoroid diseases: Remodeling of choroidal vasculature. Graefes Arch Clin Exp Ophthalmol 260: 3405-3417, 2022.
14. Jeong A, Lim J and Sagong M: Choroidal vascular abnormalities by ultra-widefield indocyanine green angiography in polypoidal choroidal vasculopathy. Invest Ophthalmol Vis Sci 62: 29, 2021.
15. Qiu B, Zhang X, Li Z, Chhablani J, Fan H, Wang Y and Xie R: Characterization of choroidal morphology and vasculature in the phenotype of pachychoroid diseases by swept-source OCT and OCTA. J Clin Med 11: 3243, 2022.
16. Matsumoto H, Hoshino J, Arai Y, Mukai R, Nakamura K, Kikuchi Y, Kishi S and Akiyama H: Quantitative measures of vortex veins in the posterior pole in eyes with pachychoroid spectrum diseases. Sci Rep 10: 19505, 2020.
17. Matsumoto H, Hoshino J, Mukai R, Nakamura K, Kishi S and Akiyama H: Clinical characteristics and pachychoroid incidence in Japanese patients with neovascular age-related macular degeneration. Sci Rep 12: 4492, 2022.
18. Sakurada Y, Fragiotta S, Leong BCS, Parikh R, Hussnain SA and Freund KB: Relationship between choroidal vascular hyperpermeability, choriocapillaris flow density, and choroidal thickness in eyes with pachychoroid pigment epitheliopathy. Retina 40: 657-662, 2020.
19. Gal-Or O, Dansingani KK, Sebrow D, Dolz-Marco R and Freund KB: Inner choroidal flow signal attenuation in pachychoroid disease: Optical coherence tomography angiography. Retina 38: 1984-1992, 2018.
20. Ryu G, Moon C, van Hemert J and Sagong M: Quantitative analysis of choroidal vasculature in polypoidal choroidal vasculopathy using ultra-widefield indocyanine green angiography. Sci Rep 10: 18272, 2020.
21. Shin MK, Lee JE, Byon IS and Park SW: Choroidal watershed zone and growth of polypoidal choroidal vasculopathy. Curr Eye Res 42: 252-259, 2017.
22. Baek J, Lee JH, Jeon S and Lee WK: Choroidal morphology and short-term outcomes of combination photodynamic therapy in polypoidal choroidal vasculopathy. Eye (Lond) 33: 419-427, 2019.
23. Spaide RF: CHOROIDAL BLOOD FLOW: Review and potential explanation for the choroidal venous anatomy including the vortex vein system. Retina 40: 1851-1864, 2020.
24. Spaide RF, Cheung CM, Matsumoto H, Kishi S, Boon CJF, van Dijk EHS, Mauget-Faysse M, Behar-Cohen F, Hartnett ME, Sivaprasad S, *et al*: Venous overload choroidopathy: A hypothetical framework for central serous chorioretinopathy and allied disorders. Prog Retin Eye Res 86: 100973, 2022.
25. Takahashi K and Kishi S: Remodeling of choroidal venous drainage after vortex vein occlusion following scleral buckling for retinal detachment. Am J Ophthalmol 129: 191-198, 2000.
26. Yu PK, Tan PE, Cringle SJ, McAllister IL and Yu DY: Phenotypic heterogeneity in the endothelium of the human vortex vein system. Exp Eye Res 115: 144-152, 2013.
27. Bacci T, Oh DJ, Singer M, Sadda S and Freund KB: Ultra-widefield indocyanine green angiography reveals patterns of choroidal venous insufficiency influencing pachychoroid disease. Invest Ophthalmol Vis Sci 63: 17, 2022.
28. Wu H, Sugano Y, Itagaki K, Kasai A, Shintake H and Sekiryu T: The characteristics of choriocapillaris flow void in the unilateral polypoidal choroidal vasculopathy fellow eyes. Sci Rep 11: 23059, 2021.
29. Yanagi Y, Mohla A, Lee WK, Lee SY, Mathur R, Chan CM, Yeo I, Wong TY and Cheung CMG: Prevalence and risk factors for nonexudative neovascularization in fellow eyes of patients with unilateral age-related macular degeneration and polypoidal choroidal vasculopathy. Invest Ophthalmol Vis Sci 58: 3488-3495, 2017.
30. Baek J, Cheung CMG, Jeon S, Lee JH and Lee WK: Polypoidal choroidal vasculopathy: Outer retinal and choroidal changes and neovascularization development in the fellow eye. Invest Ophthalmol Vis Sci 60: 590-598, 2019.
31. Kim K, Kim JM, Kim DG, Yu SY and Kim ES: Five-year follow-up of unaffected fellow eyes in patients with polypoidal choroidal vasculopathy. Ophthalmologica 243: 172-177, 2020.