Laparoscopy and ureteroscopy cooperative surgery for high burden stones in solitary kidney and ureter in one stage: A case report

KEJIA ZHU[1-3*], YAO CHANG[1,2*], DELONG ZHAO[1,2], YONG GUAN[1,3] and SENTAI DING[1-3]

[1]Department of Urology and [2]Engineering Laboratory of Urinary Organ and Functional Reconstruction of Shandong Province, Shandong Provincial Hospital Affiliated to Shandong First Medical University; [3]Department of Urology, Shandong Provincial Hospital Affiliated to Shandong University, Jinan, Shandong 250021, P.R. China

Received December 17, 2022; Accepted March 29, 2023

DOI: 10.3892/etm.2023.11956

Abstract. Treatment of kidney and ureter multiple calculi is a difficult procedure in urology. It is especially difficult to eliminate the high burden stones in a one-stage operation. When a patient has had only one kidney since he/she was born (a condition termed 'solitary kidney'), the conservation of the renal function is especially important. A series of combined surgery techniques have been developed, including endoscopic combined intrarenal surgery, extracorporeal shock wave lithotripsy sandwich therapy and laparoscopy-assisted percutaneous nephrolithotomy, but not laparoscopy or endoscopy cooperative surgery. The present study described the case of a patient with a solitary kidney and ureter who developed multiple calculi. This condition led to hydronephrosis and severe anuria for 3 days. Urinary ultrasound indicated hydronephrosis of the left kidney and several stones were detected. The maximum renal stone was sized ~2.7x0.8 cm. In addition, a maximally sized stone of 2.9x0.9 cm was found in the left upper ureter. The patient had only one kidney, the right kidney was absent. Laboratory examinations revealed severe renal dysfunction. A percutaneous nephrostomy was immediately performed on the left kidney. Laparoscopy, flexible ureteroscopy, rigid ureteroscopy and ureteroscope pneumatic lithotripsy were used to eliminate all the stones in one stage. The patient recovered well and was discharged on the eighth day post-surgery. The present case report highlighted that the conservation of kidney function is critical in the treatment of anuria lasting for 3 days in a patient with calculus. When the situation arises, laparoscopy combined with ureteroscopy cooperative surgery was shown to be a good choice for one-stage clearance of complex stones in patients with a solitary kidney and ureter.

Correspondence to: Professor Sentai Ding or Ms. Kejia Zhu, Department of Urology, Shandong Provincial Hospital Affiliated to Shandong First Medical University, 324 Jingwuweiqi Road, Jinan, Shandong 250021, P.R. China
E-mail: dingsentai@163.com
E-mail: zhukejia@sdfmu.edu.cn

[*]Contributed equally

Abbreviations: ESWL, extracorporeal shock wave lithotripsy; ECIRS, endoscopic combined intrarenal surgery; AP, anteroposterior; SFU, Society of Fetal Urology; CT, computed tomography; BUN, blood urea nitrogen; Cr, creatinine; PCN, percutaneous nephrostomy; PCNL, percutaneous nephrolithotomy; NS, normal saline; RIRS, retrograde intrarenal surgery; UPJ, ureteropelvic junction; GMSV, Galdakao-modified supine Valdivia; SFR, stone-free rate

Key words: high burden stones, laparoscope, ureteroscope, solitary kidney, ureter stones, surgery

Introduction

The prevalence of kidney stones has been increasing worldwide over the past few decades. In Asia, the prevalence is 1-19% (1,2), which represents a considerable burden for public healthcare systems. According to the European Association of Urology (EAU) Guidelines, 'high burden stones' comprise single or multiple large calculi (a total surface area >300 mm^2, or with the largest diameter measuring >20 mm, for urolithiasis) and staghorn calculi. A series of complications are associated with high burden stones, including renal deterioration, pyonephrosis, obstruction, flank pain and life-threatening sepsis. Percutaneous nephrolithotomy (PCNL) is the preferred first-line treatment for high burden urolithiasis. However, it has the disadvantage of there being more than one access site that may be required in order to bring about a complete clearance. To achieve a one-stage clearance of the stones, other novel combined techniques have been explored, such as combinations of PCNL and extracorporeal shock wave lithotripsy (ESWL; so-called 'sandwich' therapies) and endoscopic combined intrarenal surgery (ECIRS). ECIRS involves a combination of PCNL and ureteroscopy to investigate the renal cavities (3). Laparoscopic ureterolithotomy has the benefits of being a minimally invasive technique with short hospital stays, as well as the advantage of one-time removal of calculi, which is usually the case with open surgery (4). Furthermore, it is a viable option in difficult stone situations and in cases

where there is an abnormal anatomy of the urinary system. To eliminate the high burden stones from solitary kidney patients (born with one kidney), we have devised a novel type of surgery combining laparoscopy and endoscopy. The latter comprised a flexible ureteroscope, a rigid ureteroscope and ureteroscope pneumatic lithotripsy. Laparoscopy and endoscopy cooperative surgery have previously been introduced as a minimally invasive technique for the resection of gastrointestinal subepithelial tumors (5). At the present time, cooperative surgery is not routinely used as a technique in urology, although there are a few clinical studies that have been published on it (6,7). The experience of clinical treatment in the present case study could provide much guidance for the future treatment of high burden stones. Note that the following case is presented in accordance with the CARE reporting checklist.

Case report

The current study presented the case of surgical treatment of a patient with one solitary kidney and ureter with multiple calculus. Laparoscopy, flexible ureteroscopy and rigid ureteroscopy were used in the one-stage surgery. A 68-year-old male patient with a history of kidney and ureter calculus for 18 years and bilateral necrosis femoral heads for 15 years was admitted to Shandong Provincial Hospital with the complaint of intermittent left-flank pain for 10 days and anuria for 3 days. A physical examination showed limited movement of both lower limbs and percussion tenderness in the left kidney region. Laboratory examination revealed levels of blood urea nitrogen (BUN) of 23.4 mmol/l (normal range: 2.8-7.14 mmol/l), creatinine (Cr) of 706.21 μmol/l (normal range: 40-135 μmol/l) and potassium of 5.93 mmol/l (normal range: 3.5-5.3 mmol/l) (Fig. 1A-C). The patient had been treated with antibiotics prior to attending hospital. Neither sepsis nor coagulation disorders were detected in the patient; neither were bacteria cultured in his urine. The white blood cells were not increased and the C-reactive protein was increased a small amount on the day of admission. Urinary ultrasound revealed a dilation of the left renal pelvis of ~4.3 cm anteroposterior (AP) diameter [Society of Fetal Urology (SFU)-III (one of the grading systems of hydronephrosis)] (8) and several stones were detected in the left kidney. The maximum renal stone was ~2.7x0.8 cm. No kidney was detected in the right renal area. A stone of 2.9x0.9 cm size was found in the left upper ureter. Stones of diameter >2 cm were also detected in the pelvic part of the left ureter. Abdominal computed tomography (CT) showed left renal and ureteral calculus with hydronephrosis, whereas the right kidney was absent (Fig. 1D-G). On the day of admission, percutaneous nephrostomy (PCN) was performed on the left kidney. On the second day after PCN, a second ultrasound showed that the AP diameter of the left hydronephrosis had decreased from 4.3 to 1.4 cm [SFU-IIb] (8). One week after PCN, the renal function was reviewed: BUN was found to be present at a concentration of 6.5 mmol/l, Cr was 105.22 μmol/l and potassium was 4.7 mmol/l (Fig. 1A-C). Kidney, ureter and bladder plain film radiography was subsequently performed to locate the calculi again immediately prior to the surgery (Fig. 1H).

The patient underwent left laparoscopic ureterolithotomy combined with flexible ureteroscopy and rigid ureteroscopy and ureteroscope pneumatic lithotripsy on the 9th day after admission to hospital and nearly 40 stones and fragments were removed (Fig. 1P). Under general anesthesia, a urethral catheter was introduced retrograde into the bladder and 150 ml 0.8% methylene blue [diluted in normal saline (NS)] was irrigated into bladder. The catheter was then clamped. The patient was placed in an approx. 70° lateral position. Once a pneumoperitoneum was established, a 10 mm trocar was placed at the umbilicus for the camera and 5-, 10- and 12-mm ports were inserted, respectively. First, the colon was reflected to provide adequate visualization of the anterior surface of the psoas tendon. Secondly, the ureter was dissected. After carefully examining the region of the upper ureter, it was found to have become coarse and edematous. Unipolar electrocoagulation was used to cut the ureter longitudinally at the beginning of the ureterectasia and several pieces of stone were found to exist in the ureteral lumen, the largest one of them being 1 cm in length and cylindrical, with a yellow-brown color. The stone was removed using a vascular clamp (Fig. 1J). An F8 catheter was inserted into the trocar and upper side of the cut and NS was irrigated into the kidney. With a rapid withdrawal of the catheter, several stones were flushed out. More stones were flushed out as a result of NS being irrigated through the nephrostomy tube (Fig. 1K). Thirdly, a flexible ureteroscope was inserted through the trocar under the laparoscopic view and the ureteral incision was used to explore the renal pelvis (Fig. 1L). No further kidney stones were observed. Subsequently, the flexible ureteroscope was used to continue to explore the lower part of the ureter. A large number of calculi were in the pelvic part of the ureter, although they could not be removed by the flexible ureteroscope. Fourthly, the rigid ureteroscope combined with forceps were introduced through the trocar to remove the middle and lower urinary calculi. The residual calculi (i.e., >10 large calculi of diameter >1 cm) were crushed using ureteroscope pneumatic lithotripsy and pushed into the bladder (Fig. 1M). The methylene blue finally flowed out from the lower ureteral incision. A double J tube was placed in the left ureter. One end of the double J tube was in the renal pelvis, while the other end was in the bladder and the ureteral incision was ligated using sutures, with repeated washing of the wound using the internally located drainage peritoneal tube.

On the second day after surgery, renal function was analyzed once again and the concentrations of the biochemical markers were as follows: BUN, 11.6 mmol/l; creatinine, 93.73 μmol/l; and potassium, 4.06 mmol/l. The thyroid function series were subsequently tested and there were no signs of hyperparathyroidism. At 5 days post-operation, the drainage was suppressed. The catheter was then removed 7 days post-operation, although the nephrostomy tube was kept to maintain the renal function. The patient recovered well and was discharged on the eighth day post-operation. One month after the operation, the patient's BUN level was 7.4 mmol/l, the creatinine concentration was 93.10 μmol/l and the potassium level was 4.19 mmol/l. Two stones of diameter ~1 cm remained, one in the left kidney and the other in the left ureter (Fig. 1I, N and O) and ESWL was performed 43 days post-operation. The ESWL was performed using a lithotripter with up to 3,500 shock waves at 11-14 kV. The total energy used was 95.32 J. Thereafter, the patient was not subjected to any further examinations or treatment.

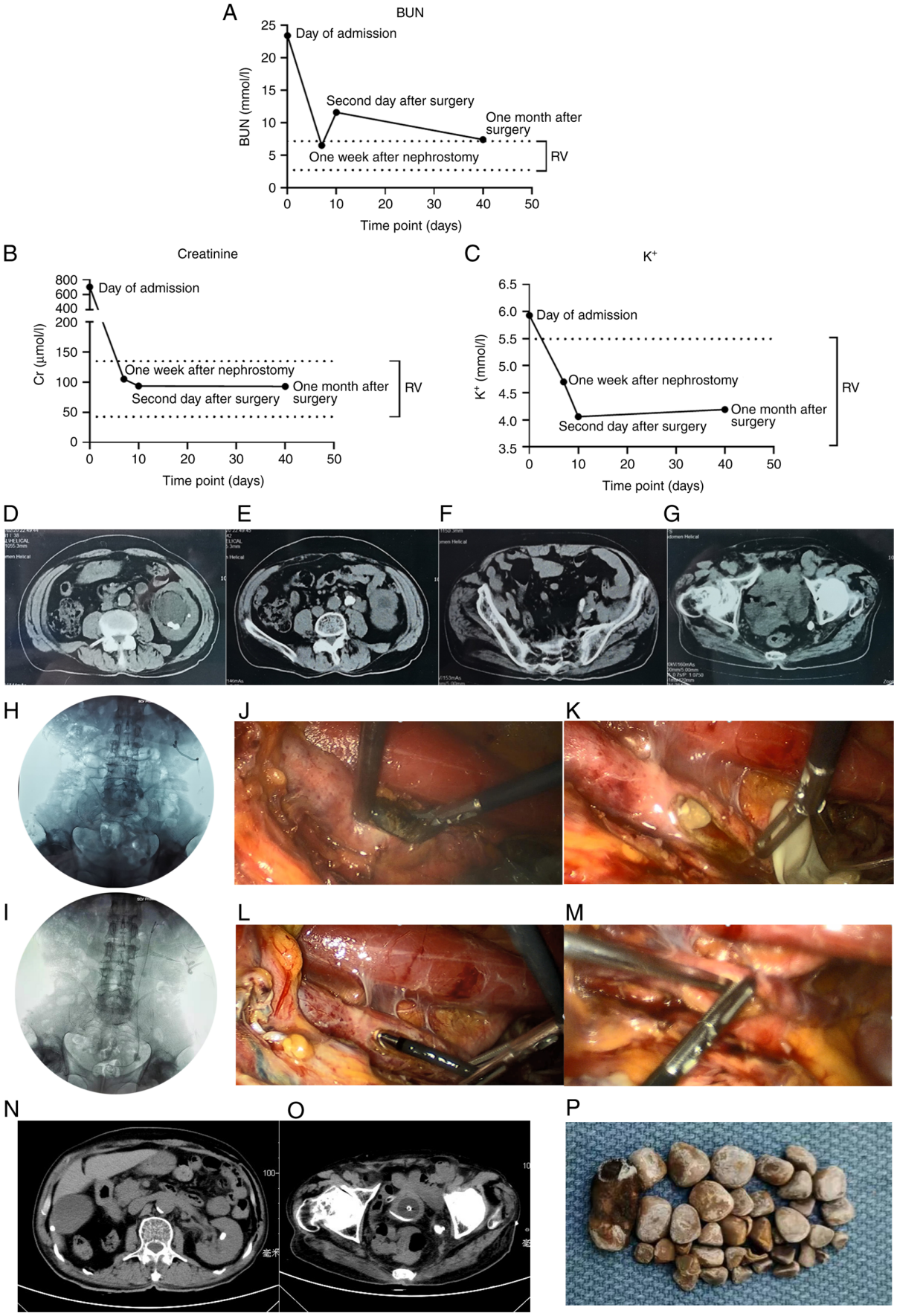

Figure 1. Laparoscopy and ureteroscopy cooperative surgery in solitary kidney and ureter stones. (A-C) Renal function and changes in blood biochemistry for the whole procedure. (D-G) CT before admission of the patient. (H, I) The kidney, ureter and bladder (H) before and (I) after surgery. The key procedures in the surgery are shown: (J) the step of laparoscopic ureterolithotomy; (K) calculi were washed out through the renal fistula; (L) the step of flexible ureteroscope exploratory surgery; and (M) the steps of rigid ureteroscope lithotripsy and pneumatic lithotripsy. (N, O) CT following the surgery. (P) Image captured of the stones removed from the patient. BUN, blood urea nitrogen; Cr, creatinine; CT, computed tomography.

All procedures performed in the present study were in accordance with the ethical standards of the institutional and/or national research committee(s) and with the Helsinki Declaration (as revised in 2013). The present study was approved by the Ethics Committee of Shandong Provincial Hospital Affiliated to Shandong First Medical University (Jinan, China; approval no. SWYX: No. 2021-370). The subject signed an informed consent form and had complete clinical data.

Discussion

The patient in the present study was an elderly male with a solitary kidney and ureter, which meant the renal function of his only kidney assumed a greater importance. He had had a history of calculi for 18 years. The accompanying bilateral necrosis femoral heads led to his limitation of movement, which also contributed to the formation of multiple stones in the left kidney and ureter. The maximum diameters of the stones were 2.7 cm in the kidney and 2.9 cm in the ureter. All the features described above contributed towards the complexity of the present case. On the day of admission, the first aim was not surgery, but to resolve the anuria and to save the patient's life. PCN was performed immediately, serving as the critical step in the whole treatment. First, it led to a rapid reduction in the concentrations of BUN, Cr and potassium, which provide a suitable precondition for subsequent treatment; secondly, in the combined surgery, the renal fistula act as another channel for irrigation of NS, which also helped to flush the stones out. For the surgical treatment of high burden stones, there are a series of surgery management strategies available. Laparoscopic ureterolithotomy has the advantage of one-time removal of large stones. Although certain large ureter stones may be squeezed out from the incision, the removal of kidney stones and stones in the pelvic region of ureter cannot be achieved and a larger incision is required. Retrograde intrarenal surgery (RIRS) has the advantages of minimal invasion and wide scope of vision, although for stones >2 cm in diameter, the duration of the surgery is usually longer compared with laparoscopy and one-stage clearance is very difficult to accomplish (9). Even if the stones are finally cleared, the formation of a ureteric steinstrasse is quite commonly seen as a side effect (9,10). To dispose of the steinstrasse, much more work is required, such as ESWL or RIRS once again (11). PCNL is the first-line choice for high burden stones in the upper urinary tract, but not for stones in the ureter. Furthermore, the injury caused to the kidney is clearly larger compared with RIRS (10). There are a series of complications in PCNL, including intraoperative complications: Hydrothorax, bleeding, pelvic perforation and postoperative events, in addition to fever, urinary tract infections, low back pain, hematuria (12). In the present case, a larger number of stones were detected in the ureter compared with in the kidney (Fig. 1D-G and H) and so the clearance of ureter stones >2 cm was the top priority and PCNL was not considered. To make good use of the advantages of laparoscopy and ureteroscopy, laparoscope-flexible, ureteroscope-rigid, ureteroscope-pneumatic lithotripsy combined surgery was performed, which, to the best of the authors' knowledge, has yet to be reported as a standard solution for high burden stones according to any guidelines. It should be noted that a similar surgery was performed in the treatment of ureteropelvic junction (UPJ) obstruction combined with renal stones (6). In addition, Salvado *et al* (7) presented a case series on the application of laparoscopy combined with flexible endoscopy for the treatment of large pelvic stones, UPJ obstruction, or a poorly functioning kidney. Pyelotomy was necessary for the removal of large kidney stones. In the present case, this combined surgery satisfied the requirements of removing large upper ureter stones (by laparoscopic ureterolithotomy) and kidney stones and pelvic ureter stones (by RIRS), while remaining minimally invasive. The use of high-pressure NS irrigation also assisted in the clearance of kidney stones. The position between operations was not changed, although the trocar and the ureter incision was used as the pathway for the ureteroscope. This helped to both shorten the operation duration and decrease the number of access sites.

Combining PCNL with RIRS, a new combined surgery (ECIRS) has been developed in recent years. ECIRS allows the combined use of all the rigid and flexible items of endourological equipment. It is usually performed in the Galdakao-modified supine Valdivia (GMSV) position. The stone-free rates (SFRs) of ECIRS have been determined to lie in the range 86.7-87.4% (3,13). The ECIRS method has the advantages of limited exposure of the surgeon's hands to X-rays (14) and more patient comfort (in terms of obviating the need for intraoperative repositioning). Certain of these advantages were also featured in our combined surgery. RIRS is a necessary step in GMSV for the management of ureter stones. The overall complication rate of ECIRS is 38.6% (3) and the commonest complications are identified as transient fever, urinary leakages and hematoma and hematuria. Our surgical method omitted PCNL, which greatly reduced the complications that are usually seen following PCNL.

Another sandwich surgery, combining PCNL with ESWL, has been reported previously (15,16). The approach began with PCNL through one or two tracts and ESWL was performed either the next day (15) or 2 weeks later (17). However, a PCNL tract is a trauma for the renal parenchyma, performing ESWL within 24 h adds another trauma that could lead to renal rupture a severe hemorrhage. Occasionally, rigid and flexible nephroscopy may be employed to achieve an improved SFR. The associated SFR is of the order of 67-70% and its main complications were found to be bleeding and fever. The sandwich surgery mainly focuses on the treatment of kidney stones, albeit without decreasing the risk of PCNL. The ESWL was usually applied to stones >2 cm, although this type of sandwich management is not often used now. For the treatment of high burden stones in the pelvic kidney or other renal anomalies (16), there have also been reports on the use of laparoscopy-assisted PCNL (LA-PNL) (18-20). The SFR of this method was found to be in the range 75-91% and no complications were reported.

Based on the literature and our experiences, PCNL is no doubt the first choice for the treatment of high burden kidney stones. In our case, however, the most urgent problem to be resolved was the ureter stones and so PCNL was not employed; rather, a combination of laparoscopy with rigid and flexible endourological equipment was used. This has seldom been reported previously and has enabled us to achieve an ideal SFR with the protection of kidney function. Using one-stage combined surgery, the side effects of multi-stage operations

on isolated renal function can be largely avoided. However, the present case also had certain limitations. For example, for the high burden urolithiasis, placement of the gauze under the ureter incision prior to cutting would help to hold the stones that emerge from the urinary tract, thereby negating the need to search unnecessarily for stones that might otherwise fall into the abdomen. Furthermore, when flexible ureteroscopy is used, laser lithotripsy becomes technically practicable and the introduction of lasers might simplify the one-stage combined surgery by a further step. We did not perform more examination such as 24-h urinalysis or spectroscopic analysis of stones, which is also a limitation to our study.

In the present case, the patient came to our hospital with the compliant of both stones and, most important, anuria. The treatment successfully solved the problem of obstruction, saved the function of solitary kidney and avoided the possible renal failure. Even if a combined surgery was performed on the patient, the laboratory examination showed an acceptable injury. At least, we can try to prolong the duration before his next admission. This is the value of the therapeutic approach. For further surveillance measures, we recommend the urine white blood cell, urine electrolytes and evaluation of hydronephrosis. Prophylaxis or metaphylaxis measures may yet be adopted. In order to avoid the antibiotic resistance, antibiotics will be added when urinary tract infection is diagnosed.

Acknowledgements

Not applicable.

Funding

The present study was supported by the Shandong Provincial Natural Science Foundation (grant no. ZR2021QH313),Academic Promotion Programme by Shandong First Medical University (grant no. 2020LI001) and the Scientific Research Incubation Fund of Shandong Provincial Hospital Affiliated to Shandong First Medical University (grant no. 2020FY041).

Availability of data and materials

The datasets used and/or analyzed during the current study are available from the corresponding authors on reasonable request.

Authors' contributions

SD proposed the concept and designed the manuscript. KZ and SD confirm the authenticity of all the raw data and provided administrative support. KZ, YC and YG collected and assembled the data. KZ, YC and DZ analyzed and interpreted the data. SD, YG and KZ contributed to the minimally invasive surgery. All authors contributed to the writing of the manuscript and have read and approved the final manuscript.

Ethics approval and consent to participate

All procedures performed in this study were in accordance with the ethical standards of the institutional and/or national research committee(s) and with the Helsinki Declaration (as revised in 2013). The present study was approved by the Ethics Committee of Shandong Provincial Hospital Affiliated to Shandong First Medical University (Jinan, China; approval no. SWYX: No. 2021-370). The subject signed an informed consent form and had complete clinical data.

Patient consent for publication

Written informed consent was obtained from the patient for publication of this case report and accompanying images.

Competing interests

The authors declare that they have no competing interests.

References

1. Liu Y, Chen Y, Liao B, Luo D, Wang K, Li H and Zeng G: Epidemiology of urolithiasis in Asia. Asian J Urol 5: 205-214, 2018.
2. Sorokin I, Mamoulakis C, Miyazawa K, Rodgers A, Talati J and Lotan Y: Epidemiology of stone disease across the world. World J Urol 35: 1301-1320, 2017.
3. Scoffone CM, Cracco CM, Cossu M, Grande S, Poggio M and Scarpa RM: Endoscopic combined intrarenal surgery in Galdakao-modified supine Valdivia position: A new standard for percutaneous nephrolithotomy? Eur Urol 54: 1393-1403, 2008.
4. Turk C, Petrik A, Sarica K, Seitz C, Skolarikos A, Straub M and Knoll T: EAU guidelines on interventional treatment for Urolithiasis. Eur Urol 69: 475-482, 2016.
5. Hiki N, Yamamoto Y, Fukunaga T, Yamaguchi T, Nunobe S, Tokunaga M, Miki A, Ohyama S and Seto Y: Laparoscopic and endoscopic cooperative surgery for gastrointestinal stromal tumor dissection. Surg Endosc 22: 1729-1735, 2008.
6. Fu W, Chen H, Ren C and Zhao J: Transabdominal laparoscopy and ureteroscopy one-stage surgery in the treatment of bilateral ureteropelvic junction obstruction combined with bilateral renal stones: A case report. Exp Ther Med 24: 450, 2022.
7. Salvado JA, Guzman S, Trucco CA and Parra CA: Laparoscopic pyelolithotomy: Optimizing surgical technique. J Endourol 23: 575-578, 2009.
8. Onen A: Grading of hydronephrosis: An ongoing challenge. Front Pediatr 8: 458, 2020.
9. Hyams ES, Munver R, Bird VG, Uberoi J and Shah O: Flexible ureterorenoscopy and holmium laser lithotripsy for the management of renal stone burdens that measure 2 to 3 cm: A multi-institutional experience. J Endourol 24: 1583-1588, 2010.
10. Jiang K, Zhang P, Xu B, Luo G, Hu J, Zhu J and Sun F: Percutaneous nephrolithotomy vs. retrograde intrarenal surgery for renal stones larger than 2 cm in patients with a solitary kidney: A systematic review and a meta-analysis. Urol J 17: 442-448, 2020.
11. Birowo P, Rasyid N, Atmoko W and Sutojo B: Case report: An occurrence of steinstrasse in retrograde intra renal surgery (RIRS) for large staghorn kidney stone: A difficult experience in managing surgical outcomes. F1000Res 9: 184, 2020.
12. Grosso AA, Sessa F, Campi R, Viola L, Polverino P, Crisci A, Salvi M, Liatsikos E, Feu OA, Maida FD, *et al*: Intraoperative and postoperative surgical complications after ureteroscopy, retrograde intrarenal surgery, and percutaneous nephrolithotomy: A systematic review. Minerva Urol Nephrol 73: 309-332, 2021.
13. Hamamoto S, Yasui T, Okada A, Taguchi K, Kawai N, Ando R, Mizuno K, Kubota Y, Kamiya H, Tozawa K and Kohri K: Endoscopic combined intrarenal surgery for large calculi: Simultaneous use of flexible ureteroscopy and mini-percutaneous nephrolithotomy overcomes the disadvantageous of percutaneous nephrolithotomy monotherapy. J Endourol 28: 28-33, 2014.
14. Ibarluzea G, Scoffone CM, Cracco CM, Poggio M, Porpiglia F, Terrone C, Astobieta A, Camargo I, Gamarra M, Tempia A, *et al*: Supine Valdivia and modified lithotomy position for simultaneous anterograde and retrograde endourological access. BJU Int 100: 233-236, 2007.
15. Streem SB and Geisinger MA: Combination therapy for staghorn calculi in solitary kidneys: Functional results with long-term followup. J Urol 149: 449-452, 1993.

16. Diri A and Diri B: Management of staghorn renal stones. Ren Fail 40: 357-362, 2018.
17. Merhej S, Jabbour M, Samaha E, Chalouhi E, Moukarzel M, Khour R and Chaiban R: Treatment of staghorn calculi by percutaneous nephrolithotomy and SWL: The hotel Dieu de France experience. J Endourol 12: 5-8, 1998.
18. Soylemez H, Penbegul N, Utangac MM, Dede O, Çakmakçı S and Hatipoglu NK: Laparoscopy assisted percutaneous stone surgery can be performed in multiple ways for pelvic ectopic kidneys. Urolithiasis 44: 345-352, 2016.
19. Haghighi R, Razi A, Haghighi A, Ebrahimipour N and Teimouri A: Laparoscopy-assisted transperitoneal percutaneous nephrolithotomy for the treatment of renal stones in a horseshoe kidney. Res Rep Urol 12: 49-52, 2020.
20. El-Kappany HA, El-Nahas AR, Shoma AM, El-Tabey NA, Eraky I and El-Kenawy MR: Combination of laparoscopy and nephroscopy for treatment of stones in pelvic ectopic kidneys. J Endourol 21: 1131-1136, 2007.