Growth restriction and congenital heart disease caused by a novel *TAB2* mutation: A case report

QIAN DENG[1*], XIN WANG[1*], JIAN GAO[1], XIAOWEI XIA[2], YUNGONG WANG[3], YIN ZHANG[4] and YUQING CHEN[1]

Departments of [1]Pediatric Endocrinology and Metabolic Disease, [2]Ultrasound Medicine, [3]Pediatric Cardiovascular Diseases and [4]Urology, Children's Hospital of Fudan University Anhui Hospital, Hefei, Anhui 230022, P.R. China

Received July 30, 2022; Accepted March 24, 2023

DOI: 10.3892/etm.2023.11957

Abstract. Congenital heart disease (CHD) is a malformation present from birth caused by the abnormal development of the heart and large blood vessels during the prenatal development. The TGF-β activated kinase 1 (MAP3K7) binding protein 2 (TAB2) gene plays an important role in the embryonic development of heart tissue. When haploid dosage is insufficient, it can lead to CHD or cardiomyopathy. The present study reported a case study of a Chinese child with growth restriction and CHD. The results of whole exome sequencing suggested that a novel frameshift mutation (c.1056delC/p.Ser353fsTer8) occurred in *TAB2*. The parents of this patient are wild-type at this locus; therefore, it may be a *de novo* mutation. The mutant plasmid was constructed *in vitro*, and the western blotting results showed that the mutation may cease protein expression. This indicated the pathogenic harmfulness of this mutation. In conclusion, the present study emphasizes that *TAB2* defects should be investigated in patients with unexplained short stature and CHD, irrespective of family history regarding CHD or cardiomyopathy. The current study provided new data on the mutation spectrum and provided information for second pregnancies and genetic counseling of the parents of patients.

Introduction

TAB2 encodes the TGF-β activated kinase 1 (MAP3K7) binding protein 2 (TAB2), which can self-phosphorylate and regulate chemokines and inflammatory signaling molecules. Therefore, *TAB2* gene defects are primarily associated with inflammatory responses (1,2). Thienpont *et al* (3) demonstrated the presence of a 6q24-q25 deletion following array-based comparative genomic hybridization detection in seven patients with congenital heart disease (CHD), and further revealed that insufficient haploid dosage of *TAB2* in this region can lead to abnormal human heart development. Mutations in *TAB2* lead to congenital heart defects, non-syndromic, 2 (CHTD2; OMIM#614980). *TAB2* results in varying types of cardiac abnormalities, such as mitral, tricuspid valve prolapse and aortic stenosis, while some patients may face sudden cardiac death (3,4). In addition to cardiac structural abnormalities, patients with CHTD2 may present dysmorphic facial, joint and skin phenotypes (5,6). Therefore, identifying the abnormal features caused by mutations of *TAB2* aids in clinical diagnosis, especially in prenatal diagnosis and genetic counseling.

The present study performed trio-whole exome sequencing (trio-WES) on a Chinese family with short stature and CHD as the main clinical features. The patient's cardiac color Doppler ultrasound showed insufficient mitral and mild regurgitation. In addition, the patient exhibited growth restriction and dysmorphic facial features. The results of genetic testing indicated that a novel pathogenic mutation occurred in the *TAB2* gene; this may lead to protein non-expression, as indicated by *in vitro* functional experiments. The present study further expanded the pathogenic mutation spectrum of *TAB2*.

Case report

A 3-year-old male child was the subject of the present study (his mother is G1P1). Prenatal ultrasound diagnosis at 24 weeks of pregnancy showed that the fetus had short legs. Vaginal delivery occurred at 41^{+6} weeks of pregnancy, there was no history of birth asphyxia, the Apgar score was unknown and birth weight was 3,200 g. After birth, the motor milestone development of the child was normal. At the age of 10 months, his parents noticed that his growth development lagged behind those of his peers. No special treatment was given, and the annual growth rate was unknown. During the study period of the present study, the child was hospitalized in The Department of Pediatric Endocrinology and Metabolic Disease (Children's Hospital of

Correspondence to: Dr Yuqing Chen, Department of Pediatric Endocrinology and Metabolic Disease, Children's Hospital of Fudan University Anhui Hospital, 39 Wangjiang Road, Hefei, Anhui 230022, P.R. China
E-mail: chenyuqing_815@163.com

[*]Contributed equally

Key words: congenital heart disease, genetic testing, growth restriction, TGF-β-activated kinase 1 binding protein 2, western blotting

Figure 1. Clinical and mutation information of the patient. (A) Color doppler echocardiography showing a misaligned closing point mitral valve and a closing gap of 0.23 cm (as shown by the arrow). (B) Color doppler echocardiography showing the thickening of the mitral valve leaflets (arrow). (C) Results of genetic detection suggesting that exon 4 of *TAB2* has frameshift mutation c.1056delC/p.Ser353fsTer8, and that the parents are wild-type, indicating a *de novo* mutation. TAB2, TGF-β-activated kinase 1 (MAP3K7) binding protein 2.

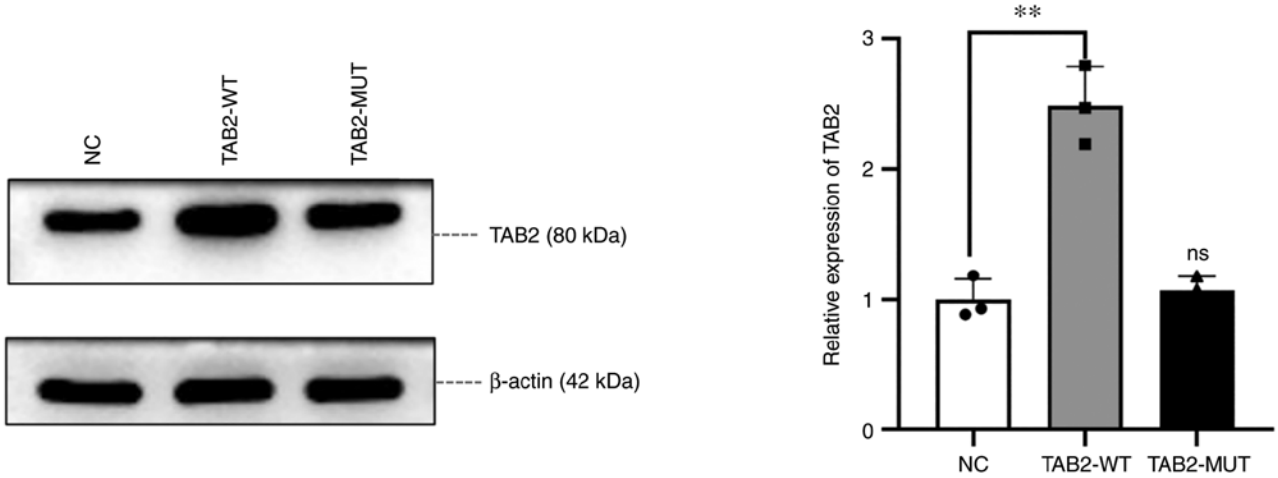

Figure 2. Western blotting results showing that protein expression in the TAB2-WT group was significantly higher compared with that in the blank plasmid group. No significant expression was observed in the TAB2-MUT group (P=0.57). This indicates that the mutant TAB2 protein was not expressed, and the mutant Ser353fsTer8 may have led to the degradation of the TAB2 protein *in vivo*, resulting in an insufficient haploid dose and disease expression. **P<0.01. TAB2, TGF-β-activated kinase 1 (MAP3K7) binding protein 2; NC, negative control; WT, wild-type; MUT, mutation; ns, not significant.

Fudan University, Anhui Hospital, Hefei, China) for the growth related treatment. The physical examination conducted on admission showed that the child was in good mental state. He had dysmorphic facial features with a wide forehead and low ear position, with a height of 89.5 cm [-3 standard deviation (SD)] and a weight of 12.7 kg (-1.5 SD). His bilateral scrotum was empty, and the testicles were not touched. His limbs moved freely, with normal muscle tension of the limbs and no bone deformities were observed. No obvious abnormalities were detected during the auxiliary examination. Color Doppler echocardiography showed mitral insufficiency with mild regurgitation; a closing gap of ~0.23 cm was observed, as shown in Fig. 1A and B. The parents of the child were healthy, and stated that they were non-consanguineously married, and had no family history of short stature and CHD.

Genetic testing. The family was tested using trio-WES. The work described in the present case report was approved by the Ethics Committee of the Children's Hospital of Fudan University Anhui Hospital (Hefei, China), and informed consent was obtained from the parents of the patient. Approximately 3 ml of peripheral blood was collected from the proband as well as his parents, DNA was extracted using the genomic DNA extraction kit (Tiangen Biochemical Technology Inc.). A DNA library was constructed using the xGen Exome Research Panel V2 Kit (Integrated DNA Technologies Inc.). The paired-end sequencing (150 bp) was run on the Hiseq 4000 platform (Illumina Inc.). The off-line data were filtered for quality control and screened using the Burrows-Wheeler Aligner sequence alignment method (refer to hg19 version) (7). The target sequence mutation sites were identified using the GATK v4.1.9 software (8) and annotated according to the public variation databases (dbSNP build 155, www.ncbi.nlm.nih.gov/snp/; ExAC v0.3.1, https://gnomad.broadinstitute.org/; and 1000 Genomes, www.international-genome.org/). Multiple biohazard prediction software were used to analyze the suspected variation to the *TAB2* gene (SIFT build 37, https://sift.bii.a-star.edu.sg/; Polyphen-2 v2.3, http://genetics.bwh.harvard.edu/pph2/; and MutationTaster 2021, www.mutationtaster.org/).

The results of the genetic testing for the child, but not his parents, revealed a heterozygous base deletion mutation TC>T in *TAB2* exon 4, resulting in a frameshift mutation after encoded amino acid 352, NM_001369506: c.1056delC, (p.Ser353fsTer8), suggesting that the frameshift mutation observed may be a *de novo* mutation of *TAB2*. The mutation was not included in the public database. According to the guidelines of the American College of Medical Genetics and Genomics, the mutation is rated as pathogenic, and the evidence rating is PVS1+PM2+PM6 (9). Sanger sequencing was performed using genomic DNA isolated from the blood of the patient and his parents. Direct sequencing was performed on the ABI 3730XL Automatic Sequencer (Thermo Fisher Scientific, Inc.). Amplification was performed using the following conditions: 1 cycle of 95˚C for 2 min, followed by 39 cycles of 95˚C for 30 sec, 60˚C for 30 sec, 72˚C for 40 sec and a final extension at 72˚C for 5 min. Sanger sequencing confirmed the existence of this mutation (Fig. 1C).

Plasmid construction and protein expression. The pcDNA3.1 vector (Tsingke Biotech) was used to construct a TAB2-wild-type (WT) plasmid using Phanta® Max Super-Fidelity DNA Polymerase (cat. no. P505; Vazyme Biotech Co., Ltd.), according to the manufacturer's instructions (amplification primers: Forward, 5'-CTTGGTACC GAGCTCGGATCCATGGCCCAAGGAAGCCAC-3'; and Reverse, 5'-TGCTGGATATCTGCAGAATTCTCAGAAATG CCTTGGCATCTC-3'). The TAB2-mutant (MUT) plasmid was constructed using a Mut Express MultiS Fast Mutagenesis Kit V2 (cat. no. C215; Vazyme Biotech Co., Ltd.) (amplification primer: Forward, 5'-CCAGCACTTCTCTTCAGTCAA TAGCCAGACCTTAA-3'; and Reverse, 5'-ACTGAAGAG AAGTGCTGGAGGTTCGAGGTCCAG-3'). The amplification conditions were as follows: Pre-denaturation at 95˚C for 3 min, denaturation at 95˚C for 15 sec, annealing at 60˚C for 15 sec, extension at 72˚C for 1 min (35 cycles in total), and a final extension at 72˚C for 10 min. The plasmids were then transfected into human 293T cells (The Cell Bank of Type Culture Collection of The Chinese Academy of Sciences) using Lipofectamine 2000 (Thermo Fisher Scientific, Inc.). After the cells were fully lysed in cell lysis buffer (Beyotime Institute of Biotechnology), 80 μg of protein was extracted and analyzed using western blotting (WB). Ultramicro spectrophotometer (NanoDrop 2000; Thermo Fisher Scientific, Inc.) was used to determine the protein concentration, and 10% SDS-PAGE gel (Epizyme, Inc.) was used to concentrate and isolate 80 μg of protein. After using polyvinylidene difluoride to transfer the film, a rapid sealing solution (cat. no. P0220; Beyotime Institute of Biotechology) was used at 20˚C for 15 min. The primary antibodies TAB2 (cat. no. A9867; ABclonal Biotech Co., Ltd.) and β-actin (cat. no. 3700; Cell Signaling Technology, Inc.) were used at a dilution ratio of 1:1,000. The secondary antibodies used were HRP goat anti-rabbit IgG (H+L) (cat. no. AS014; ABclonal Biotech Co., Ltd.), anti-mouse IgG and HRP-linked antibody (cat. no. 7076; Cell Signaling Technology, Inc.) at a dilution ratio of 1:5,000. The WB bands were analyzed using BeyoECL (cat. no. P0018FS; Beyotime Institute of Biotechnology) and ImageJ software (v1.80; National Institutes of Health), and GraphPad Prism 8 (GraphPad Software, Inc.) was used to conduct the statistical analyses and create the figures. Each experiment was repeated thrice. P<0.05 was considered to indicate a statistically significant difference.

WB experiment results showed that the protein expression in the TAB2-WT group was 2.48 times higher compared with that in the blank vector group (NC group) (P=0.0016), whereas no significant difference in the expression was observed in the TAB2-MUT group (P=0.57), indicating that the mutation led to the non-expression of TAB2 (Fig. 2).

Discussion

The present case study investigated a Chinese child with unexplained growth restriction and CHD. The height and weight of the patient in infancy were lower compared with those of his peers; however, his developmental motor milestones did not appear to be abnormal relative to his peers. Until 3-years old, there was obvious growth restriction. In addition, the patient had mild mitral valve prolapse and mild to moderate mitral regurgitation at the age of two. At the age of three, the patient still showed mitral insufficiency and semi moderate regurgitation as determined by color Doppler echocardiography. A novel frameshift mutation of *TAB2*, p.Ser353fsTer8, was discovered through genetic testing. The parents were WT at this locus; thus, the mutation identified may be a *de novo* mutation. *In vitro* function experiments showed that this mutation led to the non-expression of the TAB2 protein, suggesting that the heart structural defects and short stature may be caused by the insufficient haploid dosage of *TAB2*.

So far, to the best of our knowledge, a total of 62 cases related to *TAB2* mutation in 31 families have been reported worldwide (3-6,10-16). The main clinical manifestations of these cases are valve abnormalities (such as valve stenosis and mitral or aortic insufficiency), dilated cardiomyopathy (DCM), connective tissue diseases (such as growth restriction and hyperactivity of joints in children) and abnormal facial features (increased forehead width, wider eye distances, ptosis and lower ear positions). It is worth noting that when CHTD2 is associated with *TAB2* deficiency, it is a non-syndromic CHD by definition (3). However, statistical studies have demonstrated that <30% of affected patients show isolated CHD characteristics (10,11). The clinical phenotype spectrum of CHTD2 patients with the syndrome expressed is not scattered. Excluding cardiac structural abnormalities, the clinical phenotypes are mainly concentrated in connective/skeletal tissue and facial features, with a small sample of patients exhibiting hypotonia and hearing loss (11). The reported *TAB2* mutation is primarily located in exon 2 (NM_015093), and the majority of the mutant types are loss of function mutations, such as nonsense or frameshift mutations (3-6,10-16). The phenotypical differences between individuals appear not to be associated with the mutation sites or types, and carriers within the same family may exhibit different phenotypes. For example, Westphal *et al* (10) reported that both the patient and his father carried the *TAB2* mutation c.878del, but his father did not show physical characteristics. The patient in the present study was initially treated for growth restriction, and no other abnormal manifestations were revealed during the clinical examination, except for cardiac structural abnormalities and very slight facial abnormalities. The results of genetic testing suggested that

CHDT2 is caused by the novel frameshift mutation of *TAB2*. Therefore, multidisciplinary consultation, in conjunction with cardiovascular medicine department is necessary; furthermore, improved methodologies for the growth abnormalities (such as short stature) should also be formulated.

TAB2 is located on autosomal 6q25.1, and the encoded TAB2 protein has 693 amino acids. *TAB2* plays an important role in interleukin-1 signaling pathway and embryonic development of heart tissue (3). Although it is not clear how *TAB2* defects lead to cardiac structural or functional abnormalities mainly involving valves, studies have demonstrated that *TAB2* mutations or copy number deletions lead to insufficient haploid dose, reduce the binding ability with TAK1 (*MAP3K7* coding) or TRAF6 protein, block TAK1 protein activation, lead to NF-κB signal error regulation and slow the necrosis of cardiomyocytes (1,17). In addition to regulating the NF-κB signaling pathway, Yin *et al* (18) proposed a new regulatory mechanism, suggesting that TAB2 protein plays an indispensable role in mediating TAK1-RIPK1 interaction. When the TAB2 protein is deleted, it can promote RIPK1 kinase activation and induce RIPK1 kinase dependent apoptosis by destroying TAK1-RIPK1 interaction. Therefore, different individuals may have early- or late-onset cardiac structure issues or dysfunctions, which may be associated with the activation of TAK1-RIPK1 or the NF-κB signaling pathway regulation mediated by *TAB2* defects.

At present, there is no effective treatment for CHTD2 resulting in individuals with CHD, DCM or cardiac dysfunction. This necessitates targeted treatment for the cause of these diseases. Understanding the pathogenesis of the disease is important for developing treatment strategies. The mechanism of the aforementioned *TAB2*-related cardiac phenotype expression may be caused by promoting the activation of RIPK1 kinase (17,18). Researchers inactivated *Ripk1* in a mouse model with the *TAB2* gene knocked out; this largely reversed the pathological changes, such as severe cardiac contractile dysfunction, ventricular dilatation, and cardiac hypertrophy in mice (18). Inhibiting the RIPK1 protein or regulating the activity of the TAK1-RIPK1 pathway are potential strategies for the treatment of *TAB2*-related cardiac phenotypes (19). However, the effectiveness of growth hormone therapy on *TAB2*-related growth restriction requires further clinical study. The patient mentioned in this case report was treated using growth hormones, but longer-term follow-ups are required to ascertain its therapeutic value.

In summary, the present study reported a Chinese child with atypical facial features, short stature and CHD. The genetic testing results showed that the novel frameshift mutation of *TAB2* caused CHTD2. Functional experiments *in vitro* showed that the mutant p.Ser353fsTer8 may lead to protein non-expression. The current study adds additional information on the *TAB2* mutation spectrum and emphasizes that the occurrence of growth restriction and cardiac disorder may be associated with *TAB2* defects. For patients with confirmed CHTD2, the present study recommends multidisciplinary consultation and regular follow-ups for abnormalities in the growth, development, hearing, vision and connective tissue of the patient. However, the feasibility of using human growth hormone to treat TAB2-related growth restriction still needs to be evaluated.

Acknowledgements

Not applicable.

Funding

The funding for this research was provided by the Scientific Research Fund of Anhui Medical University (grant no. 2019xkj080).

Availability of data and materials

The datasets generated and/or analyzed during the current study are not publicly available due to data privacy considerations but are available from the corresponding author on reasonable request. *TAB2* mutation information from this study has been deposited in the ClinVar database (https://www.ncbi.nlm.nih.gov/clinvar/submitters/508986).

Authors' contributions

DQ, XW and YC designed the experiments. DQ, XW, XX, YW and YZ collected and analyzed the clinical data. XW, JG and YC were responsible for the protein experiments. XX, YW and YZ analyzed the genetic data. JG and YC confirm the authenticity of all the raw data. All authors read and approved the final manuscript.

Ethics approval and consent to participate

The study was conducted according to the guidelines of the World Medical Association (Declaration of Helsinki) and approved by the Ethics Committee of the Children's Hospital of Fudan University Anhui Hospital (approval no. EYLL-2018-020).

Patient consent for publication

The parents of patients looked at in this case signed and provided informed consent for participation in the study.

Competing interests

The authors declare that they have no competing interests.

References

1. Xia ZP, Sun L, Chen X, Pineda G, Jiang X, Adhikari A, Zeng W and Chen ZJ: Direct activation of protein kinases by unanchored polyubiquitin chains. Nature 461: 114-119, 2009.
2. Shim JH, Xiao C, Paschal AE, Bailey ST, Rao P, Hayden MS, Lee KY, Bussey C, Steckel M, Tanaka N, *et al*: TAK1, but not TAB1 or TAB2, plays an essential role in multiple signaling pathways in vivo. Genes Dev 19: 2668-2681, 2005.
3. Thienpont B, Zhang L, Postma AV, Breckpot J, Tranchevent LC, Van Loo P, Møllgård K, Tommerup N, Bache I, Tümer Z, *et al*: Haploinsufficiency of TAB2 causes congenital heart defects in humans. Am J Hum Genet 86: 839-849, 2010.
4. Chen J, Yuan H, Xie K, Wang X, Tan L, Zou Y, Yang Y, Pan L, Xiao J, Chen G and Liu Y: A novel TAB2 nonsense mutation (p.S149X) causing autosomal dominant congenital heart defects: A case report of a Chinese family. BMC Cardiovasc Disord 20: 27, 2020.

5. Ackerman JP, Smestad JA, Tester DJ, Qureshi MY, Crabb BA, Mendelsohn NJ and Ackerman MJ: Whole exome sequencing, familial genomic triangulation, and systems biology converge to identify a novel nonsense mutation in TAB2-encoded TGF-beta activated kinase 1 in a child with polyvalvular Syndrome. Congenit Heart Dis 11: 452-461, 2016.
6. Ritelli M, Morlino S, Giacopuzzi E, Bernardini L, Torres B, Santoro G, Ravasio V, Chiarelli N, D'Angelantonio D, Novelli A, *et al*: A recognizable systemic connective tissue disorder with polyvalvular heart dystrophy and dysmorphism associated with TAB2 mutations. Clin Genet 93: 126-133, 2018.
7. Li H and Durbin R: Fast and accurate short read alignment with Burrows-Wheeler transform. Bioinformatics 25: 1754-1760, 2009.
8. McKenna A, Hanna M, Banks E, Sivachenko A, Cibulskis K, Kernytsky A, Garimella K, Altshuler D, Gabriel S, Daly M and DePristo MA: The Genome Analysis Toolkit: A MapReduce framework for analyzing next-generation DNA sequencing data. Genome Res 20: 1297-1303, 2010.
9. Richards S, Aziz N, Bale S, Bick D, Das S, Gastier-Foster J, Grody WW, Hegde M, Lyon E, Spector E, *et al*: Standards and guidelines for the interpretation of sequence variants: A joint consensus recommendation of the American College of Medical Genetics and Genomics and the Association for Molecular Pathology. Genet Med 17: 405-424, 2015.
10. Westphal DS, Mastantuono E, Seidel H, Riedhammer KM, Hahn A, Vill K and Wagner M: There is more to it than just congenital heart defects-The phenotypic spectrum of TAB2-related syndrome. Gene 814: 146167, 2022.
11. Engwerda A, Leenders EKSM, Frentz B, Terhal PA, Löhner K, de Vries BBA, Dijkhuizen T, Vos YJ, Rinne T, van den Berg MP, *et al*: TAB2 deletions and variants cause a highly recognisable syndrome with mitral valve disease, cardiomyopathy, short stature and hypermobility. Eur J Hum Genet 29: 1669-1676, 2021.
12. Permanyer E, Laurie S, Blasco-Lucas A, Maldonado G, Amador-Catalan A, Ferrer-Curriu G, Fuste B, Perez ML, Gonzalez-Alujas T, Beltran S, *et al*: A single nucleotide deletion resulting in a frameshift in exon 4 of TAB2 is associated with a polyvalular syndrome. Eur J Med Genet 63: 103854, 2020.
13. Vasilescu C, Ojala TH, Brilhante V, Ojanen S, Hinterding HM, Palin E, Alastalo TP, Koskenvuo J, Hiippala A, Jokinen E, *et al*: Genetic basis of severe childhood-onset cardiomyopathies. J Am Coll Cardiol 72: 2324-2338, 2018.
14. Caulfield TR, Richter JE Jr, Brown EE, Mohammad AN, Judge DP and Atwal PS: Protein molecular modeling techniques investigating novel TAB2 variant R347X causing cardiomyopathy and congenital heart defects in multigenerational family. Mol Genet Genomic Med 6: 666-672, 2018.
15. Liu H, Giguet-Valard AG, Simonet T, Szenker-Ravi E, Lambert L, Vincent-Delorme C, Scheidecker S, Fradin M, Morice-Picard F, Naudion S, *et al*: Next-generation sequencing in a series of 80 fetuses with complex cardiac malformations and/or heterotaxy. Hum Mutat 41: 2167-2178, 2020.
16. Hanson J, Brezavar D, Hughes S, Amudhavalli S, Fleming E, Zhou D, Alaimo JT and Bonnen PE: TAB2 variants cause cardiovascular heart disease, connective tissue disorder, and developmental delay. Clin Genet 101: 214-220, 2022.
17. Cheng A, Dinulos MBP, Neufeld-Kaiser W, Rosenfeld J, Kyriss M, Madan-Khetarpal S, Risheg H, Byers PH and Liu YJ: 6q25.1 (TAB2) microdeletion syndrome: Congenital heart defects and cardiomyopathy. Am J Med Genet A 173: 1848-1857, 2017.
18. Yin H, Guo X, Chen Y, Zeng Y, Mo X, Hong S, He H, Li J, Steinmetz R and Liu Q: TAB2 deficiency induces dilated cardiomyopathy by promoting RIPK1-dependent apoptosis and necroptosis. J Clin Invest 132: e152297, 2022.
19. Mifflin L, Ofengeim D and Yuan J: Receptor-interacting protein kinase 1 (RIPK1) as a therapeutic target. Nat Rev Drug Discov 19: 553-571, 2020.