An overview and update of CO_2 laser-assisted sclerectomy surgery in primary open angle glaucoma (Review)

CHUNLIAN HUANG[1,2], XIAO SHEN[1], MIN CHEN[2] and KAIJUN WANG[2]

[1]Department of Ophthalmology, Taizhou Central Hospital, Taizhou University Hospital, Taizhou, Zhejiang 318000; [2]Eye Center of the Second Affiliated Hospital, School of Medicine, Zhejiang University, Hangzhou, Zhejiang 310009, P.R. China

Received September 22, 2022; Accepted March 15, 2023

DOI: 10.3892/etm.2023.11969

Abstract. Glaucoma is the second leading cause of blindness worldwide. The proportion of cases of primary open-angle glaucoma (POAG) in China is gradually increasing. Glaucoma surgery has become more effective, safer, minimally invasive and personalized over the years. CO_2 laser-assisted sclerectomy surgery (CLASS) is a minimally invasive glaucoma treatment. CLASS has recently been used to gradually lower intraocular pressure (IOP) in patients with POAG, pseudocapsular detachment syndrome and secondary glaucoma. In this operation, precise ablation of dry tissue followed by photocoagulation and effective absorption of water and percolating aqueous humor using CO_2 laser are performed, and the IOP is lowered by the laser ablation of the deep sclera and the outer wall of the Schlemm's canal, facilitating the drainage of the aqueous humor. Compared with other filtering surgeries, CLASS has a shorter learning curve, lower technical difficulty and higher safety. The present study reviews the clinical application progress, safety and effectiveness of CLASS.

Correspondence to: Professor Kaijun Wang, Eye Center of the Second Affiliated Hospital, School of Medicine, Zhejiang University, 1 Xihu Boulevard, Hangzhou, Zhejiang 310009, P.R. China
E-mail: ze_wkj@zju.edu.cn

Abbreviations: CLASS, CO_2 laser-assisted sclerectomy surgery; POAG, primary open angle glaucoma; IOP, intraocular pressure; NPDS, Non-penetrating deep sclerectomy; TDM, trabeculo-descemet membrane; MMC, mitomycin C; phaco, phacoemulsification; PAS, peripheral anterior synechia; LPI, laser peripheral iridectomy; ALPI, Argon laser peripheral iridoplasty; LGP, laser goniopuncture laser anterior chamber angle perforation

Key words: CO_2 laser-assisted sclerectomy surgery, non-penetrating deep sclerectomy, primary open-angle glaucoma, intraocular pressure, trabeculectomy

Contents

1. Introduction

Glaucoma is the second leading cause of blindness worldwide (1). Among the cases of glaucoma in China, the proportion of open-angle glaucoma (OAG) gradually increases. IOP is the main factor leading to loss of visual field and optic nerve atrophy (2). The treatment of glaucoma focuses on reducing and controlling IOP through drugs, lasers, or surgery (3).

Trabeculectomy, as a traditional invasive filtering surgery, significantly reduces intraocular pressure (4). However, there are several postoperative complications, including low intraocular pressure, shallow anterior chamber, scarring of filtering bubbles, complicated cataract, endophthalmitis, malignant glaucoma, and even suprachoroidal hemorrhage, which directly affect the success rate of surgery (5). As an alternative filtering surgery, non-penetrating deep sclerectomy (NPDS) reduces IOP by increasing aqueous outflow through a thin trabeculo-descemet window (TDW) into a surgically created scleral lake (6,7). NPDS does not penetrate the anterior chamber, so the incidence of postoperative complications such as low intraocular pressure, shallow anterior chamber, intraocular hemorrhage, and choroidal detachment is significantly reduced, and the safety is higher (8). However, NPDS is difficult to perform and requires advanced surgical techniques (9).

CO_2 laser-assisted sclerectomy surgery (CLASS) is a non-invasive anti-glaucoma surgery assisted by CO_2 laser. CLASS is an optimized approach to non-penetrating deep sclerectomy (NPDS) because it employs a CO_2 laser to ablate the scleral tissue instead of performing a manual procedure. In this surgery, CO_2 laser ablation reduces the intraocular

pressure (IOP) of the deep sclera and the outer wall of the Schlemm's canal, thereby facilitating the drainage of aqueous humor (10,11). Recently, CLASS has been used to gradually lower IOP in patients with Primary Open Angle Glaucoma (POAG), pseudocapsular detachment syndrome, and secondary glaucoma (12-14). CLASS has a shorter learning curve, lower technical demands, and higher safety (15) than other filtering surgeries. Dai *et al* (15) evaluated the effectiveness and safety of CLASS for treating glaucoma by systematically reviewing and meta-analyzing related studies. In our study, we reviewed and updated the CO_2 laser-assisted sclerectomy surgery in primary open-angle glaucoma, highlighted the history, actual procedure, pre/post management, mechanism of IOP-lowering effect, safety, and complications.

2. History of CLASS

As an improved glaucoma filtering surgery, NPDS can effectively reduce the intraocular pressure of OAG (6,7). NPDS, on the other hand, is difficult to perform and necessitates advanced surgical techniques. Perforation of the TDM during operation is a common complication that limits its clinical application to a certain extent.

The efficacy and safety of various types of lasers (16-19), including excimer laser, holmium: YAG laser, and erbium: YAG laser, have been assessed in NPDS. This might help overcome the technical difficulties of NPDS, including the difficulty of the operation and the possibility of intraoperative perforation.

In 2007, Assia *et al* (20) performed non-penetrating deep sclera resection in the eyes of living rabbits and human cadavers using the CO_2 laser. They suggested that the CO_2 laser was the most suitable for NPDS and could simplify the surgical procedure of NPDS due to its precise ablation of the dry tissue, as well as photocoagulation and effective absorption of the micro liquid. In 2012, Ton *et al* (21) performed a similar experiment with an improved CO_2 laser (OT-134 system), which improved the accuracy and safety of the surgery. Then, Geffen *et al* (22) and performed a clinical trial of CLASS. This clinical trial suggested that CLASS may offer a simple, safe, and effective surgical method for the treatment of OAG.

In 2016, Greifner *et al* (23) compared CLASS to traditional NPDS surgery, and the results confirmed that the effect of CLASS was equivalent to that of experienced surgeon-performed NPDS surgery. In 2018, Jankowska-Szmul *et al* (12) reported that the one-year success rate of POAG and exfoliative glaucoma following CLASS was comparable to that of trabeculectomy but with better safety.

CLASS began in China in 2015. In 2016, Yick *et al* (24) reported that the CO_2 laser parameters applicable to the Western population were not entirely applicable to the Chinese population. The difference in laser response made the Chinese population more prone to iris adhesion and scarring after CLASS surgery. Their study also reported that a larger and thicker sclera flap and a deeper sclera pool during the operation helped improve the success rate of CLASS in the Chinese population. In 2018, Yu *et al* (25) combined CLASS with phacoemulsification for the first time. They confirmed that this combination could effectively reduce IOP in the early postoperative stage of POAG with cataracts while reducing the use of IOP-lowering drugs. By combining improved CLASS with preoperative prophylactic iris laser, Zhang and Cheng (26) effectively reduced the incidence of postoperative anterior synechia. Zhang *et al* (14). reported in 2021 that CLASS and trabeculectomy had similar IOP-lowering effects in the treatment of primary open-angle glaucoma, with CLASS being safer.

3. Preoperative assessment

Before CLASS begins, a thorough medical history inquiry and eye examination should be performed. Before surgery, patients should have at least one thorough eye examination. The preoperative IOP ≤30 mmHg (1 mmHg=0.133 kPa) should be maintained. The following are specific conditions: (1) Routine medical history collection and basic ophthalmic examination (27); Evaluate the morphology, thickness, and disease of conjunctiva and sclera in the area to be operated. (2) The anterior chamber angle of the patient shall be evaluated by anterior chamber angle microscopy, ultrasonic biomicroscopy (UBM) or anterior segment OCT(optical coherent tomography), to avoid the operation at the position of anterior chamber angle lesion, anterior chamber angle stenosis or adhesion; (3) Examine the optic nerve and evaluate the visual field.

4. Surgical procedure

CLASS involves the following specific steps and points (14,26,28): (1) Local anesthesia and fixation of the eyeball. (2) Routine opening of the bulbar conjunctiva and fascia bulbi (Tenon's capsule). (3) Shrinking the pupil before or during ablation to avoid iris herniation due to micro-perforation during ablation. (4) The standard size of the sclera flap is 5x5 mm, about 1/3-1/2 sclera thickness; the scleral flap is separated from the front edge to 1 mm inside the transparent cornea, exposing three key anatomical areas of the limbus, including the transparent corneal area, the gray-blue trabecular meshwork zone, and the white sclera area (Fig. 1). (5) Cotton pieces impregnated with mitomycin C (MMC) at a recommended concentration of 0.2-0.4 mg/ml are placed under the conjunctival flap and the shallow sclera flap. If 5-fluorouracil (5-FU) is used, it is recommended to double the duration of exposure. After the removal of the cotton pieces, MMC or 5-FU is rinsed thoroughly. (6) The sclera is ablated by a CO_2 laser to make the scleral cisterna (Fig. 2). It is recommended that the area of the sclera pool should be at least 4x2 mm, with a supporting edge of at least 0.5 mm away from the edge of the sclera flap. The initial ablation energy is recommended to be 21 W, and the rectangular laser is excited perpendicular to the sclera. Ablation to reveal the uveal pigment. (7) MMC at a recommended concentration of 0.2-0.4 mg/ml is placed at the bottom of the deep sclera pool, and the duration of exposure depends on the patient's condition. It is recommended to remove the cotton piece after 30 s to 2 min and rinse it thoroughly. If 5-FU is used, it is recommended to double the stay time. (8) For glaucoma patients with severe optic nerve damage and high IOP (≥30 mmHg) before the ablation of the Schlemm's canal, it is recommended to puncture the lateral incision and slowly reduce the IOP to nearly the normal level to avoid the large difference in filtration pressure after opening the outer wall

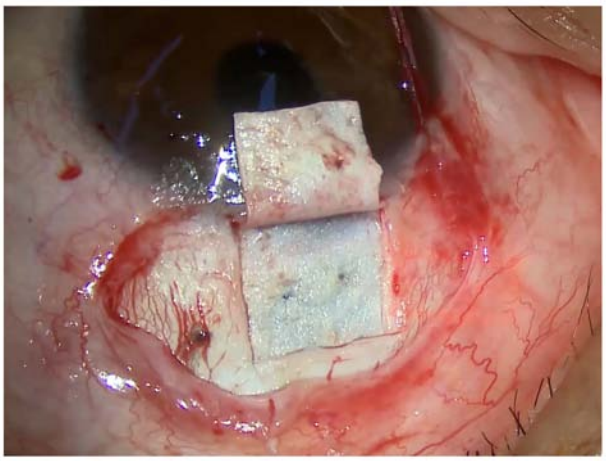

Figure 1. A one-third thickness limbus based 5x5 mm scleral flap was made, and extended by 1 mm into the clear cornea.

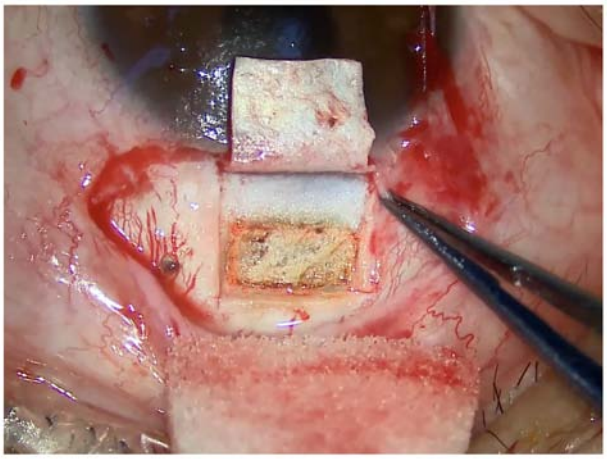

Figure 2. A 4x2 mm scleral lake was created at the posterior scleral bed by the CO_2 laser, with the depth of ~90% scleral thickness.

of the Schlemm's canal, resulting in the rupture of the inner wall of the Schlemm's canal (full-thickness penetration of the ocular wall), or development of a hernia of the iris. (9) Ablation of the outer wall of the Schlemm's canal (Fig. 3). During ablation, the bow aiming at the light front end is aligned with the transparent and gray junction area of the corneal limbus, and the ablation range shall be at least 4 x1.4 mm. Continuous ablation is performed until the outer wall of the Schlemm's canal is opened, and the aqueous humor continues to flow steadily. For patients receiving laser treatment before surgery, it is better if the center of the ablation area of the Schlemm's canal faces the laser hole at the root of the iris (LPI hole) and/or the area of peripheral laser iridoplasty (ALPI area). If the IOP is too low during surgery, water injection in the anterior chamber is needed to increase the IOP and observe the outflow of aqueous humor after ablation of the Schlemm's canal. (10) Reduction of the scleral flap is performed using a fixed suture, adjustable suture, or no suture to sew the conjunctival incision.

The operation picture of Figs. 1-3 was from the screenshot of the operation video of a 31-year-old male patient, on May 21, 2021, at the Second Affiliated Hospital of Zhejiang University School of Medicine. The surgical procedures shown in

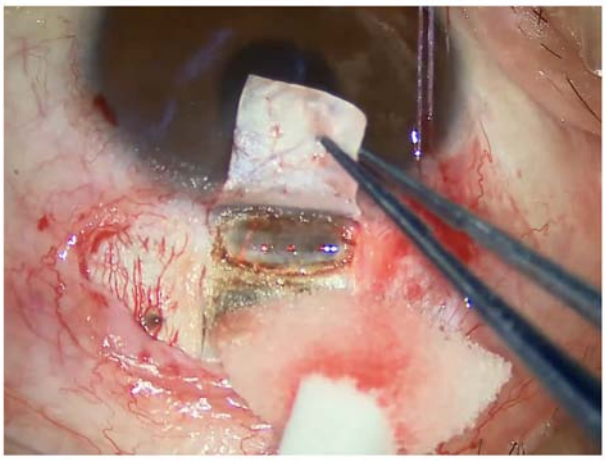

Figure 3. CO_2 laser beam was applied to ablate the outer wall of the Schlemm's canal and the trabecular meshwork, ~4x1.4 mm, until a continuous fluid percolation was observed.

Figs. 1-3 correspond to standard clinical practice, refer to the consensus of experts in the operation of CLASS (China, 2021).

5. Postoperative management

Tobramycin and dexamethasone eye drops were used four times per day for 1 month to reduce inflammation and prevent infection following CLASS. Piloneurtin eye drops were used to reduce pupil size and prevent PAS after surgery (26). Specific drug concentrations and frequencies should be adjusted based on the patient's condition, and medication should be taken for at least 3 months. Routine examinations were performed 1 day, 2 weeks, 1 month, 3 months, and 6 months postoperatively to assess visual acuity, IOP, the morphology of filtering blebs, and scleral cisterna volume. The anterior chamber angle was examined at the 2-week postoperative follow-up to detect early peripheral anterior iris adhesion. In contrast, ultrasonic biological microscopy or anterior segment OCT was used to understand the scleral cisternal morphology. If there are any complications, the number of follow-up examinations should be increased appropriately. If there are any abnormalities in the operated eyes, a doctor should be consulted as soon as possible. After surgery, the patient should avoid pressing the eyeball (including massage) or severely coughing, as these actions may rupture the inner wall of the TDM and the Schlemm's canal, resulting in iris entrapment (14,29).

The following are the key points of management within 6 months of surgery: (1) Most patients' IOP on the first day after surgery should be <10 mmHg. If the IOP is >14 mmHg, we should look for the source and eliminate it (26); (2) IOP can reach a peak 2-4 weeks after surgery. When the IOP is >21 mmHg, it is recommended to check the anterior chamber angle and scleral pool. If the anterior chamber angle and scleral pool are normal, the patient should be monitored for 6 weeks after surgery (24); If the IOP is still >21 mmHg 6 weeks after surgery and/or there is a significantly shrunk scleral pool, it is recommended that an LGP treatment be performed first (30). If the effect of LGP is not good or the scleral cisterna are at risk of disappearing, it is recommended to administer a 5-FU injection under the scleral flap or conjunctiva (31); (3)

When there is a risk of the scleral cisterna disappearing, the scleral flap should first be needled, and anti-metabolic drugs be injected (31). If the scleral cisterna is unobstructed and the IOP is >21 mmHg, laser goniopuncture (LGP) is recommended (30); (4) If peripheral anterior adhesion is observed after surgery, it should be handled in time and laser peripheral iridectomy (LPI) or Argon laser peripheral iridoplasty (ALPI) is feasible in the early stage (32); (5) LGP is a beneficial complementary treatment after CLASS (30,33); (6) For patients with iris incarceration, it is recommended to perform an internal surgery first, and trabeculectomy is not recommended.

Patients with Asian glaucoma, including Chinese patients, have a crowded anterior chamber structure, intractable high IOP, and postoperative scarring (34). Domestic researchers Zhang and Cheng (26) performed laser peripheral iridectomy and/or laser peripheral iridoplasty during the perioperative period and found that the incidence of PAS was significantly reduced after laser treatment. The consensus of Chinese CLASS experts suggests that LPI and/or ALPI laser treatment should be performed in the center of the ablated Schlemm's canal undergoing surgical ablation from 48 h before surgery to 1 week after surgery for high-risk patients who are prone to local adhesion of the anterior chamber corner (including but not limited to patients with iris hypertrophy, relaxation, and shallow anterior chamber). Thermal injury to the tissue surrounding the ablated area following surgery may result in local inflammation and adhesion (14). In addition to early postoperative local anti-inflammatory therapy, postoperative scarring of the filter channel should be detected and treated as soon as possible (using LGP, followed by needle dial filter bubble and subconjunctival injection of anti-metabolic drugs) (35,36).

6. Efficacy outcomes

CLASS. CLASS has been shown in some domestic and international studies to be effective and safe in the treatment of POAG (15,37) Table I summarizes long-term CLASS outcomes from published studies. The CS rate ranges from 45.5 to 67.9% at 12 M and from 34.1 to 73.0% at 24 M. The QS rate ranges from 69.2 to 93.1% at 12 M and from 76.9 to 96.0% at 24 M.

Ton *et al* (21) were the first to conduct a multicenter clinical study of CLASS, with a 12-month follow-up of 30 patients across three continents. The results indicated that the average IOP of patients decreased by 42.4 and 40.7% at 6 and 12 months after surgery, respectively (P<0.001). The average number of IOP-lowering drugs decreased from 2.5 before surgery to 0.1 and 0.6 after surgery, with a complete success rate of 76.7 and 60%, respectively. The conditional success rates were 83.3 and 86.6%, respectively, which indicated the short-term effectiveness and safety of CLASS in patients with POAG and pseudo-exfoliative glaucoma. Based on previous research, Geffen *et al* (11) published an open-ended study involving seven countries and nine medical centers (22) in 2016, which included more patients with POAG and pseudo-exfoliative glaucoma and completed a three-year follow-up record. The results also indicated a good IOP-lowering effect. At the same time, compared with the non-MMC group, the complete success rates of the two groups at 24 and 36 months were 62 and 0% (P=0.03) and 52 and 0% (P=0.14), respectively, while the qualified success rates were 91 and 80% (P=0.97) and 86 and 75% (P=0.87), respectively. The results indicated that the MMC group had a higher complete success rate at both 24 and 36 months postoperatively compared to the non-MMC group. In 2016, Yick *et al* (24) published the first study on the use of CLASS in Chinese patients with late glaucoma, which preliminary confirmed the effectiveness of CLASS surgery in the Chinese population.

CLASS vs. Trabeculectomy. CLASS has fewer complications, faster recovery from visual acuity, and comparable IOP-lowering effects when compared to traditional trabeculectomy (12,14,29). In 2018, Jankowska-Szmul *et al* (12) compared CLASS to traditional trabeculectomy. They found that, while the complete success rate of CLASS was lower, the qualified success rate was roughly equivalent, with fewer postoperative complications, fewer corneal endothelium losses, and less impact on astigmatism. Therefore, CLASS may be more suitable for early glaucoma patients or patients with less corneal endothelium. Zhang *et al* (14). compared the effectiveness and safety of CLASS and Trab in the treatment of POAG. The findings demonstrated that CLASS was an effective and safe treatment for POAG. The effect of lowering intraocular pressure was comparable to Trab. There were fewer complications associated with filtering blebs after surgery, and early postoperative visual recovery was faster. Zhang *et al* (28). compared the long-term effects of modified CO_2 laser-assisted sclerectomy (MCLASS) and Trab on IOP control in POAG patients. The intraocular pressure and types of glaucoma drugs used in the MCLASS group were significantly lower compared to the two groups at 24 and 36 months after surgery, and the complete and qualified success rates of the two groups were not significantly different. In contrast, the overall complication rate of the Trab group was significantly higher.

CLASS combined with phacoemulsification. In 2018, Yu *et al* (25) reported on the effect of CLASS combined with cataract phacoemulsification (phaco). For the first time, Yu *et al* (25) combined CLASS with phacoemulsification. They confirmed that this combination could effectively reduce IOP in the early postoperative stage of the treatment of POAG with cataracts while also reducing the use of IOP-lowering drugs. In the same year, Villavicencio *et al* (37) compared the surgical effects of CLASS surgery combined with phaco (33 cases) and trabeculectomy combined with phaco (37 cases) for OAG. They found that CLASS was superior to trabeculectomy in controlling IOP, improving vision, and reducing medication and postoperative complications in the case of combined phaco. In 2021, Ho *et al* (13) demonstrated that CLASS with or without phacoemulsification was at least as simple, safe, and effective in the short and medium term, implying that combined surgery should be the first choice for cataract patients. In our previous study (38), we reported the CLASS approach alone achieved a greater IOP reduction, more common functional bleb formation, and a higher success rate compared to CLASS combined with Phaco, while combination surgery yielded a better best-corrected visual acuity (BCVA) improvement and a lower PAS incidence than

Table I. Comparison of long-term outcomes of CLASS among published studies.

No.	First author	Year	Population	N (eye)	Surgery	PAS incidence (%)	Iris incarceration (%)	Complete success rate (%)			Qualified success rate (%)		
								6 M	12 M	24 M	6 M	12 M	24 M
1	Geffen *et al* (22)	2010	Mixed	37	CLASS	0.0	0.0	76.7	60.0		83.3	86.6	
2	Greifner *et al* (23)	2014	Caucasian	27	CLASS	0.0	48.0			73.0			96.0
3	Skaat *et al* (52)	2014	Caucasian	15	CLASS	0.0	6.7		45.5			90.9	
4	Geffen *et al* (11)	2016	Mixed	97	CLASS	5.6	8.3		60.2	57.9		79.6	91.2
5	Yick *et al* (24)	2016	Chinese	23	CLASS	0.0	0.0				81.8		
6	Cutolo *et al* (51)	2017	Caucasian	21	CLASS	9.5	14.3						
7	Jankowska-Szmul *et al* (12)	2018	Caucasian	66	CLASS	0.0	4.5		35.0			74.0	
8	Zhang and Cheng (26)	2020	Chinese	25	Modified CLASS	6.9	0.0		62.1	48.3		89.7	89.7
9	Sohajda *et al* (53)	2020	Caucasian	22	CLASS	0.0	0.0	72.7	64.0		77.0	72.7	
10	Yan *et al* (40)	2020	Chinese	28	CLASS	10.7	0.0	71.4	67.9	64.3	92.9	85.7	85.7
11	Zhang *et al* (14)	2021	Chinese	30	CLASS	30.0	6.7	82.8	58.6	51.7	100.0	93.1	86.2
12	Ho *et al* (13)	2021	Asian	13	CLASS	0.0	0.0	41.5	41.5	34.1	48.8	69.2	76.9
13	Chen *et al* (36)	2021	Chinese	21	CLASS	73.9	4.3		69.8			95.7	

CLASS, CO_2 laser-assisted sclerectomy surgery; PAS, peripheral anterior synechiae; Phaco, phacoemulsification; M, months.

CLASS alone. Both surgical strategies have shown favorable safety and efficacy among POAG patients. Besides, combined surgery could be a viable option for patients with co-existing POAG and cataracts.

Table II summarizes 1-year outcomes of CLASS combined with or without Phaco among published studies. These studies have confirmed that this combination could effectively reduce IOP in the postoperative stage of the treatment of POAG with cataracts.

7. Mechanism of IOP-lowering effect

The mechanism of IOP reduction after NPDS is complicated. There may be several aqueous humor drainage pathways, including subcon junctival bleb, trabecular meshwork, intra-scleral outflow and suprachoroidal outflow (39). It has been reported that the subconjunctival and suprachoroidal pathway may be the main mechanisms to achieve IOP reduction after CLASS (40).

Consensus eludes about the role of filtering bubbles in maintaining IOP after CLASS. In a study conducted by Judyta and Edward (41), the clinical grading scale and OCT were used to assess the morphological manifestations of CLASS filter bubbles following surgery. The results indicated that the presence of the filtering blebs was also important for maintaining intraocular pressure after CLASS. Consensus eludes about the role of filtering bubbles in maintaining IOP after CLASS. However, another published research reported that all patients following deep sclerectomy with collagen implant (DSCI) and mitomycin C (MMC)had flat filtering blebs, suggesting that there was no obvious relationship between intraocular pressure and filtering bleb (42).

According to some published reports, the long-term stability of the scleral cistern is critical to the success of this type of surgery (26,40). Regarding the imaging manifestations of NPDS scleral cistern, some studies have found that postoperative intraocular pressure was negatively correlated with scleral cistern height (42,43). The collapse of the scleral cistern has been linked to poor control of IOP (44,45). However, Other studies have found no correlation between the size of the scleral cistern and the decrease in IOP (41,46,47). Chihara and Hayashi (47) proposed that the presence of a scleral cistern could facilitate aqueous humor drainage to the subconjunctival and suprachoroidal cavities via the Schlemm's canal and trabecular meshwork opening, the gap between the scleral flap and the scleral bed, or scleral pressure conduction. Judyta and Edward (41) proposed that without combined implants and MMC, the size and height of the scleral cistern would significantly decrease over time and that there was no significant correlation between the size of the scleral cistern and the decrease of IOP.

Presently, the mechanism of the postoperative drainage of aqueous humor to the suprachoroidal space through the scleral cisterna remains controversial. Based on long-term clinical results, Park *et al* (48) and Chihara and Hayashi (47) concluded that the mechanism of IOP reduction by CLASS was more dependent on scleral cisterna infiltration into the suprachoroidal space rather than scleral valve infiltration into the subconjunctiva. Some researchers believe that if this mechanism is correct, the area of fluid reflux will be

Table II. Summary of 1 year outcomes of CLASS combined with or without Phaco amongst published studies.

No.	First author	Year	Population	Surgery	N (eye)	Baseline IOP (mmHg)	IOP reduction %	Medication decrease %	PAS (%)	LGP (%)	CS (%)	QS (%)
1	Yu *et al* (25)	2018	Chinese	CLASS + Phaco	17	23.9±8.6	39	70	0	0	65	88
2	Villavicencio *et al* (37)	2018	Caucasian	CLASS + Phaco	33	29.5±3.7	45.2	-	0	33.3	-	97.2
				Trab + Phaco	37	17.0±5.8	37.7	-	0	0	-	86.4
3	Ho *et al* (13)	2021	Asian	CLASS	13	20.3	40.6	-	-	-	41.5	69.2
				CLASS + Phaco	28	16.8	6.7	-	-	-	-	46.4
4	Raja *et al* (54)	2021	Indian	Trab + Phaco	18	15.7±3.2	-	-	-	-	100	100
				CLASS + Phaco	18	17.2±5.3	-	-	-	-	85.7	92.3
5	Chen *et al* (38)	2022	Chinese	CLASS	23	31.0±10.0	54.5	91.3	0-47.8	30.4	60.9	87
				CLASS + Phaco	23	19.8±6.5	26.2	85	0-8.7	34.8	26.1	32.5

CLASS, CO_2 laser-assisted sclerectomy surgery; Phaco, phacoemulsification; Trab, trabeculectomy; IOP, intraocular pressure; PAS, peripheral anterior synechia; LGP, YAG laser goniopuncture; CS, complete success; QS, qualified success.

directly proportional to the size of the postoperative sclera cistern, influencing IOP reduction. Other scholars believe that the hydrostatic pressure of the suprachoroidal cavity is 0.8-4.7 mmHg lower than that of the anterior chamber, and this pressure may form a driving force. However, because the scleral cisterna only serves as a reservoir, the size of the scleral cisterna has no effect on the decrease of IOP (49).

8. Safety and complications

Theoretically, CLASS is safe and accurate under controllable laser ablation: (1) CO_2 laser can effectively ablate the dry tissue and be absorbed by traces of liquid. Using this principle, CLASS surgery can efficiently ablate the deep sclera and the outer wall of the Schlemm's canal, completely preserve the inner wall of the Schlemm's canal and the trabecular meshwork, ensure that the anterior chamber is not penetrated, and reduce the occurrence of complications such as the shallow anterior chamber, anterior chamber hemorrhage, and secondary concurrent cataract (23,50). (2) During surgery, precise ablation of the sclera tissue can be achieved by accurately controlling energy and adjusting the size of the area of sclera ablation, which greatly reduces the difficulty of the operation and effectively reduces the operation time (11). (3) The aqueous humor is drained into the scleral pool for absorption, which avoids the problems of scarring and rupture infection caused by drainage through the filtration bubble. Further, because most of the aqueous humor is slowly and evenly absorbed from the suprachoroidal cavity, only a small part of the aqueous humor flows into the conjunctiva, which makes the filtered bubbles relatively flat and diffuse. Thus, meeting the patient's postoperative requirements for eye comfort and appearance. (4) CLASS surgery benefits from the fact that the CO_2 laser is completely absorbed by the liquid. The aqueous humor flowing out of the Schlemm's canal can absorb ablation energy, reducing postoperative fibrosis and tissue adhesion by minimizing thermal damage at the bottom of the ablated tissue. (5) Trabeculectomy can be converted at any time if TDM penetrates during the operation.

CLASS complications include, among other things, peripheral anterior synechia (PAS), iris incarceration, scleral pool collapse, shallow anterior chamber, and choroidal detachment (23). The three main causes of elevated IOP after CLASS (36) are PAS, iris incarceration, and scleral cisterna collapse. According to the literature, the incidence of PAS and iris incarceration after CLASS is relatively high, which is the primary cause of postoperative IOP (23) recurrence. The incidence of PAS in Chinese patients was relatively high when compared to white patients. Jankowska-Szmul *et al* (12) reported an incidence of PAS in only 3.0% of the patients, while Cutolo *et al* (51) reported an incidence of 9.5%, both were far lower than the 30.0% incidence reported by Zhang *et al* (14) Table I summarizes the incidence of PAS and iris incarceration in published studies. Inadequate aqueous humor infiltration due to scleral pool collapse is another cause of postoperative IOP elevation. The key to improving the long-term efficacy of CLASS is the analysis and judgment of the causes of IOP increase with time after CLASS, followed by taking the corresponding intervention and treatment measures.

9. Conclusion

Over the years, the surgical treatment of glaucoma has become more effective, safer, minimally invasive, and more personalized. Although CLASS has several advantages, it still has many limitations: (1) It is only applicable to OAG, and the potential of combining it with other surgical methods to treat refractory glaucoma needs further exploration. (2) The occurrence of PAS is highly likely after CLASS, which makes it necessary to follow up closely for its timely detection and treatment. (3) Compared to trabeculectomy, CLASS is more expensive. CLASS surgery is superior to trabeculectomy in the incidence of early postoperative complications, the protection of corneal endothelium, and the feasibility of reoperation. Its long-term clinical effect still needs confirmation by long-term, multicenter, large-sample, randomized controlled studies.

Acknowledgements

Not applicable.

Funding

No funding was received.

Availability of data and materials

The datasets used and/or analyzed during the current study are available from the corresponding author on reasonable request.

Authors' contributions

CH and XS collected and arranged the references, and drafted and revised the manuscript. MC and KW provided guidance and revised the paper. All authors have made a substantial contribution to the work. All authors have read and approved the final manuscript. Data authentication is not applicable.

Ethics approval and consent to participate

The study involving human participants was reviewed and approved by Ethics Committee of the Second Affiliated Hospital of Zhejiang University (approval no. 2020-ER721). Written informed consent was obtained from all the subjects prior to participation and for publication of the accompanying images in this study. The study was performed in accordance with the Helsinki Declaration of 1964 and its later amendments.

Patient consent for publication

Written informed consent was obtained from the subject prior to participation and for publication of the accompanying images in this study.

Competing interests

The authors declare that they have no competing interests.

References

1. Quigley HA: Glaucoma. Lancet 377: 1367-1377, 2011.
2. Zhang N, Wang J, Li Y and Jiang B: Prevalence of primary open angle glaucoma in the last 20 years: A meta-analysis and systematic review. Sci Rep 11: 13762, 2021.
3. Schuster AK, Erb C, Hoffmann EM, Dietlein T and Pfeiffer N: The diagnosis and treatment of glaucoma. Dtsch Arztebl Int 117: 225-234, 2020.
4. Hoffmann EM, Hengerer F, Klabe K, Schargus M, Thieme H and Voykov B: Glaucoma surgery today. Ophthalmologe 118: 239-247, 2021 (In German).
5. Jampel HD, Solus JF, Tracey PA, Gilbert DL, Loyd TL, Jefferys JL and Quigley HA: Outcomes and bleb-related complications of trabeculectomy. Ophthalmology 119: 712-722, 2012.
6. Hondur A, Onol M and Hasanreisoglu B: Non-penetrating glaucoma surgery: Meta-analysis of recent results. J Glaucoma 17: 139-146, 2008.
7. Cheng JW, Cheng SW, Cai JP, Li Y and Wei RL: Systematic overview of the efficacy of non penetrating glaucoma surgery in the treatment of open angle glaucoma. Med Sci Monit 17: RA155-RA163, 2011.
8. Slagle G, Groth SL, Montelongo M and Sponsel WE: Non-penetrating deep sclerectomy for progressive glaucoma: Long-term (5-year) follow-up of intraocular pressure control and visual field survival. J Curr Glaucoma Pract 14: 3-9, 2020.
9. Elhofi A and Helaly HA: Non-penetrating deep sclerectomy versus trabeculectomy in primary congenital glaucoma. Clin Ophthalmol 14: 1277-1285, 2020.
10. Geffen N, Assia EI and Melamed S: Laser-Assisted techniques for penetrating and non-penetrating glaucoma surgery. Dev Ophthalmol 59: 100-112, 2017.
11. Geffen N, Mimouni M, Sherwood M and Assia EI: Mid-term clinical results of CO_2 laser-assisted Sclerectomy Surgery (CLASS) for open-angle glaucoma treatment. J Glaucoma 25: 946-951, 2016.
12. Jankowska-Szmul J, Dobrowolski D and Wylegala E: CO_2 laser-assisted sclerectomy surgery compared with trabeculectomy in primary open-angle glaucoma and exfoliative glaucoma. A 1-year follow-up. Acta Ophthalmol 96: e582-e591, 2018.
13. Ho DCW, Perera SA, Hla MH and Ho CL: Evaluating CO_2 laser-assisted sclerectomy surgery with mitomycin C combined with or without phacoemulsification in adult Asian glaucoma subjects. Int Ophthalmol 41: 1445-1454, 2021.
14. Zhang H, Tang Y, Yan X, Ma L, Geng Y, Li F and Tang G: CO_2 laser-assisted deep sclerectomy surgery compared with trabeculectomy in primary open-angle glaucoma: Two-year results. J Ophthalmol 2021: 6639583, 2021.
15. Dai L, Li AL, Yu L and Ye J: Reply: Efficacy and safety of CO_2 laser-assisted sclerectomy surgery for glaucoma: A systematic review and meta-analysis. Arq Bras Oftalmol 84: 418-420, 2021.
16. Argento C, Sanseau AC, Badoza D, Casiraghi J: Deep sclerectomy with a collagen implant using the excimer laser. J Cataract Refract Surg 27: 504-506, 2001.
17. Klink T, Lieb W and Grehn F: Erbium-YAG laser-assisted preparation of deep sclerectomy. Graefes Arch Clin Exp Ophthalmol 238: 792-796, 2000.
18. Schuman JS, Chang W, Wang N, de Kater AW and Allingham RR: Excimer laser effects on outflow facility and outflow pathway morphology. Invest Ophthalmol Vis Sci 40: 1676-1680, 1999.
19. Traverso CE, Murialdo U, Di Lorenzo G, Venzano D, De Palma G, Gandolfo E, Calabria GA and Zingirian M: Photoablative filtration surgery with the excimer laser for primary open-angle glaucoma: A pilot study. Int Ophthalmol 16: 363-365, 1992.
20. Assia EI, Rotenstreich Y, Barequet IS, Apple DJ, Rosner M and Belkin M: Experimental studies on non-penetrating filtration surgery using the CO_2 laser. Graefes Arch Clin Exp Ophthalmol 245: 847-854, 2007.
21. Ton Y, Geffen N, Kidron D, Degani J and Assia EI: CO_2 laser-assisted sclerectomy surgery part I: Concept and experimental models. J Glaucoma 21: 135-140, 2012.
22. Geffen N, Ton Y, Degani J and Assia EI: CO_2 laser-assisted sclerectomy surgery, Part II: Multicenter clinical preliminary study. J Glaucoma 21: 193-198, 2012.
23. Greifner G, Roy S and Mermoud A: Results of CO_2 laser-assisted deep sclerectomy as compared with conventional deep sclerectomy. J Glaucoma 25: e630-e638, 2016.
24. Yick DWF, Lee JWY, Tsang S, Yeung BYM and Yuen CYF: Preliminary results of CO_2 laser-assisted sclerectomy surgery (CLASS) in the treatment of advanced glaucoma in a Chinese population. Medicine (Baltimore) 95: e5294, 2016.
25. Yu X, Chen C, Sun M, Dong D, Zhang S, Liu P, Yuan R and Ye J: CO_2 laser-assisted deep sclerectomy combined with phacoemulsification in patients with primary open-angle glaucoma and cataract. J Glaucoma 27: 906-909, 2018.
26. Zhang Y and Cheng G: Modified CO_2 laser-assisted sclerectomy surgery in Chinese patients with primary open-angle glaucoma and pseudoexfoliative glaucoma: A Two-year follow-up study. J Glaucoma 29: 367-373, 2020.
27. Prum BE Jr, Rosenberg LF, Gedde SJ, Mansberger SL, Stein JD, Moroi SE, Herndon LW Jr, Lim MC and Williams RD: Primary open-angle glaucoma Preferred Practice Pattern(®) Guidelines. Ophthalmology 123: P41-P111, 2016.
28. Zhang Y, Mao J, Zhou Q, Li L, Zhang S, Bian A and Cheng G: Comparison of long-term effects after modified CO_2 laser-assisted deep sclerectomy and conventional trabeculectomy in chinese primary open-angle glaucoma. Ophthalmol Ther 11: 321-331, 2022.
29. Bettin P and Di Matteo F: Postoperative management of penetrating and non-penetrating external filtering procedures. Dev Ophthalmol 59: 53-66, 2017.
30. Shaarawy T, Mansouri K, Schnyder C, Ravinet E, Achache F and Mermoud A: Long-term results of deep sclerectomy with collagen implant. J Cataract Refract Surg 30: 1225-1231, 2004.
31. Heuer DK, Parrish RK II, Gressel MG, Hodapp E, Palmberg PF and Anderson DR: 5-fluorouracil and glaucoma filtering surgery: II. A pilot study. Ophthalmology 91: 384-394, 1984.
32. Romano JH, Hitchings RA and Pooinasawmy D: Role of Nd:YAG peripheral iridectomy in the management of ocular hypertension with a narrow angle. Ophthalmic Surg 19: 814-816, 1988.
33. Mermou A, Karlen ME, Schnyder CC, Sickenberg M, Chiou AG, Hédiguer SE and Sanchez E: Nd:Yag goniopuncture after deep sclerectomy with collagen implant. Ophthalmic Surg Lasers 30: 120-125, 1999.
34. Lee RY, Chon BH, Lin SC, He M and Lin SC: Association of ocular conditions with narrow angles in different ethnicities. Am J Ophthalmol 160: 506-515. e1, 2015.
35. Xin Z, Chen J, Wang D, Wu X and Han Y: CO_2 laser-assisted sclerectomy surgery in the treatment of open-angle glaucoma in Chinese patients. Eur J Ophthalmol: Jan 12, 2022 (Epub ahead of print).
36. Chen M, Gu Y, Yang Y, Zhang Q, Liu X and Wang K: Management of intraocular pressure elevation after CO_2 laser-assisted sclerectomy surgery in patients with primary open-angle glaucoma. Front Med (Lausanne) 8: 806734, 2021.
37. Villavicencio JCI, Baltodano FPQ, Ramirez Jimenez IM, Mendez ALG, Ponte-Davila MC: Comparative clinical results of phacoemulsification combined with CO_2 Laser-Assisted Sclerectomy vs. Phacoemulsification combined with trabeculectomy in patients with open-angle glaucoma. J Clin Exp Ophthalmol 9: 5, 2018.
38. Chen M, Yu N, Huang C, Zhang Q, Liu X and Wang K: CO_2 Laser-Assisted sclerectomy surgery alone or combined with phacoemulsification in primary open-angle glaucoma: Comparison of 1-year outcomes. Ophthalmol Ther 11: 1719-1733, 2022.
39. Johnson DH and Johnson M: Glaucoma surgery and aqueous outflow: How does nonpenetrating glaucoma surgery work? Arch Ophthalmol 120: 67-70, 2002.
40. Yan X, Zhang H, Li F, Ma L, Geng Y and Tang G: Surgical site characteristics after CLASS followed by ultrasound biomicroscopy and clinical grading scale: A 2-year follow-up. Eye (Lond) 35: 2283-2293, 2021.
41. Jankowska-Szmul J and Wylegala E: The CLASS surgical site characteristics in a clinical grading scale and anterior segment optical coherence tomography: A one-year follow-up. J Healthc Eng 2018: 5909827, 2018.
42. Mavrakanas N, Mendrinos E and Shaarawy T: Postoperative IOP is related to intrascleral bleb height in eyes with clinically flat blebs following deep sclerectomy with collagen implant and mitomycin. Br J Ophthalmol 94: 410-413, 2010.
43. Fernández-Buenaga R, Rebolleda G, Casas-Llera P, Muñoz-Negrete FJ and Pérez-López M: A comparison of intrascleral bleb height by anterior segment OCT using three different implants in deep sclerectomy. Eye (Lond) 26: 552-556, 2012.

44. Roters S, Lüke C, Jonescu-Cuypers CP, Engels BF, Jacobi PC, Konen W and Krieglstein GK: Ultrasound biomicroscopy and its value in predicting the long term outcome of viscocanalostomy. Br J Ophthalmol 86: 997-1001, 2002.
45. Chihara E, Okazaki K, Takahashi H, Shoji T, Adachi H and Hayashi K: Modified deep sclerectomy (D-lectomy MMC) for primary open-angle glaucoma: Preliminary results. J Glaucoma 18: 132-139, 2009.
46. Khairy HA, Atta HR, Green FD, van der Hoek J and Azuara-Blanco A: Ultrasound biomicroscopy in deep sclerectomy. Eye (Lond) 19: 555-560, 2005.
47. Chihara E and Hayashi K: Relation between the volume of the lake and intraocular pressure reduction after nonfiltering glaucoma surgery: A spectral-domain anterior segment optical coherence tomography study. J Glaucoma 20: 497-501, 2011.
48. Park M, Tanito M, Nishikawa M and Chihara E: Ultrasound biomicroscopy of intrascleral lake after viscocanalostomy and cataract surgery. J Glaucoma 13: 472-478, 2004.
49. Emi K, Pederson JE and Toris CB: Hydrostatic pressure of the suprachoroidal space. Investig Ophthalmol Vis Sci 30: 233-238, 1989.
50. Gedde SJ, Schiffman JC, Feuer WJ, Herndon LW, Brandt JD and Budenz DL; Tube Versus Trabeculectomy Study Group: Three-Year Follow-up of the Tube Versus Trabeculectomy Study. Am J Ophthalmol 148: 670-684, 2009.
51. Cutolo CA, Bagnis A, Scotto R, Bonzano C and Traverso CE: Prospective evaluation of CO_2 laser-assisted sclerectomy surgery (CLASS) with Mitomycin C. Graefes Arch Clin Exp Ophthalmol 256: 181-186, 2018.
52. Skaat A, Goldenfeld M, Cotlear D and Melamed S: CO_2 laser-assisted deep sclerectomy in glaucoma patients. J Glaucoma 23: 179-184, 2014.
53. Sohajda Z, Széll N, Revák Á, Papp J and Tóth-Molnár E: Retinal nerve fibre layer thickness change after CO_2 laser-assisted deep sclerectomy surgery. Clin Ophthalmol 14: 1749-1757, 2020.
54. Raja SV, Ponnat AK, Balagiri K and Pallamparthy S: Retrospective analysis of the comparison between carbon dioxide laser-assisted deep sclerectomy combined with phacoemulsification and conventional trabeculectomy with phacoemulsification. Indian J Ophthalmol 69: 2741-2745, 2021.