Malignant behavior of a well-differentiated digestive neuroendocrine tumor with peritoneal carcinomatosis: A case report

KLARA WYFFELS[1], CHARLOTTE DE WILDE[2], JACQUES VAN HUYSSE[3] and VINCENT DE WILDE[1]

Departments of [1]Gastroenterology, [2]Radiology and [3]Anatomopathology, AZ Sint-Jan, 8000 Bruges, Belgium

Received November 8, 2022; Accepted March 15, 2023

DOI: 10.3892/etm.2023.11982

Abstract. Neuroendocrine neoplasms (NENs) are a heterogenous group of tumors, arising from enterochromaffin cells, with different biological and clinical characteristics. Well-differentiated Grade 1 (G1) small intestinal NENs are often characterized by a slow progression rate and a good prognosis. Peritoneal carcinomatosis of a G1 digestive NEN is not a very common finding, and thus there is little published evidence regarding its progression and management. The complex, multistage interplay between the peritoneum and the metastasizing neuroendocrine cells is not well understood, and a reliable predictive tool to identify these patients earlier in their disease course is lacking. The present study describes the case of a 68-year-old woman presenting with an oligosymptomatic, stage IV, small intestinal G1 NEN (pTxpN1pM1) with synchronous liver metastases, multifocal mesenteric tumor deposits and a low Ki67 labeling index (1%). Over a period of 15 months, the patient developed rapidly progressive peritoneal metastatic disease with repetitive self-limiting obstructive symptoms and eventually succumbed to her illness. The present case report discusses the potential relationship between low-grade NEN, location of the primary tumor and the metastatic site, and also speculates on the role of the underlying subcellular mechanisms, specific micro-environment, spreading modalities and therapeutic strategy.

Introduction

NENs are a heterogeneous group of tumors arising from enterochromaffin cells, being multipotent stem cells that migrate from the neural crest to the gut ectoderm (1). The most common primary sites are the gastro-intestinal and respiratory tract. Due to its heterogeneity, these tumors exhibit diverse clinical and biological characteristics (2). Grade, largely based on Ki67 proliferation index, has proven to be a powerful prognostic indicator. Apart from grade, stage, with referral to size, depth of invasion and metastatic status, has a prognostic value as well (2).

Small intestinal neuroendocrine tumors (siNENs) represent the fastest growing cohort of gastroenteropancreatic NENs (3). Well-differentiated siNENs in general behave more indolently but nevertheless tend to metastasize, with preference to the liver (4). The peritoneum is reportedly the third most common site of metastasis after the liver and lymph nodes (5). Peritoneal metastasis, but not hepatic metastasis alone, is associated with shorter disease-specific survival (6). The combination of aggressive behavior and a confirmed very low Ki67 index in siNEN is speculative.

Case report

A 68-year-old Caucasian female, with no remarkable medical history, presented herself at AZ Sint-Jan (Bruges, Belgium) in April 2017. She was referred to us because of altered defecation in association with lower abdominal cramps, and significant weight loss despite normal appetite. A CT scan of chest and abdomen revealed multifocal liver metastasis and a characteristic cartwheel at the level of the mesentery, suggestive of neuroendocrine origin (Fig. 1). Patient's basic laboratory values were normal. Serum chromogranin was raised at 39,300 mcg/l. Further imaging with 68Ga-DOTATATE PET-CT identified the mesenteric cartwheel lesion lacking SSTR expression, a focus with increased somatostatin receptor expression in the middle section of the ileum, diffuse liver metastasis and lymph nodes in the right inguinal region with high SSTR expression. No other lesions suspected for a primary tumor site outside the ileum were detected. On endoscopic ultrasound, no primary pancreatic lesion was identified. A core biopsy of one of the liver lesions confirmed the neuroendocrine origin with a Ki67 index of less than 3%. Because of sub-obstructive symptoms, the patient was sent for surgery. On histomorphological and immunohistochemical analysis of the oncologically resected ileal segment a G1 NEN with Ki67 index 1%, without clear mitosis, and with pronounced perineural and vascular invasion was diagnosed. The investigated lesions were found within the

Correspondence to: Dr Klara Wyffels, Department of Gastroenterology, AZ Sint-Jan, Ruddershove 10, 8000 Bruges, Belgium
E-mail: klara.wyffels@azsintjan.be

Abbreviations: NENs, neuroendocrine neoplasms; G, grade; siNEN, small intestinal neuroendocrine neoplasm; MTD, mesenteric tumor deposit

Key words: peritoneal neoplasm, NEN, siNEN, Ki67 index

ileal mesenteric fat (Fig. 2) and not in the wall of the provided transverse ileal sections. Two out of 5 lymph nodes were positive for metastatic involvement, with capsular invasion in one of them. The multidisciplinary oncology board confirmed the diagnosis of siNEN and a treatment with lanreotide was initiated at 90 mg on a monthly basis. During the following year, the patient started losing weight and periodically had mild symptoms of intestinal obstruction with a spontaneous resolution after a mean of 3 days. Chromogranin remained globally unchanged. One year later, the patient presented to the emergency department with bowel obstruction. A CT scan revealed disease progression with de novo peritoneal implants, ascites, an increased number of liver lesions, with central necrosis in some of them. Serum chromogranin raised from 7,320 mcg/l (value after segmental ileal resection) to 22,600 mcg/l. Symptoms resolved on supportive therapy. A 68Ga DOTATATE PET-CT was repeated, revealing clinically evident small bowel sub-obstruction as well as omental carcinomatosis, an implant in the right iliac fossa as a new finding, and progression of the liver metastases. A 18FDG PET-CT was planned and an exploratory laparoscopy was performed. The histomorphological examination of one of the peritoneal tumor nodules revealed lympho-vascular invasion and a Ki67 index of 2% (Fig. 3). Consequently, the dose of the octreotide analogue was augmented to 240 mg monthly. Peptide receptor radionuclide therapy (PRRT) and everolimus were not considered a valid therapeutic option after multidisciplinary consultation. 18FDG PET-CT did show a hazy infiltration of the mesentery, but no avidity in the liver lesions, and no pulmonary or osseous lesions. Three months later the patient presented once again to the emergency department with malaise, nausea, vomiting, and abdominal tenderness. Blood analysis showed an acute renal insufficiency and significantly raised inflammatory parameters (CRP 441 mg/l). On urgent CT scan an intestinal perforation was obvious. The patient underwent an emergency laparotomy which uncovered an inoperable state of bowel obstruction with necrotic small bowel segments and diffuse tumor invasion. Shortly after the intervention she developed sepsis. In agreement with the family as well as the medical team, life support was withdrawn, and the patient passed some hours later.

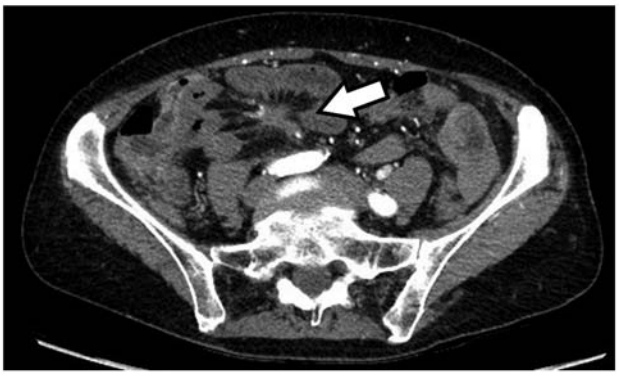

Figure 1. CT scan. Cartwheel lesion at the level of the mesentery (arrow).

Discussion

What stands out in the presented case is the rapid disease progression and the development of peritoneal metastases despite what appeared to be a histologically grade 1 siNEN, and which to our knowledge has been reported only twice (1,7).

In accordance with the latest 2019 WHO classification of tumors of the digestive system, neuroendocrine tumors are divided into NEN and neuroendocrine carcinoma, based on their molecular differences. Mutations in *MEN1*, *DAXX*, and *ATRX* are entity-defining for well-differentiated NENs, whereas NECs usually have *TP53* or *RB1* mutations (8). Whole-exome sequencing on siNENs has shown quite low mutation rates, and it is felt that epigenetic processes might be more important in tumor propagation and metastasis, accounting for the more indolent behavior (9).

The diagnosis of siNEN remains a difficult task due to the lack of overt symptoms (10). As a result the vast majority of patients have metastatic disease at the time of diagnosis. Site of metastasis seems to play an important role in survival of metastatic NEN patients, independent of commonly described prognostic factors (9). Peritoneal metastasis, but not hepatic metastasis alone, is associated with shorter disease-specific survival (6). The presence of peritoneal metastasis has always been thought to be a rare finding in digestive NENs. More recently, this rate has been estimated close to 14% (11).

In case of peritoneal metastasis, malignant cells originating from primary abdominal organs usually spread through a transcoelomic mechanism, responsible for the preferred areas for metastases such as the omentum, paracolic gutters and the right diaphragm (12). In case of NEN, dissemination usually occurs through lymphatic spread, revolving around the ligaments and mesentery (12). The complex, multistage process involves multilevel reactions among molecular and cellular components of the primary tumor site as well as the peritoneum, depending on the combination of specific intrinsic characteristics of the tumor cells and a specific receptive environment of the peritoneum, the so-called pre-metastatic niche (13).

The peritoneum, being of mesodermal origin, exhibits both mesenchymal and epithelial characteristics, and is composed of distinctive layers: the glycocalyx, mesothelial cells, the basal lamina, the submesothelial stroma, and the elastic lamina (13). In order to metastasize tumor cells need to acquire a mobile and invasive phenotype, and therefore undergo epithelial-to-mesenchymal transition. One of the changes involved in this process is the cadherin switch, promoting the detachment of cells from the primary tumor, as well as the subsequent invasion and angiogenesis (13). Another, most critical step, is the attachment to the submesothelial stroma, being a rich source of all the necessary factors required for proliferation, and protected by the mesothelial barrier (13). In case of neuro-endocrine tumors, the stroma may be reached by invasion of physiological intercellular spaces between mesothelial cells, the lymphatic stomata. Stomata are small gaps between mesothelial cells with a direct connection with the lymphatic system (13). The subsequent interactive intertalk between metastatic cells, stromal cells, like cancer-associated fibroblasts, and the specific microenvironment, is until nowadays disappointingly poorly understood.

The fact that the metastatic lesions in our patient did not show a convincing grade shift, in contrast to the evolution to

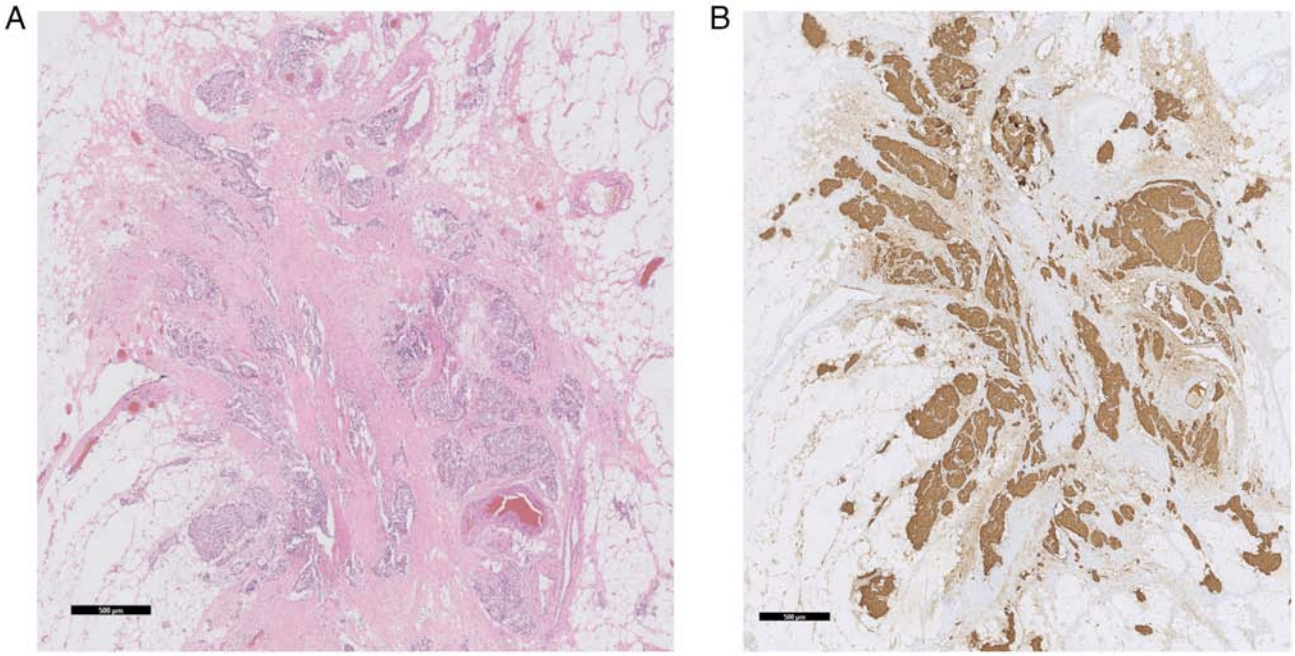

Figure 2. (A) Histopathology: Hematoxylin and eosin-stained section. Small intestinal mesenterium: multiple tumoral foci infiltrating the stroma. (B) Chromogranin staining.

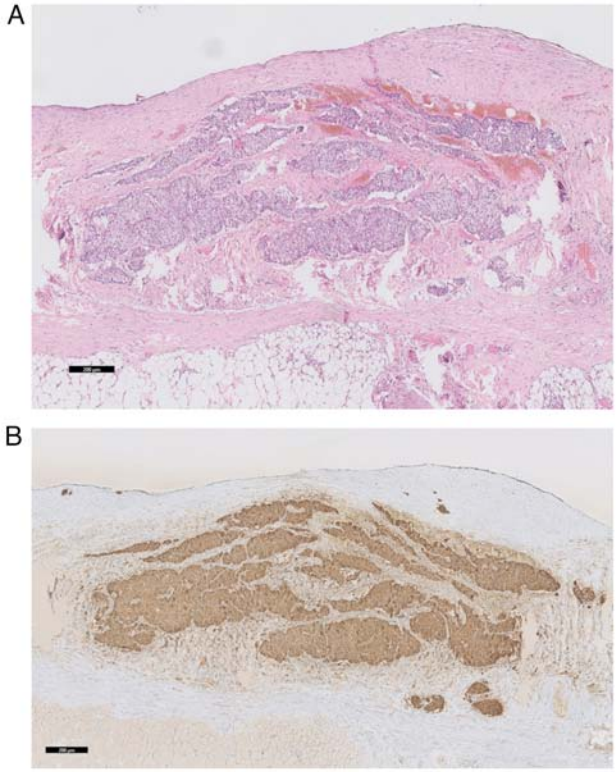

Figure 3. (A) Histopathology: Hematoxylin and eosin-stained section. Peritoneal surface with submesothelial tumor infiltration. (B) Chromogranin staining.

high aggressiveness, is an argument in the direction of epigenetic changes and transcriptome dysregulation, not affecting the Ki67 index. Besides, although Ki67 expression is tightly correlated with proliferation, the possibility has been raised that the contribution may be cell type specific and correlated with distinct stages of the cell cycle (14). Re-expression of stem-cell markers as part of the 'homing' of the recipient stroma may be a decisive contributor as well (15).

Furthermore, the presented case was initially diagnosed with mesenteric tumor deposits (MTDs), of which multifocality and not the mere presence, is carrying a stronger negative prognostic impact than true lymph node metastasis (11). It seems probable that venous invasion is the initial step for development of MTDs. The access of tumor cells in MTDs to the enterohepatic venous system further explains why they are a strong predictor for liver metastases in patients with midgut NEN (11). To our knowledge no information on a grade shift if any in MDTs, based on Ki67 labeling, is available in the literature.

Thus, a twofold metastatic mechanism, interrelated or not, and both raising several unanswered questions, may have played part in the fast fatal course of the disease in the presented patient.

The therapeutic approach of peritoneal carcinomatosis is challenging, mainly due to lack of broad knowledge of biological mechanisms and predictive factors, taking the neoplastic environment as a whole. Translated to the presented case, no benefit had to be expected from the traditional approach, whatsoever (16).

The ultimate disposition of epigenetic drugs, and of an availability-expanded arsenal of tumor-homing peptides and optimized nanocarriers most probably will allow multipronged and personally adjusted approaches to peritoneal carcinomatosis drug delivery, and thus result in a better prognosis (17).

As the importance of an accurate tumor classification lies in its prognostic implications, the present case also obviously illustrates the need of implementing indices different from Ki67, and correlated to the subcellular and molecular level.

In conclusion, the development of peritoneal carcinomatosis in NENs had initially been thought of as a rare finding.

The literature, however, alludes to the fact that it is not quite as rare as previously believed, except in well-differentiated G1 NENs. A more powerful predictive system is needed to identify those patients at increased risk of developing rapidly progressive metastatic disease. A complete understanding of the interactions between the peritoneum and metastatic neuro-endocrine cells at subcellular and molecular level should lead to new treatment strategies for peritoneal carcinomatosis.

Acknowledgements

Not applicable.

Funding

No funding was received.

Availability of data and materials

The datasets used and/or analyzed during the current study are available from the corresponding author on reasonable request.

Authors' contributions

All authors contributed to the article. VDW and KW designed the study. JVH was responsible for data collection and analysis with a focus on histopathology. CDW was responsible for data collection and analysis, with a focus on radiologic imaging. VDW and KW were responsible for data collection, analyzed the literature, and drafted, edited and reviewed the manuscript. VDW and KW confirm the authenticity of all the raw data. All authors read and approved the final manuscript.

Ethics approval and consent to participate

Not applicable.

Patient consent for publication

Written informed consent for publication of the data and accompanying images was given by the patient's husband.

Competing interests

The authors declare that they have no competing interests.

References

1. Antoniadou F, Korkolis D, Koufopoulos N, Manatakis D and Sakellariou S: A well differentiated neuroendocrine tumor of the jejunum with peritoneal carcinomatosis: A case report. Mol Clin Oncol 9: 651-655, 2018.
2. Kim JY, Hong SM and Ro JY: Recent updates on grading and classification of neuroendocrine tumors. Ann Diagn Pathol 29: 11-16, 2017.
3. Dasari A, Shen C, Halperin D, Zhao B, Zhou S, Xu Y, Shih T and Yao JC: Trends in the incidence, prevalence, and survival outcomes in patients with neuroendocrine tumors in the United States. JAMA Oncol 3: 1335-1342, 2017.
4. Yamaguchi T, Fujimori T, Tomita S, Ichikawa K, Mitomi H, Ohno K, Shida Y and Kato H: Clinical validation of the gastrointestinal NET grading system: Ki67 index criteria of the WHO 2010 classification is appropriate to predict metastasis or recurrence. Diagn Pathol 8: 65, 2013.
5. Norlen O, Edfeldt K, Akerstrom G, Westin G, Hellman P, Bjorklund P and Stalberg P: Peritoneal carcinomatosis from small intestinal neuroendocrine tumors: Clinical course and genetic profiling. Surgery 156: 1512-1521, 2014.
6. Wright MF, Cates J, Gonzales RS, Das S, Berlin JD and Shi C: Impact of peritoneal metastasis on survival of patients with small intestinal neuroendocrine tumor. Am J Surg Pathol 43: 559-563, 2019.
7. Celotti A, Pulcini G, Schieppati M, Ministrini S, Berruti A and Ronconi M: An unusual case of a well-differentiated neuroendocrine tumour of the ileum with peritoneal carcinomatosis: A case report. World J Surg Oncol 13: 169, 2015.
8. Nagtegaal ID, Odze RD, Klimstra D, Paradis V, Rugge M, Schirmacher P, Washington KM, Carneiro F, Cree IA and WHO Classification of Tumours Editorial Board: The 2019 WHO classification of tumours of the digestive system. Histopathology 76: 182-188, 2020.
9. Trikalinos NA, Tan BR, Amin M, Liu J, Govindan R and Morgensztern D: Effect of metastatic site on survival in patients with neuroendocrine neoplasm (NENs). An analysis of SEER data from 2010 to 2014. BMC Endocr Disord 20: 44, 2020.
10. Strosberg JR, Weber JM, Feldman M, Coppola D, Meredith K and Kvols LK. Prognostic validity of the American joint committee on cancer staging classification for midgut neuroendocrine tumors. J Clin Oncol 31: 420-425, 2013.
11. Das S, Shi C, Koyama T, Huang Y, Gonzalez R, Idrees K, Bailey CE and Berlin J: Peritoneal carcinomatosis in well-differentiated small-intestinal neuroendocrine tumors with mesenteric tumor deposits. J Med Surg Pathol 4: 1-10, 2019.
12. Desai JP and Moustarah F: Peritoneal metastasis. In: StatPearls (Internet). StatPearls Publishing, Treasure Island, FL, 2022. Available from: https://www.ncbi.nlm.nih.gov/books/NBK541114/.
13. van Baal JOAM, van Noorden CJF, Nieuwland R, Van de Vijver KK, Sturk A, van Driel WJ, Kenter GG and Lok CAR: Development of peritoneal carcinomatosis in epithelial ovarian cancer: A review. J Histochem Cytochem 66: 67-83, 2018.
14. Sun X and Kaufman PD: Ki-67: More than a proliferation marker. Chromosoma 127: 175-186, 2018.
15. Di Domenico A, Wiedmer T, Marinoni I and Perren A: Genetic and epigenetic drives of neuroendocrine tumours (NET). Endocr Relat Cancer 24: R315-R334, 2017.
16. Berardi R, Morgese F, Torniai M, Savini A, Partelli S, Rinaldi S, Caramanti M, Ferrini C, Falconi M and Cascinu S: Medical treatment for gastro-entero-pancreatic neuroendocrine tumours. World J Gastrointest Oncol 8: 389-401, 2016.
17. Simon-Gracia L, Hunt H and Teesalu T: Peritoneal carcinomatosis targeting with tumor homing peptides. Molecules 23: 1190, 2018.