Toripalimab combined with anlotinib for recurrent extensive-stage small-cell lung cancer: A case report

YING WU[1], YINQIAO CHEN[1] and ZHOULIANG YANG[2]

Departments of [1]Oncology and [2]Pathology, The First People's Hospital of Yongkang City, Yongkang, Zhejiang 321300, P.R. China

Received October 19, 2022; Accepted March 21, 2023

DOI: 10.3892/etm.2023.12012

Abstract. The 5-year survival rate of patients with extensive-stage small cell lung cancer (ES-SCLC) is <8%; therefore there is an urgent need for more effective treatment. Although immune checkpoint inhibitors have been widely used to treat lung cancer, the efficacy of anti-programmed death 1 therapy for SCLC is limited due to the abnormal vascular state of the tumour microenvironment. A 66-year-old man who was diagnosed with ES-SCLC and performance status (PS) 3 received first-line chemotherapy but experienced recurrence. Repeated stage IV thrombocytopenia hindered completion of second-line chemotherapy. Therefore, the patient was treated with a combination of toripalimab and anlotinib. After two cycles, the patient showed a partial response to therapy; a long-lasting curative benefit extending 20 months was achieved with PS 1. This novel and effective combined immune/anti-angiogenic therapy paradigm for patients with relapsed ES-SCLC and poor PS requires prospective clinical trials.

Introduction

Lung cancer is the most common type of malignant tumour and has the highest mortality rate worldwide, accounting for 18% of cancer-related deaths (1). Small cell lung cancer (SCLC) accounts for 15-20% of all cases of lung cancer and ~70% of patients have extensive-stage SCLC (ES-SCLC) at diagnosis (2). Limited stage SCLC, which has not metastasized is potentially curable, whereas ES-SCLC is not. Chemotherapy, radiotherapy and anti-angiogenic therapy are key treatments for ES-SCLC (3). Although this comprehensive treatment model is effective, the 5-year survival rate is <8% (4). Therefore, there is an urgent need for a more effective treatment plan.

Correspondence to: Dr Ying Wu, Department of Oncology, The First People's Hospital of Yongkang City, 599 Jinshan West Road, Yongkang, Zhejiang 321300, P.R. China
E-mail: ykwuying@163.com

Key words: extensive-stage small cell lung cancer, toripalimab, anlotinib, anti-programmed death 1 therapy, case report

Immune checkpoint inhibitors (ICIs), including monoclonal antibodies targeting programmed cell death 1 (PD-1) and PD ligand 1, have become widely used in lung cancer (2,5). Moreover, PD-1 inhibitors combined with anti-angiogenic agents are effective in patients with non-SCLC (NSCLC), significantly prolonging progression-free survival (PFS) and overall survival (OS) (6). However, the application of PD-1 inhibitors in SCLC is limited because SCLC is able to damage the immune system, downregulate components like PD-1 to present fewer targets for therapeutic drugs like PD-1 inhibitors, and improve the ability of tumour cells to evade detection by the host immune system (7).

The present study reports the case of a patient with ES-SCLC who experienced disease progression after several courses of chemotherapy but responded to combination therapy with a PD-1 inhibitor (toripalimab) and anti-angiogenic therapy (anlotinib). The present study was conducted in accordance with the CARE reporting checklist (8).

Case presentation

A 66-year-old man with performance status (PS) 3 visited The First People's Hospital of Yongkang City (Yongkang, China) in February 2020 with a chief complaint of chest tightness and haemoptysis for 5 months. The patient had a 40 pack-year smoking history and a history of resection of the right kidney and ureter due to stones in 2004.

Chest CT (SOMATOM Definition AS; Siemens AG; imaging parameters: WL 350/50, magnification x0.78, thickness 7, ctawp66653 and thorax CE 7.0 B30f) revealed a mass in the left lung invading the left hilar region and mediastinum (Fig. 1A). The patient underwent a lung biopsy. The lung biopsy tissue was immersed in 4% paraformaldehyde for 4 h at 25˚C and transferred to 70% ethanol. Individual lobes of lung biopsy material were placed in processing cassettes and dehydrated using a serial ascending ethanol gradient. After 6 h, the dehydrated tissue was soaked in xylene, and then soaked in paraffin wax (Histowax) at 62˚C for 70 min, to embed it in paraffin wax blocks. Then, 5-μm-thick lung tissue sections were dewaxed in xylene at room temperature (~25˚C), rehydrated in a descending ethanol series, washed in phosphate-buffered saline, and stained with haematoxylin and eosin for 2-5 min at ~25˚C. Following staining, sections were dehydrated using increasing concentrations of ethanol and

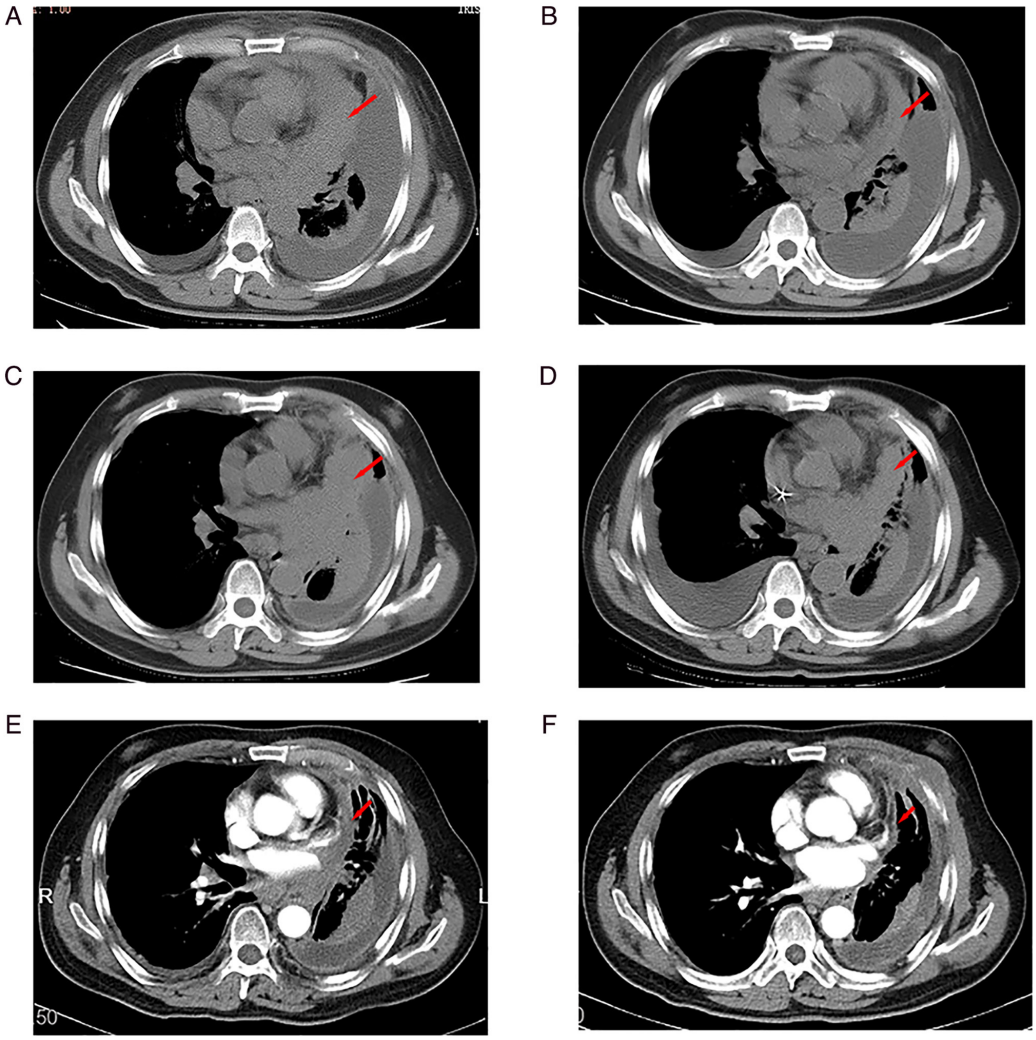

Figure 1. Chest CT images of the primary lung lesion (red arrows) at different time points. (A) Baseline image of a ~37 mm wide arc-shaped irregular mass in the left lung invading the left hilar region and mediastinum (6 February 2020). (B) Following two cycles of etoposide and carboplatin treatment the tumour was reduced to ~17 mm wide (28 March 2020). (C) Relapse of the primary lesion (width, ~37 mm; 19 November 2020). (D) After three cycles of irinotecan and cisplatin treatment, the tumour was reduced to ~27 mm wide (3 March 2021). (E) Following two cycles of toripalimab combined with anlotinib a partial response was achieved (~11 mm wide lesion; 20 April 2021). (F) Follow-up showed a partial response (~6 mm wide lesion; 13 November 2022).

xylene at ~25˚C. Finally, the sections were examined under an optical microscope (Axio Lab.A1; Zeiss). Under high magnification (x100), the cancer cells appeared small, round or oval, lymphocyte-like but larger in size (Fig. 2). Some cells were spindle- or oat-shaped, with little cytoplasm and naked, dark nuclei and thick chromatin. The cancer cells were diffusely separated or arranged in sheets and strips. Crush injury was evident. The histological characteristics, including cell crush injury, deeply stained nuclei, thick chromatin and absence of nucleoli, were typical of SCLC. Moreover, B-ultrasonography (LOGIQ E9; GE Healthcare; imaging parameters: FR 35, Frq 15, Gn 44, E/A 1/1, D 4 cm, DR 69 and AO 100%) indicated cervical lymph node metastasis, which was confirmed by a cervical lymph node biopsy. Histopathology confirmed the metastasis of poorly differentiated carcinoma.

According to the American Joint Committee on Cancer 8th edition tumour-node-metastasis staging system (9), the tumour was T4N3M1a stage IVA ES-SCLC. After obtaining consent from the patient, six cycles of etoposide [100 mg/m^2, day 1-3 (d1-3)] and carboplatin [area under the curve5, 400 mg, d1;

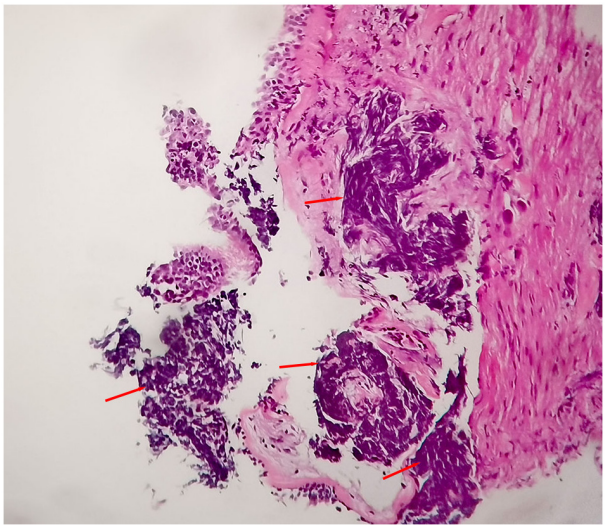

Figure 2. Histopathological findings via haematoxylin and eosin staining. The histological characteristics (red arrows), including cell crush injury, deeply stained nuclei, thick chromatin and absence of nucleoli, were typical of small cell lung cancer (magnification, x100).

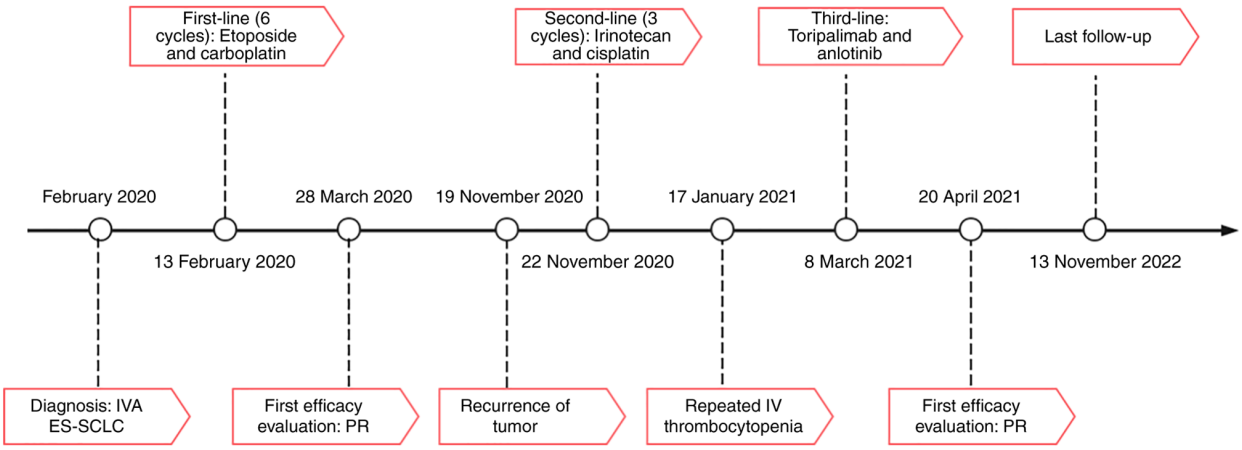

Figure 3. Timeline of the patient. In February 2020, the patient was diagnosed with stage IVA ES-SCLC. Six cycles of etoposide and carboplatin were administered between 13 February 2020 and 7 July 2020; chest CT after two cycles (28 March 2020) revealed PR, which later progressed to stable disease. On 19 November 2020, chest CT revealed enlargement of the primary lesion and mediastinal lymph nodes. Irinotecan and cisplatin was started on 22 November 2020, but after three cycles, the patient developed stage IV thrombocytopenia. The patient recovered from myelosuppression 40 days later but refused to continue chemotherapy. The patient began receiving toripalimab and anlotinib. After two cycles, chest CT showed PR. Tumour re-evaluation was performed every 3 months. The most recent review was conducted on 13 November 2022 and showed PR. PR, partial response; ES-SCLC, extensive-stage small cell lung cancer.

every 21 days (Q21d)] were administered between 13 February 2020 and 7 July 2020. Chest CT revealed partial response (PR) after two cycles (Fig. 1B) and stable disease (SD) over the next four cycles. The patient was PS 2. The lesion area was too large to receive radiotherapy; therefore, the patient was followed up with observation after chemotherapy. Periodic reviews indicated SD until November 2020. At that point, chest CT revealed enlargement of the primary lesion and mediastinal lymph nodes (Fig. 1C). The PFS with first-line chemotherapy (PFS1) was 9 months.

The patient received two cycles of irinotecan (65 mg/m^2, d1 and d8) and cisplatin (30 mg/m^2, d1 and d8; Q21d), after which chest CT showed SD. While using this regimen for the third cycle, the patient developed IV thrombocytopenia, which posed a difficult recovery, and d8 chemotherapy was interrupted. After 40 days, the patient recovered from myelosuppression but refused to continue chemotherapy. Chest CT revealed SD (Fig. 1D); PFS2 was 3 months.

At that time, the patient was repeatedly advised to undergo biopsy and genetic testing for guiding immediate management. The financial burden of long-term anti-tumour treatment was substantial. The patient refused all invasive operations and expensive genetic testing.

Due to shortness of breath, the patient could walk only ~100 m and PS was 2. Dall'Olio *et al* (10) found that PS 2 patients treated with chemotherapy had worse outcomes compared with those of PS 0-1 patients. However, PD-1 inhibitors are well tolerated in PS 2 patients (10). Moreover, Liu *et al* (2) reported a case in which a combination of carrelizumab and anlotinib was used to treat a patient diagnosed with SCLC and staged as ES-SCLC. After 26 cycles, the curative effect was evaluated as complete remission. Considering the present patient's poor PS and large economic burden, toripalimab, the least expensive domestic PD-1 inhibitor, was chosen and combined with anlotinib. Starting on 8 March 2021, the patient received a PD-1 inhibitor (toripalimab 240 mg, d1, Q21d) and anti-angiogenic therapy (anlotinib 10 mg, d1-14, Q21d). After two cycles, an evaluation by chest CT showed PR (Fig. 1E). The patient's condition gradually improved to PS 1. Tumour re-examinations were performed every 3 months, including CT of the brain and chest, and B-ultrasonography of cervical lymph nodes and abdomen. The most recent review was on 13 November 2022 (Fig. 1F). Compared with the previous review on 20 April 2021, the measurable width of the tumour was reduced by ~45% and the response was evaluated as PR. The patient's diagnosis and treatment timeline are shown in Fig. 3. During the administration of anlotinib, the primary adverse reaction was onset of the hand-foot syndrome, grade 3, according to the National Cancer Institute Common Toxicity Criteria for Adverse Events version 4.0 (11). Consequently. the dose of anlotinib was decreased from 10 to 8 mg, which downgraded the hand-foot syndrome reaction to grade 1.

The study was approved by the Ethics Committee of the First People's Hospital of Yongkang City. Written informed consent was obtained from the patient.

Discussion

Platinum-based doublet chemotherapy is considered the standard of treatment for SCLC, with a response rate as high as 75-95%. However, patients who respond to platinum therapy are prone to relapse and the median PFS is <6 months (12). In the present case, PFS1 was 9 months and PFS2 was only 3 months.

The introduction of ICIs is the first notable development in therapeutic strategies for SCLC for two decades without improvements in patient outcomes. Based on the outcomes of the CheckMate 032 and KeyNote 028/158 trials, the United States Food and Drug Administration approved nivolumab and pembrolizumab monotherapy as a third-line treatment for ES-SCLC (13-15). However, two other studies on nivolumab, CheckMate 331 and CheckMate 451, failed and Bristol-Myers Squibb withdrew the indication for nivolumab in SCLC on 30 December 2020 (16,17). The indication for pembrolizumab in

SCLC was also withdrawn because it did not provide an OS advantage in KeyNote 604 (18). Therefore, more attention is needed to improve the efficacy of PD-1 inhibitors in SCLC.

Several factors are associated with efficacy of ICIs. One such factor is an abnormal vascular state in the tumour microenvironment (19). Abnormal tumour blood vessels interact with immune cells, which hinders their anti-tumour effect and leads to tumour progression (20). This can be mitigated by combination therapy with vascular endothelial growth factor (VEGF) inhibitors such as anlotinib. VEGF inhibitors not only have anti-angiogenic effects but can also be used as immunomodulators to enhance the efficacy of immunotherapy (21).

Anlotinib is a domestic multi-target tyrosine kinase inhibitor that targets VEGF and fibroblast growth factor receptors (21-24). Several recent clinical trials have demonstrated the efficacy of anlotinib in SCLC, such as the ALTER1202 trial, in which anlotinib significantly prolonged PFS and OS compared with those in the placebo group (22,23). Anlotinib has been approved for third- and later-line treatment of SCLC in China. Hand-foot syndrome is a common anlotinib-associated adverse event. Nan *et al* (24) found that hand-foot syndrome may be a potential clinical marker for the response to anlotinib in patients with NSCLC: Significant PFS and OS benefits for patients with the hand-foot syndrome were observed in all cases.

Toripalimab is a humanised immunoglobulin G4 monoclonal antibody targeting PD-1 (25). Currently, toripalimab is used to treat unresectable or metastatic melanoma following failure of previous systemic therapy, recurrent or metastatic nasopharyngeal carcinoma without previous second- or later-line systematic treatment and locally advanced or metastatic urothelial carcinoma following platinum-containing chemotherapy failure. In addition, clinical trials for various malignancies are still in progress and good results in NSCLC were achieved in a multicentre retrospective study (25,26).

However, to the best of our knowledge, studies on the use of toripalimab in SCLC are limited. Several PD-1 drugs, including pembrolizumab, carrelizumab, and tislelizumab, were introduced in 2021, but none have been approved for treating SCLC. Liu *et al* (2) reported a case in which a combination of carrelizumab and anlotinib was used to treat a patient diagnosed with SCLC and staged as ES-SCLC. In the present case, after 26 cycles, the curative effect was evaluated as complete remission and the PFS was 24 months. In consideration of the cost, the present patient chose toripalimab rather than carrelizumab. The patient's symptoms improved notably. After two cycles, the patient showed a PR; the curative benefit was long-lasting, extending over 20 months, with a PS of 1. Before immunotherapy, the patient had obvious chest tightness and shortness of breath. The PS score was 2. The patient could not tolerate chemotherapy, but could tolerate immunotherapy, which was consistent with the report of Dall'Olio *et al* (10). For patients with poor PS who cannot tolerate chemotherapy, ICIs provide a reasonable choice that can bring some survival benefits, and the adverse reactions are few (10). In the present case and that reported by Liu *et al* (2), biopsy and genetic testing were not performed as the disease progressed. Therefore, the association between the expression of PD-1 and the efficacy of immunotherapy in SCLC could not be determined. However, the good curative effect in this patient may indirectly indicate that their PD-1 was highly expressed. To the best of our knowledge, only case reports are currently available and prospective studies would be needed to prove the efficacy of PD-1 inhibitors in SCLC. In the present case, toripalimab (PD-1 inhibitor) combined with anlotinib (an anti-angiogenic drug) notably improved the outcome of a patient with recurrent ES-SCLC and the curative benefit was long-lasting. The present novel combined immunotherapy and anti-angiogenic therapy paradigm merits prospective clinical trials.

Acknowledgements

Not applicable.

Funding

No funding was received.

Availability of data and materials

All data generated or analyzed during this study are included in this published article.

Authors' contributions

YW made substantial contributions to the conception and design of the work and drafted the manuscript. YC analysed and interpreted the data and revised the manuscript. ZY performed the histological examination of lung biopsy material and revised the manuscript. YW, YC and ZY confirm the authenticity of all the raw data. All authors have read and approved the final manuscript.

Ethics approval and consent to participate

The study was conducted according to the guidelines of the Declaration of Helsinki and approved by the Ethics Committee of the First People's Hospital of Yongkang City (approval no. YKRM2021-LS039).

Patient consent for publication

Written informed consent was obtained from the patient.

Competing interests

The authors declares that they have no competing interests.

References

1. Deneka AY, Boumber Y, Beck T and Golemis EA: Tumor-Targeted Drug Conjugates as an Emerging Novel Therapeutic Approach in Small Cell Lung Cancer (SCLC). Cancers (Basel) 11: 1297, 2019.
2. Liu L, Zhang X, Zhou L, Yang T, Qiao Y and Jiang X: Carrelizumab combined with anlotinib in the treatment of extensive-stage small cell lung cancer: A case report. Medicine (Baltimore) 100: e27138, 2021.
3. Barrows ED, Blackburn MJ and Liu SV: Evolving role of immunotherapy in small cell lung cancer. Semin Cancer Biol 86(Pt 3): 868-874, 2022.

4. Ando K, Manabe R, Kishino Y, Kusumoto S, Yamaoka T, Tanaka A, Ohmori T, Ohnishi T and Sagara H: Comparative Efficacy and Safety of Immunotherapeutic Regimens with PD-1/PD-L1 Inhibitors for Previously Untreated Extensive-Stage Small Cell Lung Cancer: A Systematic Review and Network Meta-Analysis. Curr Oncol 28: 1094-1113, 2021.
5. He Y and An T: Toripalimab in an advanced non-small cell lung cancer patient with poor general condition after multiline treatment: A case report. J Int Med Res 49: 3000605211042988, 2021.
6. Moya-Horno I, Viteri S, Karachaliou N and Rosell R: Combination of immunotherapy with targeted therapies in advanced non-small cell lung cancer (NSCLC). Ther Adv Med Oncol 10: 1758834017745012, 2018.
7. Tian Y, Zhai X, Han A, Zhu H and Yu J: Potential immune escape mechanisms underlying the distinct clinical outcome of immune checkpoint blockades in small cell lung cancer. J Hematol Oncol 12: 67, 2019.
8. Gagnier JJ, Kienle G, Altman DG, Moher D, Sox H and Riley D; CARE Group: The CARE guidelines: Consensus-based clinical case reporting guideline development. Headache 53: 1541-1547, 2013.
9. Amin MB: American Joint Committee on Cancer and American Cancer Society AJCC cancer staging manual. 8th edition. Springer, Chicago IL, 2017.
10. Dall'Olio FG, Maggio I, Massucci M, Mollica V, Fragomeno B and Ardizzoni A: ECOG performance status ≥2 as a prognostic factor in patients with advanced non-small cell lung cancer treated with immune checkpoint inhibitors-a systematic review and meta-analysis of real world data. Lung Cancer 145: 95-104, 2020.
11. U.S. Department of Health and Human Services, National Institutes of Health, National Cancer Institue: Common Terminology Criteria for Adverse Events (CTCAE)[J/OL]. http://evs.nci.nih.gov/ftp1/CTCAE/About.html.
12. Rossi A, Di Maio M, Chiodini P, Rudd RM, Okamoto H, Skarlos DV, Früh M, Qian W, Tamura T, Samantas E, *et al*: Carboplatin- or cisplatin-based chemotherapy in first-line treatment of small-cell lung cancer: The COCIS meta-analysis of individual patient data. J Clin Oncol 30: 1692-1698, 2012.
13. Antonia SJ, Lopez-Martin JA, Bendell J, Ott PA, Taylor M, Eder JP, Jäger D, Pietanza MC, Le DT, de Braud F, *et al*: Nivolumab alone and nivolumab plus ipilimumab in recurrent small-cell lung cancer (CheckMate 032): A multicentre, open-label, phase 1/2 trial. Lancet Oncol 17: 883-895, 2016.
14. Ott PA, Elez E, Hiret S, Kim DW, Morosky A, Saraf S, Piperdi B and Mehnert JM: Pembrolizumab in Patients With Extensive-Stage Small-Cell Lung Cancer: Results From the Phase Ib KEYNOTE-028 Study. J Clin Oncol 35: 3823-3829, 2017.
15. Chung HC, Piha-Paul SA, Lopez-Martin J, Schellens JHM, Kao S, Miller WH Jr, Delord JP, Gao B, Planchard D, Gottfried M, *et al*: Pembrolizumab after two or more lines of previous therapy in patients with recurrent or metastatic SCLC: Results from the KEYNOTE-028 and KEYNOTE-158 Studies. J Thorac Oncol 15: 618-627, 2020.
16. Spigel DR, Vicente D, Ciuleanu TE, Gettinger S, Peters S, Horn L, Audigier-Valette C, Pardo Aranda N, Juan-Vidal O, Cheng Y, *et al*: Second-line nivolumab in relapsed small-cell lung cancer: CheckMate 331*. Ann Oncol 32: 631-641, 2021.
17. Owonikoko TK, Park K, Govindan R, Ready N, Reck M, Peters S, Dakhil SR, Navarro A, Rodríguez-Cid J, Schenker M, *et al*: Nivolumab and ipilimumab as maintenance therapy in extensive-disease small-cell lung cancer: CheckMate 451. J Clin Oncol 39: 1349-1359, 2021.
18. Rudin CM, Awad MM, Navarro A, Gottfried M, Peters S, Csőszi T, Cheema PK, Rodriguez-Abreu D, Wollner M, Yang JC, *et al*: Pembrolizumab or placebo plus etoposide and platinum as first-line therapy for extensive-stage small-cell lung cancer: Randomized, double-blind, phase III KEYNOTE-604 study. J Clin Oncol 38: 2369-2379, 2020.
19. Yi M, Jiao D, Qin S, Chu Q, Wu K and Li A: Synergistic effect of immune checkpoint blockade and anti-angiogenesis in cancer treatment. Mol Cancer 18: 60, 2019.
20. De Palma M, Biziato D and Petrova TV: Microenvironmental regulation of tumour angiogenesis. Nat Rev Cancer 17: 457-474, 2017.
21. Sun Y, Niu W, Du F, Du C, Li S, Wang J, Li L, Wang F, Hao Y, Li C and Chi Y: Safety, pharmacokinetics, and antitumor properties of anlotinib, an oral multi-target tyrosine kinase inhibitor, in patients with advanced refractory solid tumors. J Hematol Oncol 9: 105, 2016.
22. Liu Y, Cheng Y, Li K, Shi J, Liu Y, Wu L, Han B, Chen G, He J, Wang J, *et al*: Effect of prior thoracic radiotherapy on prognosis in relapsed small cell lung cancer patients treated with anlotinib: A subgroup analysis of the ALTER 1202 trial. Transl Lung Cancer Res 10: 3793-3806, 2021.
23. Wu D, Nie J, Hu W, Dai L, Zhang J, Chen X, Ma X, Tian G, Han J, Han S, *et al*: A phase II study of anlotinib in 45 patients with relapsed small cell lung cancer. Int J Cancer Dec 15: 3453-3460, 2020.
24. Nan X, Xie C, Zhu Q, Zhang J, Fu S, Han X, Zhang Q, Han B and Liu J: Hand-foot syndrome and survival in patients with advanced non-small-cell lung cancer receiving anlotinib: A subgroup analysis of data from the ALTER 0303 study. Int J Clin Oncol 25: 1492-1498, 2020.
25. Mai HQ, Chen QY, Chen D, Hu C, Yang K, Wen J, Li J, Shi YR, Jin F, Xu R, *et al*: Toripalimab or placebo plus chemotherapy as first-line treatment in advanced nasopharyngeal carcinoma: A multicenter randomized phase 3 trial. Nat Med 27: 1536-1543, 2021.
26. Duan S, Zhang X, Wang F, Shi Y, Wang J and Zeng X: Coexistence of oral mucous membrane pemphigoid and lichenoid drug reaction: A case of toripalimab-triggered and pembrolizumab-aggravated oral adverse events. Oral Surg Oral Med Oral Pathol Oral Radiol 132: e86-e91, 2021.