Surgical ciliated cyst of the maxilla after orthognathic surgery: A case report

TERESA CORDERO-GARCIA[1], RODRIGO LOZANO-ROSADO[1], MARIA FONTILLON-ALBERDI[2], JOSE-LUIS GUTIERREZ-PEREZ[1] and PEDRO INFANTE-COSSIO[1]

Departments of [1]Oral and Maxillofacial Surgery and [2]Pathology, Virgen Del Rocio University Hospital, University of Seville, 41013 Seville, Spain

Received January 12, 2023; Accepted April 27, 2023

DOI: 10.3892/etm.2023.12042

Abstract. Surgical ciliated cysts are rare benign cystic lesions that generally occur a number of years after invasive surgical procedures or trauma involving the maxilla. The appearance of this cyst after orthognathic surgery is a complication that has rarely been reported. It usually shows as a well-defined radiolucency in the maxilla in young adults mimicking other maxillary cysts. Therefore, an exhaustive clinical-radiological diagnosis is needed to establish its differential diagnosis and appropriate treatment. The present study describes the case of a surgical ciliated cyst that appeared 20 years after LeFort I orthognathic surgery. Treatment consisted of complete enucleation with primary closure and removal of osteosynthesis material. Histopathological examination confirmed the diagnosis of a maxillary cyst lined with pseudostratified ciliated columnar cells. Clinicians should be aware of this rare type of cyst in patients with a history of maxillary surgery or trauma to establish a differential diagnosis and ensure appropriate management.

Introduction

Surgical ciliated cyst (SCC), also known as postoperative maxillary cyst, paranasal cyst, or respiratory implantation cyst, was first described by Kubo in 1927 in the Japanese literature (1) as a maxillary cyst after treatment of chronic maxillary sinusitis. In the Japanese population, this lesion accounts for up to 20% of maxillary cysts (2), being the largest published series of 71 cases of postoperative maxillary cysts (3). However, to date, few reports have been published in the English literature on non-Asian populations (4).

SCC is a benign lesion that is considered a late complication, as it can develop from a few months to several years after an initial surgical procedure or trauma involving the maxillary sinus or midface (4). It is assumed to arise from unintentional entrapment of the maxillary sinus mucosa in patients with a history of Caldwell-Luc antrostomies, orthognathic surgery, and sinus lift procedures, or in association with midface trauma involving the maxillary sinus (5).

In the present clinical report, we describe an interesting case of a patient with a large SCC located in the maxilla that was found 20 years after a LeFort I osteotomy that had been performed to correct a class II dentofacial deformity. Therefore, we extensively discuss the main clinical-radiological, histological findings and appropriate management of this unusual pathology among the Spanish population compared to the Asian literature.

Case report

A healthy 41-year-old woman came to the Department of Oral and Maxillofacial Surgery, Virgen del Rocio University Hospital (Seville, Spain) in September 2020 due to swelling in the maxillary region and intense and progressive pain of two months evolution. Previously, her dentist had medicated her with antibiotics and analgesics and performed endodontic treatment on the upper lateral incisor because of worsening pain, in an attempt to eliminate any focus of dental inflammation, without clinical improvement. Her medical history highlighted that, 20 years earlier, she had undergone orthognathic surgery at our centre to correct an Angle class II malocclusion and vertical excess by means of bimaxillary advancement using LeFort I osteotomy and bilateral ramus sagittal osteotomy with genioplasty.

Physical examination revealed a midfacial deformity in the premaxilla and nostrils with a slight airflow limitation. Intraoral view showed an expansion of the vestibular and palatal cortex in the anterior maxilla. Palpation detected a fluctuating and painful swelling with an overlying normal mucosa. No discharge or oronasal fistula was identified. Panoramic radiography revealed a rounded, well-defined unilocular radiolucent lesion in the central region of the maxilla, 3.5 cm in size, which

Correspondence to: Professor Pedro Infante-Cossio, Department of Oral and Maxillofacial Surgery, Virgen del Rocio University Hospital, University of Seville, Manuel Siurot Avenue, 41013 Seville, Spain
E-mail: pinfante@us.es

Key words: surgical ciliated cyst, postoperative maxillary cyst, non-odontogenic cysts, orthognathic surgery, LeFort I osteotomy, complication

did not appear to be related to neighbouring teeth (Fig. 1). Four L-shaped titanium plates in the maxilla and four straight ones in the mandible associated with previous orthognathic surgery, fixed with screws, were observed. Computed tomography (CT) demonstrated an extensive and well-defined unilocular cystic lesion, measuring 4.3x3.7x3.7 cm, located in the centre of the anterior maxillary region, involving the apical region of the maxillary incisor, and fenestrating the vestibular and palatal cortical bone, affecting the floor of the pyriform aperture (Fig. 2). Under local anaesthesia, a preoperative incisional biopsy was taken, which confirmed the benign nature of the lesion. The diagnostic hypothesis was a cystic lesion.

Treatment consisted of cyst enucleation and removal of the osteosynthesis material intraorally under general anaesthesia. During surgery, the cystic lesion was found to be easily enucleable and communicated with the nasal cavity but not with the maxillary sinus. No dental focus was found in relation to the lesion. Bone reconstruction was not necessary. Histopathological examination confirmed the presence of a cystic lesion with fibrous walls and a pseudostratified ciliated columnar epithelium lining with mucus-secreting cells, consistent with a ciliated cyst (Fig. 3). On the basis of the clinical-radiological and microscopic findings, a diagnosis of non-odontogenic SCC was made. No postoperative complications were identified, and the site healed uneventfully. The patient is doing well after 24 months of follow-up. CT scans showed progressive regeneration of the bone cavity, with no evidence of recurrence of the lesion.

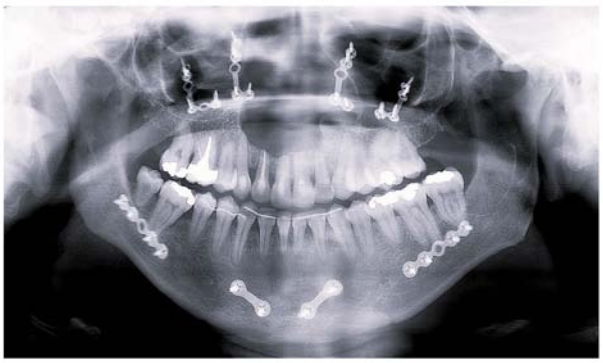

Figure 1. Panoramic radiograph showing unilocular radiolucency in the anterior maxilla in the previous surgical area of the LeFort I osteotomy.

Discussion

SCC is a rare pathology that is normally located in the maxilla and arises as a complication of a previous aggressive surgical procedure involving the maxillary sinuses and bone. They have been reported more frequently in the Japanese literature, probably due to the high prevalence of chronic sinusitis in that country and the preference for surgical treatment over antibiotics (4). This variable incidence has also been attributed to some extent to underdiagnosis or misdiagnosis of expanding mucoceles, as well as differences in facial bone structure between ethnic groups. The lack of reports is possibly related to the late presentation of these types of cysts, which are usually diagnosed 15-20 years after initial surgery (range 3-60 years) (6). In this case, the patient presented with a large maxillary cyst found 20 years after a LeFort I osteotomy. They are detected in the fourth or fifth decade of life, with a variable gender distribution (7).

SCC is probably an iatrogenic consequence of entrapment of the maxillary sinus mucosa during radical surgery. It is generally lined by a respiratory-type pseudostratified columnar epithelium compatible with the Schneider membrane, although mixed patterns with simple columnar, cuboidal, or squamous epithelium have been described in the literature (8). The appearance of SCC after orthognathic surgery is an exceptional complication that has rarely been reported (5,9,10). During a LeFort I osteotomy, the mucosal cells of the maxillary sinuses, nasal sinuses, and nasopalatal mucosa can become embedded between the bony edges of the osteotomies (10). Over time, these trapped cells can undergo cystic degeneration and, subsequently, expansion caused by the osmotic difference with locoregional tissue (11). In the mandible, respiratory epithelium transplantation has been associated with the use of nasal osteocartilage graft and maxillary bone graft used to stabilize genioplasty (12,13). These cysts could also arise from accidental transport of the sinus mucosa on the saw blade during bimaxillary surgeries (14).

The main clinical signs of SCC are progressive maxillary swelling, facial deformity, severe pain, and nasal or oral discharge. The most common location is the lateral and posterior wall of the maxilla, although they have also been described in the central region, the infraorbital rim, and the medial canthal region (4). In this case, the patient presented all the above clinical signs except the oronasal fistula, the main reason for consultation being severe and progressive pain. In its initial stage, it can be completely asymptomatic and can be discovered on routine x-rays, but as it expands, it gradually causes pain or infection. Clinically, this cyst behaves like a solitary, unilateral, but locally aggressive lesion. As it increases in size, the cyst can displace or perforate the sinus and nasal walls and invade adjacent tissues.

Radiographically, it is characterized by a well-defined, expansive, unilocular, or multilocular radiolucent image close to the sinus and the previous surgical or traumatic area (6). Even though panoramic and Waters radiographs are the imaging modalities initially used, CT is recommended to fully assess the lesion and select the best treatment (10). Despite the low number of SCCs reported in the Western literature, this lesion should be considered in the differential diagnosis of cystic lesions in patients with a history of risk. The clinical and radiographic characteristics of these lesions can mimic those of inflammatory cysts of dental origin. In the present case, these typical radiographic features were observed. Assuming that their clinical radiographic features may resemble those of inflammatory cysts of dental origin, pulp vitality tests may help in the differential diagnosis, although they are often inconclusive. The patient had root resorption and her dentist had previously performed unsuccessful endodontic treatment. It is important to distinguish knife-shaped root resorption from other aggressive odontogenic lesions, such as ameloblastoma, which may have a similar radiographic appearance. The differential diagnosis usually includes odontogenic or non-odontogenic developmental cysts (e.g., residual cyst, odontogenic keratocyst, central giant cell granuloma), fibro-osseous lesions, traumatic bone cysts, aneurysmal bone

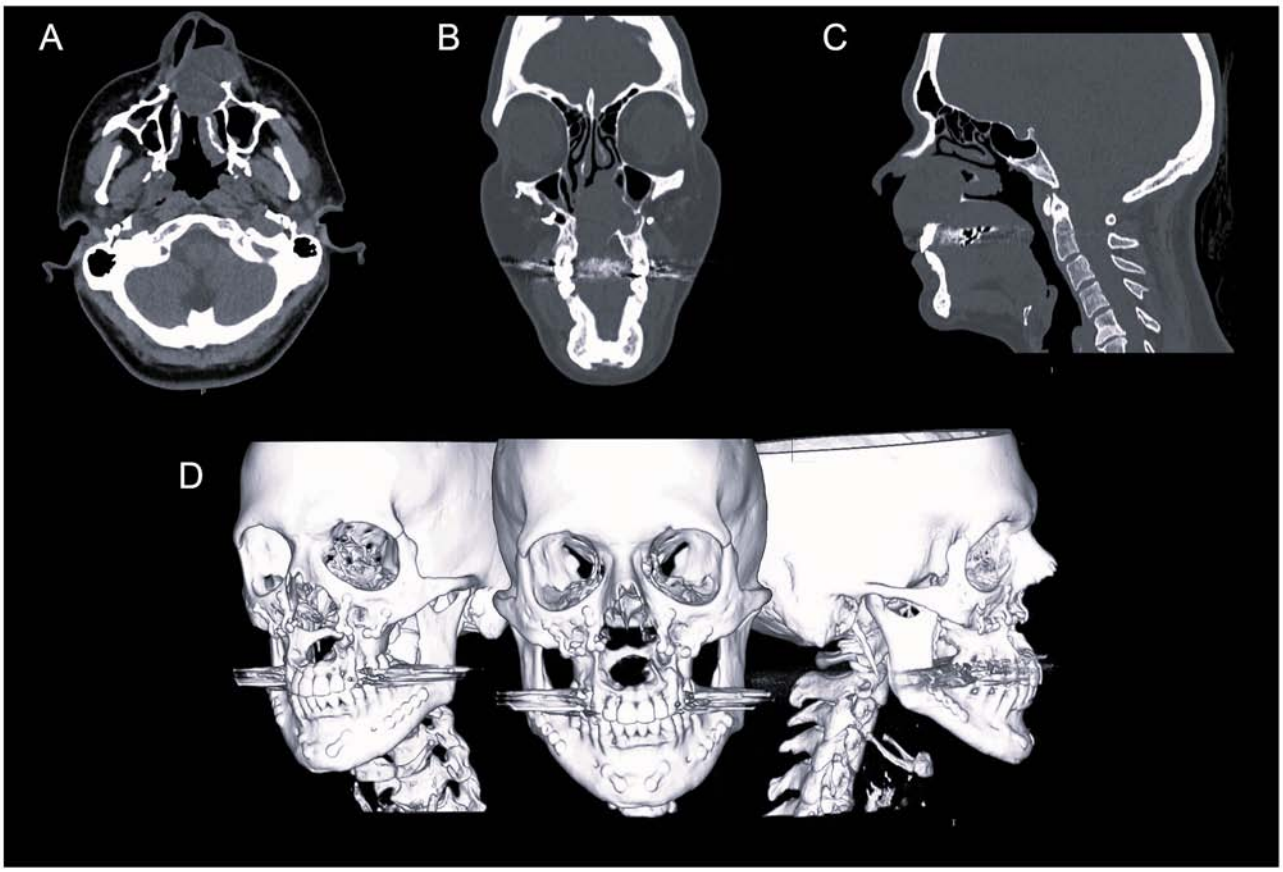

Figure 2. CT of the lesion in the (A) axial plane, (B) coronal plane, (C) sagittal plane and (D) 3D multiplanar volumetric reconstruction.

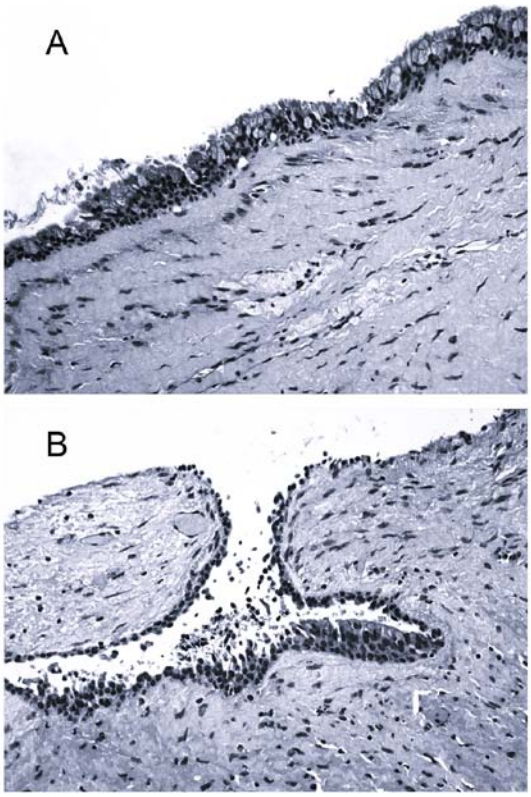

Figure 3. (A) Histological characteristics of the surgical ciliated cyst (haematoxylin-eosin x40). (B) High-power micrograph of a cystic lesion with fibrous walls and a ciliated columnar epithelium lining with the presence of mucus-secreting cells (haematoxylin-eosin x100).

cysts, odontogenic tumours (e.g., ameloblastoma, odontogenic fibroma), mucoceles, retention cysts, and pseudocysts of the maxillary sinus (5-10,15).

Early recognition of this pathology and its consideration in differential diagnosis helps to reduce treatment delay time and the growth of these lesions. In this case, the initial biopsy established the suspicion of a benign cystic lesion. However, the definitive histopathological examination corroborated the diagnosis of a maxillary cyst lined with pseudostratified ciliated columnar columnar cells. Regardless of its etiological cause, definitive treatment of SCC consists of complete enucleation with primary closure, which is generally curative given its benign nature. The most commonly used accesses are the direct intraoral approach and the Caldwell-Luc procedure, although transnasal endoscopic surgery has also been described (7). Enucleation and curettage alone, open packing, or even marsupialization have been used (8). However, in the case of large lesions, bone perforation, or recurrence, a more aggressive approach with subsequent bone reconstruction may be necessary.

Since these lesions can remain asymptomatic and appear many years after the initial intervention, long-term follow-up of patients with a possible history of risky procedures is recommended. Recurrence rates have not yet been established but are estimated to be extremely low (7). The prognosis seems to be excellent after complete enucleation in reported cases (9).

In summary, the growing demand for orthognathic surgery could increase the number of SCCs related to these procedures in the medium to long term. Assuming that this complication is underreported in the literature, the clinician should be aware to

this type of cyst in patients with a history of maxillary surgery or trauma to establish a differential diagnosis and ensure appropriate management. Simple surgical gestures, such as avoiding entrapment of the epithelium between the osteosynthesis material, suturing the nasal or sinus mucosa if broken, checking cartilage and bone grafts, and changing the saw blade between maxillary and mandibular osteotomies, could reduce the appearance of this pathology. Complete enucleation with primary closure and subsequent reconstruction when necessary is the most widely used treatment.

Acknowledgements

Not applicable.

Funding

No funding was received.

Availability of data and materials

The datasets used and/or analyzed during the current study are available from the corresponding author on reasonable request.

Authors' contributions

TCG, RLR and PIC wrote the manuscript. RLR was a major contributor to the conception and design of the study. TCG, RLR, MFA, JLGP and PIC confirm the authenticity of all the raw data. TCG and RLR performed the patient's surgery and acquired the data. MFA performed the patient's examination. TCG, RLR, MFA, JLGP and PIC analysed and interpreted the data. TCG, RLR, MFA, JLGP and PIC critically revised the manuscript for intellectual content. All authors read and approved the final manuscript.

Ethics approval and consent to participate

Not applicable.

Patient consent for publication

Written informed consent was obtained from the patient for publication of this case report and the accompanying images.

Competing interests

The authors declare that they have no competing interests.

References

1. Kubo I: A buccal cyst occurred after a radical operation of the maxillary sinus in Japanese. Z F Otol Tokyo 3: 896-897, 1927.
2. Ragsdale BD, Laurent JL, Janette AJ and Epker BN: Respiratory implantation cyst of the mandible following orthognathic surgery. J Oral Maxillofac Pathol 13: 30-34, 2009.
3. Kaneshiro S, Nakajima T, Yoshikawa Y, Iwasaki H and Tokiwa N: The postoperative maxillary cyst: Report of 71 cases. J Oral Surg 39: 191-198, 1981.
4. Cano J, Campo J, Alobera MA and Baca R: Surgical ciliated cyst of the maxilla. Clinical case. Med Oral Patol Oral Cir Bucal 14: E361-E364, 2009.
5. Theofilou NE, Lombardi T and Scolozzi P: Maxillary surgical ciliated cysts following advancement Le Fort I osteotomy with concomitant autogenous bone grafting: A simple coincidence or a cause-effect relationship? J Stomatol Oral Maxillofac Surg 122: 618-624, 2021.
6. Golaszewski J, Muñoz R, Barazarte D and Perez L: Surgical ciliated cyst after maxillary orthognathic surgery: A literature review and case report. Oral Maxillofac Surg 23: 281-284, 2019.
7. Soares JC, Villalba NC, Sanromán JF, Ferro MF, Fernández PL, Betancourt AL and López AC: Surgical ciliated cysts in orthognathic surgery. J Craniofac Surg 32: e2-e5, 2021.
8. Amin M, Witherow H, Lee R and Blenkinsopp P: Surgical ciliated cyst after maxillary orthognathic surgery: Report of a case. J Oral Maxillofac Surg 61: 138-141, 2003.
9. Shakib K, McCarthy E, Walker DM and Newman L: Post operative maxillary cyst: Report of an unusual presentation. Br J Oral Maxillofac Surg 47: 419-421, 2009.
10. Lee JH, Huh KH, Yi WJ, Heo MS, Lee SS and Choi SC: Bilateral postoperative maxillary cysts after orthognathic surgery: A case report. Imaging Sci Dent 44: 321-324, 2014.
11. Leung YY, Wong WY and Cheung LK: Surgical ciliated cysts may mimic radicular cysts or residual cysts of maxilla: Report of 3 cases. J Oral Maxillofac Surg 70: e264-e269, 2012.
12. Cai M, Shen G, Lu X and Wang X: Two mandibular surgical ciliated cysts after le Fort I osteotomy and genioplasty. Br J Oral Maxillofac Surg 53: 1040-1042, 2015.
13. Youn S, Oh HJ, Yoon HJ and Seo BM: Surgical ciliated cyst of the mandible after orthognathic surgery: A case report with review of the literature. Maxillofac Plast Reconstr Surg 44: 26, 2022.
14. Bourgeois SL Jr and Nelson BL: Surgical ciliated cyst of the mandible secondary to simultaneous Le Fort I osteotomy and genioplasty: Report of case and review of the literature. Oral Surg Oral Med Oral Pathol Oral Radiol Endod 100: 36-39, 2005.
15. Martinelli-Kläy CP, Chatelain S, Salvado F and Lombardi T: Respiratory epithelium lined cyst of the maxilla: Differential diagnosis. Case Rep Pathol 2017: 6249649, 2017.