Unexpected form of ischemic colitis: A case report

JIUYU SHI[1], GUN CHEN[2] and MINGYUAN ZHANG[3]

Departments of [1]Gastroenterology and [2]Pathology, The Affiliated People's Hospital of Ningbo University; [3]Department of Colorectal Surgery, Ningbo Medical Center Lihuili Hospital, Ningbo, Zhejiang 315000, P.R. China

Received March 30, 2023; Accepted June 19, 2023

DOI: 10.3892/etm.2023.12118

Abstract. Ischemic colitis (IC) is an ischemic injury to the colon caused by an occlusive arterial blood supply or blocked venous return. Colonoscopic manifestations most frequently include colonic mucosal edema and erosion, while tubular channels are rare. It is also known as colon cast, and doctors often misdiagnose it when they encounter it. The present study presents a rare form of IC. An 80-year-old man visited The Affiliated People's Hospital of Ningbo University (Ningbo, China) due to abdominal pain and bloody stools. He had no significant comorbidities and had not taken medication. Physical examination suggested tenderness in the left lower abdomen. Abdominal computed tomography (CT) showed thickening of the sigmoid colon wall. Laboratory tests showed positive fecal occult blood, whereas routine blood tests, including blood coagulation, were normal. Diagnostic colonoscopy revealed sigmoid colon narrowing. There was a long strip of tissue in the sigmoid with a cystic and smooth head, the base of the pedicle was edematous and anabrotic. Abdominal CT angiography revealed no abnormality of the mesenteric artery. The day after colonoscopy, the patient expelled a 17-cm strip of tissue from his anus. Pathological examination revealed inflammatory necrotic colonic mucosa. After 1 week, repeat colonoscopy revealed the strip had been shed, the sigmoid mucosa was edematous and anabrotic, but other intestinal segments were normal.

Introduction

Ischemic colitis (IC) is an ischemic injury to the colon caused by an occlusive arterial blood supply, blocked venous return (1), or by insufficient blood supply to the colon (2). Abdominal pain, bloody stools and diarrhea are often the triad of clinical manifestations (3). It commonly occurs in older individuals, and the incidence increases with age (3). IC usually includes colon ischemia, acute mesenteric ischemia (AMI) and chronic mesenteric ischemia (CMI) (4). Ahmed *et al* (4) reported that colon ischemia is the most common type followed by AMI and CMI epidemiologically.

Colon cast (CC) is a rare clinical type of IC that was first reported by Speakman and Turnbull in 1984 (5). Abe *et al* (6) reported that only 23 cases were published before 2014. Su *et al* (7), and Feuerstadt and Brandt (8) also reported a few cases. The main cause of CC is acute colonic ischemia, and the majority of the cases are secondary to abdominal aortic aneurysm repairs. Invasive treatment is required, as it is likely to develop into colonic stenosis, obstruction and bowel perforation (6). In some cases, the causes include diabetic ketoacidosis, trauma, pancreatitis, graft-versus-host disease and ischemic colitis secondary to arteriosclerotic cardiovascular disease; there are also some cases caused by ischemic colitis from preceding circulatory disorders (6). The cases that always occur with severe symptoms and involve the intrinsic muscle layer should be treated with operations. Only a few cases occur with mild symptoms and involve infarction limited to the colonic mucosa layer, and these can be successfully treated by conservative therapies, including endoscopic dilation (6). However, there are no such cases of CC reported in mainland China. To improve our understanding of this disease, the present study reported a case of CC.

Case presentation

An 80-year-old male patient visited The Affiliated People's Hospital of Ningbo University (Ningbo, China) due to abdominal pain and bloody stools for 1 day. The patient had no significant comorbidities and was not taking any medication. The patient had no past severe systemic diseases. He had no history of alcohol consumption or smoking, and he had no family history of illness. Physical examination suggested tenderness in the left lower abdomen. Laboratory tests showed positive fecal occult blood. Routine blood tests, blood coagulation function, D-dimer check and other tests were all normal. Abdominal computed tomography (CT) revealed thickening of the sigmoid colon wall. Diagnostic endoscopy was conducted, which revealed narrowing of the sigmoid colon. There was a long strip of tissue in the sigmoid cavity with a cystic and smooth head, and the base of the pedicle was edematous and erosive (Fig. 1). Further examination by CT angiography revealed thickening of the sigmoid wall and no abnormality of the mesenteric artery (Fig. 2). The day after colonoscopy,

Correspondence to: Dr Mingyuan Zhang, Department of Colorectal Surgery, Ningbo Medical Center Lihuili Hospital, 57 Xingning Road, Ningbo, Zhejiang 315000, P.R. China
E-mail: 422304773@qq.com

Key words: ischemic colitis, colon cast, colonoscopy, colon mucosa, conservative treatment, case report

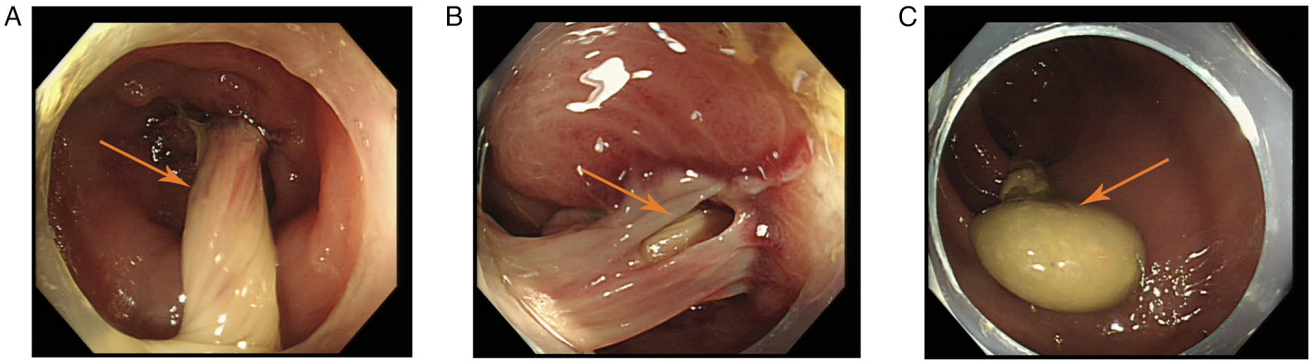

Figure 1. Colonoscopy. (A) There was a long strip of tissue in the colon cavity (orange arrow); (B) the base of the strip pedicle was edematous and erosive (orange arrow); (C) the head of the strip was cystic and smooth (orange arrow).

the patient expelled a 17-cm strip of tissue that was the eroded colonic mucosa (Fig. 3) from his anus and developed fever of 38.5˚C. Pathological examination with hematoxylin and eosin staining (25˚C, 45 min) revealed an inflammatory, necrotic colonic mucosa (Fig. 4). After 1 week, re-examination by colonoscopy revealed that the strip had been shed, the sigmoid mucosa was edematous and anabrotic, but other intestinal segments were normal (Fig. 5).

After reviewing the relevant literature, the present study concluded that this was a rare type of IC called CC. The patient was treated by fasting for 5 days and anti-inflammatory medication consisting of cefmetazole (2.0 g twice a day) for 5 days and low molecular weight heparin (5,000 IU) as anticoagulant therapy for 1 week. He recovered well and was discharged after remission. He has been followed up for 1 year without relapse.

Discussion

CC is a rare clinical type of IC. Studies have shown that colon hypoperfusion and reperfusion injury are involved in the occurrence of IC (9,10). Colonoscopy combined with histopathological biopsy is the gold standard for the diagnosis of IC (11). The endoscopic manifestations of typical patients with IC are a clear demarcation between the pathological and normal mucosa, and the common endoscopic manifestations include congestion, edema, erosion, intestinal stenosis and hemorrhage (9,12). The dark blue nodules with dusty background often indicate gangrene during endoscopic tests (12). However, CC often confuses the diagnosis because of its non-typical symptoms (13).

This type of IC presents insidiously, with abdominal pain, distension, watery bloody stools, fever and elevated white blood cell count. In addition, erythrocyte sedimentation rate increases, which peaks after several weeks. The necrotic intestinal tissue is discharged from the anus. The clinical manifestations, colonoscopy, blood test and CT angiography results of the current patient were consistent with those reported in the literature for CC (14).

At present, the pathogenesis of CC is still not clear. Most cases have been reported secondary to abdominal aortic aneurysm or mesenteric thrombosis (6). However, abdominal CT angiography of the current patient showed no vascular abnormalities; therefore, the present study hypothesizes that the pathogenesis of CC needs to be further explored.

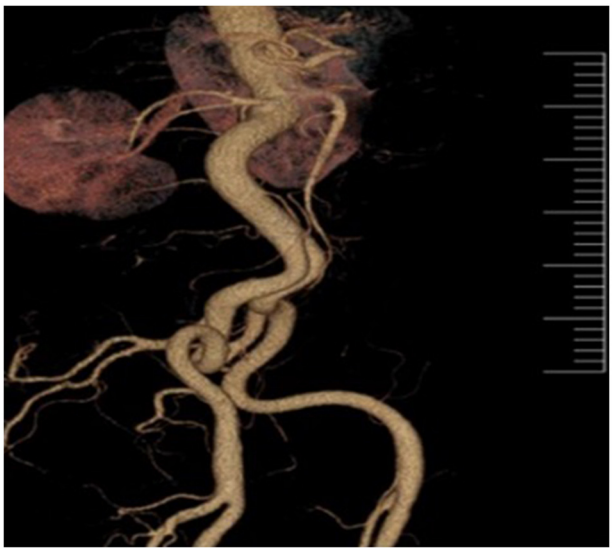

Figure 2. Computed tomography angiography. There was no abnormality of the mesenteric artery.

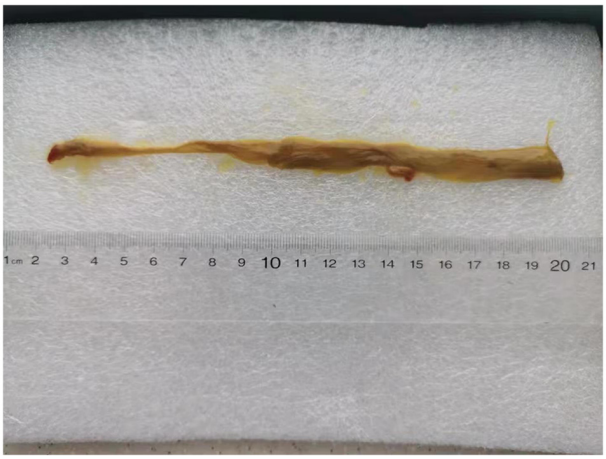

Figure 3. A 17-cm strip of tissue, which was eroded colonic mucosa, was expelled from the anus.

According to previous case reports, the lesions of tubular IC are all located in the left colon; the rectum is often not involved, and as such IC occurring in the right colon has not

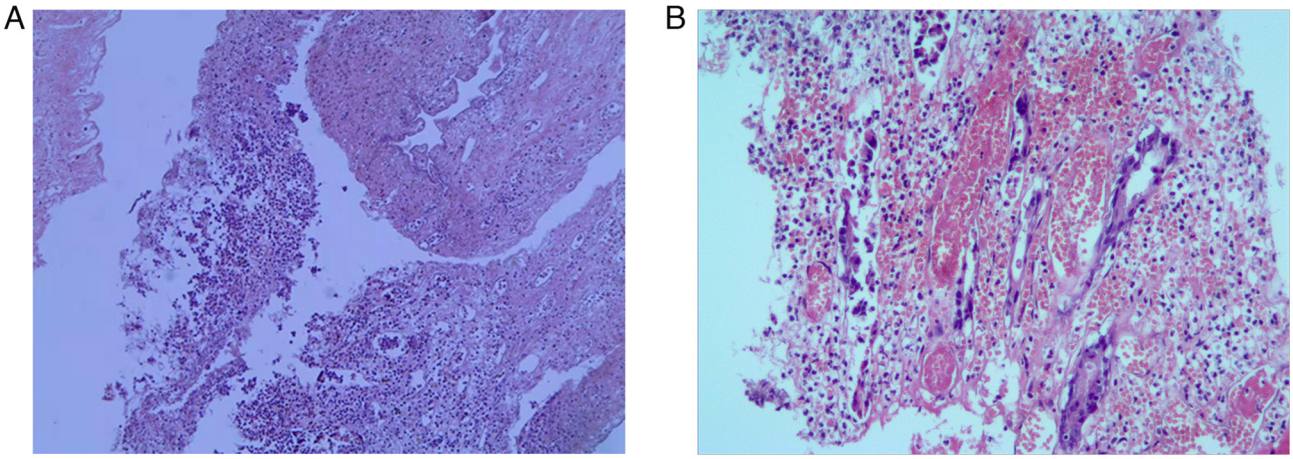

Figure 4. Pathological findings. (A) Pathological examination revealed an inflammatory necrotic colonic mucosa; (B) ischemia necrotic colonic mucosa; some regions showed multiple granulocyte infiltration (hematoxylin-eosin; magnification, x100).

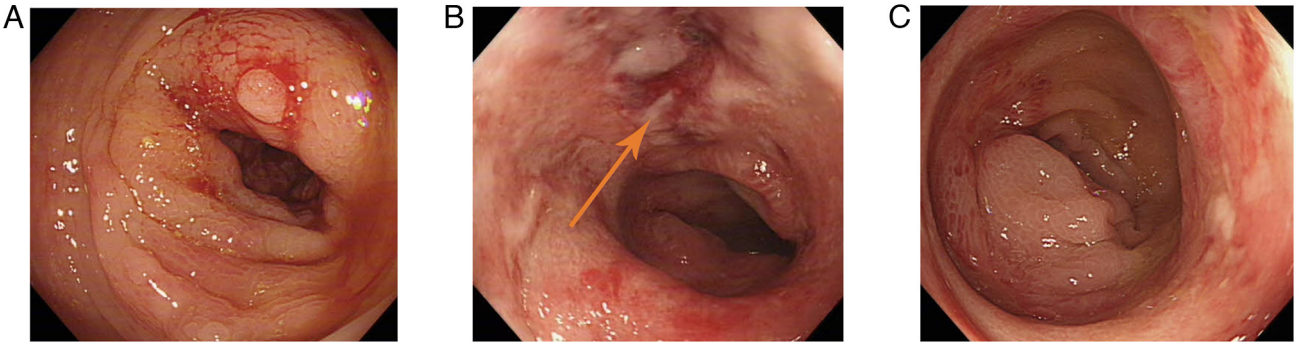

Figure 5. Re-examination by colonoscopy. (A) The strip of eroded colonic mucosa was shed, and the colonic cavity was clean; (B) the former pedicle site was edematous and anabrotic (orange arrow); (C) the other bowel segment was normal.

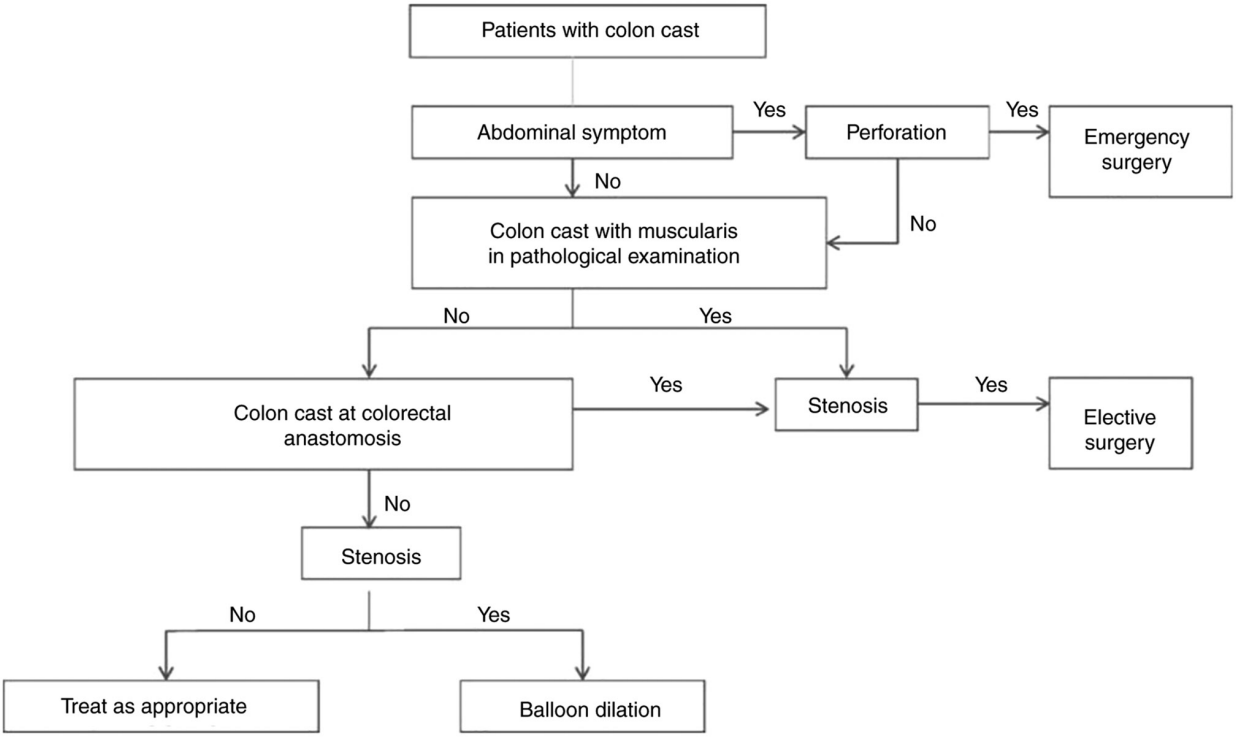

Figure 6. Management of CC cases. The current case had abdominal symptoms and no perforation. A pathological examination indicated an inflammatory, necrotic colonic mucosa, with no stenosis. The eroded colonic mucosa was expelled from the anus, and the patient was treated as appropriate.

been reported (6,13). The present case is consistent with the literature. We hypothesize that this may be related to the characteristics of colorectal vascular anatomy and blood perfusion. The colon is supplied by the superior mesenteric artery, inferior mesenteric artery and superior rectal artery. The splenic curvature of the colon and sigmoid colon are special, because of the limited collateral circulation in these two regions (15). Therefore, the left colon is the site most easily involved in IC, while rectal ischemia is less common, because it has a relatively rich double blood supply (15). In 2014, Abe *et al* (6) reported that the incidence of IC was 82.6% (19/23) in the left colon. In 2015, Cruz *et al* (13) reported that the incidence of IC was 62.7% (64/102) in the descending colon and 56.9% (58/102) in the sigmoid colon, and that the splenic curvature was rarely involved.

The initially reported cases of CC are marked by prompt interventions following the cast passage, presumably because of a desire to discover the pathology or fear of missing a lethal condition (16). The necessity for surgery is controversial. Foley *et al* (17) recommends that patients should undergo conservative treatment for a period of time to rest the bowel and use broad-spectrum antibiotics to cover the fecal flora to minimize intestinal ischemia. In the present case, acute abdominal pain and bloody stools were the main manifestations in the early stage of the disease, and intestinal obstruction and fever appeared later. After fasting, anti-inflammatory treatment with cefmetazole and fluid infusion, the condition of the patient gradually improved. On the second day after colonoscopy, the patient discharged the intestinal mucosa from the anus, and the intestinal obstruction and intestinal infection were gradually relieved. At 1 week later, colonoscopy showed that the symptoms of ischemic edema and intestinal stenosis were significantly improved.

During diagnosis and treatment of the patient, the present study revealed that the intestinal mucosal lesions of this type of IC could cause intestinal obstruction after forming tubular channels, and the CC was discharged from the anus after necrosis and shedding (14,18). The severity of the colonic mucosal ischemia determines the treatment (19). If pathological examination suggests that the lesions only affect the mucosa and submucosa and not the intrinsic muscle layer, IC including AMI and CMI, as well as CC can be treated conservatively, including the usage of broad-spectrum antibiotics, anticoagulants or nutritional supplementation, and the symptoms will disappear gradually, with no long-term sequelae (19). These cases are the so-called mild cases. To the best of our knowledge, such cases have not been reported before in mainland China. If the lesions affect deeper than the intrinsic muscle layer, they cause bowel stenosis or persistent colonic inflammation, which leads to chronic intestinal obstruction, gangrene and peritonitis. In these cases, emergency surgery cannot be avoided (19). If the cases have colorectal anastomosis or the lesion contains muscularis propria, surgical treatment was also suggested (Fig. 6).

The correct diagnosis and treatment of CC is important for a favorable outcome. Abe *et al* (6) reported that the pathologic depth of the layer of the excreted colon cast may be the key element in determining the appropriate treatment, if the lesions consisting of the mucosa/submucosa layer alone, without colorectal anastomosis might likely be managed by conservative therapy. Although less severe mild cases may present with similar symptoms, the prognosis and management are completely different depending on severity of the colonic mucosal ischemia and they are managed conservatively rather than surgically (20). In the present case, no gangrene was found by colonoscopy, and pathological examination indicated that the ischemia only involved the mucosal layer; therefore, it was a mild case of CC and could be cured by conservative medical treatment.

However, there are limitations to the present study, this was a single rare case, and the diagnostic and therapeutic experience for CC is limited because of the rarity of the disease. Therefore, further studies are needed to improve understanding of the comorbidities, pathology, diagnosis and treatment of CC.

In conclusion, CC is a rare type of IC. The diagnosis of CC should be based on the clinical presentation and pathological colonoscopy examination, and the depth of the layer of CC might be the key element in determining the appropriate treatment. Conservative therapy is also an effective treatment in the cases consisting of mucosa/submucosa layer, such as in the present case. The present case will improve our understanding of comorbidities, pathology, diagnosis and treatment of CC and IC.

Acknowledgements

Not applicable.

Funding

No funding was received.

Availability of data and materials

The datasets used and/or analyzed during the present study are available from the corresponding author on reasonable request.

Authors' contributions

JS performed the colonoscopy, reviewed the literature, and contributed to manuscript drafting. GC performed the pathological work. MZ designed the study and was responsible for manuscript drafting and analysis. JS and MZ confirm the authenticity of all the raw data. All authors have read and approved the final manuscript.

Ethics approval and consent to participate.

Not applicable.

Patient consent for publication

The patient provided written informed consent for publication.

Competing interests

The authors declare that they have no competing interests.

References

1. Brandt LJ, Feuerstadt P, Longstreth GF, Boley SJ and American College of Gastroenterology: ACG clinical guideline: Epidemiology, risk factors, patterns of presentation, diagnosis, and management of colon ischemia (CI). Am J Gastroenterol 110: 18-44, 2015.
2. Rania H, Mériam S, Rym E, Hyafa R, Amine A, Najet BH, Lassad G and Mohamed TK: Ischemic colitis in five point: An update 2013. Tunis Med 92: 299-303, 2014.
3. Yngvadottir Y, Karlsdottir BR, Hreinsson JP, Ragnarsson G, Mitev RUM, Jonasson JG, Möller PH and Björnsson ES: The incidence and outcome of ischemic colitis in a population-based setting. Scand J Gastroenterol 52: 704-710, 2017.
4. Ahmed M: Ischemic bowel disease in 2021. World J Gastroenterl 27: 4746-4762, 2021.
5. Speakman MJ and Turnbull AR: Passage of a colon 'cast' following resection of an abdominal aortic aneurysm. Br J Surg 71: 935, 1984.
6. Abe S, Yamaguchi H, Murono K, Kanazawa T, Ishihara S, Sunami E and Watanabe T: Passage of a sigmoid colon cast in a patient with ischemic colitis. Int Surg 99: 500-505, 2014.
7. Su TH, Liou JM and Wang HP: The passage of a colonic cast. Lancet 375: 2099, 2010.
8. Phillips RK and Armitage NC: Colon 'cast' in a patient with ischaemic colitis. Br J Surg 74: 759-760, 1987.
9. Feuerstadt P and Brandt LJ: Update on colon ischemia: Recent insights and advances. Curr Gastroenterol Rep 17:45, 2015.
10. Feuerstadt P and Brandt LJ: Colon ischemia: recent insights and advances. Curr Gastroenterol Rep 12: 383-390, 2010.
11. Xu Y, Xiong L, Li Y, Jiang X and Xiong Z: Diagnostic methods and drug therapies in patients with ischemic colitis. Int J colorectal Dis 36: 47-56, 2021.
12. Montoro MA, Brandt LJ, Santolaria S, Gomollon F, Sánchez Puértolas B, Vera J, Bujanda L, Cosme A, Cabriada JL, Durán M, *et al*: Clinic patterns and outcomes of ischaemic colitis: Results of the working group for the study of ischemic colitis in Spain (CIE study). Scand J Gastroenterol 46: 236-246, 2011.
13. Cruz C, Abujudeh HH, Nazarian RM and Thrall JH: Ischemic colitis: Spectrum of CT findings, sites of involvement and severity. Emerg Radiol 22: 357-365, 2015.
14. Mantas D, Damaskos C, Bamias G and Dimitroulis D: Colonic casts: Unexpected complications of colonic ischaemia. Ann R Coll Surg Engl 98: e109-e110, 2016.
15. Brandt LJ, Feueratadt P and Blaszka MC: Anatomic patterns, patient characteristics and clinical outcomes in ischemic colitis: A study of 313 cases supported by histology. Am J Gastroenterol 105: 2245-2252, 2010.
16. Gregory PJ and Barrett G: Spontaneous passage of a colon 'cast' in a patient with ischemic colitis. Br J Surg 74: 436, 1987.
17. Foley CL, Taylor CJ, Aslam M, Reddy KP, Birch HA and Owen ER: Failure of conservative management after the passage of a distal colonic 'cast': Report of a case. Dis Colon Rectum 48: 1090-1093, 2005.
18. Park YM, Lee CK and Kim HJ: Gastrointestinal: Colon cast with segmental stricture following colonic ischemia. J Gastroenterol Hepatol 34: 630-630, 2018.
19. Erguney S, Yavuz N, Ersoy YE, Teksoz S, Selcuk D, Ogut G, Dogusoy G and Alver O: Passage of 'Colonic Cast' after colorectal surgery: Report of four cases and review of the literature. J Gastrointest Surg 11: 1045-1051, 2007.
20. Maimone A, De Ceglie A, Siersema PD, Baron TH and Conio M: A comprehensive review. Clin Res Hepatol Gastroenterol 45: 101592, 2021.