Abscopal effect with fever of unknown cause during radiotherapy: Two case reports and review of the literature

YOSHIKO OSHIRO[1], MASASHI MIZUMOTO[2], TAKAYUKI HISANAGA[3], KEN TANAKA[4], MANABU KOMINE[4], MIZUKI TAKAHASHI[1,2], KOJI KIKUCHI[4] and HIDEYUKI SAKURAI[2]

[1]Department of Radiation Oncology, Tsukuba Medical Center Hospital, Tsukuba, Ibaraki 305-8558; [2]Department of Radiation Oncology, University of Tsukuba, Tsukuba, Ibaraki 305-8576; Departments of [3]Palliative Medicine and [4]Urology, Tsukuba Medical Center Hospital, Tsukuba, Ibaraki 305-8558, Japan

Received April 21, 2023; Accepted June 8, 2023

DOI: 10.3892/etm.2023.12209

Abstract. The abscopal effect is a rare phenomenon that is defined as regression of tumor lesions distant from irradiation targets. At our department, two cases with an abscopal effect with fever of unknown cause (FUC) and an inflammatory response during radiotherapy were encountered. Radiotherapy is a local treatment; therefore, it rarely causes systemic side effects during radiotherapy, and if a patient develops a fever during radiotherapy, it is frequently considered tumor fever. We experienced 2 cases of FUC during irradiation followed by abscopal effect. The obvious relationship between the abscopal effect and the fever remains to be clarified. However, FUC during radiotherapy may be a hint to the abscopal effect, considering that immune response and cytokines are closely related to the abscopal effect.

Introduction

Radiotherapy has an important role in the local treatment of malignancies. The mechanism of radiotherapy is mainly through the damage of deoxyribonucleic acid (DNA) inside the malignant cells in the irradiation field. However, the rare phenomenon of spontaneous regression in lesions distant from an irradiation field has been reported and is called 'abscopal effect'. The abscopal effect was initially suggested by Mole (1) in 1953. While the biological mechanism of this effect has remained to be completely elucidated, immunologic mechanisms are considered to mediate this effect. In recent years, tumor immunity in combination with immune checkpoint inhibitors (ICIs) has become of increasing interest in the abscopal effect. However, this phenomenon is rarely encountered in clinical practice, particularly for an abscopal effect to manifest itself without pharmacologic immunomodulation (pure abscopal effect) (2). The present study reported on two cases with abscopal effects: One showed a pure abscopal effect and the other occurred after resistance to immunotherapy. Fever of unknown cause (FUC) was observed immediately after initiation of radiotherapy in both cases. The relationship between this fever and the abscopal effect was unclear, but radiotherapy does not normally induce a systemic response. The symptoms at presentation, physical exams and laboratory results are provided for each case in the following section.

Case report

Case 1. A male patient aged 78 years was diagnosed with pleomorphic sarcoma of the iliac bone (size, 8.1x12.1x15.5 cm) with pelvic lymph node metastases and bilateral lung metastases at an external hospital in June 2019, and the treatment options of chemotherapy, radiotherapy and palliative care were considered. However, taking into account the patient's age, the patient and his family chose palliative care at our institution, and the patient was referred to the department of palliative medicine of Tsukuba Medical Center Hospital (Ibaraki, Japan) within the same month. Palliative photon radiotherapy of 36 Gy in 12 fractions over 16 days was indicated for iliac pain control and fracture prevention. The day after the start of radiotherapy, the patient complained of fever without respiratory or urinary tract symptoms. Fever of up to 38˚C was observed twice a day during the irradiation period. This fever broke spontaneously in 3 h after it started each time. Blood tests indicated no characteristic findings other than a mild inflammatory reaction and thrombocytopenia [C-reactive protein (CRP), 7.07 mg/dl (normal range: ≤0.3 mg/dl); platelets, $5.6x10^4/\mu l$ ($15\text{-}45x10^4/\mu l$). Celecoxib was prescribed for antipyretic and analgesic therapy but was ineffective. The fever continued for 2 days after the end of radiotherapy but then spontaneously resolved. After radiotherapy, no additional treatment was

Correspondence to: Dr Yoshiko Oshiro, Department of Radiation Oncology, Tsukuba Medical Center Hospital, Amakubo 1-3-1, Tsukuba, Ibaraki 305-8558, Japan
E-mail: ooyoshiko@hotmail.com

Abbreviations: ICI, immune checkpoint inhibitors; CT, computed tomography; CRP, C-reactive protein; PET, positron emission tomography; RCC, renal cell carcinoma; PFS, progression-free survival

Key words: abscopal effect, renal cell carcinoma, pleomorphic sarcoma, radiotherapy, unknown fever

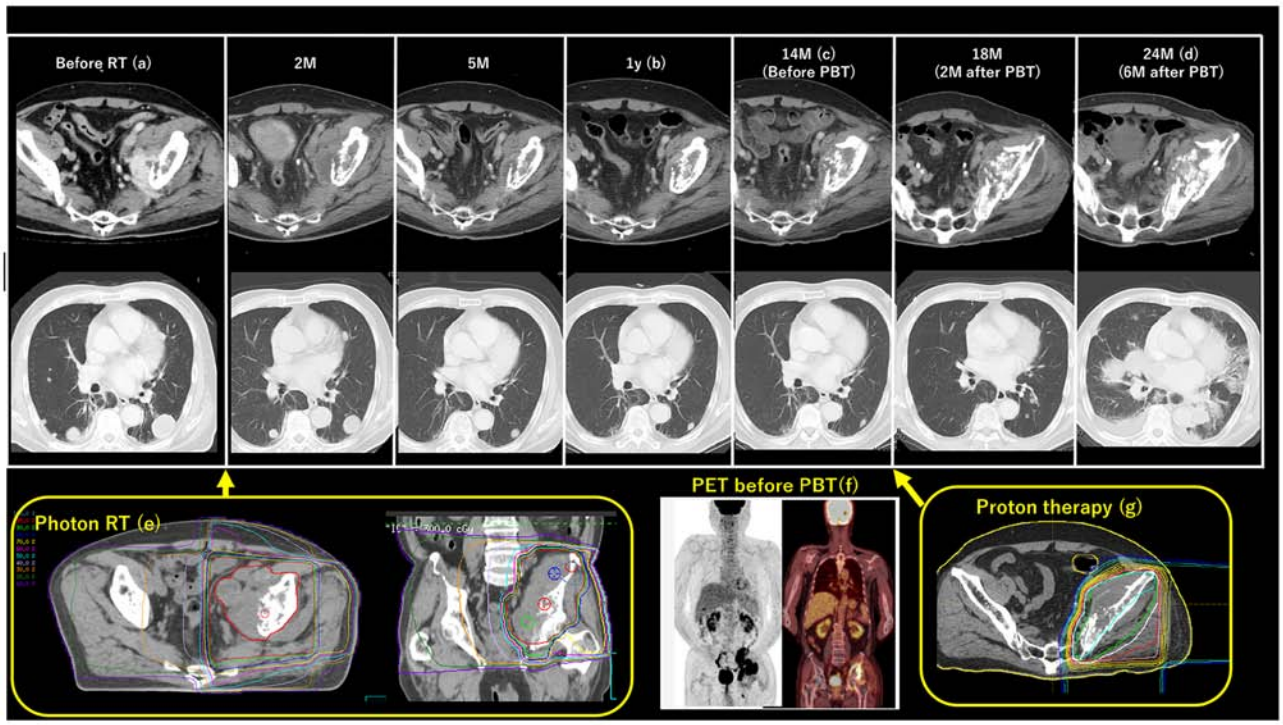

Figure 1. Clinical course and imaging series for iliac pleomorphic sarcoma (Case 1) and treatment planning for photon and protonradiotherapy. PBT, proton beam therapy; RT, radiation therapy; PET, positron emission tomography; M, months; y, years.

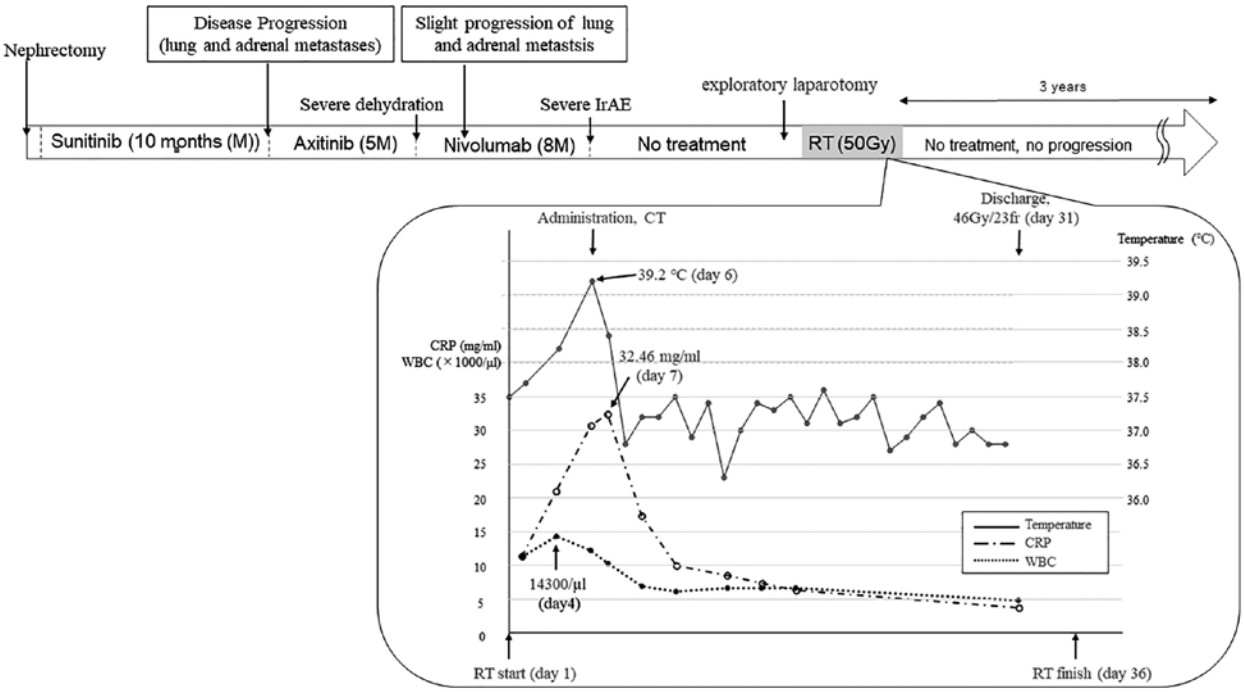

Figure 2. Clinical course during radiotherapy (Case 2). CRP, C-reactive protein; WBC, white blood cells; RT, radiation therapy; IrAE, immune-related adverse events.

given except for drugs for pain relief. Pain improved gradually and the patient started to be able to walk on his own 3 months after radiotherapy. Computed tomography (CT) indicated significant shrinkage of the primary irradiated tumor and lung metastases. At one year after radiotherapy, the primary tumor size was 3.6x6x5.5 cm. However, 14 months after radiotherapy, the patient complained of left coxalgia again and the iliac tumor had slightly increased. At this time, the tumor size was 4.4x8x6 cm, but lung metastases still remained small and ^{18}fluorodeoxyglucose-positron emission tomography

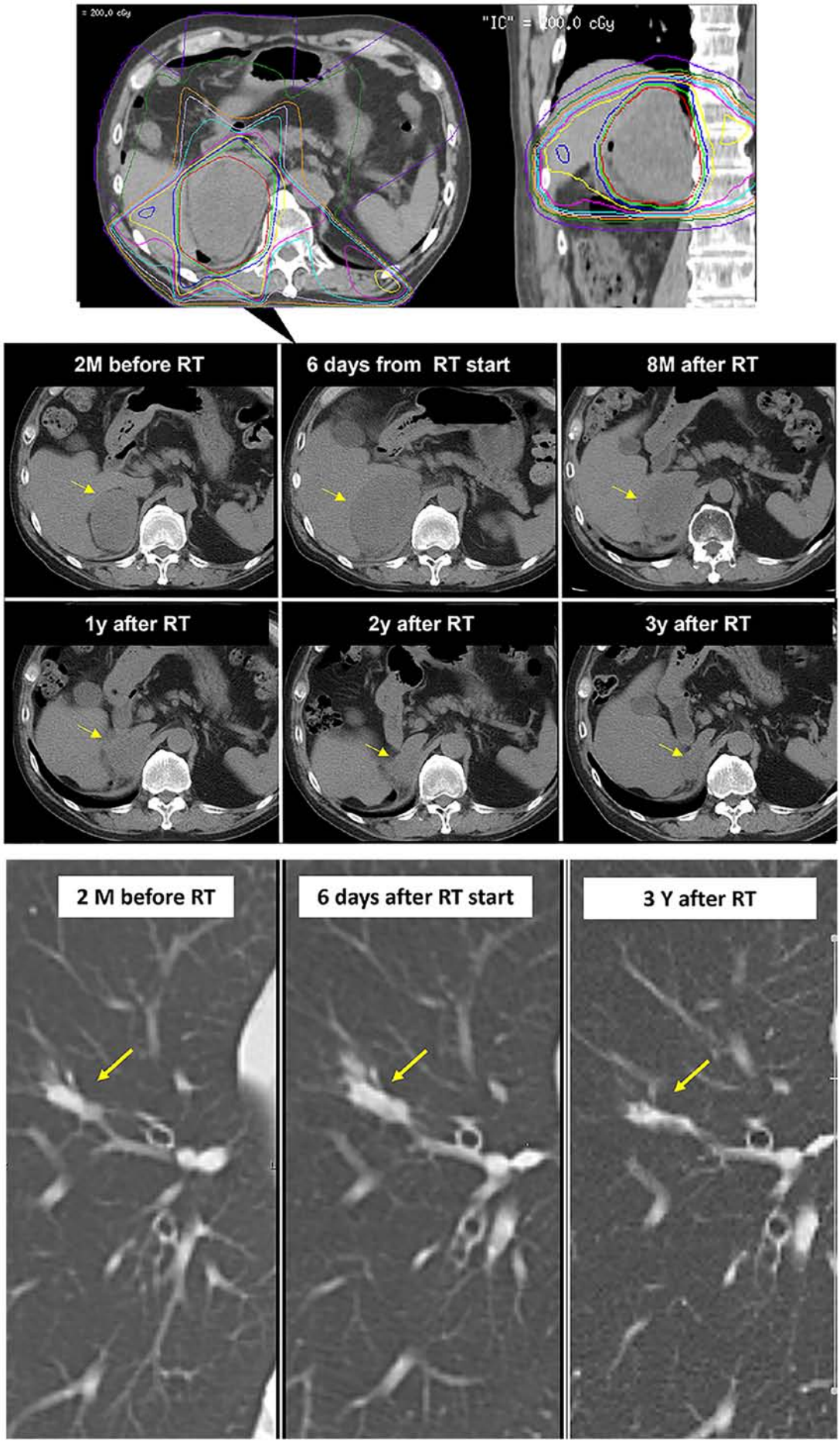

Figure 3. Images for adrenal and lung metastases (Case 2). Lesions are indicated by yellow arrows. IC, iso-center; RT, radiation therapy; M, months; y, years.

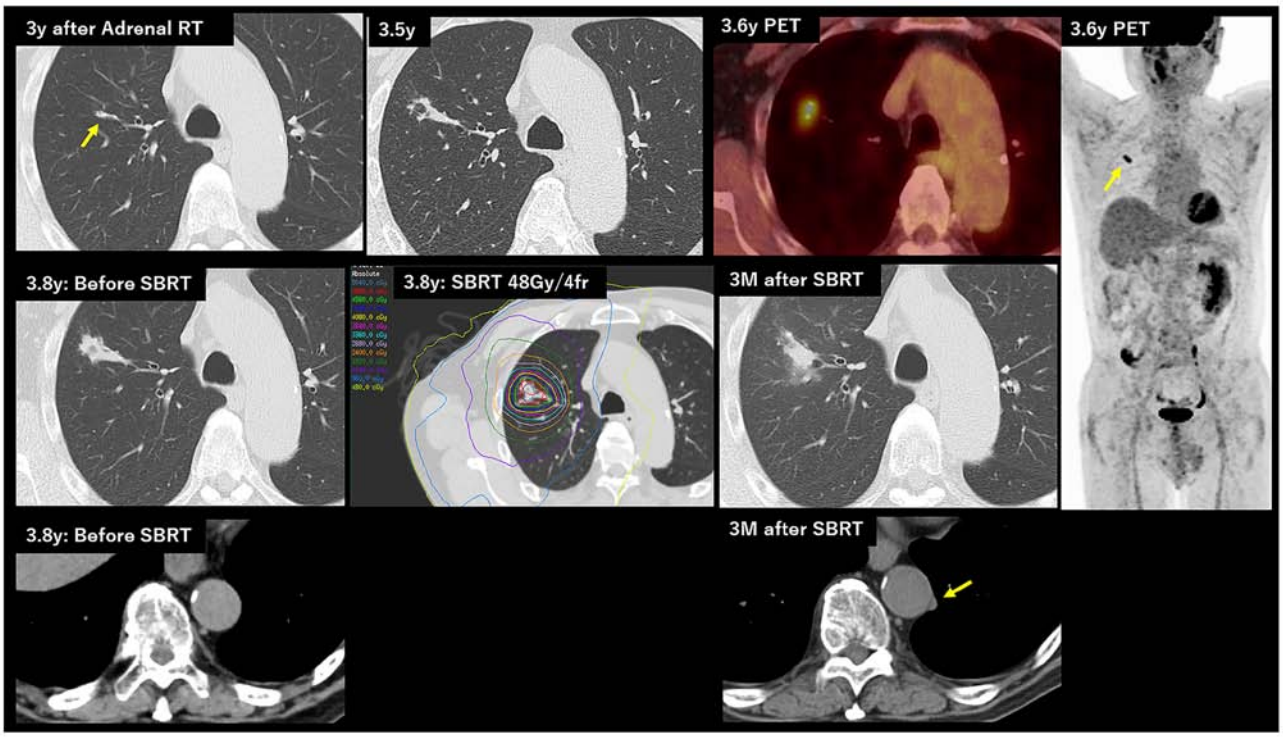

Figure 4. Images of lung for Case 2. SBRT was performed for increasing lung metastasis. After the SBRT, enlargement of ground glass opacity around the tumor and a new nodule (arrow) were observed. RT, radiation therapy; PET, positron emission tomography; M, months; y, years; SBRT, stereotactic body radiotherapy.

(PET) indicated no accumulation except for the iliac tumor. Reirradiation with photon radiotherapy was impossible because the alimentary tract could not be avoided; therefore, proton therapy of 51 Gy in 17 fractions over 27 days was used for the iliac tumor. During this course, there was no fever. Pain was slightly relieved, but the tumor did not shrink at all. The tumor then rapidly increased in size and lung metastases also progressed markedly. After proton therapy, palliative care was offered and the patient died from lung lymphangitis. The timeline, CT, PET images and the treatment fields of photon and proton radiotherapy are presented in Fig. 1.

Case 2. A 59-year-old male patient was diagnosed with renal cell cancer based on CT at the time of admission to Tsukuba Medical Center Hospital (Ibaraki, Japan) due to capsular hemorrhage in March 2016. After recovering from this hemorrhage, a close examination for renal cell carcinoma (RCC) revealed metastasis to renal hilum lymph nodes and lung metastases, and the clinical stage was T3aN1M1. Nephrectomy was performed in 2016 and the pathological results indicated clear cell carcinoma. Sunitinib was started one month after nephrectomy, and lung and lymph node metastases decreased. Sunitinib was continued for 10 months, then after the lung metastases increased and right adrenal metastasis appeared, treatment was switched to axitinib and the metastases shrank again. However, severe chemical dehydration occurred 5 months after the start of axitinib; therefore, nivolumab was started thereafter and continued for 8 months, despite slight progression of lung and adrenal metastases 2 months after the start of nivolumab. However, nivolumab was then stopped due to severe immune-related adverse events of pituitary insufficiency followed by infectious endocarditis and severe ischemic enteritis. Subsequently, no additional drug therapy was given and in the 8 months after stopping nivolumab, right adrenal metastasis increased to 70x54 mm. Other metastases remained small. At that time, the size of the lung metastasis was 12.8x4.4 mm. Therefore, resection of the adrenal metastasis was attempted; however, this proved to be impossible due to strong adhesion. Radiotherapy was then considered and photon radiotherapy of 50 Gy in 25 fractions over 36 days was delivered with palliative intent. On the first day of the radiotherapy, the patient had a fever of 37.5˚C after returning home from radiotherapy. On the second day, blood tests were performed because the fever persisted and a high inflammatory response was observed: White blood cells (WBC), 14,300/μl (normal range: 3,100-8,400/μl); and CRP, 11.38 mg/dl. The fever was not broken with oral aspirin and the inflammatory reaction rapidly increased; the body temperature reached 39.2˚C and CRP was 32.46 mg/dl. CT was performed to search for the cause of inflammation on the 6th day, but it could not be identified. At this time, the adrenal metastasis increased to 97x69 mm and one of the lung metastases had slightly increased to 13.6x4.8 mm, compared to 4 months earlier. Urine tests and blood and urine cultures were all negative. Therefore, it was considered that the inflammation was caused by the tumor itself, and radiotherapy was continued despite the high inflammatory response. The inflammatory reaction gradually decreased spontaneously during the treatment period. The treatment course of Case 2 is presented in Fig. 2. After radiotherapy, the adrenal metastasis shrunk gradually and had reached a size of 35x25 mm by June 2022. The pulmonary metastases also slightly shrank to 9.7x3.1 mm.

The treatment field and CT images of the lung and adrenal metastases until June 2022 are presented in Fig. 3.

However, in December 2022, the lung metastasis exhibited certain changes of calcification and dilatation of downstream bronchus with endobronchial effusion. This finding suggested secondary tracheal atresia, fungal infection or tumor recurrence. However, blood tests were all negative for serum beta-D-glucan (3), *Aspergillus* antigen, *Mycobacterium avium complex* antibody and the QuontiFeron test (4), which ruled out a fungal or mycobacterium infection. After one month, the lung tumor had continued to grow and PET accumulation was observed, so this change of lung metastasis was diagnosed as recurrence. There was no PET accumulation for adrenal metastasis. Bronchoscopy was not performed due to hemorrhage risk. Considering oligo-progression and previous adverse effects of tyrosine kinase inhibitor and ICI, stereotactic body radiotherapy (SBRT) to the lung metastasis with a dose of 48 Gy in 4 fractions was performed in February 2023. This time, no fever or CRP/WBC elevation was observed. After 3 months from the SBRT, tumor consolidation was observed and ground glass opacity around the tumor was enlarged. This change suggested tumor progression, tumor hemorrhage or inflammation after SBRT. In addition, new subpleural nodules were observed and lung atelectasis or lung metastasis was considered for this nodule. The size of the adrenal metastasis has remained unchanged since June 2022. This patient will continue to be followed up. The CT and PET images and treatment field of the lung are presented in Fig. 4.

Discussion and literature review

Abscopal effect has been reported in various carcinomas. Siva *et al* (5) suggested that this effect is transmitted by an acute inflammatory cytokine cascade and the immune system. Ionizing radiation releases cytokines, which elicit augmented tumor surveillance, inhibit tumor growth and have direct tumoricidal properties (6). In addition, ionizing radiation directly elicits innate immune recognition of a tumor: Dendritic cells are activated by irradiated dying cells and antitumor T cells are activated by the cross-presentation of tumor-derived antigens presented to T cells (7).

In clinical practice, however, an abscopal effect of radiotherapy alone is rare. In a literature review of abscopal effects of radiotherapy, only 46 cases reported between 1969 and 2014 were retrieved (8). However, the number of reports of abscopal effect in patients treated with a combination of radiotherapy and ICI has increased (9-17). In only one year, 2021, 21 case reports of abscopal effect promoted after radiotherapy were yielded (15,18-37). This is thought to be due to T-cell activation by a damage signal from irradiated dying cells and upregulation of programmed death receptor-1 and programmed cell death 1-ligand 1 (38,39), and an ICI disarms immune escape mechanisms, and this may increase the effects of the innate immune response activated by radiotherapy. Grimaldi *et al* (40) reported an abscopal response in 52% of patients with melanoma who received ipilimumab followed by radiotherapy.

In the present study, two cases of abscopal effect were reported. The most characteristic feature of the two cases is that both patients had FUC soon after the start of radiotherapy. Case 1, the patient with pleomorphic sarcoma, featured a pure abscopal effect. In this case, a fever was observed during the initial irradiation period, but since it was mild and there were no signs of infection, not much attention was paid to it. By contrast, the re-irradiation using proton therapy did not cause fever and no abscopal effect was observed. Case 2, a patient with RCC, exhibited an abscopal effect following radiotherapy after ICI. RCC frequently has periods of disease quiescence; however, lung metastasis in this case had an increasing trend at the start of radiotherapy; therefore, it was expected to increase after radiotherapy to the adrenal metastasis. In general, the prognosis of RCC after disease progression during treatment with an ICI is poor. In a retrospective analysis of 33 patients from 7 clinical trials, Barata *et al* (41) found a median progression-free survival (PFS) from initiation of molecular targeted therapy after progression on an ICI of 6.4 months (95% CI: 4.4-8.4 months). Roviello *et al* (42) obtained a PFS of 5 and 3 months (95% CI: 1-6 vs. 2-5; P=0.6) for patients who received active treatment and best supportive care, respectively, after progression of metastatic RCC while on nivolumab and cabozantinib. However, in Case 2 of the present study, adrenal metastasis was well controlled with a palliative dose and lung metastasis shrank over 3 years. This may be due to enhanced immune response to nivolumab and the strong inflammatory response observed during radiotherapy was also related to immune response. After almost 4 years, the lung metastasis recurred and SBRT was performed. This time, no inflammatory response was observed, and the disease is suspected to be progressing.

There was no evidence of a relationship between the abscopal effect and fever during radiotherapy. However, the abscopal effect is known to involve the activation of inflammatory cytokines and these two phenomena are both so unusual that they may not be coincidental. The two cases in the present study were treated palliatively and detailed data are missing. However, given that an inflammatory cytokine cascade is involved in the abscopal effect, it may be concluded that FUC during radiotherapy may be a hint to the abscopal effect, not by coincidence, although it is frequently considered as a tumor fever without much of a concern.

In conclusion, abscopal effect is rare and difficult to predict. A total of 2 cases of abscopal effect with FUC during radiotherapy were encountered at our institution. Awareness of FUC during radiotherapy may offer the possibility of better patient follow-up.

Acknowledgements

Not applicable.

Funding

No funding was received.

Availability of data and materials

The datasets used and/or analyzed during the current study are available from the corresponding author on reasonable request.

Authors' contributions

YO conducted photon radiotherapy on the 2 patients and wrote a draft of the manuscript. MM and HS conducted proton therapy on Case 1. MT and YO followed up Case 2. TH provided care for Case 1. MK, KT and KK provided care for Case 2. All authors contributed to manuscript revision, and have read and agreed to be accountable for the content of the work. All authors have read and approved the final manuscript. YO and MM checked and confirmed the authenticity of all the raw data.

Ethics approval and consent to participate

Not applicable.

Patient consent for publication

Written informed consent for the publication of this manuscript, including case data and images, was obtained from each patient.

Competing interests

The authors declare that they have no competing interests.

References

1. Mole RH: Whole body irradiation; radiobiology or medicine? Br J Radiol 26: 234-241, 1953.
2. Ellerin BE, Demandante CGN and Martins JT: Pure abscopal effect of radiotherapy in a salivary gland carcinoma: Case report, literature review, and a search for new approaches. Cancer Radiother 24: 226-246, 2020.
3. Obayashi T, Yoshida M, Mori T, Goto H, Yasuoka A, Iwasaki H, Teshima H, Kohno S, Horiuchi A, Ito A, *et al*: Plasma (1-3)-beta-D-glucan mesurement in didagnosis of invasive deep mycosis and fungal febrile episodes. Lancet 345: 17-20, 1995.
4. Mazurek GH and Villarino ME; CDC: Guidelines for using the QuantiFERON-TB test for diagnosing latent Mycobacterium tuberculosis infection. Centers for Disease Control and Prevention. MMWR Recomm Rep 52(RR-2): 15-18, 2013.
5. Siva S, MacManus MP, Martin RF and Martin OA: Abscopal effects of radiation therapy: A clinical review for the radiobiologist. Cancer Lett 356: 82-90, 2015.
6. Kaminski JM, Shinohara E, Summers JB, Niermann KJ, Morimoto A and Brousal J: The controversial abscopal effect. Cancer Treat Rev 31: 159-172, 2005.
7. Obeid M, Tesniere A, Ghiringhelli F, Fimia GM, Apetoh L, Perfettini JL, Castedo M, Mignot G, Panaretakis T, Casares N, *et al*: Calreticulin exposure dictates the immunogenicity of cancer cell death. Nat Med 13: 54-61, 2007.
8. Abuodeh Y, Venkat P and Kim S: Systematic review of case reports on the abscopal effect. Curr Probl Cancer 40: 25-37, 2016.
9. Postow MA, Callahan MK, Barker CA, Yamada Y, Yuan J, Kitano S, Mu Z, Rasalan T, Adamow M, Ritter E, *et al*: Immunologic correlates of the abscopal effect in a patient with melanoma. N Engl J Med 366: 925-931, 2012.
10. Golden EB, Demaria S, Schiff PB, Chachoua A and Formenti SC: An abscopal response to radiation and ipilimumab in a patient with metastatic non-small cell lung cancer. Cancer Immunol Res 1: 365-372, 2013.
11. Hori K, Hirohashi Y, Aoyagi T, Taniguchi N, Murakumo M, Miyata H, Torigoe T, Abe T, Shinohara N and Morita K: Abscopal effect following nivolumab induction in a patient with metastatic renal cell carcinoma-unique pathological features of the primary specimen: A case report. Exp Ther Med 19: 1903-1907, 2020.
12. Kuryk L, Moller AW and Jaderberg M: Abscopal effect when combining oncolytic adenovirus and checkpoint inhibitor in a humanized NOG mouse model of melanoma. J Med Virol 91: 1702-1706, 2019.
13. Nakajima N, Kano T, Oda K, Uchida T, Otaki T, Nagao K, Shimizu Y, Kawakami M, Kim H, Nitta M, *et al*: Possible abscopal effect after discontinuation of nivolumab in metastatic renal cell carcinoma. IJU Case Rep 3: 215-218, 2020.
14. Oei AL, Korangath P, Mulka K, Helenius M, Coulter JB, Stewart J, Velarde E, Crezee J, Simons B, Stalpers LJA, *et al*: Enhancing the abscopal effect of radiation and immune checkpoint inhibitor therapies with magnetic nanoparticle hyperthermia in a model of metastatic breast cancer. Int J Hyperthermia 36(sup1): S47-S63, 2019.
15. Sezen D, Patel RR, Tang C, Onstad M, Nagarajan P, Patel SP, Welsh JW and Lin LL: Immunotherapy combined with high- and low-dose radiation to all sites leads to complete clearance of disease in a patient with metastatic vaginal melanoma. Gynecol Oncol 161: 645-652, 2021.
16. Ishiyama Y, Takagi T, Yoshida K, Iizuka J, Kakuta Y, Okumi M, Ishida H and Tanabe K: Possible abscopal effect in urothelial carcinoma of the upper urinary tract after treatment with immune checkpoint inhibitors. IJU Case Rep 3: 25-27, 2019.
17. Song HN, Jin H, Kim JH, Ha IB, Kang KM, Choi HS, Jeong HJ, Kim MY, Kim HJ and Jeong BK: Abscopal effect of radiotherapy enhanced with immune checkpoint inhibitors of triple negative breast cancer in 4T1 mammary carcinoma model. Int J Mol Sci 22: 10476, 2021.
18. Damante MA, Huntoon KM, Palmer JD, Liebner DA and Elder JB: A case of multiple synchronously diagnosed brain metastases from alveolar soft part sarcoma without concurrent lung involvement. Surg Neurol Int 12: 111, 2021.
19. D'Andrea MA and Reddy GK: Systemic effects of radiation therapy-induced abscopal responses in patients with advanced lung cancer. Oncology 99: 1-14, 2021.
20. Fiorica F, Belluomini L, Giuliani J, Urbini B, Milella M, Frassoldati A, Pilotto S and Giorgi C: Abscopal effect and resistance reversion in nivolumab-treated non-small-cell lung cancer undergoing palliative radiotherapy: A case report. Immunotherapy 13: 971-976, 2021.
21. Herrscher H, Sauer B, Truntzer P and Robert C: Abscopal antitumor effect in a patient with melanoma and coronavirus disease 2019. Eur J Cancer 149: 91-93, 2021.
22. Hotta T, Okuno T, Nakao M, Amano Y, Isobe T and Tsubata Y: Reproducible abscopal effect in a patient with lung cancer who underwent whole-brain irradiation and atezolizumab administration. Thorac Cancer 12: 985-988, 2021.
23. Huynh LM, Bonebrake BT, DiMaio DJ, Baine MJ and Teply BA: Development of bullous pemphigoid following radiation therapy combined with nivolumab for renal cell carcinoma: A case report of abscopal toxicities. Medicine (Baltimore) 100: e28199, 2021.
24. Kim TH and Chang JS: Abscopal effect after palliative five-fraction radiation therapy on bone and lymph node metastases from luminal B breast cancer: A case report and clinical implications for palliative radiation therapy. Radiat Oncol J 39: 139-144, 2021.
25. Kondo T, Nakatsugawa M, Okubo M, Nakamura H, Yunaiyama D, Wakiya M, Takeda A, Kikawada N, Kishida T, Someya M, *et al*: Laryngeal cancer with lung metastases showing long-term complete response and delayed immune-related adverse event after nivolumab discontinuation. Ear Nose Throat J 1455613211031025, 2021.
26. Mampuya WA, Bouchaab H, Schaefer N, Kinj R, La Rosa S, Letovanec I, Ozsahin M, Bourhis J, Coukos G, Peters S and Herrera FG: Abscopal effect in a patient with malignant pleural mesothelioma treated with palliative radiotherapy and pembrolizumab. Clin Transl Radiat Oncol 27: 85-88, 2021.
27. Mazzaschi G, Tommasi C, Pietri E, Corcione L, De Giorgi A, Bini P and Bui S: Abscopal effect as part of treatment of oligometastatic head and neck cancer: A case report. Clin Case Rep 9: 1334-1338, 2021.
28. Moradi LA, Clark CA, Schneider CS, Deshane AS and Dobelbower MC: Durable metastatic melanoma remission following pembrolizumab and radiotherapy: A case report of prophylactic immunosuppression in a patient with myasthenia gravis and immune-mediated colitis. Front Immunol 12: 788499, 2021.
29. Muto M, Nakata H, Ishigaki K, Tachibana S, Yoshida M, Muto M, Yanagawa N and Okumura T: Successful treatment of advanced gastric cancer with brain metastases through an abscopal effect by radiation and immune checkpoint inhibitor therapy. J Gastric Cancer 21: 319-324, 2021.

30. Ohmatsu K, Hashimoto Y, Kawanishi M, Ishii Y, Kono S, Kuribayashi S, Ariizumi S and Karasawa K: Abscopal complete regression of hepatocellular carcinoma with multiple pleural metastases. Int Cancer Conf J 10: 54-58, 2021.
31. Piercey O, Tomaszewski JM and Smith K: Intracranial response after extracranial radiation in a patient with rapidly progressing metastatic melanoma. BMJ Case Rep 14: e240921, 2021.
32. Sakamoto T, Fujimoto N and Nakashima M: One course of pembrolizumab after radiation therapy was very effective against metastatic bladder cancer and Cr was confirmed: A case report. Nihon Hinyokika Gakkai Zasshi 112: 220-223, 2021 (In Japanese).
33. Vilinovszki O, Andratschke N, Huellner M, Curioni-Fontecedro A and Kroeze SGC: True abscopal effect in a patient with metastatic non-small cell lung cancer. Radiat Oncol 16: 194, 2021.
34. Wu M, Liu J, Seery S, Meng X and Yue J: Cytoreductive nephrectomy promoted abscopal effect of camrelizumab combined with radiotherapy for metastatic renal cell carcinoma: A case report and review of the literature. Front Immunol 12: 646085, 2021.
35. Yamaguchi T, Fushida S, Kinoshita J, Saito H, Shimada M, Terai S, Moriyama H, Okamoto K, Nakamura K, Ninomiya I and Inaki N: A case of primary malignant melanoma of the esophagogastric junction with abscopal effect after nivolumab administration. Surg Case Rep 7: 253, 2021.
36. Zhang X, Zhang Y, Liu Y, Yang Y, Dong P, He L and Zhou F: Stereotactic body radiotherapy-induced abscopal effect twice after pembrolizumab failure in hereditary leiomyomatosis and renal cell carcinoma: A case report with genetic and immunologic analysis. Transl Androl Urol 10: 4304-4312, 2021.
37. Zhang YS, Zhang YH, Li XJ, Hu TC, Chen WZ, Pan X, Chai HY and Ye YC: Bystander effect and abscopal effect in recurrent thymic carcinoma treated with carbon-ion radiation therapy: A case report. World J Clin Cases 9: 6538-6543, 2021.
38. Deng L, Liang H, Burnette B, Beckett M, Darga T, Weichselbaum RR and Fu YX: Irradiation and anti-PD-L1 treatment synergistically promote antitumor immunity in mice. J Clin Invest 124: 687-695, 2014.
39. Lauber K and Dunn L: Immunotherapy mythbusters in head and neck cancer: The abscopal effect and pseudoprogression. Am Soc Clin Oncol Educ Book 39: 352-363, 2019.
40. Grimaldi AM, Simeone E, Giannarelli D, Muto P, Falivene S, Borzillo V, Giugliano FM, Sandomenico F, Petrillo A, Curvietto M, *et al*: Abscopal effects of radiotherapy on advanced melanoma patients who progressed after ipilimumab immunotherapy. Oncoimmunology 3: e28780, 2014.
41. Barata PC, De Liano AG, Mendiratta P, Crolley V, Szabados B, Morrison L, Wood L, Allman K, Tyler A, Martin A, *et al*: The efficacy of VEGFR TKI therapy after progression on immune combination therapy in metastatic renal cell carcinoma. Br J Cancer 119: 160-163, 2018.
42. Roviello G, Gambale E, Giorgione R, Santini D, Stellato M, Fornarini G, Rebuzzi SE, Basso U, Bimbatti D, Doni L, *et al*: Effect of systemic therapies or best supportive care after disease progression to both nivolumab and cabozantinib in metastatic renal cell carcinoma: The Meet-Uro 19BEYOND study. Cancer Med 11: 3084-3092, 2022.