Subsequent pregnancy in women who have undergone bilateral uterine artery ligation during cesarean section: A case series

JIAN AN

Department of Gynecology, Women and Children's Hospital, School of Medicine, Xiamen University, Xiamen, Fujian 361000, P.R. China

Received February 14, 2023; Accepted September 20, 2023

DOI: 10.3892/etm.2023.12296

Abstract. Bilateral uterine artery ligation (BUAL) serves as an effective surgical devascularization procedure in obstetric emergencies. However, concerns regarding the impact of uterine devascularization have evoked dispute. Here, the fetal growth index and obstetrical outcomes during the subsequent pregnancy of women who had undergone BUAL during cesarean section are reported. The case series of women who underwent BUAL during cesarean section and had another delivery later at the Xiamen Women and Children's Hospital between 2011 and 2020 is described. Pregnancies that did not continue beyond 20 weeks of gestation were excluded. Cases were identified from neonatal and obstetric databases and the clinical data of all cases were extracted. A total of 12 cases were identified retrospectively. Fetal biometric parameters of subsequent pregnancies in all cases including biparietal diameter, head circumference, abdominal circumference, and femur length are presented graphically across the different gestational ages and were all within the range of the 3rd-97th percentile. No maternal or neonatal morbidity was observed. BUAL did not appear to compromise a woman's subsequent obstetric outcomes. As a safe and simple surgical technique, it is safe to recommend BUAL in clinical practice.

Introduction

Uterine devascularization methods, including bilateral ligation of hypogastric (internal iliac) arteries, uterine devascularization procedures, and radiological arterial embolization (1-4), have long been practiced as effective management in obstetric emergencies caused by excessive bleeding. As a quick and simple surgical devascularization procedure, bilateral uterine artery ligation (BUAL) can decrease the blood supply to the uterus and effectively reduce intraoperative blood loss, and reduce the incidence of postpartum hemorrhage (PPH) and the urgent hysterectomy rate (5). However, some obstetricians hold the view that the adverse effects of this invasive procedure on patients' subsequent fertility and obstetrical outcomes should be considered (6-8). It has been suggested that infertility, intrauterine synechia, placenta accreta, and certain adverse pregnancy outcomes are associated with uterine devascularization, and therefore this procedure should be performed taking these possibilities into consideration.

Concerns regarding the impact following uterine devascularization have led some investigators to conduct relevant studies. Reports indicate that uterine devascularization does not appear to adversely affect the menstrual and fertility outcomes of the majority of women, but their sample sizes are small (9-11). Conversely, there are also studies on uterine artery Doppler scans revealing that the recanalization rate and isolated uterine blood supply are low following BUAL (12,13), and assessment for intrauterine fetal growth restriction in the next pregnancy is recommended.

To date, to the best of our knowledge, no studies have reported the fetal growth index in the subsequent pregnancy and discussed whether intrauterine growth restriction (IUGR) is related to BUAL. Therefore, the aim of the current case series was to describe the fetal growth index and obstetrical outcomes during the subsequent pregnancy of women who had undergone BUAL due to obstetric emergencies in a single center over a 9-year period.

Patients and methods

The present study was approved by the Institutional Board Review of Xiamen Women and Children's Hospital. A total of 12 cases were identified retrospectively from the clinical database of Xiamen Women and Children's Hospital. This database is an electronic record of all patients admitted to the Xiamen Women and Children's Hospital since 2011. This database was queried to obtain a list of all patients who had at least two hospital deliveries from October 2011 to December 2020. Women who underwent BUAL during cesarean section and had another delivery later were included. Patients whose pregnancies did not continue beyond 20 weeks of gestation were excluded, as delivery records were built in the database only when the gestational age at delivery was ≥20 weeks.

Correspondence to: Dr Jian An, Department of Gynecology, Women and Children's Hospital, School of Medicine, Xiamen University, 10 Zhenhai Road, Xiamen, Fujian 361000, P.R. China
E-mail: anjian1994@foxmail.com

Key words: artery ligation, intrauterine retardation, fetal biometry parameters, maternal and neonatal outcome

Table I. Clinical characteristics of the patients who underwent bilateral uterine artery ligation.

Case	Age, years	Parity	Reason for cesarean	Indication for BUAL	Other surgical management	Term of delivery, weeks	Fetal birth weight, g	Maternal and neonatal outcome
1	24	0	Failed induction of labor	Durative intrauterine bleeding	Bakri Postpartum Balloon	41	3,870	PPH
2	21	0	Central placenta	Durative intrauterine bleeding	None	32	1,300	Neonatal death
3	26	0	Suspected of macrosomia	Hematoma of broad	None	40	2,950	PPH
4	27	0	Suspected of macrosomia	Uterine atony	None	40	4,100	PPH
5	29	0	Amniotic fluid pollution, OCT (+)	Uterine atony	B-lynch	41	3,850	PPH
6	31	0	Failed induction of labor	Durative intrauterine bleeding	None	40	3,460	Normal
7	28	0	Persistent OT	Durative intrauterine bleeding	B-lynch	39	3,510	PPH
8	21	0	Persistent OP	Durative intrauterine bleeding	B-lynch	40	3,670	PPH
9	20	0	Multiple pregnancy	Uterine atony	None	37	2,680, 2,800	Normal
10	27	0	Failed induction of labor	Durative intrauterine bleeding	None	41	4,220	Normal
11	32	1	Suspected of placental abruption	Durative intrauterine bleeding	None	28	1,130	Normal
12	29	0	Multiple pregnancy	Uterine atony	B-lynch	37	2580, 2450	Normal

BUAL, bilateral uterine artery ligation; OCT, oxytocin challenge test; OT, occiput transverse; OP, occiput posterior; PPH, postpartum hemorrhage.

The clinical characteristics of the 12 patients who had undergone BUAL during cesarean delivery in a previous pregnancy are described in Table I. BUAL was performed in all patients for PPH. In all patients, the principal contributor to hemorrhage was durative intrauterine bleeding and uterine atony, which did not respond to oxytocic drugs. All the patients required blood transfusions. No maternal deaths were recorded, and no surgical complications arose during the BUAL.

Results

The delay before a subsequent pregnancy following BUAL was 2-7 years. As biparietal diameter (BPD), head circumference (HC), abdominal circumference (AC), and femur length (FL) are fetal biometric parameters for intrauterine growth restriction calculations, for the subsequent pregnancy, the data of fetal biometry parameters were fitted to the gestational age in weeks (gestational age) satisfactorily with a cubic polynomial model (Fig. 1). Parameters for all the patients were within the range of the 3rd-97th percentile (14) according to gestational age.

The outcomes of the 12 patients in the subsequent pregnancy after BUAL are described in Table II. For 7 of the 12 cases, the mode of delivery was cesarean section, and five had a vaginal delivery. There were no cases of PPH or maternal or neonatal death in the series. Follow-ups were performed by telephone annually, and all children in the study exhibited normal development.

Discussion

Ligation of the uterine artery is a simple procedure that can be adopted in emergency situations, even by obstetricians with limited training. For decades, ligation of the uterine artery was theoretically and erroneously assumed to shut off the uterine blood supply, which may thus result in hypoxemic injury of the uterus, leading to endometrial or myometrial damage. Furthermore, it may cause placental dysfunction and subsequent placental disorders, leading to IUGR in subsequent pregnancies (15,16).

Apart from occasional reported complications, overall data appear reassuring regarding the long-term fertility and obstetric outcomes after ligation of the uterine artery (9-11,17,18), according to data on the return of menses, the subsequent new pregnancies, and re-canalization of arteries and normal blood flow in the uterine artery as shown by color Doppler examination (19). To the best of our knowledge, no previous

Table II. Outcomes of the subsequent pregnancies after bilateral uterine artery ligation for obstetric emergencies.

Case	Period since previous delivery, months	Mode of delivery	Term of delivery, weeks	BUAL	PPH	Fetal birth weight, g	Maternal and neonatal outcome
1	41	Cesarean section	41	Yes	No	3,840	Normal
2	31	Vaginal delivery	36	No	No	2,485	Normal
3	35	Cesarean section	39	No	No	3,280	Normal
4	80	Cesarean section	38	No	No	3,490	Normal
5	52	Cesarean section	39	No	No	3,310	Normal
6	39	Cesarean section	39	No	No	3,420	Normal
7	84	Cesarean section	39	No	No	4,030	Normal
8	37	Cesarean section	40	No	No	3,540	Normal
9	34	Vaginal delivery	38	No	No	3,120	Normal
10	55	Vaginal instrumental delivery (forceps)	40	No	No	3,965	Normal
11	87	Vaginal delivery	37	No	No	2,695	Normal
12	34	Vaginal delivery	38	No	No	3,325	Normal

BUAL, bilateral uterine artery ligation; PPH, postpartum hemorrhage.

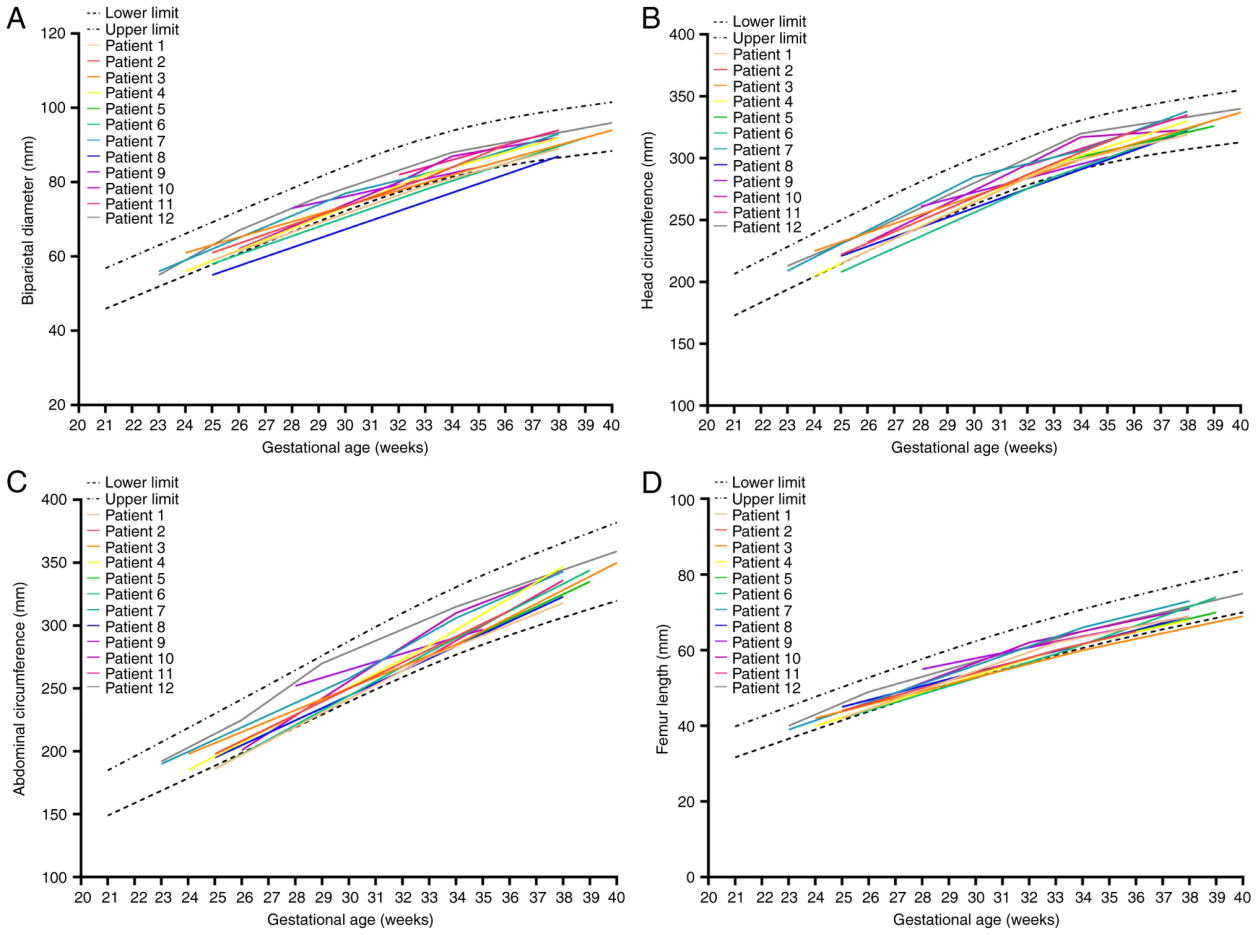

Figure 1. Fitted 3rd and 97th percentile curves superimposed on the raw data for (A) biparietal diameter, (B) head circumference, (C) abdominal circumference, and (D) femur length.

studies have reported complications in pregnancy, such as IUGR, and subsequent maternal and neonatal outcomes. In the present study, no IUGR or maternal or neonatal morbidity was observed. These results are consistent with the absence of adverse effects of BUAL on the subsequent gestational period. The underlying mechanism of unaffected pregnancy may be

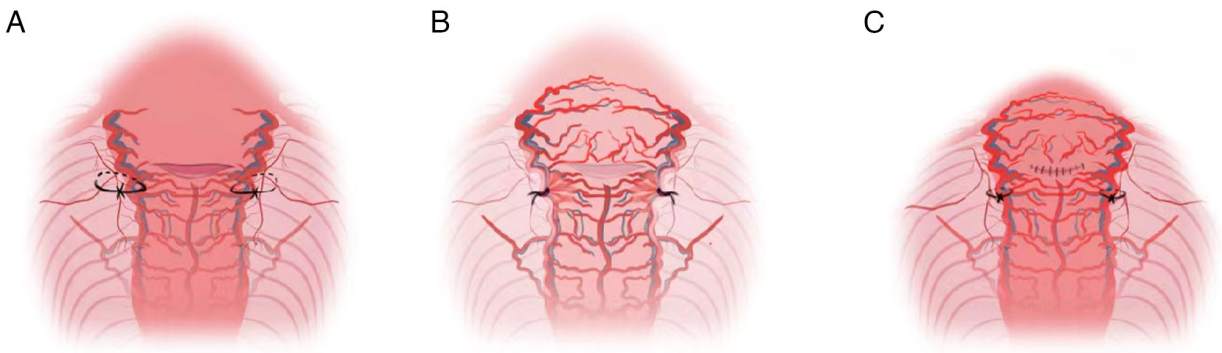

Figure 2. Schematic illustration of mechanism of unaffected pregnancy. (A) Bilateral uterine artery ligation during cesarean section. (B) Blood flow shifts to the collateral circulation after blockage of the uterine artery. (C) Ligation loosening during the period of uterine involution, and re-canalization of the arteries.

that the blood flow shifts to the collateral circulation after the blockage of the uterine artery and ensures adequate blood flow to the uterus. Additionally, re-canalization of the arteries may proceed during the period of uterine involution (Fig. 2) (13,20).

The results of the present study are based on retrospective data from a single center, and clinical information, including patient characteristics, maternal and neonatal outcomes, and fetal biometry parameters (BPD, HC, AC, and FL) in each pregnancy, was reported in detail. To the best of our knowledge, the present study is the first to focus on IUGR in subsequent pregnancy among women who had undergone BUAL in a previous pregnancy. The primary limitations of the present study are the small sample size, and that it was not possible to identify all patients who underwent BUAL in our hospital and who had subsequent pregnancies based on the database. Therefore, these results need to be interpreted with caution and may should only serve as a reference for future more comprehensive studies, and there is a need for good-quality evidence-based prospective studies with larger sample sizes to confirm these findings.

In conclusion, BUAL is a safe surgical technique, and it does not appear to compromise a woman's subsequent obstetric outcomes. Future pregnancies do not appear to pose an increased risk of intrauterine growth retardation. Therefore, BUAL may be more widely recommended in clinical practice.

Acknowledgements

Not applicable.

Funding

No funding was received.

Availability of data and materials

All data generated and/or analyzed during the present study are included in this published article.

Authors' contribution

JA designed the study, analyzed data, wrote the paper, and confirmed the authenticity of all the raw data. JA read and approved the final manuscript.

Ethics approval and consent to participate

This study was reviewed and approved by the Institutional Board Review of Xiamen Women and Children's Hospital (approval no. KY2023018). All the methodology was performed in accordance with the relevant guidelines and regulations. The Institutional Board Review of Xiamen Women and Children's Hospital waived the requirement for informed consent from patients.

Patient consent for publication

Not applicable.

Competing interests

The authors declare they have no competing interests.

References

1. O'Leary JA: Pregnancy following uterine artery ligation. Obstet Gynecol 55: 112-113, 1980.
2. Fahmy K: Uterine artery ligation to control postpartum hemorrhage. Int J Gynaecol Obstet 25: 363-367, 1987.
3. AbdRabbo SA: Stepwise uterine devascularization: A novel technique for management of uncontrolled postpartum hemorrhage with preservation of the uterus. Am J Obstet Gynecol 171: 694-700, 1994.
4. Gonsalves M and Belli A: The role of interventional radiology in obstetric hemorrhage. Cardiovasc Intervent Radiol 33: 887-895, 2010.
5. Abbas AM, Shady NW and Sallam HF: Bilateral uterine artery ligation plus intravenous tranexamic acid during cesarean delivery for placenta previa: A randomized double-blind controlled trial. J Gynecol Obstet Hum Reprod 48: 115-119, 2019.
6. Sentilhes L, Gromez A, Clavier E, Resch B, Verspyck E and Marpeau L: Fertility and pregnancy following pelvic arterial embolisation for postpartum haemorrhage. BJOG 117: 84-93, 2010.
7. Fiori O, Deux JF, Kambale JC, Uzan S, Bougdhene F and Berkane N: Impact of pelvic arterial embolization for intractable postpartum hemorrhage on fertility. Am J Obstet Gynecol 200: 384.e1-e4, 2009.
8. Hardeman S, Decroisette E, Marin B, Vincelot A, Aubard Y, Pouquet M and Maubon A: Fertility after embolization of the uterine arteries to treat obstetrical hemorrhage: A review of 53 cases. Fertil Steril 94: 2574-2579, 2010.
9. Wagaarachchi PT and Fernando L: Fertility following ligation of internal iliac arteries for life-threatening obstetric haemorrhage: Case report. Hum Reprod 15: 1311-1313, 2000.
10. Sentilhes L, Trichot C, Resch B, Sergent F, Roman H, Marpeau L and Verspyck E: Fertility and pregnancy outcomes following uterine devascularization for severe postpartum haemorrhage. Hum Reprod 23: 1087-1092, 2008.

11. Unal O, Kars B, Buyukbayrak EE, Karsidag AYK and Turan C: The effectiveness of bilateral hypogastric artery ligation for obstetric hemorrhage in three different underlying conditions and its impact on future fertility. J Matern Fetal Neonatal Med 24: 1273-1276, 2011.
12. Domingo S, Perales-Puchalt A, Soler I, Marcos B, Tamarit G and Pellicer A: Clinical outcome, fertility and uterine artery Doppler scans in women with obstetric bilateral internal iliac artery ligation or embolisation. J Obstet Gynaecol 33: 701-704, 2013.
13. Kaplanoglu M, Karateke A, Un B, Gunsoy L and Baloglu A: Evaluation of uterine artery recanalization and Doppler parameters after bilateral uterine artery ligation in women with postpartum hemorrhage. Int J Clin Exp Med 8: 7823-7829, 2015.
14. Zhang Y, Meng H, Jiang Y, Xu Z, Ouyang Y, Li S, Chen Q, Wu Q, Li R, Ru T, *et al*: Chinese fetal biometry: Reference equations and comparison with charts from other populations. J Matern Fetal Neonatal Med 32: 1507-1515, 2019.
15. Gizzo S, Saccardi C, Patrelli TS, Di Gangi S, Breda E, Fagherazzi S, Noventa M, D'Antona D and Nardelli GB: Fertility rate and subsequent pregnancy outcomes after conservative surgical techniques in postpartum hemorrhage: 15 Years of literature. Fertil Steril 99: 2097-2107, 2013.
16. Blanc J, Courbiere B, Desbriere R, Bretelle F, Boubli L, d'Ercole C and Carcopino X: Is uterine-sparing surgical management of persistent postpartum hemorrhage truly a fertility-sparing technique? Fertil Steril 95: 2503-2506, 2011.
17. Sziller I, Hupuczi P and Papp Z: Hypogastric artery ligation for severe hemorrhage in obstetric patients. J Perinat Med 35: 187-192, 2007.
18. Doumouchtsis SK, Nikolopoulos K, Talaulikar V, Krishna A and Arulkumaran S: Menstrual and fertility outcomes following the surgical management of postpartum haemorrhage: A systematic review. BJOG 121: 382-388, 2014.
19. Demirci F, Ozdemir I, Safak A, Ozden S and Somunkiran A: Comparison of colour Doppler indices of pelvic arteries in women with bilateral hypogastric artery ligation and controls. J Obstet Gynaecol 25: 273-274, 2005.
20. Dubay ML, Holshauser CA and Burchell RC: Internal iliac artery ligation for postpartum hemorrhage: Recanalization of vessels. Am J Obstet Gynecol 136: 689-691, 1980.