SARS-CoV-2 infection and associated risk factors for clinical cases of cerebral venous thrombosis: A case series

ANY AXELERAD[1,2*], LAVINIA FLORENTA MUJA[1,2*], CRISTINA MARIA MIHAI[3*], ALINA ZORINA STUPARU[1,2], ANCA ELENA GOGU[4], DRAGOS CATALIN JIANU[4], CORINA ELENA FRECUS[3], SILVIU DOCU AXELERAD[5], SILVIA GEORGETA PETROV[6], CARMEN ADELLA SIRBU[7], SIMONA CLAUDIA CAMBREA[8,9], RADU ANDREI BAZ[10] and FLORENTINA IONITA-RADU[11]

[1]Department of Neurology, General Medicine Faculty, Ovidius University, 900470 Constanta; [2]Department of Neurology, Clinical Emergency Hospital 'St. Apostol Andrei' of Constanta, 900527 Constanta; [3]Department of Pediatrics, General Medicine Faculty, Ovidius University, 900470 Constanta; [4]Department of Neurology, Victor Babes University of Medicine and Pharmacy, 300041 Timisoara; [5]Vasile Goldis' University, Faculty of General Medicine, 317046 Arad; [6]Doctoral School of The Faculty of Psychology and Educational Sciences within The University of Bucharest, 050663 Bucharest; [7]Neurology Department, Titu Maiorescu University, 040441 Bucharest; [8]Infectious Diseases Clinic, Clinical Infectious Diseases Hospital, 900708 Constanta; [9]Department of Infectious Diseases, General Medicine Faculty, Ovidius University; [10]Department of Radiology, Faculty of Medicine, Ovidius University, 900470 Constanta; [11]Faculty of Medicine, Titu Maiorescu University, 004051 Bucharest, Romania

Received February 20, 2022; Accepted May 22, 2023

DOI: 10.3892/etm.2023.12300

Abstract. The present study focused on examining the association between the SARS-CoV-2 virus, responsible for the COVID-19 pandemic, and cerebral venous thrombosis (CVT), a specific form of stroke that affects the brain's vessels and sinuses. While COVID-19 is primarily recognized for its respiratory impact, it may also affect other organs, including the brain. One notable aspect of COVID-19 is its association with coagulopathy, an abnormal condition of blood clotting. Coagulopathy may result in various complications, including neurological ones such as stroke. The study analyzed data obtained from patients admitted to a neurology department who had confirmed neurological pathologies along with COVID-19. It specifically examined the cases of three patients with neurological conditions and COVID-19, discussing their risk factors and how their conditions progressed clinically. The study concluded that COVID-19 infection increases the likelihood of stroke, particularly within the initial 10 days after infection. CVT in particular is strongly linked to COVID-19 and its underlying mechanisms involve immune systemic processes, cytokine storms, increased blood thickness, thrombogenesis, hypercoagulability and inflammation. The presence of SARS-CoV-2 infection may worsen the procoagulant cascade, thereby affecting the clinical condition of patients with CVT. The study underscores the importance of recognizing this uncommon but treatable consequence of COVID-19 infection. Furthermore, it highlights the uniqueness of the study in evaluating COVID-19 infection in patients with CVT from Romania and South-East Europe. The findings support the existence of neurological disorders, including clotting complications in the brain's sinuses and vessels, in individuals infected with SARS-CoV-2. Several risk factors contribute to the development of CVT, such as infections, oral contraceptives, pregnancy, hematological disorders, trauma, autoimmune disorders and malignancies.

Correspondence to: Dr Alina Zorina Stuparu, Department of Neurology, General Medicine Faculty, Ovidius University, 1 Aleea Universității, 900470 Constanta, Romania
E-mail: zorina.stroe@yahoo.com

[*]Contributed equally

Key words: cerebral venous thrombosis, risk factors, COVID-19, severe acute respiratory syndrome-coronavirus-2

Introduction

Severe acute respiratory syndrome 2 (SARS-CoV-2) is the causal agent of the COVID-19 outbreak (1). At the global level, according to the National Center for Surveillance and Control of Communicable Diseases, a total of 244,089,628 cases of infection and 4,958,793 COVID-19-associated deaths had been confirmed (as of October 2021) (2).

Being primarily a respiratory disease with major pulmonary complications, it is characterized by fever, a non-productive cough, respiratory difficulties, dyspnea, and hypoxia in most patients, and signs of interstitial pneumonia on X-rays or CT scans; however, COVID-19 may also affect other organs, including the brain (3). Thromboembolic events have been reported after infection with SARS-CoV-2, primarily in the pulmonary vasculature, as well as an increased rate of thromboembolic complications of the nervous system with

subsequent cerebrovascular accidents (4). The most common complication after infection with SARS-CoV-2 remains ischemic stroke, but cases of cerebral venous sinus thrombosis have been confirmed (4).

This infectious disease, caused by the most recently discovered coronavirus, COVID-19, can induce hypercoagulability associated with an increased prevalence of venous thromboembolism grouped with thrombotic complications, primarily connected to pulmonary vascularization, but these thrombotic complications may also involve the vasculature of the brain (for 2% of the patients with confirmed SARS-CoV-2 infection). Currently, the mechanism of thrombophilia associated with COVID-19 infection is not completely understood. However, it is known that the severe inflammatory response after the infection with SARS-CoV-2 virus leads to an outburst of cytokines which induces a pro-coagulable state. The virus has a specific pro-coagulative effect, and infection with this virus produces large-scale endothelial dysfunction and inflammation. Both Von Willebrand factor (VWF) and factor VIII (FVIII) are known to be highly rated for patients with COVID-19. These factors are not only connected to the risk of inflammation and thrombosis but are strongly connected to endothelial lesions. A decrease in the FVIII/VWF ratio in patients infected with the SARS-CoV-2 virus is associated with a higher risk of aggravation of the respiratory state followed by an increased need for oxygen (4).

A well-known characteristic of infection with SARS-CoV-2 is coagulopathy and the fact that hypercoagulability may lead to other complications associated with COVID-19, in particular, venous thromboembolic events and stroke. Disseminated intravascular coagulation, increased D-dimer levels, modified fibrinogen levels, fibrin or fibrinogen degradation products, thrombocytopenia, and the presence of antiphospholipid antibodies are all linked to SARS-CoV-2 infection and severity. However, there are a few case reports that have described cerebral venous sinus thrombosis (CVST) associated with SARS-CoV-2 infection (5).

Cerebral venous thrombosis (CVT) is caused by complete or partial occlusion of the major cerebral venous sinuses (thrombosis of the major cerebral venous sinuses) or smaller cortical supply veins and represents a common cause of stroke (6). It is a rare disease, accounting for ~0.5% of all cerebrovascular diseases worldwide (7). Prothrombotic hematological conditions, hormonal (oral contraceptive pill, pregnancy, puerperium, steroids), local factors (skull abnormalities/trauma, compressing mass or infection), systemic illness (dehydration, sepsis, malignancy or connective tissue disorders), or idiopathic causes (7) are all risk factors.

CVST is known to be a multifactorial disease, with at least one risk factor for 85% of the affected adult patients. Risk factors are associated with the Virchow triad of thrombogenesis (lesions of the vessel wall, hypercoagulability, and blood stasis). The most frequent risk factors associated with CVT are prothrombotic conditions. Patients known to have hereditary thrombophilia present with an increased susceptibility to developing any form of thrombosis, CVST included; the most frequent causes are V Leiden factor, polymorphism of G20210A prothrombin and antiphospholipid syndrome, and the rarest risk factors are antithrombin III deficiency, C protein deficiency and S protein deficiency (8).

Previously, a prognosis of CVT was fatal, especially due to tardive or post-mortem identification of the diagnosis. Most patients diagnosed with CVT today have a good prognosis, largely due to improvements in high-performance imaging methods. However, CVT management is notably complicated by SARS-CoV-2 infection. SARS-CoV-2 increases systemic hypercoagulability and thromboembolism and is associated with cerebrovascular diseases, particularly CVT (9).

For confirmation of neurological pathologies, diagnosis is established according to clinical manifestations, objective neurological examinations, paraclinical investigations (biological data analyzed during a patient's stay, and biological material collected to establish hereditary factors for thrombosis), and based on cerebral imaging. The most commonly used imaging methods are CT, native or with angiography, and magnetic resonance imaging (MRI), native or with angiography. Furthermore, the device used was a SIGNA Explorer 1.5 T (GE Healthcare). In order to determine the hereditary thrombosis profile, the test for the identification of mutations associated with thrombophilia, biological material/blood was collected and the equipment used was as follows: For acid DNA isolation a vortex combispin FVL-2400N (Biosan) and a Thermo-Shaker TS-100 centrifuge Hettich Universal 320R (Biosan); for DNA amplification, a Real-Time thermal cycler qTower 2.2 (Analytic Jena); and for hybridization and detection, a Thermo-Shaker PST-60HL (Biosan). The presence of infection with SARS-CoV-2 virus was detected using ARN SARS-CoV-2 testing by reverse transcription-quantitative PCR.

The purpose of neurological treatment is to eliminate the obstacle at the level of the sinus lumen or vessels affected and to stop the progression of a thrombus, to cure the prothrombotic status in order to prevent both venous thrombotic events and relapse (10).

Materials and methods

The statistical data collected from patients with neurological disorders and SARS-CoV-2 infection, who were admitted to the Neurology Section of 'Sf. Apostol Andrei' Emergency Clinical Hospital in Constanta, provide confirmation of the observed pathological findings. The Ethics Committee for Clinical Studies at the Constanta County Emergency Clinical Hospital approved the study (approval no. 31/03.11.2021), which was performed in compliance with the Declaration of Helsinki. All subjects provided written informed consent prior to enrolment. In the present report, the cases of three patients affected by a neurological disease (patient no. 1: Left subacute venous transversal-sigmoid-jugular thrombosis; patient no. 2: Right superior frontal cortical vein thrombosis, superior sagittal sinus, sinuses' confluent, sigmoid sinuses and transverse on the right side, and partially the right internal jugular vein; and patient no. 3: Thrombosis of transverse and sagittal sinuses) and diagnosed with COVID-19. Paraclinical investigations included CT scan, MRI scan and electromyography.

Results

Patient no. 1. The first case presented is of a patient aged 66 years, known to be at high risk of hypertension, who was

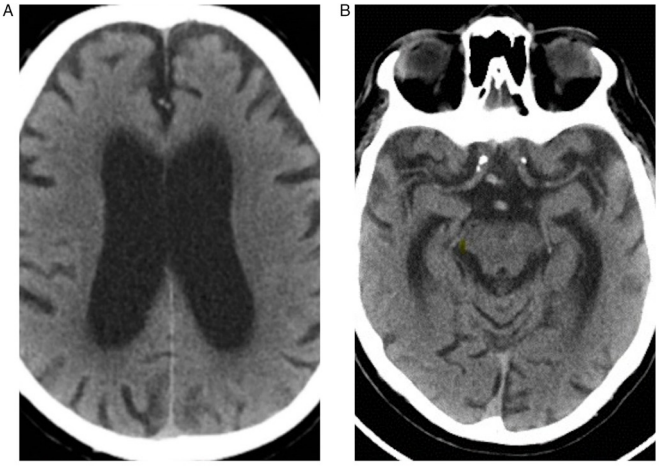

Figure 1. Case 1. The native cranial and encephalus scans performed on the first day of hospitalization highlight (A) cerebral abiotrophy; calcified atheroma plaques localized at the level of intra- and supracavernous segments of both internal carotid arteries, and at the level of intracranial segment of both vertebral segments; infra- and supratentorial pericerebral liquid spaces with dimensions within the physiological range; absence of evoking images of acute ischemia, intra-/extra-cerebral blood accumulations or masses with tumoral sub-layer; small millimeter intra-nevraxial areas; (B) spontaneously hypodense, well-delimited, situated bilaterally in the capsula and lenticular area and compatible with dilations of Virchow-Robin perivascular spaces; cortical relief with deep incisions and large Sylvian valleys; symmetrical ventricular system, with increased dimensions (maximum frontal diameter, ~49 mm), with no transependymal resorption oedema (maximum frontal diameter, ~49 mm), with no transependymal resorption oedema; and a median structure in the normal position.

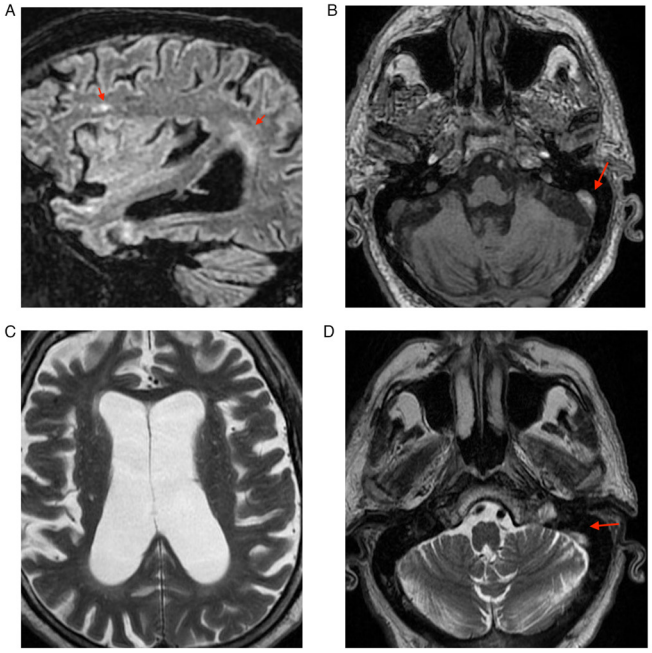

Figure 2. Case 1. (A) MRI scan highlighting supratentorial demyelinating lesions (fluid-attenuated inversion recovery-small red arrows); (B) left subacute venous transversal-sigmoid-jugular thrombosis (T1 hyperintensity-red arrow); (C) cerebral abiotrophy outside of the physiological range (T2); (D) left subacute venous transversal-sigmoid-jugular thrombosis (T2 hyperintensity-red arrow).

hospitalized in November 2020 in the Neurology Clinic for a language disorder that started 15 days before presentation.

When the patient came to the Emergency Unit, he underwent native cranial CT (Fig. 1). When hospitalized, the ARN SARS-CoV-2 test was negative. During hospitalization, the patient presented dynamically increased blood glycemia and increased glycated hemoglobin (glycated hemoglobin, 11.2%; normal range, 4.8-5.6%), and thus a diabetes consultation was requested. The patient was diagnosed with newly discovered type II diabetes mellitus and insulin therapy was started.

The neurological objective examination when the patient was hospitalized was conscious and cooperative, prone to roughness in his right superior member, with no motor deficit at the level of inferior members, with no coordination or sensory disorders, and no cutaneous plantar reflex indifferently bilateral.

On the 4th day the patient submitted a neurological examination, he was conscious, cooperative, and oriented in time and space, with no movement deficits, no sensory disorders, presented ataxia at the level of the bilateral inferior members, orthostatic intolerance, and sustained walking. On the 8th day, the objective of the neurological examination differed; the patient was conscious, cooperative, and oriented in time and space, he presented with normal ocular ability, no nystagmus, movement deficits at the level of inferior members bilaterally proximal right 2-3/5 and left 3-4/5, and bilateral brachia proximal right 3/5 and left 3-4/5. The native cranial and brain MRI examination which was performed on the 9th day of hospitalization highlighted left subacute venous transversal-sigmoid-jugular thrombosis (as depicted by the arrows in Fig. 2D); supratentorial demyelinating lesions (as depicted by the arrows in Fig. 2A and B), most probably with ischemic vascular sublayer; and cerebral abiotrophy which surpassed the age limit (Figs. 1 and 2). During the 9th day of hospitalization, the patient underwent electromyography, and was diagnosed with predominantly sensitive axonal polyneuropathy, and on the 14th day of hospitalization, the Echo Doppler of cervical vessels highlighted bilateral carotid atheromatosis. In addition, the patient underwent native Nuclear Magnetic Resonance (NMR) examination of the cervical and thoracic spine and under the reserve of movement artifacts, and the results were: T7, T9, and T10 intraspongious herniation (as depicted by the arrows in Fig. 3C); C5-C6 herniated disk (as depicted by the arrows in Fig. 3A), compression over the anterior spine of LCR; C6-C7 left median and paramedian protrusion, with C7 left intraforaminal radicular conflict (Fig. 3).

On the 14th day of hospitalization, the patient's health status had changed, as he exhibited desaturation up to 89% and was feverish (body temperature, 37.3°C). RT-PCR was performed to determine whether a SARS-CoV-2 infection was present; the results were positive, and the patient was isolated on the 16th day and transferred to the Municipal Hospital in Medgidia (support hospital for COVID-infected patients) in order to receive special treatment. When transferred, the patient was submitted to a neurological examination, he was conscious, hardly cooperative, with a symmetric face, brachial distal movement deficit 3-4/5, crural 3/5, plantary cutanate reflex in bilateral flexion, and did not cooperate for sensory stimuli and coordination tests. The results of the patient examination are presented in Table I.

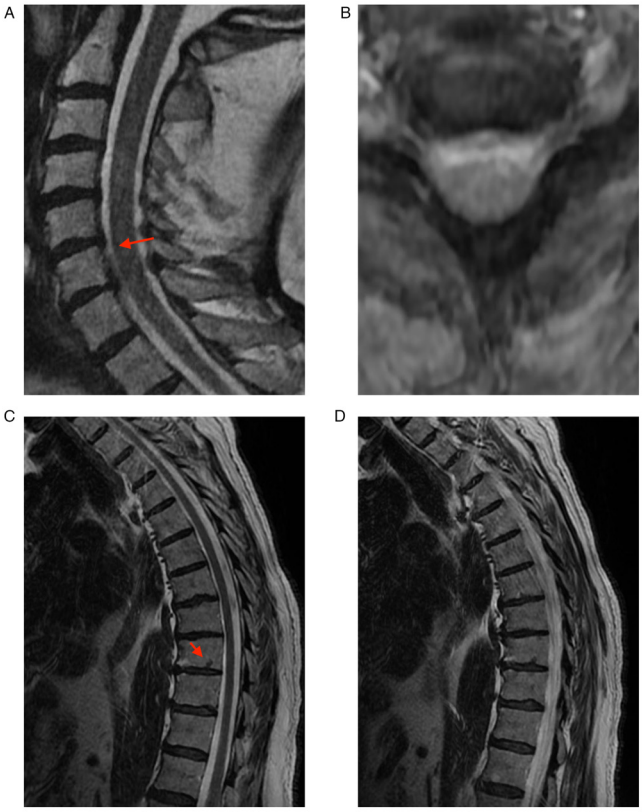

Figure 3. Case 1. (A) Cervical spine MRI showing herniated C5-C6 and C6-C7 disks (red arrow); (B) cervical spine MRI showing herniated C5-C6 and C6-C7 disks with discrete compression over the anterior column of cerebrospinal fluid; (C) dorsal spine MRI showing intraspongious herniations T7, T9 (red arrow); (D) dorsal spine MRI showing T10 intraspongious herniation without markings.

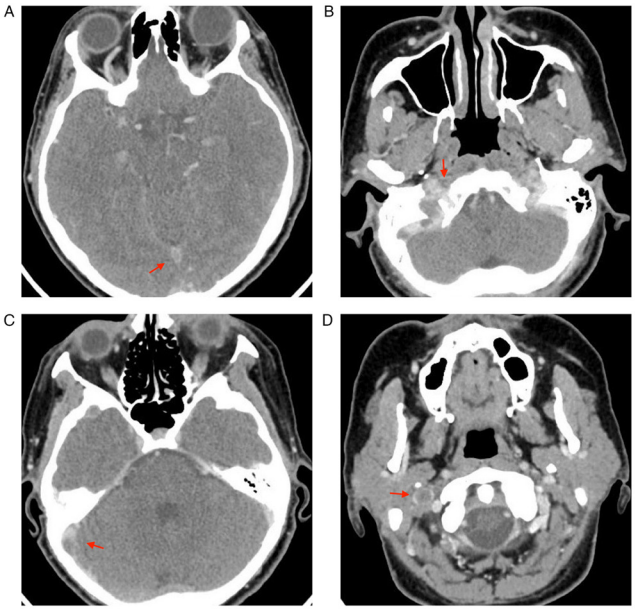

Figure 4. Case 2. (A) CT cranial angiography performed on the first day of hospitalization indicated thrombosis of the superior sagittal transverse (red arrow); (B) thrombosis of the right sigmoid sinuses (red arrow); (C) thrombosis of the right transverse sinus (red arrow); (D) thrombosis of the right jugular vein (red arrow).

During the 15 days of hospitalization in the Neurology Department, the patient underwent treatment with cerebral depletion (Manitol 20% 100 ml every 8 h-only on the first 4 days of hospitalization), platelet antiaggregatory agent (Aspenter 75 mg for the first 3 days; 3 tablets every day at lunchtime, followed by 2 tablets at lunchtime on day 4, and 1 tablet at lunchtime on days 5 and 6), therapy with vitamins (vitamin B1 100 mg 1 ampoule x2 every day, vitamin B6 250 mg ampoule x2 every day), hydro-electrolytic rebalancing (normal saline solution 500 ml every day, slowly endovenous drip), statin (Atorvastatine 20 mg 1 tablet every day in the evening), gastric protector (Zencopan 40 mg 1 tablet every day in the morning), antihypertensive (Tertensif 1.5 mg 1 tablet every day in the morning), Atacand (8 mg 1 tablet every day in the evening), rapid insulin (10 units at 08:00, 8 units at 13:00, 8 units at 19:00, and 6 units at 24:00), low-molecular-weight heparin (Clexane 0.7 ml every 12 h, subcutaneously from the 7 to 11th day) and oral anticoagulant [Sintrom 4 mg 1/2 tablet from the 7th day, according to International Normalized Ratio (INR)].

During hospitalization, the patient was paraclinically monitored, the biological data obtained are summarized in Tables II and III.

On the 15th day of hospitalization, biological material was collected to determine the hereditary thrombosis profile which was transmitted to the Clinical Service of Pathological Anatomy, a test for identifying the mutations associated with cardiovascular disease and thrombophilia. The test identified 9 mutations: FV G1691A (Leiden), FV H1299R (R2), Prothrombin G20210A, MTHFR C677T, MTHFR A1298C, Factor XIII V34L, PAI-1 4G/5G, EPCR A4600G, and EPCR G4678C.

The test identified the genotype 5G/5G of PAI-1 and haplotype A2/A2 of EPCR.

Patient no. 2. The second case was a patient aged 41 years, with a personal pathological history consisting of uterine fibrosis, following treatment with oral contraceptives and a smoker, who was transferred from the Section of Gynecology of the Emergency Hospital in Tulcea to the Neurology Section of 'Sf. Apostol Andrei' Emergency Hospital in Constanta in January 2021, where she was hospitalized for a period of 13 days. In the Gynecology Clinical Section, a day before being transferred, the patient underwent a native cerebral CT, which highlighted an occipital epidural hematoma, for which she was transferred for additional investigation.

The results of the neurological examination performed in the Section of Neurology were: The patient was conscious, cooperative, partially oriented in time and space, with no cervix stiffness, normal ocular ability, left hemiparesis 4/5 easily ataxic, and Babinski present on the left side. The RT-PCR SARS-CoV-2 test, which was performed when the patient was hospitalized, was negative.

On the first day of hospitalization in the Clinical Section of Neurology, the patient underwent a cranial and encephalic CT and cranial CT angiogram, an examination which evoked thrombosis of the right internal jugular vein (as depicted by the arrows in Fig. 4D), sigmoid sinuses (as depicted by the arrows in Fig. 4B), right transverse (as depicted by the arrows in Fig. 4C) and superior sagittal (as depicted by the arrows

Table I. Biological parameters of patient no. 1.

Parameter (normal range)	Day 1	Day 3	Day 8	Day 12	Day 14
White blood cells (4,000-10,000/μl)	6.31	6.4	-	6.69	-
Hemoglobin (12.6-17.4 g/dl)	16.90	15.8	-	16	-
Hematocrit (37-51%)	46.20	46.1	-	44.2	-
Platelets (150,000-450,000/μl)	212.00	246	-	185	-
Erythrocyte sedimentation rate (<20 mm/h)	-	-	-	26	-
Aspartate amino-transferase (0-37 U/l)	22.92	-	-	-	-
Alanine amino-transferase (0-40 U/l)	20.26	-	-	-	-
Urea (<49 mg/dl)	79.81	100	-	67	-
Creatinine (<1.2 mg/dl)	1.01	1.72	1.42	0.82	-
Glycemia (100-125 mg/dl)	670.24	449	154	-	-
Vitamin B12 (191-663 pg/ml)	-	-	-	-	892
Potassium (3.5-5.1 mmol/l)	4	4.6	4.1	3.3	-
Sodium (136-145 mmol/l)	127	136	134	141	-

Table II. Results of the coagulation tests in patient no. 1.

Parameter (normal range)	Day 7	Day 8	Day 9	Day 10	Day 11	Day 12	Day 13	Day 14	Day 16
INR (2.0-3.0)	1.1	1.06	1.5	3.51	4.58	2.18	2.9	5.2	4.6
Prothrombin time (70-100%)	87	91	57	21	16	36	26	14	16
Clotting time (11.7-15.3 sec)	14.6	14.2	19.7	43.7	56.3	27.9	36.5	63.5	56.5
Partial thromboplastin time (<40 sec)	32.4	34.9	35.4	47.8	-	52	51.8	64.6	-

INR, international normalized ratio.

Table III. Hereditary thrombophilia profile in patient no. 1.

Mutation	Wild type	Mutation status	Genotype
FV G1691A (Leiden)	Positive	Negative	Normal
FV H1299R (R2)	Positive	Negative	Normal
Prothrombin G20210A	Positive	Negative	Normal
MTHFR C677T	Positive	Negative	Normal
MTHFR A1298C	Positive	Negative	Normal
Factor XIII V34L	Positive	Negative	Normal
PAI-1 4G/5G	Positive 5G	Negative 4G	Homozygous 5G/5G
EPCR A4600G	Positive A	/	A2/A2
EPCR G4678C	Positive G	/	A2/A2

in Fig. 4A). On the first day of hospitalization the patient underwent a cardiac assessment, the results of which indicated that a thrombosis profile should be performed, an X-ray of the heart and exploration according to the affected protocol, and to follow a treatment with Heparin 25 000 UI with a syringe pump at a rate of 2 ml/h with a Partial Thromboplastin Time target of 50-70. On the 7th day of hospitalization, the patient underwent a cardiac X-ray, which indicated cavities of normal dimensions, without any kinetic modifications on the left ventricle, an ejection fraction of 60%, no abnormalities in the valves, no pulmonary hypertension, and obstruction free cavities.

On the 4th day of hospitalization, a dermato-venereological assessment was requested, which indicated the fact that the patient was from another city, the reason for which it was not known whether she was on the list of the people affected by Lues. The following investigations were performed: Tests highlighting non-specific antibodies by

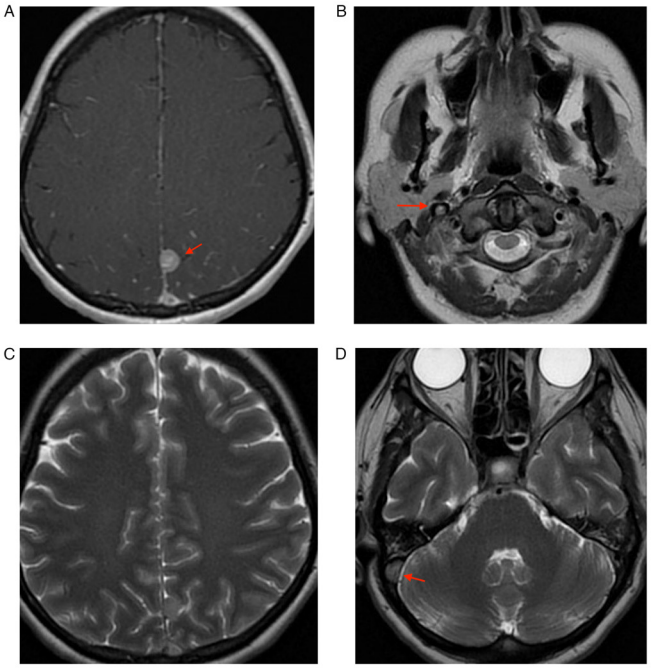

Figure 5. Case 2. On the 4th day of hospitalization, the patient underwent native cranial cerebral magnetic resonance imaging and a venous/segment angiography, examination indicated (A) small left parasagittal superior parietal meningioma (T1-red arrow); (B) thrombosis on transverse sinus on the right side, partially the right internal jugular vein (red arrow); (C) small left parasagittal superior parietal meningioma (T2); (D) thrombosis in the right superior frontal subacute cortical tardive-vein, superior sagittal sinus, sinuses confluent, sigmoid sinuses (right-red arrow).

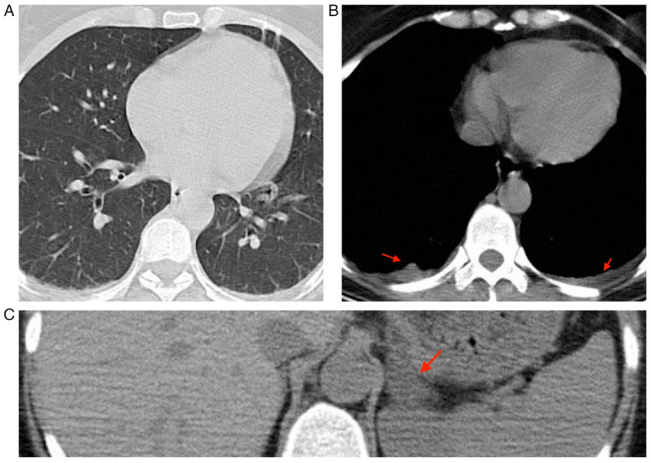

Figure 6. Case 2. On the 10th day, the native co-axial tomography of the thorax indicated (A) right inferior lobar and alveolar opacities; (B) an evoking aspect of bilateral pleurisy in small quantities (red arrows) and (C) in opaque glass, left superior lobar opacities and left suprarenal adenoma (red arrow).

the Venereal Disease Research Laboratory (VDRL) and Rapid Plasma Reagin test (RPR), Treponema pallidum Hemagglutination Assay (TPHA) and treatment with antibiotic injection (Moldamin 1,200,000 UI fl. X, 2 bottles every 5 days, 5 doses), but considering the anticoagulant medication, the patient received oral antibiotic (Doxycycline 100 mg 1 tablet every 12 h for 4 weeks), probiotic (Eubiotic forte 1 tablet every day, after meals, 2 h between antibiotic treatment), and proton pump inhibitor (Nexium 20 mg 1

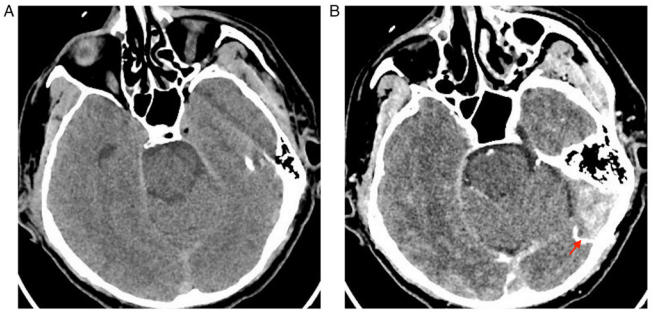

Figure 7. Case 3. On the cranial and encephalic co-axial tomography performed (A) before and (B) after administering the contrast substance, on the second day of hospitalization, highlighted the following: Thrombosis of transverse and sagittal sinuses (arrow) and some bilateral frontal and parietal superior cortical veins.

tablet every day, 20 min before meals). A gynecological assessment was performed, the results of which showed uterine fibrosis, metrorrhagia, and secondary anemia. On the 4th day of hospitalization, the patient underwent a native cranial cerebral NMR and a venous/segment angiography, which indicated thrombosis in the right superior frontal subacute cortical tardive-vein, superior sagittal sinus, sinuses' confluent, sigmoid sinuses, and transverse on the right side (as depicted by the arrows in Fig. 5), partially the right internal jugular vein (as depicted by the arrows in Fig. 5B); and small left parasagittal superior parietal meningioma (as depicted by the arrows in Fig. 5A).

On the 6th day of hospitalization, the patient underwent a hematological assessment for thrombocytosis, which indicated an iron deficit (severe posthemorrhagic hypochromic microcitary anemia). As the patient was young, even if she was following an anticoagulant treatment, a subsequent practice was recommended: C protein, S protein, antithrombin III, factor V Leiden mutation, mutation of prothrombin/factor II gene, lupus anticoagulant, dosing serum homocysteine, iron supplementation, and ferritin.

On the 9th day of hospitalization, biological material was collected to determine the hereditary thrombosis profile which was analyzed by the Clinical Service of Pathological Anatomy, where assays for identifying the mutations associated with the cardio-vascular disease and thrombophilia were performed. The test identified 9 mutations: FV G1691A (Leiden), FV H1299R (R2), Prothrombin G20210A, MTHFR C677T, MTHFR A1298C, Factor XIII V34L, PAI-1 4G/5G, EPCR A4600G, and EPCR G4678C. The results of the hereditary thrombophilia profile in patient no. 2 are shown in Table IV.

The following genotypes were identified: Composed heterozygote (double heterozygote) for mutations C677T and A1298C of MTHFR and homozygote for mutation 4G of PAI-1. Moreover, haplotype A1/A1 (H1/H1) of EPCR was also identified.

On the 10th day of hospitalization, the patient reported experiencing headache and had a fever. As a result, a native thorax CT scan was performed, revealing several findings. The scan showed bilateral pleurisy in a small quantity (indicated by the arrows in Fig. 6B), as well as opacities in the right inferior lobe and alveoli. Additionally, there were opacities in the left superior lobe in the form of opaque

Table IV. Hereditary thrombophilia profile in patient no. 2.

Mutations	Wild type	Mutation	Genotype
FV G1691A (Leiden)	Positive	Negative	Normal
FV H1299R (R2)	Positive	Negative	Normal
Prothrombin G20210A	Positive	Negative	Normal
MTHFR C677T	Positive	Positive	Heterozygous
MTHFR A1298C	Positive	Positive	Heterozygous
Factor XIII V34L	Positive	Negative	Normal
PAI-1 4G/5G	Negative 5G	Positive 4G	Homozygous 4G/4G
EPCR A4600G	Positive A	/	A1/A1 (H1/H1)
EPCR G4678C	Positive C	/	A1/A1 (H1/H1)

glass. It was recommended to correlate these findings with the PCR test. Furthermore, the CT scan also revealed a left suprarenal adenoma (indicated by the arrows in Fig. 6C). It is a recommendation following the patient's symptomatology and the immastigmatic investigation carried out, because SARS-CoV-2 infection must always be suspected even if it is not clear from the beginning, which is why studies and articles (1-4) have been published precisely to help doctors prevent further complications and catch the infection early. The patient was tested again on the 10th day of hospitalization, the results of the PCR test for SARS-CoV-2 was positive. In the neurologic examination, the patient was conscious, cooperative, and oriented in time and space, with no cervical stiffness, normal ocular ability, no nystagmus, no movement deficit, no sensory disorders, no coordination disorders and plantary cutanate reflex in bilateral flexion.

During the patient's hospitalization, various treatments were administered. These included cerebral depletion with mannitol (20% mannitol, 100 ml every 6 h for the first 5 days), hydro-electrolytic rebalancing with normal saline solution (250 ml every 12 h), anti-inflammatory medication (Algocalmin, 1 g/2 ml, 1 bottle every 12 h), antiemetic medication (Metoclopramide, 5 mg/ml, 1 bottle as needed), continuous infusion of Heparin (25,000 units in 50 ml normal saline solution, with a rate of 2 ml per hour) to maintain a target partial thromboplastin time of 50-70 (for 11 days).

On the 8th day of hospitalization, additional treatments were added to the regimen. These included oral anticoagulant (Sintrom, 4 mg, 1 tablet per day according to INR), oral antibiotic (Doxycycline, 100 mg, 1 tablet every 12 h for 4 weeks), probiotic supplement (Eubiotic forte, 1 tablet per day, taken after meals, at least 2 h apart from the antibiotic), and a proton pump inhibitor (Nexium, 20 mg, 1 tablet per day, taken 20 min before a meal). The patient's general condition was good during hospitalization, she was discharged conscious, cooperative, and oriented in time and space, with no sign of neurological focal point, on the 14th day, with self-isolation according to the indication of the Directorate for Public Health in Constanta and continued the treatment indicated by the dermatologist for up to 4 weeks, and for the neurological condition, she continued the treatment with oral anticoagulant (Sintrom 4 mg 1/4 tablet every day according to INR target 2-3 and repeats INR on the 7th, 14th day, then on a monthly basis).

The biological data dynamically obtained during the period of hospitalization are summarized in Table V. The results of the coagulation tests are summarized in Table VI.

Patient no. 3. The third case was of a patient aged 46, with asthma, who came to the Emergency Unit in April 2021 for repeated hematemesis in the morning, and was thus hospitalized in the Gastroenterology Section for additional investigation and etiological treatment. When admitted to the hospital, the patient performed a SARS-CoV-2 rapid antigen test and PCR test for SARS CoV-2 test which were both negative. When admitted to the clinical section, the patient underwent an abdominal and pelvic X-ray which showed the following: Absence of liquid in the peritoneal cavity, liver steatosis, a hyperecogenous pancreas, apparently homogeneous; gallbladder, and no modifications in the liver and kidneys. Biologically during the admission to the Gastroenterology section: Leukocytosis with neutrophilia, slight increase of amylase, modified basal glycemia, hepatic cytolysis, thrombocytopenia, nitrogen retention, and hepatic cholestasis syndrome.

On the 2nd day of hospitalization, the patient's condition was aggravated, thus a neurological assessment was requested for the deviation of eyeballs and force deficit at the level of the right hemibody. During the neurological assessment, the patient was preferentially looking towards the left-side and presented right lateral homonymous hemianopsia, movement deficit at the level of the right superior member 0/5 and right inferior member 1/5. Cerebral CT was requested immediately. At the cranial and encephalic CT performed before and after administering the contrast substance showed the following: Thrombosis of the transverse (as depicted by the arrows in Fig. 7B) and sagittal sinuses and some bilateral frontal and parietal superior cortical veins (Fig. 7). At the neurological re-evaluation and a cerebral CT performed on the same day, the neurological assessment indicated a severe general condition, no cervical stiffness, head and eyeballs deviated towards the left side, reactive intermediary pupils, right hemiplegia, plantary cutanate reflex in bilateral plantary indifference, and the patient mobilized the left members at nociception. The patient was transferred to the intensive

Table V. Biological data of patient no. 2.

Parameter (normal range)	Day 1	Day 2	Day 4	Day 5	Day 10	Day 12
White blood cells (4,000-10,000/μl)	8.41	9.37	6.56	4.96	4.63	6.99
Hemoglobin (12.6-17.4 g/dl)	8.4	8.6	8	7.9	8.1	8
Hematocrit (37-51%)	28.7	29.9	28.2	27.1	27.9	27.4
Platelets (150,000-450,000/μl)	573	625	607	437	413	376
Erythrocyte sedimentation rate (<20 mm/h)	61	-	-	-	66	-
Fibrinogen (200-400 mg/dl)	360	-	-	-	405	-
C-reactive protein (0-5 mg/l)	1.4	-	0.95	-	-	-
Aspartate amino-transferase (0-37 U/l)	29	-	-	-	17	-
Alanine amino-transferase (0-40 U/l)	22	-	-	-	26	-
Cholesterol (<200 mg/dl)	240	-	-	-	-	-
Cholesterol low-density lipoprotein (<100 mg/dl)	163	-	-	-	-	-
Lactate dehydrogenase (135-214 U/l)	-	-	-	-	221	-
Triglycerides (<150 mg/dl)	249	-	-	-	-	-
Urea (<49 mg/dl)	14	26	15	-	16	15
Creatinine (<1.2 mg/dl)	0.49	0.6	0.56	-	0.41	0.56
Glycemia 100-125 mg/dl)	110	107	101	-	-	-
Potassium (3.5-5.1 mmol/l)	3.5	-	-	-	-	-
Sodium (136-145 mmol/l)	137	-	-	-	-	-
Rapid plasma reagin test (<1, negative; >1 positive)	1.61	-	-	-	-	-
Anti-human immunodeficiency virus (1+2)	Negative	-	-	-	-	-
Free thyroxine 4 (12-22 pmol/l)	15.6	-	-	-	-	-
Thyroid stimulating hormone (0.27-4.2 μUl/ml)	1.37	-	-	-	-	-
Homocysteine(≤12 μmol/l)	10.3	-	-	-	-	-
D-dimer (0-0.5 μg FEU/ml)	-	-	-	-	1.17	-

Table VI. Results of the coagulation tests in patient no. 2.

Parameter (normal value)	Day 21	Day 2	Day 3	Day 4	Day 5	Day 6	Day 7	Day 8	Day 9	Day 10	Day 11	Day 12
INR (2.0-3.0)	0.99	-	-	-	-	-	1.09	-	1.06	1.32	2.29	2.33
Prothrombin time (70-100%)	101	-	-	-	-	-	89	92	-	68	35	34
Clotting time (11.7-15.3 sec)	13.2	-	-	-	-	-	14.4	14	-	17.3	29.2	29.6
Partial thromboplastin time (<40 sec)	37	35.1	47.5	69.2	87.9	62.2	64.5	75.7	-	58.8	155.4	75.4

INR, international normalized ratio.

care section-neurology and was submitted for a cranial and encephalic IRM with angiography sequence when the condition allowed.

On the 9th day of hospital admission, the PCR test was positive. The patient's condition continued to be severe, and on the 10th day, the patient exhibited a cardiac and respiratory arrest, did not respond to cardiopulmonary resuscitation, and therefore was declared exitus.

During the hospitalization, the patient received treatment with cerebral depletive (20% mannitol), hydro-electrolytic rebalancing solution (normal saline solution, 5% glucose), proton pump inhibitor (Pantoprazole 40 mg, 1 bottle intravenously every 12 h), antiemetic (Metoclopramide 5 mg/ml, 1 bottle when needed), therapeutic vitamins (vitamin B 1,100 mg 1 bottle x2 every day, vitamin B2 250 mg 1 bottle x2 every day, vitamin C 750 mg 1 bottle x2 every day), cerebral trophic medicine (Cerebrolysin 1 bottle x2 every day), anti-inflammatory (Algocalmine 1 g/2 ml 1 bottle intravenous, Paracetamol 10 mg/ml 1 bottle every day), low molecular weight heparin (Clexane 0.6 ml 1 bottle subcutaneously every day), antihypertensive medication (Enap 1.25 mg/ml 1 bottle, Furosemide 20 mg/2 ml 1 bottle, when needed), bronchodilator (Miofilin 24 mg/ml 1 bottle every 12 h), injectable antibiotic (Ceftamil 1 g every 8 h).

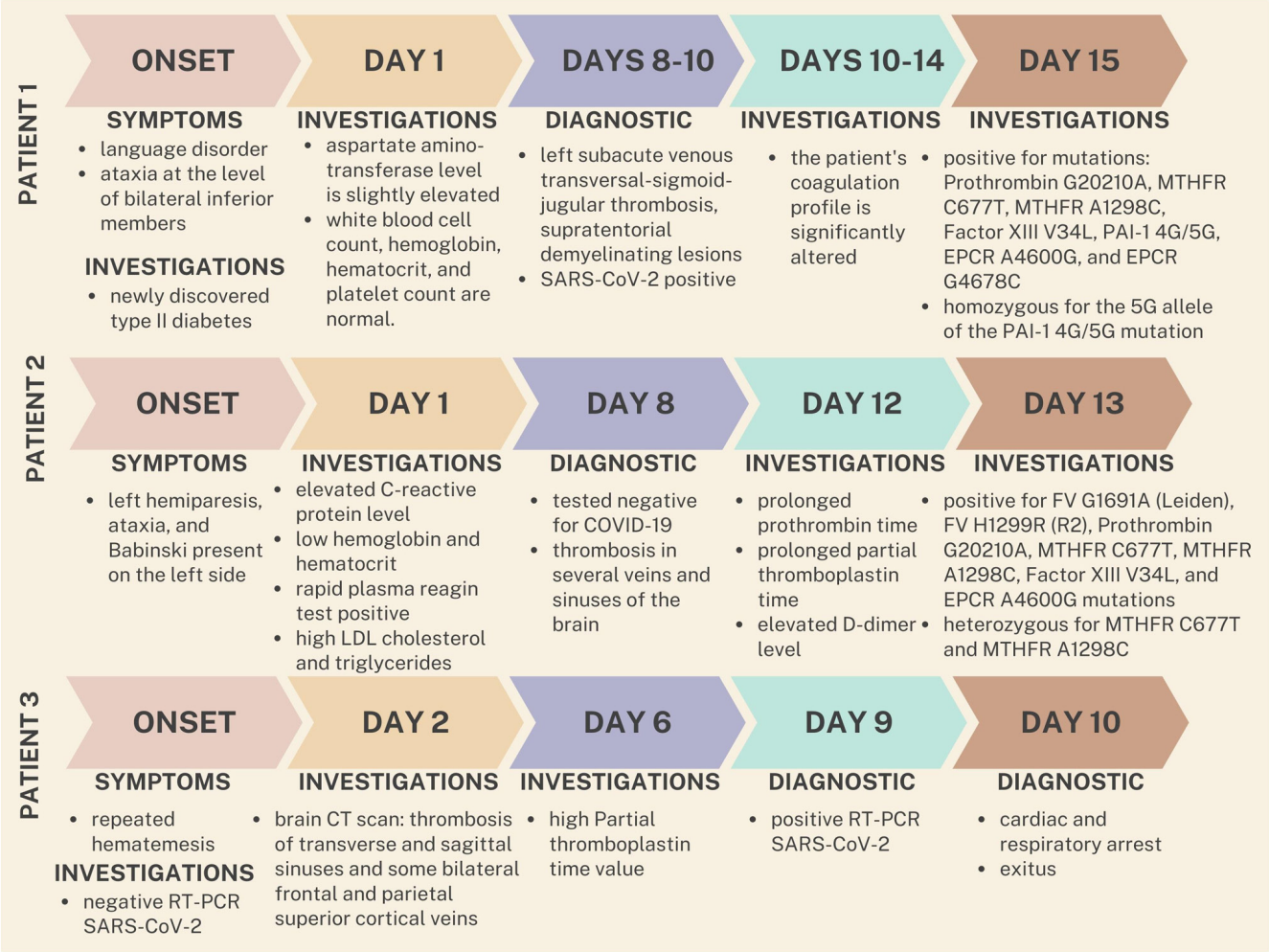

Figure 8. Evolutions of the patients. LDL, low-density lipoprotein; CT, co-axial tomography.

During hospitalization, the patient was paraclinically monitored and the biological data obtained are summarized in the Table VII.

Discussion

These case presentations describe cases of neurological disease in patients associated with SARS-CoV-2 infection hospitalized in the Neurology Section of Constanta County Hospital (Fig. 8). Although the data is limited, observational studies such as these improve our understanding of the evolution of a disease in patients affected by CVT and similar diseases, and its evolution in association with SARS-CoV-2 infection.

In the present report, the cases of two male patients aged 46 and 66, and a female patient aged 41 are presented. When hospitalized, each of these patients presented negative on a PCR test for infection with SARS-CoV-2, but the results of the test changed during hospitalization, along with various localizations of CVT, different risk factors, and distinctly associated pathologies. PCR may miss detection of individuals with SARS-CoV-2 infection, and early sampling minimizes false-negative diagnoses (11). It may be the case that the PCR test was taken too early or taken incorrectly, or the symptoms appeared a period of time after infection, which is why they were diagnosed first with CVST and then with COVID-19 (5).

The patients had no direct contact with patients infected with SARS-CoV-2. There was no data on the vaccination status of patients, although this may not be as relevant given numerous reports of individuals infected with COVID-19 following vaccination or prior infection.

The first case described here was that of a male patient, aged 66, with left subacute venous transversal-sigmoid-jugular thrombosis indicated by the native cerebral NMR. The patient's associated risk factors, such as high blood pressure, newly discovered type II diabetes mellitus, and bilateral carotid atheromatosis, appeared in the hereditary thrombosis profile (genotype 5G/5G PAI-1 and haplotype A2/A2 of EPCR) and on the 14th day of hospitalization, the patient tested positive for COVID-19 following a PCR test.

The second case described a female patient, aged 41, with thrombosis in the right superior frontal subacute cortical tardive-vein, superior sagittal sinus, sinuses' confluent, sigmoid sinuses, and transverse on the right side; partially the right internal jugular vein was indicated on native NMR and angiography. The patient's associated risk factors such as uterine fibrosis, treatment with oral contraceptives, chronic tabagism, acute syphilis, severe

Table VII. Biological data of patient no. 3.

Parameter (normal range)	Day 1	Day 2	Day 3	Day 4	Day 5	Day 6	Day 7	Day 8
White blood cells (4,000-10,000/μl)	13.74	16.04	21.59	9.66	12.61	-	12.12	8.65
Hemoglobin (12.6-17.4 g/dl)	14.1	14	14.6	12.3	12	-	10.9	10.2
Hematocrit (37-51%)	41.9	40.2	42.5	37.2	37	-	32.8	31
Platelets (150,000-450,000/μl)	472	149	460	197	183	-	96	109
Fibrinogen (200-400 mg/dl)	-	-	879	774	706	686	686	593
C-reactive protein (0-5 mg/l)	-	-	-	-	-	-	24.47	28.53
Aspartate amino-transferase (0-37 U/l)	35.98	-	31	-	89	-	148	102
Alanine amino-transferase (0-40 U/l)	89.61	-	59	-	86	-	109	81
Urea (<49 mg/dl)	33	-	78	-	66	92	151	-
Creatinine (<1.2 mg/dl)	0.83	-	1.76	1.46	1.51	2.84	4.93	7.67
Glycemia (100-125 mg/dl)	129	-	-	-	-	-	-	-
Potassium (3.5-5.1 mmol/l)	-	4.1	-	-	-	-	-	-
Sodium (136-145 mmol/l)	-	140	-	-	-	-	-	-
D-Dimer (0-0.5 μg FEU/ml)	1.6	-	-	-	-	-	-	-
Amylase (20-100 U/l)	114.62	-	-	-	-	-	-	-
Lipase (13-60 U/l)	47.92	-	-	-	-	-	-	-
Direct bilirubin (<0.2 mg/dl)	-	-	0.33	-	-	-	3.36	5.08
Indirect bilirubin (≤1 mg/dl)	-	-	-	-	-	-	2.37	0.066
Total bilirubin (≤1 mg/dl)	-	-	0.55	-	-	-	5.74	5.14

posthemorrhagic hypochromic microcitary anemia, dyslipidemia and presented modifications at the hereditary thromboliphic profile [composed heterozygote for C677T and A1298C of MTHFR mutations, homozygote for 4G of PAI-1 mutation and haplotype A1/A1 (H1/H1) of EPCR]. On the 10th day of hospitalization, the patient was positive for COVID-19 infection following a PCR test.

The third case was a male patient, aged 46, who had thrombosis of the transverse and sagittal sinuses and in some bilateral frontal and parietal superior cortical veins in the CT native and contrast substance CT. The patient presented with SARS-CoV-2 infection on the 9th day of hospitalization. He presented with risk factors, such as high blood pressure, asthma, acute renal failure, and syndrome of hepatic cytolysis. The evolution of this patient's disease was not favorable, as he developed a vascular coma, and cardiac and respiratory arrest during hospitalization.

CVST presents as one of three clinical syndromes: Isolated intracranial high blood pressure (characterized by headaches, papillary edema, and visual problems), focal syndrome (accompanied by convulsions reported in 39.3%, paresis in 37.2%, and aphasia in 19.1% of cases), and encephalopathy (characterized by the alteration of the mental state, extended neurological signs, and coma). Risk factors include a genetic predisposition to thrombophilia, which can be determined in patients with CVST by assessing C protein deficit and S protein deficit (12), antithrombin III and factor V Leiden levels, and mutations of the G20210A prothrombin gene. Other risk factors, which may explain an increased predisposition to CVST in women more than in men, may be due to use of oral contraceptives, pregnancy, and puerperium. Among the risk factors, there are also focal infections at the level of the head, neck, and sinuses, or malign infections, particularly in older patients (12). However, a previous study indicated that up to 12.5% of cases did not present with any associated risks. Therefore, the lack of an associated risk suggests that the infection with SARS-CoV-2 virus acted as a potential etiological factor in the development of CVST (12).

In the study by Cavalcanti *et al* (13), three patients (<41 years old) were infected with SARS-CoV-2 virus and cerebral vein sinus thrombosis. One patient in the study presented with thrombosis in both the superficial and profound venous systems. Another patient showed involvement of the right sinus, Galen vein and internal cerebral veins. The third patient had thrombosis in the profound spinal veins. Additionally, two of these patients experienced hemorrhagic venous heart attacks. On average, the time from the onset of symptoms indicating SARS-CoV-2 infection to a thrombotic event was 7 days, with a range of 2 to 7 days. It is worth noting that one of the patients had recently been diagnosed with diabetic ketoacidosis, while another patient was using oral contraceptives. All three patients had an unfavorable evolution and eventually succumbed to their conditions. Even though COVID-19 is severe and its primary effect is acute respiratory distress, cardiac disorders, acute renal disorders and thromboembolic events are increasingly being reported (13). The association between profound cerebral thrombosis and potentially fatal complications may complicate the initial clinical presentation of a patient infected with COVID-19. The cases presented herein offer us a new perspective on the fact that such cases display insights regarding the proofs accumulated according to which COVID-19 contributes to hypercoagulation and therefore increases the risk of mortality (13).

In the present study, the third case was an uncommon manifestation of catastrophic CVT in a relatively young patient who

had previously only presented with asthma and was infected with SARS-CoV-2, with an unfavorable outcome, leading to exitus. In the study by Cavalcanti *et al* (13), in the case of symptomatic CVT with a recent COVID-19 infection, one patient presented the same risk factor as case 2 in the present study, the use of oral contraceptives; COVID-19 infection was almost certainly a risk factor synergistic in both studies. Based on the given statement, it can be understood that in the present study, the third case described an uncommon manifestation of catastrophic cerebral venous thrombosis (CVT) in a relatively young patient. This patient had previously only been diagnosed with asthma and was also infected with SARS-CoV-2. Unfortunately, the outcome for this patient was unfavorable, leading to death (exitus).

The statement then refers to a study conducted by Cavalcanti *et al* (13), where a similar risk factor was observed in a patient with symptomatic CVT and recent COVID-19 infection. Specifically, in both the present study (case 2) and the study by Cavalcanti *et al*, the use of oral contraceptives was identified as a shared risk factor. Additionally, it suggests that COVID-19 infection likely acted as a synergistic risk factor in both cases, indicating that the combination of COVID-19 and oral contraceptive use may have contributed to the development of CVT.

Additionally, the study by Hameed *et al* (9) also included one patient who had used oral contraceptives. Another similarity of our study and the case report by Cavalcanti *et al* (13) is the fact that the patients from both studies received antibiotic treatments. A similarity between our study and the studies by Cavalcanti *et al* (13) and Hameed *et al* (9) consisted of the fact that in the present study, at least one patient exhibited dehydration, which is known to be a contributor to the pathology of COVID-19.

Mowla *et al* (5) presented a case series of 13 individuals with symptomatic CVT and concurrent COVID-19 infection from Iran, Singapore, and the United States. The mean age of the SARS-CoV-2 positive patients was substantially greater than that of the CVST-positive patients in the control sample. Their patients exhibited a much lower prevalence of recognized CVST risk factors than the general population. That is, the older age and considerably fewer risk factors for CVST in comparison to the non-SARS-CoV-2 infected comparison group suggested that SARS-CoV-2 infection may have served as a precursor for CVST. The statement suggests that in the comparison group, the patients infected with SARS-CoV-2 were older and had fewer risk factors for CVST compared to the non-SARS-CoV-2 infected group. This observation indicates that SARS-CoV-2 infection may have acted as a potential precursor or trigger for the development of CVST, considering that the infected group had an older age and fewer established risk factors for the condition.

Hameed *et al* (9) studied 20 cases with symptomatic CVT and recent COVID-19 infection from Pakistan, Egypt, Singapore, and the United Arab Emirates. In the same study, the most frequent neurological manifestations were headaches and seizures. Although mortality was high, survivors had a favorable functional neurological result.

The novelty of the present study compared with previous studies, comes from the fact that our patients were also tested for their hereditary thrombosis profile and the test revealed gene mutations. Furthermore, the patients were previously relatively healthy (one patient had asthma and the other was diagnosed at admission with diabetes type 2) and did not have any pathological antecedents in this area; thus, the COVID-19 infection was almost certainly an additive risk factor. It is also noteworthy as, in contrast to previous studies, in the present study, the patients were admitted due to their neurological symptoms and the COVID-19 infection was detected later. In the study of Hameed *et al* (9), CVT was a presenting characteristic in 65% of patients, whereas 35% of patients developed CVT when receiving treatment for COVID-19 infection. Additionally, in the study of Mowla *et al* (5), only one patient was asymptomatic at presentation; thus, another novelty of the present study is that the patients were asymptomatic at presentation, but CVST was present and apparent.

Additionally, in patients with severe COVID-19, rapid clinical deterioration or exacerbation could be associated with a neurological event, possibly CVST, adding to the disease's high fatality rate. Furthermore, physicians may consider SARS-CoV-2 infection as a differential diagnosis when dealing with patients who exhibited these neurological symptoms simultaneously during the COVID-19 pandemic in order to avoid a late diagnosis or misdiagnosis. Furthermore, accurate epidemiological data and pathophysiological results are necessary to aid future therapeutic management.

In summary, the present case series provides cases to exemplify that COVID-19 may serve as a significant contributor to hypercoagulation, thus increasing the potential lethality of the disease. Increased recognition of this uncommon but possibly curable consequence of COVID-19 infection is thus recommended, particularly given that the present is the only such study assessing COVID-19 infection in patients with CVT from Romania and South-East Europe, to the best of our knowledge.

In conclusion, patients with COVID-19 are at an increased risk of stroke, especially in the first 10 days after infection. A particular form of stroke is presented by CVT; the pathophysiological mechanisms presented are immune systemic processes, a cytokine storm leading to increased blood viscosity, and thrombogenesis within the state of hypercoagulability, at the same time producing inflammation marked by the increase of prothrombotic factors.

Recent data collected from research and studies supports that there is an increase in neurological pathologies, such as thrombotic complications of the sinuses and cerebral vessels for patients confirmed to be infected with SARS-CoV-2. Risk factors for CVT include infections, oral contraceptives, pregnancy, hematological disorders, mechanical or traumatic factors, autoimmune inflammatory disorders or even malign pathologies. Coexistent risk factors and age are well-defined risk factors for the development of CVT. Moreover, an association of the infection with SARS-CoV-2 virus for these patients may involve the onset of a procoagulant cascade and the evolution of the clinical status of the patient.

Acknowledgements

Not applicable.

Funding

No funding was received.

Availability of data and materials

The datasets used and/or analyzed during the present study are available from the corresponding author on reasonable request.

Authors' contributions

AA, LFM, AEG, CMM, SGP and SCC conceived the study. AA, CMM, LFM, AEG, CMM and SCC collected the data. AA, LFM, AEG and CMM analyzed the data. AA, CMM and LFM performed the investigation. AA, CMM, LFM, DCJ, SDA and CEF were involved in study design. AA, LFM, CMM, RAB and CAS: Software. CAS, FIR, AA, LFM, CMM and FIR: Validation. AA, LFM, CMM, CEF, AZS and FIR: Visualization. CAS, FIR, AA, LFM, CMM, AZS, SDA and SGP wrote the manuscript. AA, LFM, CMM, AZS, SDA, SGP and RAB reviewed and edited the manuscript. AA, AZS, CMM and LFM collected the data. AZS, SDA and SGP performed the analysis and interpretation of data. All authors confirm the authenticity of the raw data generated during the study.

Ethics approval and consent to participate

The current study was approved by the Ethics Committee of the Constanta Clinical Hospital, (Constanta, Romania; approval no. 31/03.11.2021).

Patient consent for publication

All patients consented in written form to the publication of the findings and images based on their examinations.

Competing interests

The authors declare that they have no competing interests.

References

1. World Health Organization (WHO): Coronavirus disease (COVID-19). WHO, Geneva. Accessed December 30, 2021.
2. Centrul național de supraveghere şi control al bolilor transmisibile-redheader. Cnscbt.ro.
3. Nannoni S, de Groot R, Bell S and Markus HS: Stroke in COVID-19: A systematic review and meta-analysis. Int J Stroke 16: 137-149, 2021.
4. Abouhashem S, Eldawoody H and Taha MM: Cerebral venous sinus thrombosis in patients with COVID-19 infection. Interdiscip Neurosurg 24: 101091, 2021.
5. Mowla A, Shakibajahromi B, Shahjouei S, Borhani-Haghighi A, Rahimian N, Baharvahdat H, Naderi S, Khorvash F, Altafi D, Ebrahimzadeh SA, *et al*: Cerebral venous sinus thrombosis associated with SARS-CoV-2; a multinational case series. J Neurol Sci 419: 117183, 2020.
6. Ulivi L, Squitieri M, Cohen H, Cowley P and Werring DJ: Cerebral venous thrombosis: A practical guide. Pract Neurol 20: 356-367, 2020.
7. Gaillard F, Ranchod A, Alhusseiny K, *et al*: Cerebral venous thrombosis. Radiopaedia. https://doi.org/10.53347/rID-4449. Accessed September 25, 2023.
8. Idiculla PS, Gurala D, Palanisamy M, Vijayakumar R, Dhandapani S and Nagarajan E: Cerebral venous thrombosis: A comprehensive review. Eur Neurol 83: 369-379, 2020.
9. Hameed S, Wasay M, Soomro BA, Mansour O, Abd-Allah F, Tu T, Farhat R, Shahbaz N, Hashim H, Alamgir W, *et al*: Cerebral venous thrombosis associated with COVID-19 infection: An observational, multicenter study. Cerebrovasc Dis Extra 11: 55-60, 2021.
10. Johansson A, Mohamed MS, Moulin TC and Schiöth HB: Neurological manifestations of COVID-19: A comprehensive literature review and discussion of mechanisms. J Neuroimmunol 358: 577658, 2021.
11. Mallett S, Allen AJ, Graziadio S, Taylor SA, Sakai NS, Green K, Suklan J, Hyde C, Shinkins B, Zhelev Z, *et al*: At what times during infection is SARS-CoV-2 detectable and no longer detectable using RT-PCR-based tests? A systematic review of individual participant data. BMC Med 18: 346, 2020.
12. Bolaji P, Kukoyi B, Ahmad N and Wharton C: Extensive cerebral venous sinus thrombosis: A potential complication in a patient with COVID-19 disease. BMJ Case Rep 13: e236820, 2020.
13. Cavalcanti DD, Raz E, Shapiro M, Dehkharghani S, Yaghi S, Lillemoe K, Nossek E, Torres J, Jain R, Riina HA, *et al*: Cerebral venous thrombosis associated with COVID-19. AJNR Am J Neuroradiol 41: 1370-1376, 2020.