Pseudoaneurysm of the superficial temporal artery after sagittal split ramus osteotomy: A case report

TOMOKI KATO[1], TAKESHI YOSHIDA[1], YASUYUKI ONISHI[2], TAKUMA WATANABE[1], SHIGEKI YAMANAKA[1], SHIZUKO FUKUHARA[1] and KAZUMASA NAKAO[1]

Departments of [1]Oral and Maxillofacial Surgery, and [2]Diagnostic Imaging and Nuclear Medicine, Graduate School of Medicine, Kyoto University, Kyoto 606-8507, Japan

Received May 1, 2023; Accepted September 20, 2023

DOI: 10.3892/etm.2023.12301

Abstract. Sagittal split ramus osteotomy (SSRO) is a widely performed orthognathic surgery; however, among the various reported complications of SSRO, pseudoaneurysms are rarely reported. Pseudoaneurysms are rare vascular lesions formed by damage to the arterial wall that can occur after trauma or postoperatively, causing uncontrolled bleeding. The present report describes a case of a pseudoaneurysm that occurred after SSRO in a 22-year-old female patient. Le Fort I osteotomy and bilateral SSRO were performed under general anesthesia to improve the gummy smile and mandibular asymmetry of the patient. While osteotomizing the medial side of the left SSRO, major bleeding occurred from the soft tissue of the posterior margin of the mandibular branch. Direct compression with gauze and a local hemostatic agent stopped the bleeding. Immediately after returning to the ward, bleeding was observed from the left wound site and marked swelling of the left buccal area occurred. Contrast-enhanced computed tomography revealed a pseudoaneurysm of the left superficial temporal artery (STA). Subsequently, arterial embolization for the pseudoaneurysm was performed. Overall, the present report describes a rare case of pseudoaneurysm of the STA as a postoperative complication of SSRO.

Correspondence to: Dr Tomoki Kato, Department of Oral and Maxillofacial Surgery, Graduate School of Medicine, Kyoto University, 54 Kawahara-cho, Shogoin, Sakyo-ku, Kyoto 606-8507, Japan
E-mail: t.kato.clpc@gmail.com

Abbreviations: CT, computed tomography; ICU, intensive care unit; SSRO, sagittal split ramus osteotomy; STA, superficial temporal artery

Key words: hemorrhage, orthognathic surgery, pseudoaneurysm, STA, therapeutic embolization

Introduction

Sagittal split ramus osteotomy (SSRO) is a widely used orthognathic surgery, and complications such as accidental intraoperative fracture, nerve damage, and heavy intraoperative bleeding can be encountered (1,2). Among the complications of SSRO, pseudoaneurysms are rarely reported. To the best of our knowledge, pseudoaneurysms have been reported in only eight cases, including our own experience (3-7).

Pseudoaneurysms are rare vascular lesions formed by damage to the arterial wall that occurs after a trauma or postoperatively, causing difficult-to-control bleeding (3). The injured vessels in the previously seven cases were the facial, maxillary, and inferior alveolar arteries. Pseudoaneurysms are at risk of rupturing and, if not treated appropriately, may result in neurological damage or death. Therefore, pseudoaneurysms should be treated in all cases. In our case, angiography was performed to confirm the lesion site, endovascular treatment was successful and produced good results. If a pseudoaneurysm is superficial, surgical treatment is possible. However, when an aneurysm is deeply located, as in our case, endovascular treatment which we performed for this patient, is indicated.

Here, we report a rare case of a female patient with a pseudoaneurysm arising from the superficial temporal artery (STA), as a postoperative complication of SSRO, for whom a timely diagnosis was made using angiography, and endovascular treatment with a discussion of the literature.

Case report

A 22-year-old healthy, 150 cm female, weighing 45 kg (body mass index, 20 kg/m^2), with a history of preoperative orthodontic treatment was referred to our department for improvement of her gummy smile and mandibular asymmetry. Le Fort I osteotomy and bilateral SSRO were performed under general anesthesia. The surgery began with a Le Fort I osteotomy and maxillary positioning using the intermediate splint described by Ellis (8), followed by osteosynthesis using a miniplate and monocortical screws. SSRO was then performed in accordance with Obwegeser's original method (9), and right-sided SSRO was performed uneventfully. While osteotomizing the inside of the left SSRO using an ultrasonic cutting instrument, a large amount of suspected arterial bleeding was observed

in the soft tissue of the posterior margin of the mandibular branch. Hemostasis was challenging; however, after using gauze compression and direct compression with hemostatic microfibrous collagen (Aviten; Zeria Pharmaceuticals, USA) the bleeding stopped.

After hemostasis, lateral osteotomy, bone division, and bone union were performed with a miniplate and monocortical screws in the planned occlusal position. After intraoperative hemostasis, there was no significant bleeding, and the estimated blood loss was approximately 1,600 ml.

After consulting the anesthesiologist in charge of the patient, intraoperative transfusion of allogeneic blood was not performed because the patient was young and had returned 800 ml of autologous transfusion. As no bleeding was observed after extubation and hemostasis was achieved, the patient was returned to the oral and maxillofacial surgery ward. Immediately after returning to the room, we observed bleeding from the left wound site and significant swelling of the left buccal area. Bleeding was stopped by direct compression with gauze. The patient was managed in the intensive care unit (ICU) for airway management, and because he continued to bleed after returning to the ICU, transfusions of six units of red blood cells and four units of fresh frozen plasma were administered.

Contrast-enhanced computed tomography (CT) was performed to confirm the vascular injury using a 320-detector row CT scanner (Aquilion One; Canon Medical Systems Corporation, Japan), with the following parameters: tube voltage: 120 kVp; tube current: 150 mA; spiral pitch factor: 0.844. A pseudoaneurysm of the left external carotid artery was observed in the left external carotid artery (Fig. 1). Angiography and endovascular treatment were performed on postoperative day one using an angiography system (Azurion; Philips Healthcare, Netherlands). The right femoral artery was punctured, and a 5F sheath was placed. A JB2 catheter was used to select the left external carotid artery. Angiography of the left external carotid artery revealed stenosis at the origin of the STA and delayed contrast of the STA. We considered this stenosis to be the site of vascular injury because it was close to the site where a pseudoaneurysm was observed on contrast-enhanced CT (Fig. 2A). Therefore, embolization of the proximal portion of the STA and the area from the proximal portion of the maxillary artery to the distal portion of the external carotid artery, where the STA branches, was desirable. However, the stenosis of the STA was so severe that the microwire could not be advanced into it. Therefore, detachable coil (Target 360 soft, Stryker, USA) and pushable coil (C-stopper coil, Piolax, Japan) were placed from the proximal portion of the maxillary artery to the distal portion of the external carotid artery (Fig. 2B). Angiography confirmed that the vessel was occluded in the area where the coil was placed, and the endovascular treatment was completed. On postoperative day three, the patient was discharged from the ICU and returned to the oral and maxillofacial surgery ward. Postoperative delirium was observed; however, the patient gradually recovered and was discharged on postoperative day 27 after rehabilitation.

Discussion

SSRO is one of the most common orthognathic surgical procedures. Similar to any surgical procedure, various intra- and postoperative complications can occur, including bleeding, fusion failure, infection, and nerve damage (1,2). Among intraoperative complications, bleeding is considered the most serious, and among the main causes of intraoperative bleeding in SSROs are damage to the facial, maxillary, and inferior alveolar arteries (10,11). Injury to the retromandibular vein can also cause bleeding that is difficult to stop (10,12). Panula *et al* (2) reported an injury to the maxillary artery during medial osteotomy of the SSRO that resulted in 4,000 ml of bleeding per hour, and Lanigan *et al* (10) reported an increased likelihood of maxillary artery laceration during medial osteotomy when the osteotomy was performed at a higher position near the sigmoid notch. In this case, contrast-enhanced CT and angiography suggested that an injury slightly above the bifurcation of the STA and the maxillary artery had caused the pseudoaneurysm. Vascular injury occurred despite careful and conservative osteotomy using an ultrasonic cutting instrument rather than a rotary cutting instrument to reduce the risk of bleeding due to entrapment of the surrounding tissue. Therefore, to prevent vascular injury, it is important to clearly define the operative field, carefully dissect the periosteum to prevent perforation into the subperiosteum, and correctly use the retractor.

Pseudoaneurysms have been reported to occur less frequently in mandibular osteotomies than in maxillary osteotomies (13,14). The first report of a pseudoaneurysm in a mandibular osteotomy was by Clark *et al* (15) in 1987 who reported a pseudoaneurysm following a mandibular vertical branch osteotomy. The first report of a pseudoaneurysm in an SSRO was by Silva *et al* (3) in 2007, and seven cases have been reported to date (Table I). Madani *et al* (16) reported a case of a pseudoaneurysm after SSRO; however, it was excluded because of postoperative trauma and controversy concerning whether it was a complication of SSRO (17). The mean age in the seven reported cases was 24 years (five males, two females), and all the affected vessels were right-sided. Aneurysms were identified in the maxillary artery (one patient), inferior alveolar artery (one patient), and facial artery (five patients), and the most common symptoms during the first episode were swelling, pain, and bleeding. The time from the first episode to a diagnosis of pseudoaneurysm was frequently reported as being as soon as the symptoms were recognized; however, there were also reports of between 1 and 4 weeks passing prior to a diagnosis having been made, suggesting that a pseudoaneurysm should be suspected when swelling, edema, and pain in the cheek area are observed with no known cause.

AlQahtani *et al* (14) reported that CT angiography should be performed, and intervention should be indicated in the presence of epistaxis, significant facial edema, and pain after Le Fort I osteotomy. In our case, a pseudoaneurysm of the left STA was diagnosed using CT angiography after sudden hemorrhage and swelling. Our patient's initial symptoms were similar to those reported in previous studies; however, the pseudoaneurysm site was the STA and our patient was female, which differed from those reported in previous studies.

Unlike true aneurysms, pseudoaneurysms are formed owing to arterial wall rupture. The outer layer of hematoma or fibrin in the surrounding tissue of the arterial wall becomes organic and forms a wall structure, and the lumen created through internal melting and resorption is then connected to the original arterial lumen (3). The period until the occurrence

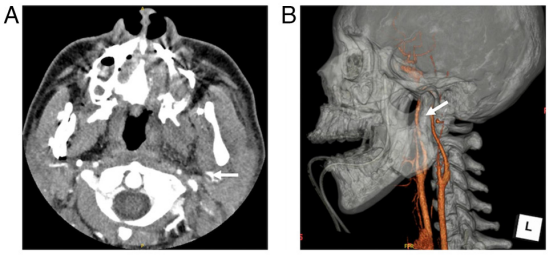

Figure 1. Pseudoaneurysm of the left superficial temporal artery (arrow). (A) Contrast-enhanced computed tomography (axial). (B) Three-dimensional constructed image. L, left side.

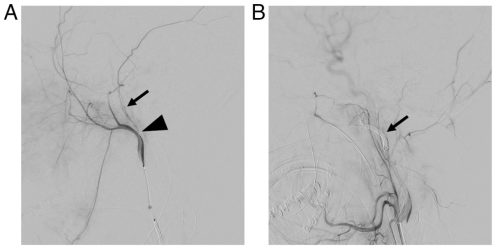

Figure 2. Lateral view of digital subtraction angiography during embolization procedure. (A) Angiography of the distal portion of the left external carotid artery before embolization shows narrowing (arrowhead) of the proximal portion of the left superficial temporal artery (arrow), which is considered as the site of vascular injury. Active bleeding or pseudoaneurysm were not observed. (B) Angiography of the left common carotid artery after embolization shows coils (arrow) that were placed from the proximal portion of the maxillary artery to the distal portion of the external carotid artery.

of a pseudoaneurysm varies, with cases reported as early as 4 h after a penetrating orbitofacial wound injury (18) and as late as 8 months after injury to the common carotid artery (19). In our case, a pseudoaneurysm was confirmed on postoperative contrast-enhanced CT, suggesting that the formation of the pseudoaneurysm occurred within a few hours after the artery was injured, causing rebleeding.

Endovascular treatment, as the first choice of treatment for pseudoaneurysms, is a safe procedure to perform (20). Kumar *et al* (13) suggested that embolization of pseudoaneurysms after orthognathic surgery is always advantageous over surgical intervention as it spares more proximal vessels and allows selective embolization of distal bleeding sources. Furthermore, it has the advantage of maintaining blood supply to the osteotomized segment through preventing aseptic necrosis, which is particularly important after orthognathic surgery. In our case, angiography was performed to confirm the lesion site, followed by endovascular treatment with a good outcome.

If an aneurysm of the external carotid artery is superficial, surgical treatment is possible. However, when an aneurysm is deeply located, as in our case, endovascular treatment such as stent grafting (21) and coil embolization, which we performed for this patient, is indicated. Since the external carotid artery that feeds the maxillofacial region has well-developed collateral vasculature and embolization rarely causes soft tissue necrosis (22), preservation of blood flow to the mother vessel through stent grafting is not always necessary. Therefore, we opted for coil embolization to ensure hemostasis rather than to preserve blood flow. When coil embolization of cerebral

Table I. Cases of pseudoaneurysm after sagittal split ramus osteotomy.

First author/s, year	No.	Age, years	Sex	Affected side	First episode	Time from surgery to first episode	Artery	Time from surgery to diagnosis	Intervention	(Refs.)
Silva *et al*, 2007	1	20	M	Right	Cheek swelling; pulsations	N.A.	Maxillary artery	6 weeks	Embolization with coils	(3)
Precious *et al*, 2012	2	32	M	Right	Increasing swelling and pain	2 weeks	Facial artery	3 weeks	Embolization with coils	(4)
	3	26	M	Right	Mild discomfort	1 week	Facial artery	5 weeks	Embolization with coils	
	4	20	M	Right	Increased edema	1 week	Facial artery	1 week	Embolization	
Jo *et al*, 2013	5	19	M	Right	Pain with swelling	N.A.	Facial artery	3 weeks	Embolization with coils	(5)
Neto *et al*, 2019	6	33	F	Right	Swelling, pain	3 days	Facial artery	15 days	Cyanoacrylate embolization	(6)
AbuKaraky *et al*, 2021	7	21	F	Right	Recurring bleeding; throbbing pain of the throat	18 days	Inferior alveolar artery	18 days	Embolization with coils	(7)
Present study	8	22	F	Left	Bleeding, swelling temporal artery	0 days	Superficial	1 day	Embolization with coils	-

F, female; M, male; N.A., not applicable.

aneurysms is performed, antithrombotic agents are typically administered pre- and postoperatively in consideration of the risk of cerebral infarction in clinical practice. However, in our case, coil embolization was performed without antithrombotic agents for the following two reasons. First, the embolization site was at the junction of the maxillary artery and superficial temporal artery, and the risk of cerebrovascular disease due to thrombosis was considered to be low. Second, administration of antithrombotic agents carries a risk of hemorrhagic complications during the embolization procedure.

Pseudoaneurysms are at risk of rupturing and, if not treated appropriately, may result in neurological damage or death. Therefore, pseudoaneurysms should be treated in all cases. In our case, endovascular treatment was successful and produced good results. However, since endovascular treatment may not be effective and surgical intervention may be necessary, prompt collaboration with head and neck surgeons as well as radiologists is extremely important.

In conclusion, we report a rare case of a female patient with a pseudoaneurysm, as a postoperative complication of SSRO in the STA, for whom a timely diagnosis was made using angiography. The pseudoaneurysm was treated with therapeutic embolization.

Acknowledgements

The authors would like to thank Dr Chikashi Takeda and Dr Gento Yasuhara (Department of Anesthesia, Kyoto University Hospital, Kyoto, Japan) who contributed to patient treatment and care.

Funding

No funding was received.

Availability of data and materials

The datasets used and/or analyzed during the current study are available from the corresponding author on reasonable request.

Authors' contributions

TK and YO acquired the clinical data of the patient, performed the literature review, and edited the manuscript. TK and TY contributed substantially to the study concept and design. KN, TW, SY and SF acquired data and provided clinical advice. TK and YO revised the manuscript. TK had a major role in writing the manuscript. TK, TY and YO confirm the authenticity of all the raw data. All authors have read and approved the final version of the manuscript.

Ethics approval and consent to participate

Not applicable.

Patient consent for publication

Written informed consent was obtained from the patient for the publication of this case report and accompanying images.

Competing interests

The authors declare that they have no competing interests.

References

1. Ferri J, Druelle C, Schlund M, Bricout N and Nicot R: Complications in orthognathic surgery: A retrospective study of 5025 cases. Int Orthod 17: 789-798, 2019.
2. Panula K, Finne K and Oikarinen K: Incidence of complications and problems related to orthognathic surgery: A review of 655 patients. J Oral Maxillofac Surg 59: 1128-1137, 2001.
3. Silva AC, O'Ryan F, Beckley ML, Young HY and Poor D: Pseudoaneurysm of a branch of the maxillary artery following mandibular sagittal split ramus osteotomy: Case report and review of the literature. J Oral Maxillofac Surg 65: 1807-1816, 2007.
4. Precious DS, Powell JE, Tuzuner AM, Schmidt M, Doucet JC and Vandorpe R: False aneurysms after sagittal split ramus osteotomies. J Oral Maxillofac Surg 70: e58-e65, 2012.
5. Jo HW, Kim YS, Kang DH, Lee SH and Kwon TG: Pseudoaneurysm of the facial artery occurred after mandibular sagittal split ramus osteotomy. Oral Maxillofac Surg 17: 151-154, 2013.
6. Neto TJL, Maranhão CAA and Neto PJO: Pseudoaneurysm of facial artery after orthognathic surgery. J Craniofac Surg 30: e607-e609, 2019.
7. AbuKaraky A, Al Mousa M, Samara OA and Baqain ZH: Pseudoaneurysm in the inferior alveolar artery following a bad split in bilateral sagittal split osteotomy. Int J Oral Maxillofac Surg 50: 798-800, 2021.
8. Ellis E III: Bimaxillary surgery using an intermediate splint to position the maxilla. J Oral Maxillofac Surg 57: 53-56, 1999.
9. Trauner R and Obwegeser H: The surgical correction of mandibular prognathism and retrognathia with consideration of genioplasty. I. Surgical procedures to correct mandibular prognathism and reshaping of the chin. Oral Surg Oral Med Oral Pathol 10: 677-689, 1957.
10. Lanigan DT, Hey J and West RA: Hemorrhage following mandibular osteotomies: A report of 21 cases. J Oral Maxillofac Surg 49: 713-724, 1991.
11. MacIntosh RB: Experience with the sagittal osteotomy of the mandibular ramus: A 13-year review. J Maxillofac Surg 9: 151-165, 1981.
12. Behrman SJ: Complications of sagittal osteotomy of the mandibular ramus. J Oral Surg 30: 554-561, 1972.
13. Kumar A, Kaur A, Singh M, Rattan V and Rai S: 'Signs and symptoms tell all'-pseudoaneurysm as a cause of postoperative bleeding after orthognathic surgery-report of a case and a systematic review of literature. J Maxillofac Oral Surg 20: 345-355, 2021.
14. AlQahtani FA, Kuriadom ST, Bishawi K and AlAssiri N: Pseudoaneurysms and orthognathic surgery: A systematic review and a proposed algorithm of treatment. J Craniofac Surg 34: 1031-1035. 2023.
15. Clark R, Lew D, Giyanani VL and Gerlock A: False aneurysm complicating orthognathic surgery. J Oral Maxillofac Surg 45: 57-59, 1987.
16. Madani M, Veznedaroglu E, Pazoki A, Danesh J and Matson SL: Pseudoaneurysm of the facial artery as a late complication of bilateral sagittal split osteotomy and facial trauma. Oral Surg Oral Med Oral Pathol Oral Radiol Endod 110: 579-584, 2010.
17. Dediol E: Pseudoaneurysm of the facial artery as a complication of the sagittal split osteotomy. Oral Surg Oral Med Oral Pathol Oral Radiol Endod 110: 683-684, 2010.
18. Ferry DJ Jr and Kempe LG: False aneurysm secondary to penetration of the brain through orbitofacial wounds. Report of two cases. J Neurosurg 36: 503-506, 1972.
19. Beale PJ: Late development of a false aneurysm of the facial region. J Oral Surg 58: 76-78, 1971.
20. Fernández-Prieto A, García-Raya P, Burgueño M, Muñoz-Caro J and Frutos R: Endovascular treatment of a pseudoaneurysm of the descending palatine artery after orthognathic surgery: Technical note. Int J Oral Maxillofac Surg 34: 321-323, 2005.
21. Nadig S, Barnwell S and Wax MK: Pseudoaneurysm of the external carotid artery-review of literature. Head Neck 31: 136-139, 2009.
22. Guss J, Cohen MA and Mirza N: Hard palate necrosis after bilateral internal maxillary artery embolization for epistaxis. Laryngoscope 117: 1683-1684, 2007.