A novel animal model of abdominal aortic aneurysm by mechanical injury

SOO-HONG KIM[1*], JE-HYUNG PARK[2*], DONG HYUN KIM[3], JIN-HO MUN[3], JAE HUN CHUNG[1] and SANG SU LEE[3]

[1]Department of Surgery, School of Medicine, Pusan National University, Pusan National University Yangsan Hospital, Yangsan, Gyeongsangnam 50612; [2]Department of Surgery, Bongseng Memorial Hospital, Busan 48775; [3]Department of Surgery, Division of Endovascular and Vascular Surgery, School of Medicine, Pusan National University Yangsan Hospital, Pusan National University, Yangsan, Gyeongsangnam 50612, Republic of Korea

Received January 27, 2023; Accepted July 6, 2023

DOI: 10.3892/etm.2024.12391

Abstract. The present study established a novel and reproducible animal model to study abdominal aortic aneurysms. In total, 22 adult Lewis rats underwent a procedure to produce mechanical injuries at the infrarenal aorta which was opened temporarily. The aortas were injured 6 times and repaired. Those rats were divided into 2 groups and the aortic aneurysm tissue was harvested after 42 (6-week group) or 63 (9-week group) days and evaluated for the progression of aortic aneurysms. In the 6-week group, changes in the aneurysm were observed in 6/10 (60%) rats and the mean maximum diameter of the aorta demonstrated a 119% increase in size from the baseline measurement. In the 9-week group, changes in the aneurysm were observed in 8/11 (88%) rats and the mean maximum diameter of aorta demonstrated a 133% increase in size. Additional findings from the aortic aneurysm tissue were found microscopically, including the destruction of the tunica media and the elastic fiber. The present study demonstrated that this novel animal model for the development of abdominal aortic aneurysms (AAAs) produced by mechanical injury may have high reproducibility and similar gross and microscopic morphology to humans. This model could be helpful to investigate the treatment of AAAs.

Correspondence to: Dr Sang Su Lee, Department of Surgery, Division of Endovascular and Vascular Surgery, School of Medicine, Pusan National University Yangsan Hospital, Pusan National University, 20 Geumo-ro, Mulgeum, Yangsan, Gyeongsangnam 50612, Republic of Korea
E-mail: phoenixdr@naver.com

[*]Contributed equally

Key words: aortic aneurysm, abdominal, models, animal, aorta, rats, mechanical injury

Introduction

An abdominal aortic aneurysm (AAA) is an abnormal dilation of the abdominal aorta and is associated with a mortality rate of >50% in the event it ruptures. AAAs are characterized by an increase of ³50% in aortic diameter compared with the normal diameter or a maximum infrarenal aortic diameter ≥30 mm (1). The prevalence of AAA increases with age and ~4% of men >55 years have an AAA (1) and AAAs cause ~1% of all deaths in developed countries (2).

Therapeutic options for AAA are currently limited to surgical or interventional repair to prevent rupture which can be effective for several decades; however, no pharmacologic therapy has been reported to have a significant effect in humans (1,3,4). A delay in the development of AAA treatments is partly due to the absence of an AAA animal model of human AAA (3) and because human AAA tissue can only be obtained during surgical repair, investigation of AAA with human tissue is limited (5). Previous studies have proposed AAA animal models (2,6); however, more evidence of histological features and similarities in shape is needed to establish an effective AAA animal model for the study of human clinical applications. A common animal model for the aneurysmal aortic lesions consists of the transient perfusion of the abdominal aorta with porcine pancreatic elastase (PPE) (2,7-10). Another common model of AAA induction is $CaCl_2$ perfusion of the aorta (2,4). Other AAA induction methods, including mechanical induction through aortic stretching, patching or injury, have also been reported (2). In certain cases, a combination of the aforementioned methods have been reported (11-13). The present model causes mechanical injury to the aortic intima, making it similar to human AAA. The present study established a novel and reproducible animal model of AAA using mechanical injury. This model is based on the hypothesis that the mechanical injury will initiate the inflammation process and destruction of the elastin and collagen fibers at the abdominal aorta, as observed in human AAA tissue.

Materials and methods

This experimental animal study was approved by the Pusan National University Institutional Animal Care and Use

Committee (approval no. PNU-2018-1909; Republic of Korea). A total of 22 adult Lewis rats (male; age, 8-12 weeks; Koatech Technology Corporation) weighing ~330 g (range, 256-450 g) were used. Rats were housed and maintained at 25˚C and 50% humidity, with a 12 h light/dark cycle according to the institutional animal protocols. All rats had regular food and water *ad libitum* with no restrictions on movement. All rats were from a specific pathogen free herd and evaluated as healthy by a veterinarian prior to inclusion. The rats were randomly divided into 2 groups and harvested after 42 (6-week group) and 63 (9-week group) days to investigate the progression of the AAAs. All experimental procedures were performed according to Pusan National University's guidelines for animal care.

AAA induction. High blood pressure could be the cause of mechanical injuries that initiate the inflammation process and destruction of the elastin and collagen fibers of the abdominal aorta. Therefore, the present study used a mechanical injury model to mimic the physical effects that may lead to AAAs.

The rats were anesthetized with an intraperitoneal injection of pentobarbital sodium (120 mg/kg). The skin incision site was disinfected with a povidone-iodine swab (Q & Q Pham Co. Ltd.). After midline laparotomy, the aorta and inferior vena cava were carefully dissected from neighboring tissues. The infrarenal aorta was then exposed by isolating it from the inferior vena cava. The aorta was clamped distally and superiorly to the renal artery and proximally and inferiorly to the gonadal artery. After ligating the lumbar artery, the entire circumference of the abdominal aorta was temporarily opened to apply the same level of injury and tension in all directions. Six deep stabs from the intima to the adventitia around the aortic wall were performed using a 7-0 blue nylon cutting needle (25 mm; 3/8; 75 cm; AILEE Co., Ltd.). The opened aortic wall was anastomosed using 9-0 Monosof™ sutures (5 mm; 3/8; 13 cm; Medtronic) using the 12-14 point open-loop technique. Hemostasis was performed using cotton swabs. Finally, the retroperitoneum and laparotomy were closed with 5-0 or 6-0 Vicryl™ sutures (Ethicon, Inc.; Johnson & Johnson) (Figs. 1 and 2).

Postoperative care. The rats were separated and raised in the same environment as aforementioned. Rats were housed and maintained at 25˚C and 50% humidity, with a 12 h light/dark cycle according to the institutional animal protocols. All rats had regular food and water *ad libitum* with no restrictions on movement.

Harvest and data collection. On postoperative day 42 and 63, the respective groups of rats were euthanized by intraperitoneal injection with a lethal dose of pentobarbital (120 mg/kg). After a midline laparotomy, the aorta from the level of the renal artery to the gonadal artery, including the AAAs, was harvested. Microscopic AAA were defined as cases that had a >50% increase in aorta diameter at the time of harvest compared with the initially measured diameter of the infrarenal aorta in each rat (Fig. 3). Representative 4-μm sections of formalin-fixed, in 10% neutral-buffered formalin at room temperature for 12 h, paraffin-embedded tissues were cut on charged glass slides. Slides were placed in a 65˚C oven for 20 min to dry the tissue. Immunostaining was performed using the Bond-Max staining instrument (Leica Microsystems, Inc.) as described by the manufacturer. Briefly, paraffin wax was removed with a Bond Dewax Solution (cat. no. AR9222; Leica Biosystems Nussloch GmbH) at 72˚C and the sections were rehydrated. Heat-induced epitope retrieval was achieved using a Bond Epitope Retrieval Solution (EDTA-based buffer; Leica Microsystems, Inc.) for 20 min at 100˚C. The section was then incubated with antibodies SMA (cat. no. M0851; monoclonal; 1:800; DAKO; Agilent Technologies, Inc.) for 15 min at room temperature. The secondary antibody was incubated for 8 min and horseradish peroxidase (HRP) for 10 min at room temperature. Both the secondary antibody and HRP were provided as ready-to-use kit (Bond™ Polymer Refine Detection; cat. no. DS9800; Leica Microsystems, Inc.). Finally, 3,3'-diaminobenzidine tetrahydrochloride was used as the chromogen. Verhoeff-van Gieson staining for elastin were also performed at room temperature for 30 min. The slides were examined using the Olympus BX53 light microscope (Olympus Corporation) by a single pathologist.

Results

Summary data. In the 6-week group, 10/11 rats survived the study period and in the 9-week group 11/11 rats survived the study period (Table I). The mean weight of the rats was 338.5±49.3 g (range, 256-450 g) and 452±21.3 g (range, 411-500 g) at the time of the procedure and the time of harvest, respectively. The mean operative time was 33±3.3 min (range, 24-37 min). No immediate postoperative complications were noted. One rat died during the follow-up period due to an unknown cause and its data were omitted from the analysis.

Macroscopic study. Preoperatively, the overall mean maximum diameter of the infrarenal aorta was 1.3±0.13 mm (range, 1.0-1.5 mm). In the 6-week group, a marked increase in the diameter of the aneurysm was observed in 6/10 (60%) of the surviving rats. The mean maximum diameter of the infrarenal aorta was 2.85±2.63 mm which was a 119% increase from the preoperative size. In the 9-week group, changes in the diameter of the aneurysm were observed in 8/11 (88%) of the rats. The mean maximum diameter of the infrarenal aorta was 2.9±1.25 mm, a 123% increase from the preoperative size (Table I).

Microscopic study. In the transverse section of the aorta from all induced samples in the 6- and 9-week groups, the difference in the diameter compared with the control under the same magnification was clear (Fig. 4). The decrease in the cellular density was not apparent in the H&E slides. The vascular smooth muscle cells were gone and were replaced by hyalinizing material. The loss of smooth muscle cells was confirmed by staining for smooth muscle actin (Fig. 5). The thickness of the protruding vessel wall was irregular and elastin production was reduced (Fig. 6). The elastic fibers showed breaks and looked flat with no coiling or resilience, and the number of elastic fibers was reduced (Fig. 4).

Discussion

The present study aimed to establish evidence for a novel and reproducible animal model of AAA. It was hypothesized that

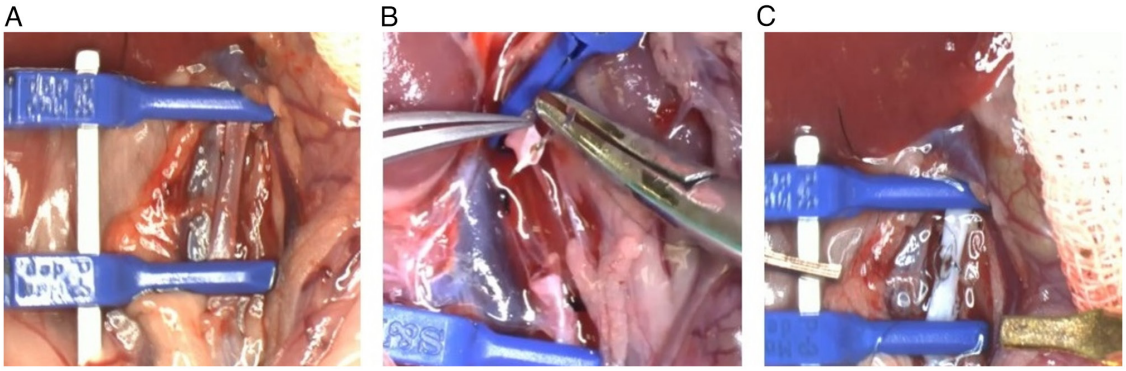

Figure 1. (A) Aorta was clamped at proximal and distal aorta. (B) A total of 6 cuts were made into the entire layer of the vessel wall with a cutting needle of Blue Nylon 7-0. (C) Opened aorta was anastomosed with 9-0 Monosof™ sutures using the open-loop suture technique.

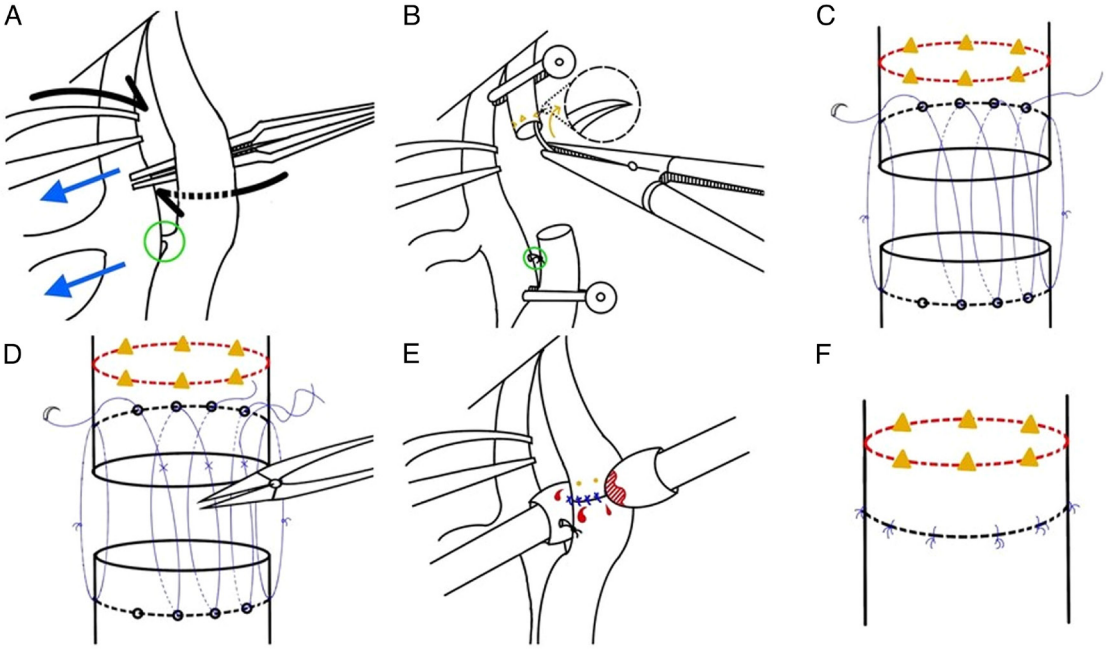

Figure 2. (A) Aorta and inferior vena cava were dissected. Ligating the lumbar artery, the entire circumference of the abdominal aorta was opened. (B) A total of six deep stabs from the intima to the adventitia were performed using a cutting needle of blue nylon 7-0. (C and D) The opened aortic wall was anastomosed with 9-0 Monosof™ sutures using as open loop suture technique. (E and F) Hemostasis by pressing against the anterior and posterior walls of anastomosis site with a cotton swab.

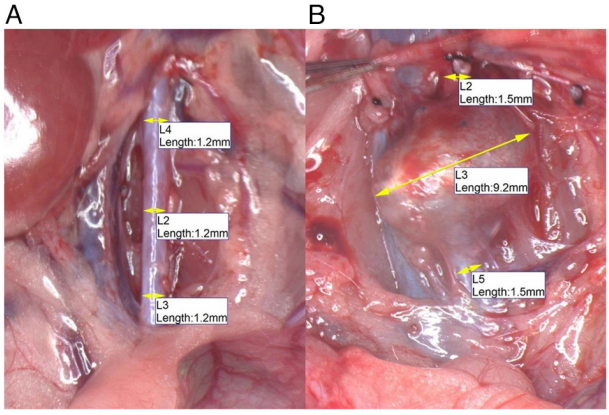

Figure 3. Comparison of normal aorta with induced abdominal aortic aneurysm. Transverse sections of the (A) control and (B) experimental aortas under the same magnification (x20). The difference in the diameter between the two aortas is clearly visible.

mechanical injury would initiate the inflammation process and destruction of the elastin and collagen fibers at the abdominal aorta, thus mimicking the formation of AAAs in humans. To evaluate this hypothesis, changes in the AAA tissue at 6 and 9 weeks were evaluated by observing macro- and microscopic. The results of the present supported this hypothesis, as the animal models demonstrated similar morphological and microscopic findings as human cases of AAA. This can be seen by how induced AAAs in the present model had a symmetric fusiform shape in the infrarenal area, similar to human AAAs.

The development of new experimental techniques, genetic analysis and robust molecular tools has contributed to the understanding of the pathophysiology of AAAs. While certain cellular mechanisms, such as inflammatory response mechanisms, have been reported to be responsible for AAA formation (14), the application of physical force to put pressure

Table I. Changes in animal weight and maximum diameter of the infrarenal aorta.

A, 6-week group

No.	Initial weight,g	Weight at harvest, g	Preoperative maximum diameter of infrarenal aorta, mm	Maximum diameter of infrarenal aorta at harvest, mm	Increase in aorta diameter, (%)
1	320	500	1.3	2.5	92
2	293	454	1.1	1.1	0
3	256	423	1.2	1.1	-8
4	260	443	1.3	1.3	0
5	364	452	1.3	7.2	454
6	364	444	1.4	4.8	243
7	363	463	1.2	9.2	667
8	364	470	1.3	3.2	146
9	364	443	1.4	3.8	171
10	357	411	1	1.5	50
11	450	Died	1.4	Died	Died
Mean ± SD	363±53.3	448±23.4	1.3±0.12	2.9±2.6	119±210

B, 9-week group

No.	Initial weight,g	Weight at harvest, g	Preoperative maximum diameter of infrarenal aorta, mm	Maximum diameter of infrarenal aorta at harvest, mm	Increase in aorta diameter, (%)
1	359	490	1.4	5.5	293
2	366	478	1.5	5	233
3	370	466	1.4	1.8	29
4	365	438	1.3	2.9	123
5	270	462	1.2	1.3	8
6	276	443	1.2	2.8	133
7	290	454	1.1	2.9	164
8	290	446	1.3	2.8	115
9	284	458	1.1	3.1	182
10	281	416	1.1	1.5	36
11	288	450	1.2	3.6	200
Mean ± SD	312±40	454±19.1	1.2±0.13	2.9±1.3	133±85

SD, standard deviation.

on the heartbeat and blood flow are not commonly used techniques for AAA animal modeling. However, hypertension is positively associated with the incidence of AAAs (15) and physical force, such as that from high blood pressure, could be the cause of mechanical injuries that initiate the inflammation process and the destruction of the elastin and collagen fibers of the abdominal aorta (16). Therefore, a mechanical injury model was used to mimic the physical effects that may lead to AAAs in the present study. Several models were evaluated in pilot studies, including end-to-end anastomosis, out-in-needle injury and in-out-needle injury. Aneurysm was not formed in the end-to-end anastomosis model, and bleeding was not controlled in the out-in-needle injury model. Therefore, the in-out-needle injury model was further evaluated in the present study as this had demonstrated the best results in the pilot studies (data not shown).

There are numerous AAA animal models in use, each of which have drawbacks in the matching of the effects of human AAAs. For example, the porcine pancreatic elastase model is commonly used and AAAs have been previously induced via PPE perfusion in mice (2,8). PPE modeling in rats has been reported to demonstrate similar temporal and pathophysiological findings as those found in humans, such as the correlation of aortic dilation with the state of the inflammatory response,

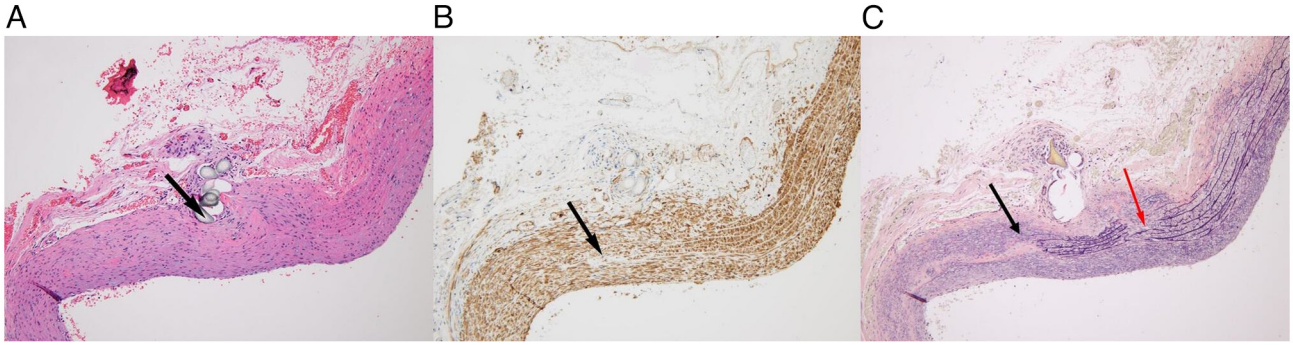

Figure 4. Microscopic results. (A) Hematoxylin and eosin staining, the black arrow indicates decreased cellular density. (B) α-smooth muscle actin staining, the black arrow indicates reduction in the number of smooth muscle cells. (C) Verhoeff-van Gieson staining demonstrating that the elastic fiber is generally reduced and looks flat with no coiling or resilience. The black arrow indicates fiber breaks and the red arrow indicates a loss of integrity. Magnification, x100.

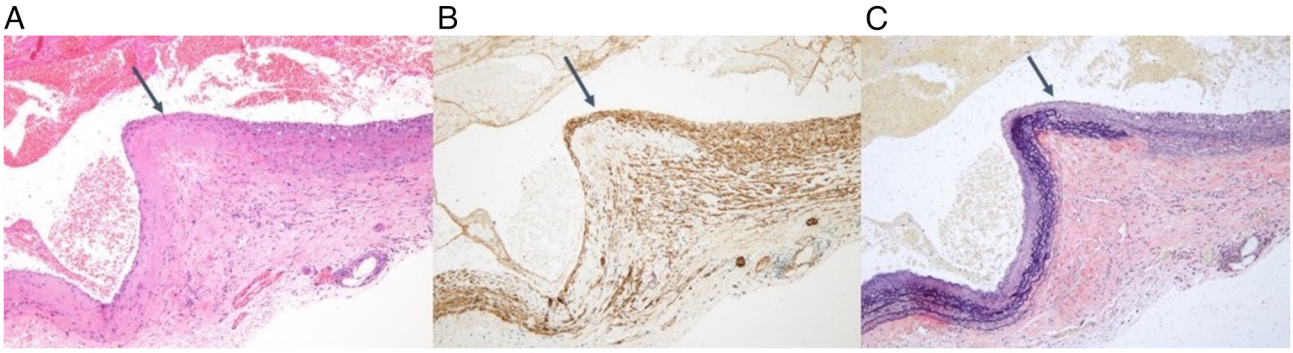

Figure 5. Microscopic findings. (A) Hematoxylin and eosin, (B) α-smooth muscle actin and (C) Verhoeff stained slides. In the area indicated by the arrow, the vascular smooth muscle cells are gone and have been replaced by the hyalinizing material. Magnification, x100.

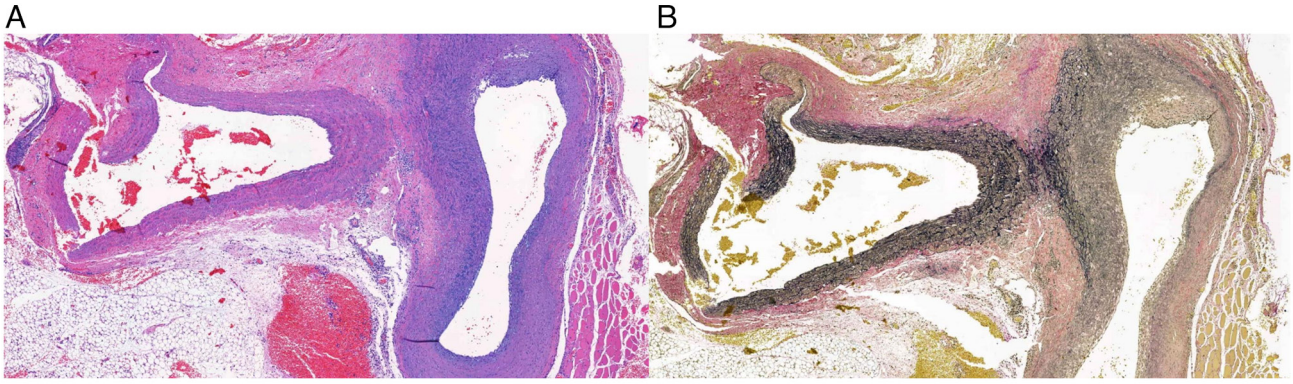

Figure 6. Microscopic findings. (A) Transverse section stained with hematoxylin and eosin show aneurysmal change. (B) The protruded vessel wall is irregular in thickness and there are reduced levels of elastin is attenuated demonstrated when stained using Verhoeff-van Gieson. Magnification, x50.

which leads to the destruction of the medial elastic tissue (2,8). In rat PPE models, the rates of successful induction have been high but in larger animals, the success rates have been reported to be lower (9) due to technical difficulties with the model. Specifically, when infusing the PPE, cannulation of the aorta is required and leakage of the PPE solution during perfusion happens frequently, and this process can result in the death of the animal (2).

The $CaCl_2$ model is another frequently used model (2). Exposing the aorta to $CaCl_2$ leads to the destruction of the elastin fibers of the wall of the aorta, the infiltration of inflammatory cells and AAA induction. However, periaortic $CaCl_2$ application does not reliably induce AAA formation, with success varying from 80-100% of the models developing aneurysms (2,10,17).

An angiotensin II model in mice is technically less challenging than others mentioned here and there is no need for major surgical manipulation. It has been previously reported that AAA is encouraged in hyperlipidemic apolipoprotein E-deficient mice with continuous subcutaneous angiotensin II infusion (5,18). However, the induced AAAs in this model have certain differences when compared with human AAAs such as

a significantly higher incidence of aortic dissection and rupture, and more frequently observed suprarenal AAAs, while humans present a much higher incidence of infrarenal AAAs (2).

The xenograft model uses implanted xenograft arterial tissues to generate AAAs using the rejection of the implanted tissue by the immune response (7,19). Models which use knockout animals, which focus on the disruption of one or more gene alleles resulting in the creation of strain-deficient animals have also been previously reported (2).

The mechanical injury model used in the present study has three distinct advantages. First, the model had high reproducibility. At 9 weeks, the size of the aorta increased by up to 133% in 88% of the rats (8/11). Reproducibility is one of the most important conditions to meet in animal models so that additional studies can be performed reliably. Second, the gross and microscopic findings of the model were very similar to findings previously reported in human AAAs. The induced AAAs in this model had a symmetric fusiform shape in the infrarenal area, similar to human AAAs. However, in other animal models, saccular shaped AAAs (20) or suprarenal AAAs (5) were reported to have been induced. Because the different shapes could indicate different blood flow and progression, gross similarities are important to consider. In the present model, important microscopic findings were found such as the destruction of the tunica media and the elastic fibers, neovascularization, infiltration of lymphocytes and intraluminal mural hematomas (19). In particular, the histological characteristic of broken elastin in the formation of an aneurysm is similar to that of human aneurysm. Finally, the model described in the present study can be reproduced at a very low cost as it did not require special drugs or equipment. Only typical vascular surgical instruments were needed to perform the surgical intervention and because the rats were allowed to live without subsequent manipulation, there was no additional cost. Furthermore, no paraplegia occurred in the short operation time of 30-50 min.

The limitation of the model comes from the surgical intervention which required microsurgical skills, which can be difficult for inexperience staff to follow. Improper surgical technique may result in animal deaths or unsuccessful induction of AAAs, which could cause reproducibility to decrease and costs to increase. Furthermore, the present study only performed a 9-week investigation. Because the AAA diameters increased from 6- to 9-weeks, it could be hypothesized that the AAAs would grow larger over time, however this and whether they eventually rupture like human AAAs was not confirmed. Before starting to use this model, it is recommended that researchers should be trained on animal experiments and vascular management. Furthermore, the present study did not yield clear results for the inflammatory response and confirmation of the inflammatory response requires further microscopic examination in future studies.

In the 6-week group, it was demonstrated that the aortic diameter did not increase in 3/10 animals. They typically had an initial weight of <300 g, which was 18% less than the mean weight of 365 g. This suggested the need to investigate the relationship between weight and hemodynamic parameters such as blood pressure and cardiac output. Further studies are also required to elucidate the timeframe for the occurrence of AAAs and what the effect of proteins expressed by different genes on the formation of aneurysms in mice with and without aneurysms are. Whether the use of certain drugs can prevent the formation of aneurysms, delay the continued increase of an aneurysm until rupture or even make the aneurysm shrink also requires evaluation. Future studies, are also required to assess the long-term results of this model while measuring the AAAs with ultrasound. This model should also be trialed in larger animals although there have been many reports of failures when applied to larger animals (2,21). However, a trial in larger animals is needed to confirm that the AAAs in the present model are similar to human AAAs with infrarenal symmetric fusiform shape.

In conclusion, the mechanical injury-induced AAA animal model reported in the present study demonstrated very similar morphological and microscopic findings to those of human AAAs. The model showed high reproducibility, with 60% induction in the 6-week group and 88% induction in the 9-week group. Though the present study was performed in rodents, this method could provide evidence for AAA treatment if it can be applied to middle and large sized animals.

Acknowledgements

Not applicable.

Funding

The present study was supported by a 2022 research grant from Pusan National University Yangsan Hospital.

Availability of data and materials

The datasets used and/or analyzed during the current study are available from the corresponding author on reasonable request.

Authors' contributions

SHK, JHP and SSL were responsible for study conception and design. SHK, JHP, DHK, JHM and JHC were responsible for data analysis and interpretation. SSL was responsible for data collection. SHK, JHP and SSL confirm the authenticity of all the raw data. SHK, JHL and SSL were responsible for writing and revising the article. SHK, JHP, DHK, JHL and SSL were responsible for final approval of the article. SSL was responsible for overall supervision. All authors have read and approved the final manuscript.

Ethics approval and consent to participate

The present study was approved by Pusan National University Institutional Animal Care and Use Committee (approval no. PNU-2018-1909; Republic of Korea).

Patient consent for publication

Not applicable.

Author information

Dr Sang Su Lee ORCID: https://orcid.org/0000-0003-0648-976X.

Competing interests

The authors declare that they have no competing interests.

References

1. Rughani G, Robertson L and Clarke M: Medical treatment for small abdominal aortic aneurysms. Cochrane Database Syst Rev: CD009536, 2012.
2. Patelis N, Moris D, Schizas D, Damaskos C, Perrea D, Bakoyiannis C, Liakakos T and Georgopoulos S: Animal models in the research of abdominal aortic aneurysms development. Physiol Res 66: 899-915, 2017.
3. Yoshimura K, Morikage N, Nishino-Fujimoto S, Furutani A, Shirasawa B and Hamano K: Current status and perspectives on pharmacologic therapy for abdominal aortic aneurysm. Curr Drug Targets 19: 1265-1275, 2018.
4. Wang Y, Krishna S and Golledge J: The calcium chloride-induced rodent model of abdominal aortic aneurysm. Atherosclerosis 226: 29-39, 2013.
5. Fashandi AZ, Hawkins RB, Salmon MD, Spinosa MD, Montgomery WG, Cullen JM, Lu G, Su G, Ailawadi G and Upchurch GR Jr: A novel reproducible model of aortic aneurysm rupture. Surgery 163: 397-403, 2018.
6. Mouton R, Pollock J, Soar J, Mitchell DC and Rogers CA: Remote ischaemic preconditioning versus sham procedure for abdominal aortic aneurysm repair: An external feasibility randomized controlled trial. Trials 16: 377, 2015.
7. Allaire E, Muscatelli-Groux B, Mandet C, Guinault AM, Bruneval P, Desgranges P, Clowes A, Méllière D and Becquemin JP: Paracrine effect of vascular smooth muscle cells in the prevention of aortic aneurysm formation. J Vasc Surg 36: 1018-1026, 2002.
8. Halpern VJ, Nackman GB, Gandhi RH, Irizarry E, Scholes JV, Ramey WG and Tilson MD: The elastase infusion model of experimental aortic aneurysms: Synchrony of induction of endogenous proteinases with matrix destruction and inflammatory cell response. J Vasc Surg 20: 51-60, 1994.
9. Marinov GR, Marois Y, Pâris E, Roby P, Formichi M, Douville Y and Guidoin R: Can the infusion of elastase in the abdominal aorta of the Yucatán miniature swine consistently produce experimental aneurysms? J Invest Surg 10: 129-150, 1997.
10. Zhu JX, Tang QQ, Zhou C, Shi XC, Yi SY and Yang Y: Establishment of a new abdominal aortic aneurysm model in rats by a retroperitoneal approach. Front Cardiovasc Med 9: 808732, 2022.
11. Li MW, Mian MO, Barhoumi T, Rehman A, Mann K, Paradis P and Schiffrin EL: Endothelin-1 overexpression exacerbates atherosclerosis and induces aortic aneurysms in apolipoprotein E knockout mice. Arterioscler Thromb Vasc Biol 33: 2306-2315, 2013.
12. Lin PY, Wu YT, Lin GC, Shih YH, Sampilvanjil A, Chen LR, Yang YJ, Wu HL and Jiang MJ: Coarctation-induced degenerative abdominal aortic aneurysm in a porcine model. J Vasc Surg 57: 806-815.e1, 2013.
13. Czerski A, Bujok J, Gnus J, Hauzer W, Ratajczak K, Nowak M, Janeczek M, Zawadzki W, Witkiewicz W and Rusiecka A: Experimental methods of abdominal aortic aneurysm creation in swine as a large animal model. J Physiol Pharmacol 64: 185-192, 2013.
14. Quintana RA and Taylor WR: Cellular mechanisms of aortic aneurysm formation. Circ Res 124: 607-618, 2019.
15. Takagi H and Umemoto T; ALICE (All-Literature Investigation of Cardiovascular Evidence) Group: Association of hypertension with abdominal aortic aneurysm expansion. Ann Vasc Surg 39: 74-89, 2017.
16. Gao J, Cao H, Hu G, Wu Y, Xu Y, Cui H, Lu HS and Zheng L: The mechanism and therapy of aortic aneurysms. Signal Transduct Target Ther 8: 55, 2023.
17. Bi Y, Zhong H, Xu K, Zhang Z, Qi X, Xia Y and Ren L: Development of a novel rabbit model of abdominal aortic aneurysm via a combination of periaortic calcium chloride and elastase incubation. PLoS One 8: e68476, 2013.
18. Ghoshal S and Loftin CD: Cyclooxygenase-2 inhibition attenuates abdominal aortic aneurysm progression in hyperlipidemic mice. PLoS One 7: e44369, 2012.
19. Riber SS, Ali M, Bergseth SH, Stubbe J, Stenger M, Behr-Rasmussen C and Lindholt JS: Induction of autoimmune abdominal aortic aneurysm in pigs-A novel large animal model. Ann Med Surg (Lond) 20: 26-31, 2017.
20. Maynar M, Qian Z, Hernandez J, Sun F, DeMiguel C, Crisostomo V, Usón J, Pineda LF, Espinoza CG and Castañeda WR: An animal model of abdominal aortic aneurysm created with peritoneal patch: Technique and initial results. Cardiovasc Intervent Radiol 26: 168-176, 2003.
21. Verbrugghe P, Verhoeven J, Clijsters M, Vervoort D, Coudyzer W, Verbeken E, Meuris B and Herijgers P: Creation of abdominal aortic aneurysms in sheep by extrapolation of rodent models: Is it feasible? Ann Vasc Surg 52: 225-236, 2018.

Copyright © 2024 Kim et al. This work is licensed under a Creative Commons Attribution-NonCommercial-NoDerivatives 4.0 International (CC BY-NC-ND 4.0) License.