Acute myocardial infarction due to spontaneous coronary artery dissection in a young male with systemic lupus erythematosus: A case report

YUNYI LI, QUAN ZHOU and XIAO MENG

The Key Laboratory of Cardiovascular Remodeling and Function Research, Chinese Ministry of Education, Chinese National Health Commission and Chinese Academy of Medical Sciences, The State and Shandong Province Joint Key Laboratory of Translational Cardiovascular Medicine, Department of Cardiology, Qilu Hospital, Cheeloo College of Medicine, Shandong University, Jinan, Shandong 250012, P.R. China

Received October 21, 2023; Accepted February 20, 2024

DOI: 10.3892/etm.2024.12534

Abstract. Systemic lupus erythematosus (SLE) is an autoimmune disease which typically presents in young women. Patients with SLE exhibit features of accelerated atherosclerosis. Here, the present study reported a rare case of acute myocardial infarction (AMI) in a male patient diagnosed with SLE. A 29-year-old male with no cardiovascular history was diagnosed with AMI and underwent coronary angiography, which showed a long-extended spiral-shaped dissection of the right coronary artery (RCA). The patient's autoimmune panel tested positive for antinuclear, anti-nuclear ribonucleoprotein/Smith and anti-Sjogren's syndrome A antibodies. The patient was diagnosed with SLE and was administered prednisone, hydroxychloroquine and calcium carbonate therapy. At the 3-month follow-up, a repeat coronary angiography showed no dissection in the RCA. Intravascular ultrasound and optical coherence tomography also showed an isolated atherosclerotic lesion without arterial dissection in the RCA. To the best of our knowledge, this is the first reported case of a male patient with SLE who developed myocardial infarction caused by spontaneous coronary artery dissection (SCAD). The present report may provide new insights into possible future treatments for SCAD. SCAD should be considered in patients with SLE and AMI, particularly in young patients without cardiovascular risk factors. Early diagnosis of SCAD is important to provide accurate therapy that differs from the treatment of AMI caused by atherosclerosis.

Correspondence to: Dr Xiao Meng, The Key Laboratory of Cardiovascular Remodeling and Function Research, Chinese Ministry of Education, Chinese National Health Commission and Chinese Academy of Medical Sciences, The State and Shandong Province Joint Key Laboratory of Translational Cardiovascular Medicine, Department of Cardiology, Qilu Hospital, Cheeloo College of Medicine, Shandong University, 107 Wen Hua Xi Road, Jinan, Shandong 250012, P.R. China
E-mail: mx81fly@163.com

Abbreviations: AMI, acute myocardial infarction; CAD, coronary artery disease; CVD, cardiovascular disease; IVUS, intravascular ultrasound; LAD, left anterior descending; OCT, optical coherence tomography; PCI, percutaneous coronary intervention; RCA, right coronary artery; SCAD, spontaneous CAD; SLE, systemic lupus erythematosus

Key words: coronary artery disease, acute myocardial infarction, coronary artery dissection, systemic lupus erythematosus

Introduction

Systemic lupus erythematosus (SLE) is an autoimmune disease of unknown etiology, characterized by systemic inflammation and clinical heterogeneity, which typically presents in young women of childbearing age (20-40 years old) (1). It can affect almost all organ systems, with clinical manifestations ranging from skin involvement to multisystem organ failure (1,2). The heart is one of the most commonly affected organs in SLE. Cardiovascular complications of SLE include pericarditis, myocarditis, cardiomyopathy, endocarditis, heart block and coronary artery disease (CAD) (3). Cardiovascular disease (CVD) is the leading cause of morbidity and mortality in patients with SLE (4). Patients with SLE exhibit features of accelerated atherosclerosis and an increased risk of CAD that can be clinically silent in the initial stages, or angina or acute myocardial infarction (AMI) during disease progression (5). It has been reported that the risk of developing AMI is 2.67-10.00 times higher among patients with SLE compared with individuals without SLE (6).

Women, especially young women, are more susceptible to SLE compared with men (7). However, male and female patients with SLE have different clinical profiles and outcomes. Studies have reported that male patients are more likely to experience cardiovascular and renal complications and have higher mortality rates compared with female patients (8-10). Males with SLE have been reported to have a higher prevalence of CAD and myocardial infarction and poorer outcomes (9,11). To date, few studies have investigated the cause of CAD in male patients with SLE. Herein, the

present study reported a rare case of AMI in a male patient diagnosed with SLE.

Case report

A 29-year-old male with no previous cardiovascular history was admitted to Qilu Hospital of Shandong University (Jinan, China) in June 2019 with intermittent strangulation and crushing of the chest for ~10 days. Accompanying symptoms included shoulder and back pain, odynophagia and toothache. There was no history of trauma, cough, fever, syncope or palpitations. The patient was a nonsmoker with normal lipid levels. Physical examination showed that the patient had no obvious positive signs of other acute or chronic diseases. An electrocardiogram exhibited ST-T abnormalities, including abnormal Q waves and a slight ST elevation in the inferior (II, III and aVF) limb leads (Fig. 1A). The patient's blood pressure was 133/85 mmHg and serum cardiac troponin T level was 0.517 ng/ml (normal range, 0.000-0.014 ng/ml). The left ventricular ejection fraction, assessed using echocardiography, was 59%. The patient was diagnosed with acute inferior myocardial infarction. After the patient was admitted, their symptoms were relieved. Therefore, emergency coronary angiography was not performed. During hospitalization, the patient received medications, including aspirin (100 mg/day), clopidogrel (75 mg/day), rosuvastatin (20 mg/day), metoprolol succinate (47.5 mg/day) and low-molecular-weight heparin (5,000 IU) twice daily. At 5 days post-admission, the patient underwent coronary angiography, which showed a long, extended, spiral-shaped dissection of the right coronary artery (RCA) (Fig. 1B and 1C). No significant stenosis was observed in the left main artery, left anterior descending (LAD) artery or left circumflex artery.

The treatment of spontaneous coronary artery dissection (SCAD) with percutaneous coronary intervention (PCI) is associated with high rates of technical failure related to passage of coronary wire into the false lumen of the dissected vessel or loss of coronary flow through propagation of dissection, and complications. In a previous retrospective study of 189 patients with SCAD, the PCI failure rate was 53% (12). Conservative therapy (nonoperative treatment) is preferred for patients with SCAD (12). Considering the young age and absence of atherosclerosis risk in the present patient, a coronary stent was not implanted and the possible etiologies were investigated. A detailed medical history and examination was performed and laboratory tests showed an increased erythrocyte sedimentation rate of 36.00 mm/h (normal range, 0.00-15.00 mm/h). Immunological testing was performed and the autoimmune panel was positive for antinuclear (titer, 1/1280), anti-nuclear ribonucleoprotein/Smith and anti-Sjogren's syndrome A antibodies. The patient was diagnosed with SLE and was administered prednisone (50 mg/day), hydroxychloroquine (200 mg/twice daily) and calcium carbonate (600 mg/day). The patient remained stable and asymptomatic during treatment in the following 3 months.

In September 2019, a coronary angiography was repeated and showed no dissection of the RCA (Fig. 2A and B). Intravascular ultrasound (IVUS) and optical coherence tomography (OCT) were performed to evaluate the morphology of the lumen and vessel walls. These tests showed an isolated atherosclerotic lesion without arterial dissection in the RCA (Fig. 2C-H). During drug treatment, the patient experienced no further episodes of intermittent chest strangulation or squeezing. In conjunction with the clinical manifestations and coronary angiography, clopidogrel was discontinued and the prednisone dose was reduced to 30 mg/day. Calcium carbonate (600 mg/day) treatment was continued to prevent osteoporosis and osteopenia.

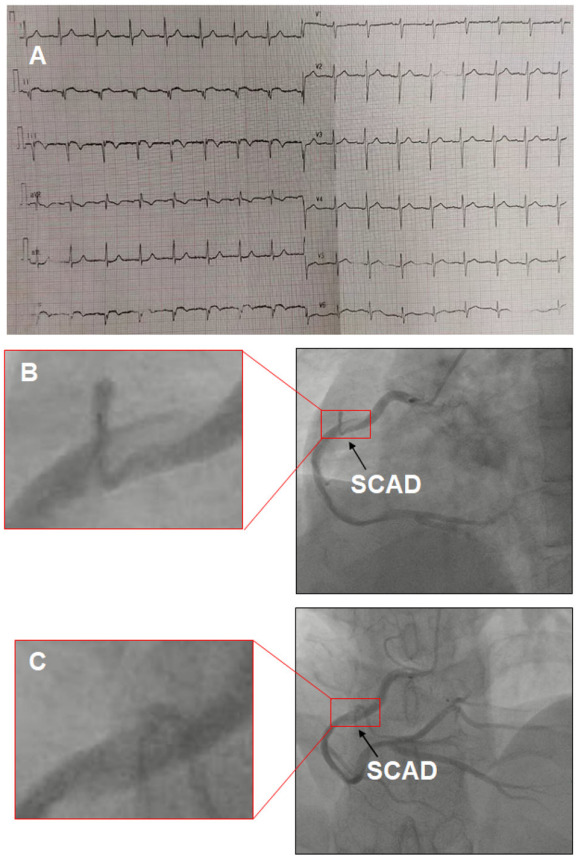

Figure 1. Results of electrocardiograms and baseline coronary angiogram. (A), Electrocardiogram exhibited abnormal Q waves and slightly ST elevation in inferior (II, III and aVF) limb leads. (B and C) Coronary angiogram showed a dissection of spiral shape in the right coronary artery. SCAD, spontaneous coronary artery dissection.

After September 2019, the patient visited the hospital every 3 months for follow-up. No other chest pain symptoms were observed during follow-up. In December 2023, no major complications of AMI or SLE had occurred. The patient was able to perform daily activities normally under continuous long-term drug therapy with hydroxychloroquine (200 mg/twice daily) and prednisone (5 mg/day). The prognosis of the patient for SCAD is considered to be favorable; however, the condition of SLE requires long-term evaluation of clinical follow-up. In order to evaluate the condition of the patient and adjust the medication according to the condition, the patient has been asked to visit the Rheumatology Department of Qilu Hospital every 3-6 months.

Discussion

SLE is associated with an increased prevalence of CAD. The most common cause of CAD in patients with SLE is premature coronary atherosclerosis, independent of traditional risk

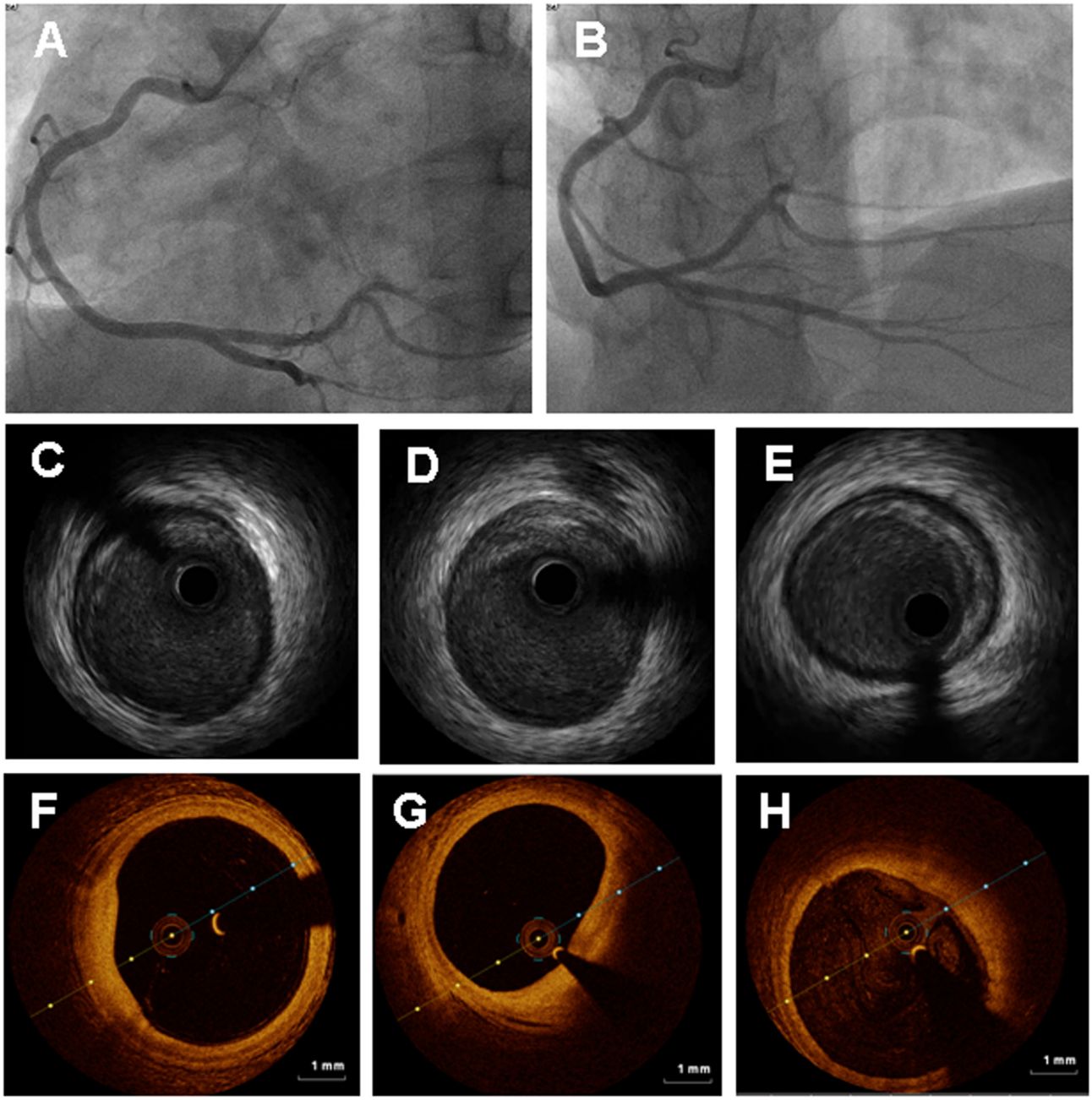

Figure 2. Results of the repeated coronary angiogram. (A) Coronary angiogram (left anterior oblique view) showed no dissection in the RCA. (B) Coronary angiogram (anteroposterior view) showed no dissection in the RCA. Intravascular ultrasound showed an isolated atherosclerotic lesion without arterial dissection in the RCA with the (C) proximal entry of SCAD, (D) middle of SCAD and (E) distal outlet of SCAD. Optical coherence tomography showed an isolated atherosclerotic lesion without arterial dissection in the RCA with the (F) proximal entry of SCAD, (G) middle of SCAD and (H) distal outlet of SCAD. RCA, right coronary artery; SCAD, spontaneous coronary artery dissection.

factors, such as hypercholesterolemia, smoking and hypertension, for cardiovascular disease (13). SCAD is an uncommon condition that causes sudden coronary artery occlusion and AMI, and SCAD is responsible for 1-4% of AMI cases as the underlying cause (14,15). The cause of SCAD remains unclear and may be associated with patient vulnerability, emotional and physical stress, use of stimulant medications or illicit drugs and hormonal triggers (16). It has previously been reported that there may be an association between SCAD and systemic inflammatory disorders, including SLE (14). To the best of our knowledge, the present study is the first reported case of a male diagnosed with SLE who presented with an AMI secondary to SCAD. Furthermore, the present patient exhibited no other symptoms of SLE and AMI was the primary presentation.

However, there are few reports on the prevalence of SCAD caused by SLE (17-28). Chest pain was the most common symptom and was the first manifestation in two of the aforementioned cases (21,25). Notably, only two cases involving male patients have been reported (19,26). A young male developed persistent chest tightness ~4 years after the diagnosis of SLE and coronary angiography revealed a long dissection, as well as the presence of a thrombus shadow originating from the diagonal branch of the LAD (19). Huang *et al* (19) reported that a young male was hospitalized several times for acute

pericarditis, acute pleurisy, myocarditis, coronary arteritis and lupus nephritis. Based on a comprehensive assessment of the aforementioned patient's condition, a stent was implanted in the LAD lesion to prevent further development of coronary dissection. In another case, a young adolescent with SLE was reported as having SCAD (26). However, the study did not provide a detailed report of this case.

SLE is a chronic autoimmune inflammatory disease affecting multiple organs. Cardiac involvement is a major cause of morbidity and mortality in patients with SLE (3). SLE accelerates the formation of atherosclerotic plaques, with or without the presence of traditional cardiac risk factors (29). Endothelial dysfunction is the initial step in atherosclerosis and previous studies have reported that vascular damage is accelerated in patients with SLE and vascular repair mechanisms are ineffective (29,30). On the one hand, the inflammatory response caused by SLE directly damages the vascular endothelium. By contrast, antibodies such as antiphospholipid, anti-oxidized low-density lipoprotein, anti-apolipoprotein A-I and anti-double-stranded DNA can mediate endothelial cell damage, which increases lipid deposition (31). In addition, studies have reported that certain cytokines, such as IFN-α (32), INF-γ, TNF-α (33) and IL-17 (34) can promote the development of atherosclerosis.

SCAD is a rare cause of AMI. SCAD is characterized by the rupture of the coronary intima and the formation of an intramural hematoma, which leads to obstruction of the coronary artery lumen and myocardial infarction (35). A number of mechanisms have been proposed to explain the primary events of SCAD. The first states that the primary event is the rupture of the intima of the coronary artery, while the second states that there is spontaneous hemorrhage originating from the vasa vasorum within the vessel wall (36,37). Patients with SLE less frequently exhibit traditional cardiovascular risk factors; however, coronary disease in this population is deemed a cumulative outcome of vasculitis, persistent vessel wall inflammation and an elevated susceptibility to atherosclerosis (38). A previous report suggested that specific proteases, such as tryptase and chymase, may promote arterial dissection and thrombosis (39). In addition, the presence of antiphospholipid antibodies (aPL) in patients with SCAD-SLE has been reported in two cases, whereas data on the role of aPL in promoting coronary artery disease in humans are inconsistent (21,40). Therefore, more in-depth basic research investigating the role of aPL in SCAD-SLE is required.

In the present report, the patient was diagnosed with AMI and a coronary angiography showed a spiral dissection of the RCA. The patient was 29 years of age with no history of traditional cardiovascular risk factors. Therefore, a coronary drug-eluting stent was not placed in the patient. Immunological tests showed the presence of antibodies against SLE, which indicated a diagnosis of SLE. Corticosteroids are used for the treatment of SLE and they may control vascular inflammation of the coronary arteries caused by SLE (41). There may be an association between SCAD and systemic inflammatory disorders and, conversely, inflammation may be involved in SCAD (16). Anti-inflammatory treatment may be effective in patients with SCAD, especially those with inflammation-related SCAD phenotypes, by promoting the healing of arterial dissections (42).

In the present study, following a corticosteroid and standard medication treatment regime for AMI for 3 months, the coronary artery dissection of the RCA was resolved as demonstrated by coronary angiography. IVUS and OCT further confirmed these results. To the best of our knowledge, no study has adequately reported the intravascular imaging characteristics of the coronary arteries in patients with SLE and SCAD to date.

To the best of our knowledge, this is the first report on SLE-related SCAD. SCAD should be considered in patients with SLE and AMI, particularly in young patients without cardiovascular risk factors. Coronary angiography should be performed immediately and appropriate medical treatment should be initiated. Clinical follow-up by specialist physicians should be recommended. Considering that cardiovascular events may be clinically silent during the initial stages of SLE, further studies are required to explore the associations between SLE, AMI and SCAD. Early diagnosis of SCAD is important for providing an appropriate therapy, which differs from that for AMI caused by atherosclerosis.

Acknowledgements

Not applicable.

Funding

The present study was supported by the grants of the National Natural Science Foundation of China (grant no. 81970319) and the Taishan Scholars Program of Shandong Province (grant no. tsqn202103170).

Availability of data and materials

The data generated in the present study may be requested from the corresponding author.

Authors' contributions

YL designed the study, analyzed and interpreted the clinical data and patient symptoms after coronary angiography and drafted the manuscript. QZ performed the clinical data aggregate review. XM was responsible for the supervision, funding and critical review. YL and XM confirm the authenticity of all the raw data. All authors read and approved the final version of the manuscript.

Ethics approval and consent to participate

The present study was approved by the Ethics Committees of Qilu Hospital of Shandong University (Jinan, China; approval no. 2021155).

Patient consent for publication

Written informed consent for publication of the clinical details and images was obtained from the patient.

Competing interests

The authors declare that they have no competing interests.

References

1. Kiriakidou M and Ching CL: Systemic lupus erythematosus. Ann Intern Med 172: ITC81-ITC96, 2020.
2. Smith PP and Gordon C: Systemic lupus erythematosus: Clinical presentations. Autoimmun Rev 10: 43-45, 2010.
3. Miner JJ and Kim AH: Cardiac manifestations of systemic lupus erythematosus. Rheum Dis Clin North Am 40: 51-60, 2014.
4. Zen M, Salmaso L, Amidei CB, Fedeli U, Bellio S, Iaccarino L, Doria A and Saia M: Mortality and causes of death in systemic lupus erythematosus over the last decade: Data from a large population-based study. Eur J Intern Med 112: 45-51, 2023.
5. Zafar A, Mohib A, Syed H and Kumar S: Role of cardiologists in the management of systemic lupus erythematosus: First reported case of three-vessel disease in a young woman in Pakistan. Cureus 11: e5096, 2019.
6. Wells DK and Ward MM: Nephritis and the risk of acute myocardial infarction in patients with systemic lupus erythematosus. Clin Exp Rheumatol 28: 223-229, 2010.
7. Tian J, Zhang D, Yao X, Huang Y and Lu Q: Global epidemiology of systemic lupus erythematosus: A comprehensive systematic analysis and modelling study. Ann Rheum Dis 82: 351-356, 2023.
8. Frutos AR, Casas I, Rúa-Figueroa I, López-Longo FJ, Calvo-Alén J, Galindo M, Fernández-Nebro A, Pego-Reigosa JM and Marqués AO; RELESSER Group, part of the Spanish Society of Rheumatology Systemic Autoimmune Diseases Study Group (EASSER): Systemic lupus erythematosus in Spanish males: A study of the Spanish rheumatology society lupus registry (RELESSER) cohort. Lupus 26: 698-706, 2017.
9. Mihailovic J, Ribi C, Chizzolini C, Trendelenburg M, Von Kempis J, Dahdal S and Huynh-Do U; Swiss Systemic Lupus Erythematosus Cohort Study Group (SSCS): Worse cardiovascular and renal outcome in male SLE patients. Sci Rep 13: 18628, 2023.
10. Lai CC, Sun YS, Chen WS, Liao HT, Chen MH, Tsai CY, Huang DF, Chou CT and Chang DM: Risk factors for mortality in systemic lupus erythematosus patients: Analysis of adult and pediatric cohorts in Taiwan. J Chin Med Assoc 85: 1044-1050, 2022.
11. Vavlukis M, Pop-Gjorcevab D, Poposka L, Sandevska E and Kedev S: Myocardial infarction in systemic lupus erythematosus-the sex-specific risk profile. Curr Pharm Des 27: 3221-3228, 2021.
12. Tweet MS, Eleid MF, Best PJ, Lennon RJ, Lerman A, Rihal CS, Holmes DR Jr, Hayes SN and Gulati R: Spontaneous coronary artery dissection: Revascularization versus conservative therapy. Circ Cardiovasc Interv 7: 777-786, 2014.
13. Asanuma Y, Oeser A, Shintani AK, Turner E, Olsen N, Fazio S, Linton MF, Raggi P and Stein CM: Premature coronary-artery atherosclerosis in systemic lupus erythematosus. N Engl J Med 349: 2407-2415, 2003.
14. Mahmoud AN, Taduru SS, Mentias A, Mahtta D, Barakat AF, Saad M, Elgendy AY, Mojadidi MK, Omer M, Abuzaid A, *et al*: Trends of incidence, clinical presentation, and in-hospital mortality among women with acute myocardial infarction with or without spontaneous coronary artery dissection: A population-based analysis. JACC Cardiovasc Interv 11: 80-90, 2018.
15. Tweet MS, Hayes SN, Pitta SR, Simari RD, Lerman A, Lennon RJ, Gersh BJ, Khambatta S, Best PJ, Rihal CS and Gulati R: Clinical features, management, and prognosis of spontaneous coronary artery dissection. Circulation 126: 579-588, 2012.
16. Kim ESH: Spontaneous coronary-artery dissection. N Engl J Med 383: 2358-2370, 2020.
17. Álvarez-Lario B, Álvarez-Roy L, Mayordomo-Gómez S and García-García JM: Spontaneous coronary artery dissection in systemic lupus erythematosus: Case-based review. Rheumatol Int 39: 1821-1827, 2019.
18. Chaaban N and Kshatriya S: Spontaneous coronary artery dissection with systemic lupus erythematosus. Ochsner J 22: 353-355, 2022.
19. Huang H, Ma X, Xu L, Wang X, Shi D, Zhao F and Zhang Y: Spontaneous coronary artery dissection and atherosclerosis in a young man with systemic lupus erythematosus: A case report and literature review. Front Cardiovasc Med 9: 951188, 2022.
20. Kumanayaka DD, Hernandez I, Ahmad A and Suleiman A: Systemic lupus erythematous associated with multi-vessel spontaneous coronary artery dissection. Global Cardiol Sci Pract 2023: e202324, 2023.
21. Reddy S, Vaid T, Sanjeeva NC and Shetty RK: Spontaneous coronary artery dissection as the first presentation of systemic lupus erythematosus. BMJ Case Rep 24: bcr2016216344, 2016.
22. Patel R, Patel R, Rahming H, Tian J and Kandov R: Spontaneous coronary artery disease (SCAD) in a patient with systemic lupus erythematosus (SLE). Cureus 15: e43061, 2023.
23. Rekik S, Lanfranchi P, Jacq L and Bernasconi F: Spontaneous coronary artery dissection in a 35 year-old woman with systemic lupus erythematosus successfully treated by angioplasty. Heart Lung Circ 22: 955-958, 2013.
24. Besinger BR and Gardner S: Spontaneous coronary artery dissection in a 27-year-old woman. J Emerg Med 44: e239-e242, 2013.
25. Aldoboni AH, Hamza EA, Majdi K, Ngibzadhe M, Palasaidi S and Moayed DA: Spontaneous dissection of coronary artery treated by primary stenting as the first presentation of systemic lupus erythematosus. J Invasive Cardiol 14: 694-696, 2002.
26. Kothari D, Ruygrok P, Gentles T and Occleshaw C: Spontaneous coronary artery dissection in an adolescent man with systemic lupus erythematosus. Intern Med J 37: 342-343, 2007.
27. García-Sánchez M, Carrillo J, Montero Y and Seniscal D: Spontaneous coronary dissection associated with systemic lupus erythematosus. Archivos de cardiologia de Mexico 91: 114-120, 2020.
28. Sharma AK, Farb A, Maniar P, Ajani AE, Castagna M, Virmani R, Suddath W and Lindsay J: Spontaneous coronary artery dissection in a patient with systemic lupus erythematosis. Hawaii Med J 62: 248-253, 2003.
29. Skaggs BJ, Hahn BH and McMahon M: Accelerated atherosclerosis in patients with SLE-mechanisms and management. Nat Rev Rheumatol 8: 214-223, 2012.
30. Rajagopalan S, Somers EC, Brook RD, Kehrer C, Pfenninger D, Lewis E, Chakrabarti A, Richardson BC, Shelden E, McCune WJ and Kaplan MJ: Endothelial cell apoptosis in systemic lupus erythematosus: A common pathway for abnormal vascular function and thrombosis propensity. Blood 103: 3677-3683,2004.
31. Wigren M, Nilsson J and Kaplan MJ: Pathogenic immunity in systemic lupus erythematosus and atherosclerosis: Common mechanisms and possible targets for intervention. J Intern Med 278: 494-506, 2015.
32. Buie JJ, Renaud LL, Muise-Helmericks R and Oates JC: IFN-α negatively regulates the expression of endothelial nitric oxide synthase and nitric oxide production: Implications for systemic lupus erythematosus. J Immunol 199: 1979-1988, 2017.
33. Rho YH, Chung CP, Oeser A, Solus J, Raggi P, Gebretsadik T, Shintani A and Stein CM: Novel cardiovascular risk factors in premature coronary atherosclerosis associated with systemic lupus erythematosus. J Rheumatol 35: 1789-1794, 2008.
34. von Vietinghoff S, Koltsova EK, Mestas J, Diehl CJ, Witztum JL and Ley K: Mycophenolate mofetil decreases atherosclerotic lesion size by depression of aortic T-lymphocyte and interleukin-17-mediated macrophage accumulation. J Am Coll Cardiol 57: 2194-2204, 2011.
35. Hayes SN, Kim ESH, Saw J, Adlam D, Arslanian-Engoren C, Economy KE, Ganesh SK, Gulati R, Lindsay ME, Mieres JH, *et al*: Spontaneous coronary artery dissection: Current state of the science: A scientific statement from the American heart association. Circulation 137: e523-e557, 2018.
36. Saw J, Mancini GB, Humphries K, Fung A, Boone R, Starovoytov A and Aymong E: Angiographic appearance of spontaneous coronary artery dissection with intramural hematoma proven on intracoronary imaging. Catheter Cardiovasc Interv 87: E54-E61, 2016.
37. Kwon TG, Gulati R, Matsuzawa Y, Aoki T, Guddeti RR, Herrmann J, Lennon RJ, Ritman EL, Lerman LO and Lerman A: Proliferation of coronary adventitial vasa vasorum in patients with spontaneous coronary artery dissection. JACC Cardiovasc Imaging 9: 891-892, 2016.
38. Karrar A, Sequeira W and Block JA: Coronary artery disease in systemic lupus erythematosus: A review of the literature. Semin Arthritis Rheum 30: 436-443, 2001.
39. Kounis NG, Koniari I, Velissaris D, Soufras G and Hahalis G: Aortic aneurysm and dissection in systemic lupus erythematosus-pathophysiologic and therapeutic considerations. Eur J Rheumatol 5: 209-211, 2018.
40. Nisar MK and Mya T: Spontaneous coronary artery dissection in the context of positive anticardiolipin antibodies and clinically undiagnosed systemic lupus erythematosus. Lupus 20: 1436-1438, 2011.
41. Chuang YW, Yu MC, Lin CL, Yu TM, Shu KH and Kao CH: Risk of peripheral arterial occlusive disease in patients with systemic lupus erythematosus: A nationwide population-based cohort study. Medicine (Baltimore) 94: e2121, 2015.
42. Krittanawong C, Saw J and Olin JW: Updates in spontaneous coronary artery dissection. Curr Cardiol Rep 22: 123, 2020.