INTERNATIONAL JOURNAL OF MOLECULAR MEDICINE 25: 353-359, 2010

SPANDIDOS PUBLICATIONS

Abnormal distribution of sarcoglycan subcomplex in colonic smooth muscle cells of aganglionic bowel

SALVATORE ARENA[1], GIUSEPPINA CUTRONEO[2], ANGELO FAVALORO[2], MARIA TERESA SINATRA[1], FABIO TRIMARCHI[2], SILVIA SCARVAGLIERI[1], AGOSTINO MALLAMACE[3], FRANCESCO ARENA[4], GIUSEPPE ANASTASI[2] and VINCENZO DI BENEDETTO[1]

[1]Department of Pediatric Surgery, Unit of Pediatric Surgery, University of Catania, Vittorio Emanuele Hospital, Via Plebiscito, n. 628, 95124 Catania; Departments of [2]Biomorphology and Biotechnologies, [3]Clinical-Experimental of Medicine and Pharmacology, University of Messina, Policlinico 'G. Martino', Torre Biologica, Viale Gazzi, 98125 Messina; [4]Department of Medical and Surgical Pediatric Surgery, Unit of Pediatric Surgery, University of Messina, Policlinico 'G. Martino', Pad. NI, Viale Gazzi, 98125 Messina, Italy

Received September 2, 2009; Accepted October 27, 2009

DOI: 10.3892/ijmm_00000352

Abstract. Hirschsprung's disease (HD) is a development disorder of the enteric nervous system in which the altered innervation explains the inability of the aganglionic segment to relax. Impairment of cytoskeleton in SMC of aganglionic bowel has been shown. Sarcoglycan subcomplex (SG) may support the development and maintenance of muscle cells. We examined the SG subunit expression in colonic aganglionic and ganglionic specimens obtained from patients with HD. Full-thickness bowel specimens were obtained from six patients with HD. Six normal colon specimens were used as controls. Immunofluorescent analysis and reverse transcriptase polymerase chain reaction evaluation were performed for α-, ß-, γ-, δ- and ε-SG. In control colon, the indirect immunofluorescence showed a strong staining pattern of ß- γ- δ- and ε-SG while a weak positivity of α-SG was recorded. In aganglionic bowel, immunofluorescence intensity values documented a significant lack of ε-SG while an enhanced α-SG, coupled to a loss of ε-SG, was recorded in ganglionic bowel in HD-affected patients. Our observations underscore the assumption that non-neuronal elements of the colon might play a key role in the pathogenesis of HD and loss of ε-SG might critically alter the cytoskeleton in the aganglionic bowel segment. Up-regulation of α-SG is probably an acquired phenomenon to reinforce the sarcolemma and to perform a forceful contraction in dilated ganglionic HD-affected colon, related to chronic pseudo-obstruction, contributing to the intestinal dysmotility that persists in 20% of patients after resection of the aganglionic bowel.

Correspondence to: Dr Angelo Favaloro, Department of Biomorphology and Biotechnologies, University of Messina, Policlinico 'G. Martino', Torre Biologica, Viale Gazzi, 98125 Messina, Italy
E-mail: angelo.favaloro@unime.it

Key words: Hirschsprung's disease, sarcoglycans, smooth muscle cells, aganglionic bowel

Introduction

Hirschsprung's disease (HD) is a development disorder of the enteric nervous system characterized by the absence of the ganglionic cells along a variable portion of the distal intestine. Physiologically, the altered innervation explains the inability of the aganglionic segment to relax and, as a consequence, it remains tonically constricted, generating a functional obstruction to the normal propulsion of the colonic content (1,2). Langer *et al* (3) focused on the influence of smooth muscle cells (SMC) on neural development adding neurons to the established primary cultures of SMC from specimens of normal and aganglionic bowel. They documented that neuronal development is impaired significantly during co-culture with aganglionic SMC (3) and normal maturation is inhibited in neurons cultured with SMC of aganglionic colon in comparison to normal colon (4).

Moreover, Nemeth *et al* showed an impairment of contractile apparatus and cytoskeleton in SMC of aganglionic bowel (5). In particular, Nemeth *et al* described a lack of desmin, an intermediate filament protein of SMC, vinculin, a functionally related protein of adherent junctions, and dystrophin (5) in intestinal aganglionic specimens. The latter is a plasma-membrane associated cytoskeletal protein of the spectrin superfamily and binds to sub-plasmalemmal actin filaments via its amino-terminal domain. The carboxy-terminus of dystrophin binds to a plasma membrane anchor, ß-dystroglycan, which is associated on the external side with the extracellular matrix receptor, α-dystroglycan, which binds to the basal lamina proteins, laminin 1, laminin 2 and agrin (6).

In the SMC, the dystroglycan complex (DGC) is associated with the sarcoglycan complex (SGC) (5-10), in order to provide a mechano-signalling connection from the cytoskeleton-to-extracellular matrix (ECM) in myocytes (11-14). SGC plays a key role at the membrane and it is crucial in maintaining

sarcolemma viability in muscle fiber membrane (12). Moreover, SGC may be important in maintaining proper calcium ion balance or may support the development and maintenance of muscle cells through signaling functions (15). The SGC consists of five transmembrane proteins: α-SG, type-1 transmembrane protein, with amino-terminus on the intracellular face of muscle cells specifically expressed in skeletal and cardiac muscle; ß-SG, a type-2 transmembrane protein that is abundant in cardiac and skeletal muscle; γ- and δ-SG, also type-2 glycosylated transmembrane protein, highly similar among themselves and to ß-SG (14); ε-SG, homologous to α-SG, a single-pass type I transmembrane protein with a short cytoplasmic tail containing three putative protein kinase phosphorylation site (16), associated with ß- and δ-SG in SMC (14).

It is reported that the integrity of SG complex seems to be essential for the viability of smooth muscle (11,14), so that the sarcoglycan subunity mutations or loss is accompanied by pathology (17-21).

Although numerous studies have been carried out on SGC in pathological smooth muscle, there are insufficient data on the role of these proteins in the cystoskeletal alterations of SMC in bowel of patients affected by HD.

Addressing this issue, we examined the SG subunits expression in colonic aganglionic and ganglionic specimens obtained from patients with HD, performing immunofluorescence and molecular investigations.

Materials and methods

Muscle biopsy samples. Full-thickness bowel specimens were obtained from six patients (age 4.8±5.4 years, ranged 4 months to 13 years) with HD who underwent pull-through procedure. The diagnosis of HD was performed preoperatively from rectal biopsies by acetylcholinesterase and α-naphthylesterase enzymo-histochemistry (Bio-Optica S.p.A, Milan, Italy, code 30-50110 and 30-50111). Six normal colon specimens of matched-aged subjects with no evidence of intestinal diseases and no history of constipation, were collected during organ explantation. The biopsy specimens were analysed using immunohistochemistry and RT-PCR technique. All patients gave their informed consent. The investigation conformed with the principles outlined in the Declaration of Helsinki.

Immunohistochemistry. Segments of intra-operative intestinal specimens were fixed in 3% paraformaldehyde in 0.2 M phosphate buffer at pH 7.4 for 2 h at room temperature. They were then washed extensively with 0.2 M phosphate buffer and phosphate-buffered, pH 7.4, and then with phosphate-buffered saline (PBS), containing 12% and 18% sucrose.

The samples were snap-frozen in liquid nitrogen and 20 μm sections were prepared in a cryostat for their use in a protocol to perform immunofluorescence. The sections were placed on glass slides that were coated with 0.5% gelatin and 0.005% chromium potassium sulphate.

To block non-specific sites and to permeabilize the membranes permeable, the sections were preincubated with 1% bovine serum albumin (BSA) and 0.3% Triton X-100 in PBS at room temperature for 15 min. Finally, the sections were incubated with primary antibodies for 15 min.

The following primary antibodies were used: anti-α-SG diluted 1:100, anti-ß-SG diluted 1:200, anti-γ-SG diluted 1:100, anti-δ-SG diluted 1:50 and anti-ε-SG diluted at 1:100 (all from Novocastra Laboratories, Newcastle upon Tyne, UK).

Primary antibodies were detected using Texas Red-conjugated IgG (Jackson ImmunoResearch Laboratories, Inc., West Grove, PA). Slides were finally washed in PBS and sealed with mounting medium.

The sections were then analysed and images acquired using a Zeiss LSM 5 META (Carl Zeiss; Jena, Germany) confocal laser scanning microscope. All images were digitized at a resolution of 8 bits into an array of 2048x2048 pixels. Optical sections of fluorescence specimens were obtained using HeNe laser (wavelength = 543 nm) and Ar laser (wavelength = 458 nm) at a 62-sec scanning speed with up to eight averages; 1.50-μm-thick sections were obtained using a pinhole of 250. For each reaction, at least 100 individual fibers were examined to obtain a statistical analysis.

Contrast and brightness were established by examining the most brightly labelled pixels and choosing setting that allowed clear visualization of the structural details while keeping the pixel intensity at its highest (~200). Each image was acquired within 62 sec, in order to minimize photodegradation.

The 'display profile' function f the laser scanning microscope was used to show the intensity profile across an image along a freely selectable line. The intensity curves are shown in a graph below the scanned image. Digital images were cropped and figure montages were prepared using Adobe Photoshop 10.0 (Adobe Systems, Palo Alto, CA).

Statistical analysis. Student's t-test was used to compare fluorescent intensity values (obtained using display profile mode) of each SG subunit (α-, ß-, γ-, δ-, ε-SG) in each group (control, aganglionic colon and ganglionic HD-affected colon). Quantitative values are expressed as the mean (Standard Deviation) and statistical significance was accepted at $p<0.05$.

RT-PCR. We collected tissue samples of human control and HD-affected intestinal specimens, evaluating the expression of α-, ß-, γ-, δ- and ε-SG in each of them by RT PCR.

Total RNA isolation. Each tissue sample (50-100 mg) was homogenized using a power homogenizer (Ultra Turrax IKA - Werke GmbH, Staufen, Germany). Total RNA was isolated by procedures based on the monophasic solution of phenol and guanidine isothiocyanate upon single-step RNA isolation (Trizol® Reagents, Invitrogen, Carlsbad, CA).

RT PCR analysis. The RT-PCR procedure was carried out using the two-step protocol (GeneAmp Gold RNA PCR reagent core kit, Applied Biosystems, Foster City, CA) in a thermal cycler (GeneAmp PCR System 9600 PE, Applied Biosystems).

In the first step, an initial reverse transcription reaction (RT) was carried out in 20-μl volume containing 3 μg of total RNA, 10 U RNase inhibitor, DTT 10 mM, 15 U Multiscribe Reverse Transcriptase and oligod(T) 16 1.25 μM under the

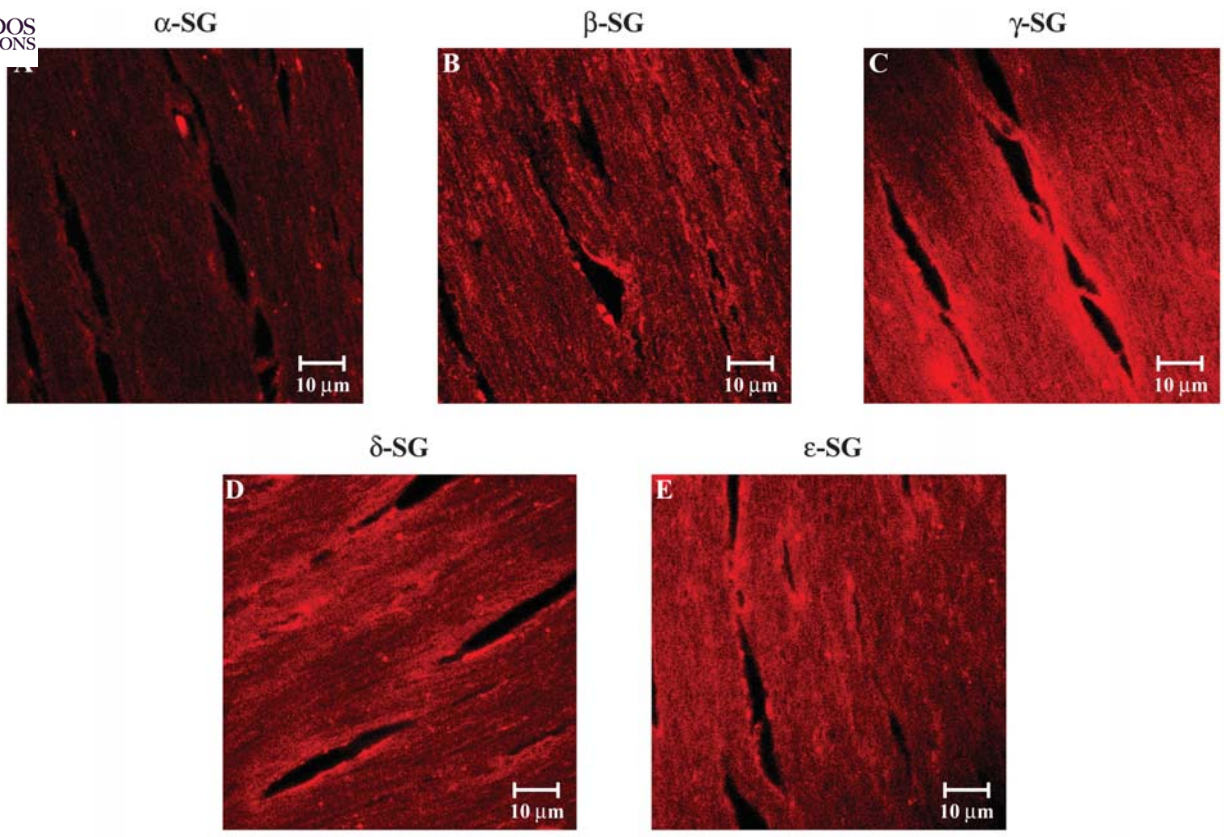

Figure 1. Compound panel of immunofluorescent findings in control colon of α- (A), ß- (B), γ- (C), δ- (D), and ε-SG (E). A strong staining pattern of ß-, γ-, δ-, and ε-sarcoglycan and a weak immunostaining for α-sarcoglycan was recorded.

following thermal cycler conditions: hold 10 min at 25˚C and 12 min at 42˚C.

In the second step, a further independent PCR was carried out in 50-μl volume containing 5 μl of cDNA of the first step (RT) as template, 2.5 U AmplTaq Gold DNA Polymerase and 0.2 μM of each primer designed by us of mRNA sequences.

DNA amplification was performed conventionally; each sample together with an internal control was subjected to 30 cycles of amplification (exponential phase of amplification) consisting of 30 sec of denaturation, 30 sec of annealing and 40 sec of extension. The final extension step at 72˚C was extended to 7 min. The annealing temperature was optimized for each primer set.

For each component of the SGC, human GADPH cDNA as internal control was used. The sequence of sarcoglycans was later confirmed by nucleotide sequencing analysis.

Nucleotide sequencing analysis. Amplified DNA was purified using a commercially available kit (GFX PCR DNA and Gel Band purification kit; Amersham Biosciences, Piscataway, NJ). The fragments extracted were directly sequenced with the primers used for the RT-PCR assay and labeled with the ABI PRISM Big Dye terminator cycle sequencing method, according to manufacturer's instructions, on a 377 ABI PRISM sequencer analyzer (Applied Biosystems). ABI sequencing Analysis 3.4.1 was used to process the raw sequence data and ABI Sequencing navigator to align sequenced data.

Results

In order to analyze the immunostaining patterns of SGs in our samples we performed immunofluorescence analysis of the human intestinal biopsies from control patients and from patients affected by HD.

A common feature of all SGs was their sarcolemmal expression. First, we analyzed the biopsy of the patients with no evidence of intestinal diseases. These control reactions showed a strong staining pattern of ß- γ- δ- and ε-SG (Fig. 1B-D) while a weak positivity of α-SG was recorded (Fig. 1A). Immunofluorescence results, obtained by 'display profile' function, showed that the value of fluorescence intensity, in control samples, was 36.94 (16.95) for α-SG and 115.90±30.21, 112.40±24.37, 116.25±29.40, 113.80±42.82, respectively for ß-, γ-, δ- and ε-SG. Student's t-test values are summarized in Table I.

Secondly, we performed immunostaining on intestinal specimens from patients with aganglionic and ganglionic-HD bowel. In patients with HD-aganglionic bowel, immunofluorescence analysis revealed that immunostaining of α-SG was slightly but not significantly increased (Fig. 2A), compared with that of the control, while the immunostaining of the ε-SG was severely reduced (Fig. 2E); other sarcoglycan subunits showed not significant modifications (Fig. 2B-D). Immunofluorescence intensity was 40.41±22.51, 116.75±17.30, 115.40±19.49, 118.51±24.39 and 4.73±4.44, respectively for α-, ß-, γ-, δ- and ε-SG. Student's t-test values are summarized in Table I.

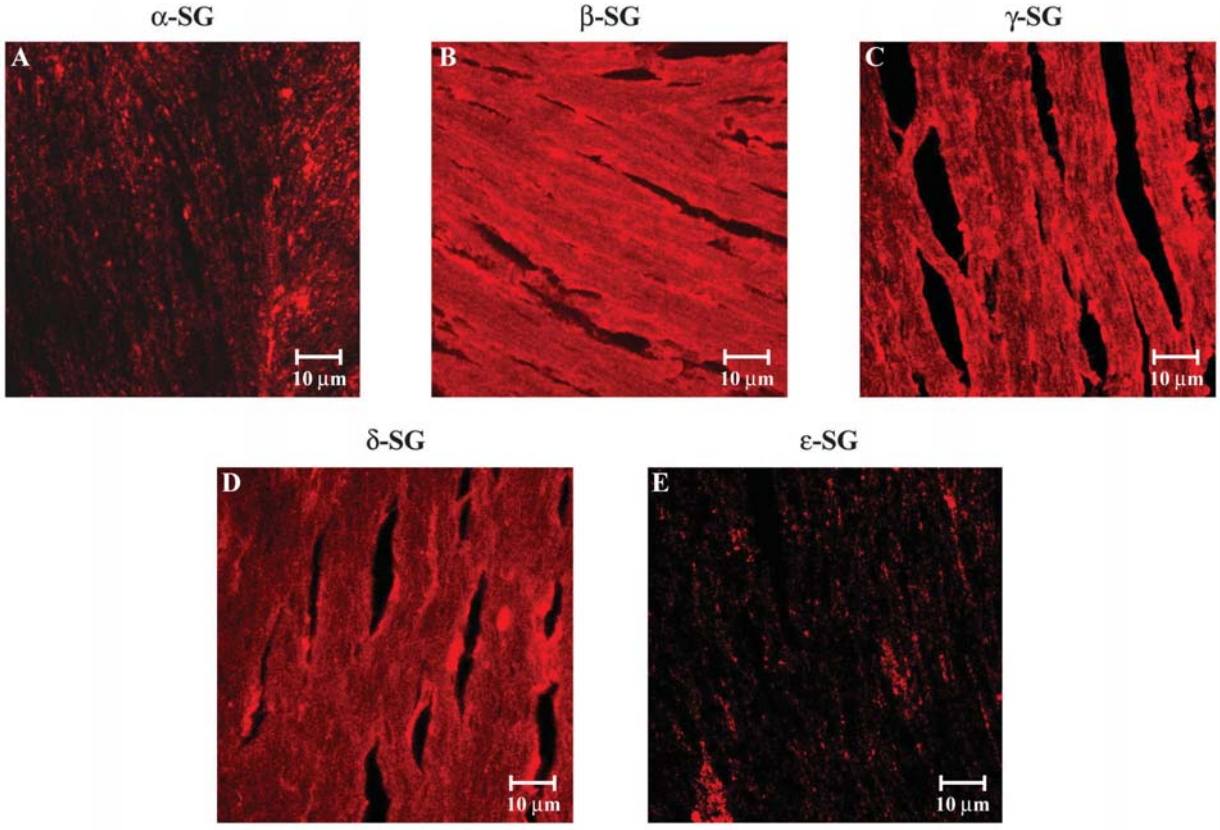

Figure 2. Compound panel of immunofluorescent findings in aganglionic colon of α- (A), ß- (B), γ- (C), δ- (D), and ε-SG (E). ß-, γ- and δ-SG showed a strong positivity. Immunostaining of α-SG was slightly but not significantly increased compared with the control while a significant loss of ε-SG was recorded.

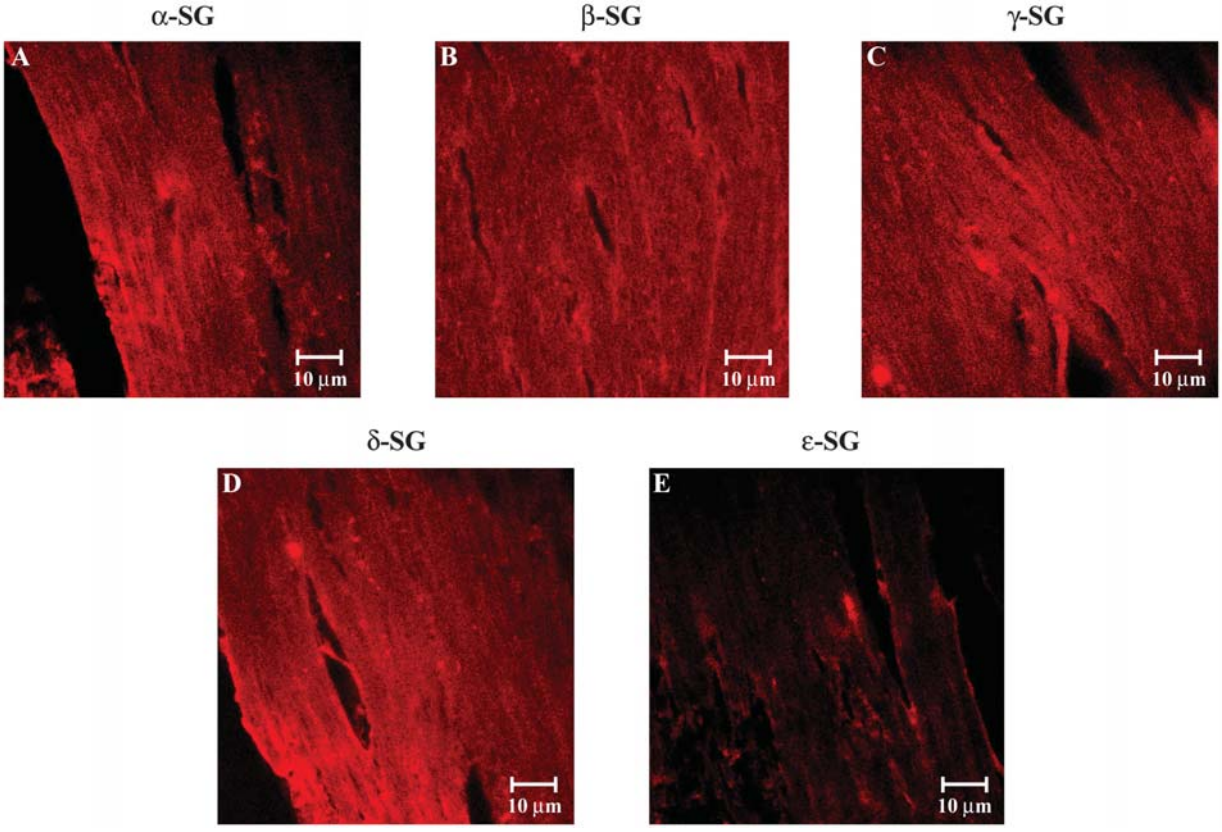

Figure 3. Compound panel of immunofluorescent findings in ganglionic colon of α- (A), ß- (B), γ- (C), δ- (D), and ε-SG (E), in patients affected by Hirschsprung's disease. A strong staining pattern of ß-, γ- and δ-SG was recorded. A loss of ε-SG, couplet to an enhancement of α-SG, was observed.

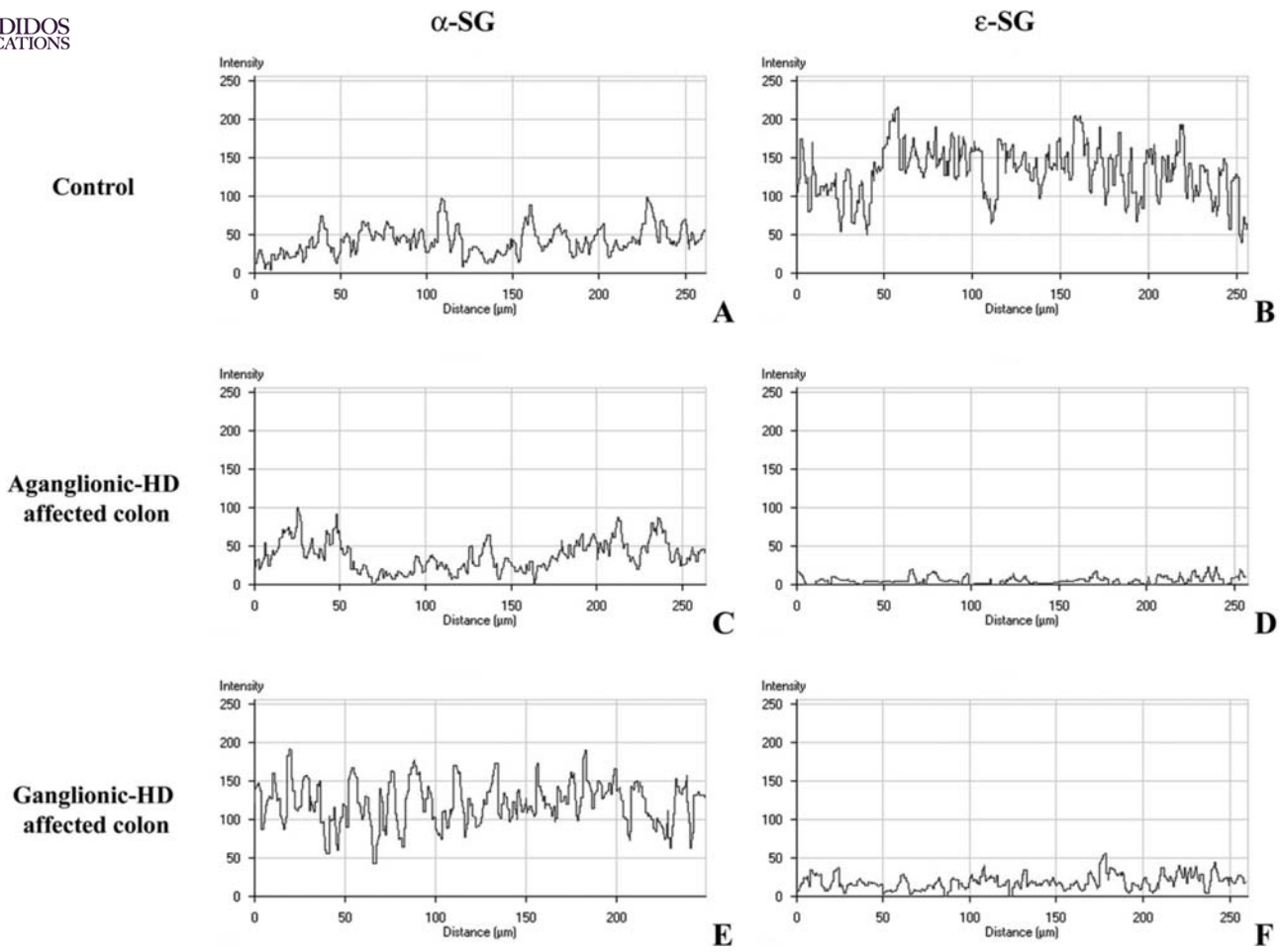

Figure 4. Display profiles showed lower peaks of fluorescence of α-SG (A) and clear peaks for ε-SG in control specimens (B), lower peaks of α-SG (C) and an almost absent peak for ε-SG (D) in aganglionic bowel and increased in magnitude peaks of α-SG (E) with low peaks ε-SG (F) in ganglionic HD-affected bowel.

In ganglionic-HD affected specimens, interestingly, immunofluorescence intensity of α-SG was increased (Fig. 3A), compared to control and to aganglionic-HD bowel; also the analysis of the immunostaining of α-SG revealed a decrease of this subunit (Fig. 3E). Other sarcoglycan subunits showed not significant modifications (Fig. 3B-D). Immunofluorescence was evaluated as 116.97±32.34, 116.01±16.39, 119.32±32.07, 118.35±19.35 and 14.78±8.27, respectively for α-, ß-, γ-, δ- and ε-SG (Fig. 3). Student's t-test values are summarized in Table I.

To confirm the protein staining patterns, we used the 'display profile' software function of the laser scanning microscope for selected samples. This additional analysis, which reveals the fluorescence intensity profile across an image along a freely selectable line, converted the immunofluorescence signal into a graph.

The display profiles of the control specimens showed lower peaks of fluorescence for α-SG (Fig. 4A) and clear peaks for α-SG (Fig. 4B). The profiles for α-SG in aganglionic-HD bowel showed lower peaks (Fig. 4C), while the peaks of α-SG, in same specimens, showed almost absent peaks (Fig. 4D). By applying this analysis to the intestinal samples taken from the patients with ganglionic-HD bowel, it was possible to show that the peaks of α-SG were increased in

Table I. Values obtained using Student's t-test.[a]

Control colon	ß	γ	δ	ε
α	<0.001	<0.001	<0.001	<0.001
ß	-	0.12 (NS)	0.92 (NS)	0.56 (NS)
γ	-	-	0.19 (NS)	0.66 (NS)
δ	-	-	-	0.60 (NS)
Aganglionic colon	**ß**	**γ**	**δ**	**ε**
α	<0.001	<0.001	<0.001	<0.001
ß	-	0.57 (NS)	0.60 (NS)	<0.001
γ	-	-	0.21 (NS)	<0.001
δ	-	-	-	<0.001
Ganglionic HD-affected colon	**ß**	**γ**	**δ**	**ε**
α	0.73 (NS)	0.37 (NS)	0.96 (NS)	<0.001
ß	-	0.60 (NS)	0.56 (NS)	<0.001
γ	-	-	0.89 (NS)	<0.001
δ	-	-	-	<0.001

[a]NS, not significant.

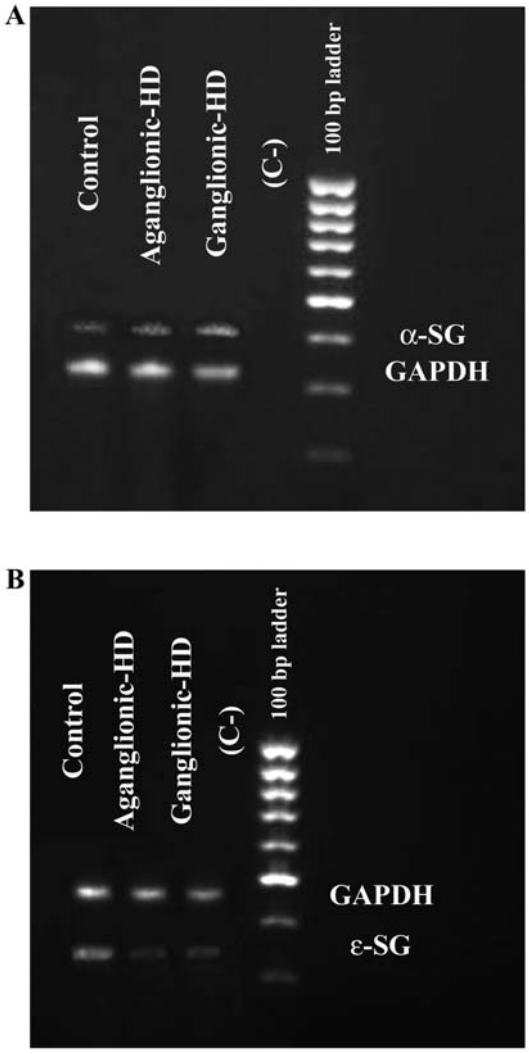

Figure 5. Two percent agarose gel electropherogram of RT PCR products amplified using human RNA as template, primer pairs of α- and ε-SG and primer pairs of GADPH (internal control). bp, base pairs; C-, negative correlation.

magnitude (Fig. 4E), while the peaks of α-SG were slightly increased as compared to aganglionic colon they were lower than in control specimens (Fig. 4F).

Using RT-PCR and nucleotide sequencing analysis with specific primers, the expression of α-, and ε-SG in control, in aganglionic and ganglionic HD-affected intestinal specimens was confirmed (Fig. 5). By this techniques the immunofuorescence results of ß-, γ-, δ-SG were also confirmed (not shown in RT-PCR figure).

Discussion

It is known that HD is characterized by the presence of a non-propulsive, non-relaxing aganglionic segment of the intestine (16), due to the absence of enteric ganglia containing cholinergic neurons, interneurons and non-adrenergic, non-cholinergic neurons, accompanied by increased cholinergic and adrenergic nerve fibers (1,2). The exact pathogenesis of this motility disorder and the increased tone of the aganglionic segments is not fully understood (3,5,22,23). It was demonstrated that in patients with HD, SMC cytoskeleton-ECM relationships are altered because the absence of laminin (24), desmin, vinculin and dystrofin (5). The interaction of DGC with components of the ECM may have an important role in force transmission (25) and the integrity of the DGC seems to be essential for the viability of SMC because disruption of the complex, due to a defect in dystrophin or any one of the SGs has been reported to cause various forms of muscular dystrophy or pathology (17-21). Moreover, SG complex reinforces the dystrophin-dystroglycan molecular linkage between the ECM and cytoskeletal actin (26).

In our study, we assessed the hypothesis that an alteration of SGs could explain the cytoskeletal alteration of SMC in colons affected by HD, as compared to control ones. Our previous immunohistochemical and molecular studies on many sites of the human body, demonstrated that all sarcoglycans, with higher or lower expression, are expressed in human smooth muscle fibers hypothesizing the intriguing possibility of the existence of a pentameric arrangement of the SGC. The higher or lower expression of sarcoglycan subunits could be in conformity with the location and function of smooth muscle (14,27).

In control ganglionic colons, our immunohistochemical data and relative semiquantitative analysis provided by the software function 'display profile' applied to each SG subunit, and our molecular data obtained by RT-PCR demonstrated a normal pattern of ß-, γ-, δ- and ε-SG while a reduced but clearly detectable staining for α-SG was recorded. These results confirmed that ε-SG is an integral component of the DGC in SMC of colons. In contrast, we noted a significantly lower expression of ε-SG in aganglionic bowel than in the normal bowel. It was hypothesized that ε-SG might often replace α-SG in SMC. It is known that the loss of the SGC clearly has an adverse effect on the maintenance of proper function in myocytes (15). In particular, loss of mutation of ε-SG is reported to cause the myoclonic dystonia syndrome in humans and anorectal manometric findings in HD (1) might be in accordance with a lack of ε-SG. It is suggestive also that ε-SG is highly expressed in the developing nervous system (15), so that mutations in the human ε-SG gene are associated with defects in the nervous system, possibly affecting neuronal development and patterning (28). In this manner, a segmental down-regulation of ε-SG during embryonic development might explain both SMC and neuronal abnormality in colon affected by HD.

A deleterious influence on neuronal development in co-culture with aganglionic SMC has been suggested (3). Therefore, a lack of ε-SG in SMC during embryonic life might impair the course of neuronal development, because the ongoing evidence for a consistent tropic and trophic interaction between nerve and target (3). Intestinal SMC probably plays a major role in guiding and influencing its own innervation (3) and our data documented an alteration of SG subcomplex, implying subsequent nerve alterations. Another explanation for the down-regulation of ε-SG could be ascribed by reduced amplitude of contraction and relaxation of the smooth muscle fibers of the constricted colon caused by absence of ganglia and altered intestinal peristalsis. This condition could provoke a loss of mechanical stress transmitted over cell surface receptors that physiologically couple the cytoskeleton to the ECM or to other

Therefore, mechanical signals could be integrated with environmental signals and transduce into a biochemical response through force-dependent changes in scaffold geometry or molecular mechanism by multimodular tensegrity architecture (29). Resultant changes in the topology of these networks could alter cellular biochemistry directly. Consequently, these mechanical changes could cause modifications of chemical signals, although variations of the structural pathways of SG subcomplex and promote down-regulation of ε-SG.

The significant up-regulation of α-SG in ganglionic-HD affected colons is important. The α-, ß-, γ- and δ-SG are typically expressed in skeletal muscle cells while ε-SG usually replaced α-SG in SMC to form the DGC (30). As regards, α- and ε-SG genes appear to have originated from a common ancestor by gene duplication, showing 43% amino acid identify (31), but the above proteins have different roles. In contrast to skeletal muscle, which is specialized for relatively forceful contraction of short duration, smooth muscle is specialized for continuous contractions of relatively low force producing diffuse movements, resulting in contraction of the whole muscle mass rather than contraction of individual motor units (30). In this manner, ganglionic HD-affected bowel has to win a functional intestinal obstruction, and it probably expresses α-SG rather than ε-SG because ganglionic HD-affected colon must acquire a mechanic reinforcement of sarcolemma to maintain membrane integrity during cycles of contraction and relaxation and modify its peristaltic pattern, producing a more forceful contraction.

In conclusion, our results demonstrate that in both aganglionic and ganglionic colon of patients with HD, SG subcomplex are significantly abnormal in SMC. Our observations underscore the assumption that non-neuronal elements of the colon might play a key role in the pathogenesis of HD and the loss of ε-SG might critically alter the cytoskeleton in the aganglionic bowel segment. Up-regulation of α-SG is probably an acquired phenomenon to reinforce the sarcolemma and to perform a forceful contraction in dilated ganglionic HD-affected colon, related to chronic pseudo-obstruction, contributing to the intestinal dysmotility that persists in 20% of patients after resection of all aganglionic bowel.

References

1. de Lorijn F, Boeckxstaens GE and Benninga MA: Symptomatology, pathophysiology, diagnostic work-up, and treatment of Hirschsprung disease in infancy and childhood. Curr Gastroenterol Rep 9: 245-253, 2007.
2. Scharli AF: Pathophysiology of classical Hirschsprung's disease. In: Hirschsprung's disease and allied disorders. Holschneider AM and Puri P (eds). Springer, Frankfurt, pp109-125, 2000.
3. Langer JC, Betti PA and Blennerhassett MG: Smooth muscle from aganglionic bowel in Hirschsprung's disease impairs neuronal development in vitro. Cell Tissue Res 276: 181-186, 1994.
4. Puri P, Ohshiro K and Wester T: Hirschsprung's disease: a search for etiology. Semin Pediatr Surg 7: 140-147, 1998.
5. Nemeth L, Rolle U and Puri P: Altered cytoskeleton in smooth muscle of aganglionic bowel. Arch Pathol Lab Med 126: 692-696, 2002.
6. Stromer MH: Immunocytochemistry of the muscle cell cytoskeleton. Microsc Res Tech 31: 95-105, 1995.
7. Small JV and Limona M: The cytoskeleton of the vertebrate smooth muscle cell. Acta Physiol Scand 164: 341-348, 1998.
8. Stromer MH: The cytoskeleton in skeletal, cardiac and smooth muscle cells. Histol Histopathol 13: 283-291, 1998.
9. Byers TJ, Kunkel LM and Watkins SC: The subcellular distribution of dystrophin in mouse skeletal, cardiac, and smooth muscle. J Cell Biol 115: 411-421, 1991.
10. Miyatake M, Miike T, Zhao JE, Yoshioka K, Uchino M and Usuku G: Dystrophin: localization and presumed function. Muscle Nerve 14: 113-119, 1991.
11. Campbell KP: Three muscular dystrophies: loss of cytoskeleton-extracellular matrix linkage. Cell 80: 675-679, 1995.
12. Liu LA and Engvall E: Sarcoglycan isoforms in skeletal muscle. J Biol Chem 274: 38171-38176, 1999.
13. Blake DJ, Weir A, Newey SE and Davies KE: Function and genetics of dystrophin and dystrophin-related proteins in muscle. Physiol Rev 82: 291-329, 2002.
14. Anastasi G, Cutroneo G, Sidoti A, *et al*: Sarcoglycan subcomplex expression in normal human smooth muscle. J Histochem Cytochem 55: 831-843, 2007.
15. Wheeler MT and McNally EM: Sarcoglycans in vascular smooth and striated muscle. Trends Cardiovasc Med 13: 238-243, 2003.
16. Ciftci AO, Sara Y, Tanyel FC, Bozdag O, Orer HS and Onur R: The role of nitrergic system on the contractility of colonic circular smooth muscle in Hirschsprung's disease. J Pediatr Surg 34: 1477-1481, 1999.
17. Bönnemann CG, Passos-Bueno MR, McNally EM, *et al*: Genomic screening for beta-sarcoglycan gene mutations: missense mutations may cause severe limb-girdle muscular dystrophy type 2E (LGMD 2E). Hum Mol Genet 5: 1953-1961, 1996.
18. McNally EM, Duggan D, Gorospe JR, *et al*: Mutations that disrupt the carboxyl-terminus of gamma-sarcoglycan cause muscular dystrophy. Hum Mol Genet 5: 1841-1847, 1996.
19. Noguchi S, McNally EM, Ben Othmane K, *et al*: Mutations in the dystrophin-associated protein gamma-sarcoglycan in chromosome 13 muscular dystrophy. Science 270: 819-822, 1995.
20. Bönnemann CG, Modi R, Noguchi S, *et al*: Beta-sarcoglycan (A3b) mutations cause autosomal recessive muscular dystrophy with loss of the sarcoglycan complex. Nat Genet 11: 266-273, 1995.
21. Arena S, Favaloro A, Cutroneo G, *et al*: Sarcoglycan subcomplex expression in refluxing ureteral endings. J Urol 179: 1980-1986, 2008.
22. Martucciello G, Ceccherini I, Lerone M and Jasonni V: Pathogenesis of Hirschsprung's disease. J Pediatr Surg 35: 1017-1025, 2000.
23. Nemeth L, Yoneda A, Kader M, Devaney D and Puri P: Three-dimensional morphology of gut innervation in total intestinal aganglionosis using whole-mount preparation. J Pediatr Surg 36: 291-295, 2001.
24. Parikh DH, Tam PK, Lloyd DA, Van Velzen D and Edgar DH: Quantitative and qualitative analysis of the extracellular matrix protein, laminin, in Hirschsprung's disease. J Pediatr Surg 27: 991-995, 1992.
25. Petrof BJ, Shrager JB, Stedman HH, Kelly AM and Sweeney HL: Dystrophin protects the sarcolemma from stresses developed during muscle contraction. Proc Natl Acad Sci USA 90: 3710-3714, 1993.
26. Imamura M, Mochizuki Y, Engvall E and Takeda S: Epsilon-sarcoglycan compensates for lack of alpha-sarcoglycan in a mouse model of limb-girdle muscular dystrophy. Hum Mol Genet 14: 775-783, 2005.
27. Anastasi G, Cutroneo G, Sidoti A, *et al*: Sarcoglycan subcomplex in normal human smooth muscle: an immunohistochemical and molecular study. Int J Mol Med 16: 367-374, 2005.
28. Zimprich A, Grabowski M, Asmus F, *et al*: Mutations in the gene encoding epsilon-sarcoglycan cause myoclonus-dystonia syndrome. Nat Genet 29: 66-69, 2001.
29. Ingber DE: Cellular mechanotransduction: putting all the pieces together again. FASEB J 20: 811-827, 2006.
30. Straub V, Ettinger AJ, Durbeej M, Venzke DP, Cutshall S, Sanes JR and Campbell KP: Epsilon-sarcoglycan replaces alpha-sarcoglycan in smooth muscle to form a unique dystrophin-glycoprotein complex. J Biol Chem 274: 27989-27996, 1999.
31. Ozawa E, Mizuno Y, Hagiwara Y, Sasaoka T and Yoshida M: Molecular and cell biology of the sarcoglycan complex. Muscle Nerve 32: 563-576, 2005.