SPANDIDOS PUBLICATIONS

MOLECULAR AND CLINICAL ONCOLOGY 2: 203-206, 2014

Association of transarterial chemoembolization with survival in patients with unresectable hepatocellular carcinoma

PENG WANG[1*], LILI SHENG[2*], GUOXIANG WANG[3], HEPING WANG[3], XINYU HUANG[3], XIAOXING YAN[3], XIAOHUA YANG[3] and RENGUANG PEI[3]

[1]Department of Head and Neck Surgery, Zhejiang Cancer Hospital, Hangzhou, Zhejiang 310022; Departments of [2]Medical Oncology and [3]Interventional Therapy, Yijishan Hospital of Wannan Medical College, Wuhu, Anhui 241001, P.R. China

Received November 1, 2013; Accepted December 20, 2013

DOI: 10.3892/mco.2014.239

Abstract. Hepatocellular carcinoma (HCC) is one of the most common types of cancer worldwide. Only a minority of HCC patients benefit from curative therapies, such as surgical resection, liver transplantation, or percutaneous treatment, since the majority of HCCs are diagnosed at intermediate or advanced stages. To determine whether transarterial chemoembolization (TACE) affects survival in patients with unresectable HCC, we conducted a case-controlled study, investigating 129 patients diagnosed with intermediate- or advanced-stage HCC, classified according to the Barcelona Clinic Liver Cancer staging system. Of these 129 patients, 102 received TACE and 27 received symptomatic treatment alone. The primary follow-up endpoint was survival. The association of TACE with survival was estimated with the Kaplan-Meier method. Survival was significantly higher in the chemoembolization group compared to that in the symptomatic treatment group. The estimated 1-, 2- and 3-year survival rates were 61.8, 34.0 and 24.3% for the chemoembolization group and 51.9, 9.9 and 0% for the symptomatic treatment group (P<0.001). TACE was shown to significantly improve survival and is an effective form of treatment for patients with unresectable HCC.

Introduction

Hepatocellular carcinoma (HCC) is one of the most common types of cancer worldwide (1). However, only a minority of HCC patients benefit from curative therapies, such as surgical resection, liver transplantation, or percutaneous treatment, since the majority of HCCs are diagnosed at intermediate or advanced stages (2). For patients with unresectable HCC, the goal of palliative treatment is to control symptoms and prolong survival. Transarterial chemoembolization (TACE) plays an important role in palliative treatment, although the effect of TACE on unresectable disease remains controversial (3). Several previous randomized trials suggested that TACE exerts little effect on survival (4-6). However, two more recent randomized trials reported that TACE improved the survival of patients with unresectable HCC (7,8).

The above mentioned data on the association of TACE with survival in unresectable HCC are mainly obtained from Western populations. However, Western populations differ from the Chinese population in certain aspects, such as ethnicity, etiology of HCC and use of the TACE regimen (1). Thus far, only one randomized controlled trial investigating TACE for unresectable HCC was conducted in Hong Kong, China and reported that TACE improved survival (8). However, this trial was limited by its limited sample size, recruiting only 80 patients.

Available data regarding the effect of TACE on unresectable HCC are currently limited; therefore, it has not yet been determined whether TACE is beneficial to patients with unresectable HCC in the Chinese mainland, although the incidence of HCC in this area accounts for >50% of the total HCC cases worldwide (1). Several patients receive symptomatic treatment due to the high cost or unavailability of TACE in the underdeveloped Chinese mainland. In view of these facts, we conducted a retrospective case-controlled study to evaluate whether patients with unresectable HCC in the Chinese mainland may benefit from TACE.

Materials and methods

Study population. A total of 129 patients with unresectable HCC who were found to be eligible for this study were treated at the Yijishang Hospital of Wannan Medical College between March, 2005 and June, 2007. The eligibility criteria for entering this study were B or C class HCC according to the Barcelona Clinic Live Cancer (BCLC) staging system (9), as follows: (i) multinodular, performance status (PS) 0, Child-Pugh class A-B; and (ii) portal invasion, N1, M1, PS 1-2,

Correspondence to: Dr Renguang Pei, Department of Interventional Therapy, Yijishan Hospital of Wannan Medical College, 2 Zheshan Road, Wuhu, Anhui 241001, P.R. China
E-mail: doctoprg@sohu.com

*Contributed equally

Key words: chemoembolization, symptomatic treatment, survival, unresectable hepatocellular carcinoma

Table I. Clinical characteristics of the TACE and symptomatic treatment groups.

Characteristics	No.	TACE n (%)	Symptomatic n (%)	P-value n (%)
Total patient no.	129	102	27	
Age (years)				0.230
<60	61	51 (50.0)	10 (37.0)	
≥60	68	51 (50.0)	17 (63.0)	
Gender				0.413
Male	108	84 (82.4)	24 (88.9)	
Female	21	18 (17.6)	3 (11.1)	
Etiology				0.669
HBV-positive	113	90 (88.2)	23 (85.2)	
HBV-negative	16	12 (11.8)	4 (14.8)	
AFP levels (ng/ml)				0.459
<400	78	60 (58.8)	18 (66.7)	
≥400	51	42 (41.2)	9 (33.3)	
Child-Pugh class				0.280
A	92	75 (73.5)	17 (63.0)	
B	37	27 (26.5)	10 (37.0)	
BCLC stage				0.317
B	100	81 (79.4)	19 (70.4)	
C	29	21 (20.6)	8 (29.6)	

TACE, transarterial chemoembolization; HBV, hepatitis B virus; AFP, α-fetoprotein; BCLC, Barcelona Clinic Liver Cancer.

Child-Pugh class A-B. Of the 129 patients, 102 received TACE as the case group and 27 received symptomatic treatment alone as the control group. The data retrieved from patient medical records included gender, age of onset, levels of α-fetoprotein (AFP), BCLC staging and Child-Pugh classification. This study was approved by the Research and Ethics Committee of the Yijishan Hospital of Wannan Medical College.

Treatment procedure. The control group received conservative treatment alone for the management of the symptoms and complications. The case group underwent transarterial Lipiodol chemoembolization following a standard protocol. The femoral artery was catheterized under local anaesthesia. Hepatic arteriography and superior mesenteric arterial portovenography were performed to determine the size and location of the tumor nodules. The right or left hepatic artery feeding the tumor was super-selectively catheterized. An emulsion of doxorubicin (30 mg/m^2; Haizheng Pharmaceutical Co., Ltd., Shanghai, China) or cisplatin (30 mg/m^2; Haosen Pharmaceutical Company, Jiangxi, China) mixed with Lipiodol (Guerbet, Villepinte, France) was infused prior to mechanical obstruction. TACE was repeated every 1.5 to 3 months, unless there was evidence of contraindications or progressive disease.

Follow-up. Follow-up data were available for all the patients, with a median follow-up of 11 months. The primary outcome measure was survival, calculated from the date of diagnosis at the Yijishan Hospital. The patients were followed up monthly at the outpatient clinic or by telephone. During the follow-up period, 122 patients succumbed to the disease and 7 patients were censored, 6 of which were in the case group and 1 in the control group.

Statistical analysis. The comparison of the clinical characteristics between the two groups was measured by the χ^2 test. The primary endpoint was survival, which was estimated with the Kaplan-Meier method and the log-rank test. All the statistical tests and P-values were two-tailed and P-values <0.05 were considered to indicate statistically significant differences. All the analyses were performed using the SPSS software, version 16.0 (SPSS Inc, Chicago, IL, USA).

Results

Patient characteristics. Between March, 2005 and June, 2007, a cohort of 129 patients with unresectable HCC entered this study. The case group included 102 patients who received TACE and the control group included 27 patients who received symptomatic treatment alone.

The clinical characteristics of the two groups are summarized in Table I. None of these characteristics, including age, gender, HBV infection status, levels of AFP, Child-Pugh class and BCLC stage, were found to be statistically significantly different between the TACE and the symptomatic treatment groups.

Survival comparison. As shown in Fig. 1, the TACE group exhibited a significantly better overall survival compared to

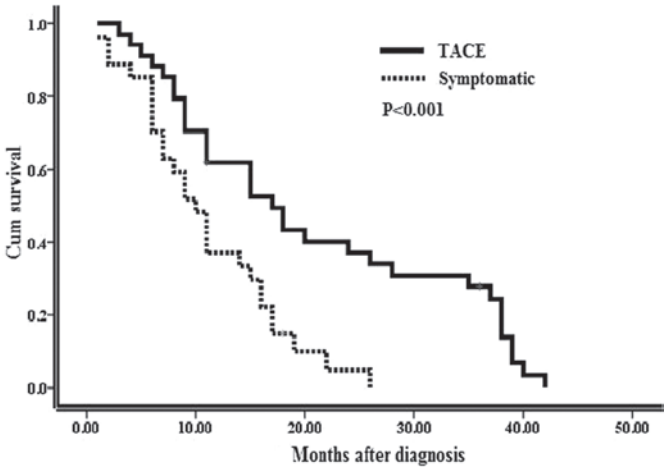

Figure 1. Cumulative survival in the transarterial chemoembolization (TACE) and symptomatic treatment groups.

the symptomatic treatment group. The estimated 1-, 2- and 3-year cumulative survival rates were 61.8, 34.0 and 24.3% for the TACE group and 51.9, 9.9 and 0% for the symptomatic treatment group (P<0.001).

Discussion

In the present study, we demonstrated that TACE was significantly associated with improved survival compared to symptomatic treatment in Chinese mainland patients with unresectable HCC. There were no significant differences between the two groups regarding clinical characteristics, such as Child-Pugh class and BCLC stage.

There is currently no standard treatment for patients with unresectable HCC, although the therapeutic approaches are rapidly evolving, as the biology and natural history of this disease becomes gradually elucidated (1). It is widely accepted that partial hepatectomy, local ablation or liver transplantation offer the best chance for long-term and disease-free survival for patients with HCC. However, only a minority of patients with HCC are candidates for these curative therapies, due to advanced tumor stage, multicentric disease, poor liver function, or comorbidities at diagnosis (10). Additionally, systematic chemotherapy was shown to be mostly ineffective for HCC (11).

In our study, we only evaluated the association of TACE with survival, excluding assessment of the tumor response following TACE, since tumor response in HCC patients was not found to be a valuable predictor of prognosis (12).

A number of case-control and retrospective studies on Western populations demonstrated a considerable improvement in patient survival with TACE (13). In a selective population with HCC, the 1-, 3- and 5-year survival rates were 82, 47 and 26%, respectively (14). Despite these encouraging results, there remains considerable controversy over the effectiveness and safety of TACE. To date, there have been at least five randomized controlled trials (RCTs) comparing TACE to symptomatic treatment by survival (4-8). Three trials failed to demonstrate any significant patient benefit from TACE regarding survival (4-6) and two systematic reviews of non-randomized and randomized studies also reported similar results, i.e., that TACE exerts little effect on survival (15,16). By contrast, two subsequent RCTs reported that TCAE significantly improved survival (7,8). Accordingly, two more recent systematic reviews reached the same positive conclusion (17,18). The results of our study are in accordance with those of the two RCTs supporting that TCAE significantly improved survival (7,8), one of which was conducted in Hong Kong, China and included a patient population similar to ours (8).

The inconsistence among these studies may be due to several factors. First, the study populations were from different sources. Three negative trials mainly included Western populations or mixed-race patients with advanced tumors in a background of alcohol-induced liver disease. There was a marked variation in the outcome of patients with respect to race and ethnicity and the natural history of untreated disease in European patients is considerably better compared to that of Asians (19,20). Our study, as well as the Hong Kong trial (8) mostly included patients positive for HBV. It was reported that HBV-positive patients have a worse prognosis (21). The 2-year survival rate in the symptomatic group in our study was 9.9%, which was lower compared to the 26% reported by a French multicenter trial (6). In addition, the selection criteria for patients receiving TACE must be considered. Different tumor classifications were adopted in our study compared with the three negative trials (4-6). Our study adopted BLCL staging, whereas Okuda stage was used in the three negative trials. Tumor stage was also significantly associated with survival and may sway the effect of TACE (3).

Second, the technique and regimen of TACE may have accounted, at least in part, for the inconsistence. Similar to the two positive trials (7,8), in order to maximize the efficacy and minimize toxicity, chemoembolization was conducted by selective injection into the feeding artery in over half of our cases. In comparison with the negative trials, our study used doxorubicin- or cisplatin-Lipiodol emulsion. Among several single-agent chemotherapies for HCC, doxorubicin was found to be the most effective (22).

Furthermore, the negative systematic reviews and meta-analyses may be outdated, as they excluded the two positive trials. Subsequent systematic reviews, including the two positive trials, demonstrated that TACE improved the survival of patients with unresectable HCC (17,18).

In conclusion, our study confirmed that TACE is efficient in prolonging survival in selected HCC patients compared to symptomatic treatment alone. To the best of our knowledge, the present study was the first case-control study to evaluate the effect of TACE in Chinese mainland patients with HCC. The limitations of our study lie in its retrospective nature. The regimen and effect of TACE tailored for the Chinese population require further investigation by large prospective RCTs conducted in China.

References

1. Yang JD and Roberts LR: Hepatocellular carcinoma: a global view. Nat Rev Gastroenterol Hepatol 7: 448-458, 2010.
2. Bruix J and Sherman M: Management of hepatocellular carcinoma. Hepatology 42: 1208-1236, 2005.
3. Bruix J, Sala M and Llovet JM: Chemoembolization for hepatocellular carcinoma. Gastroenterology 127: S179-S188, 2004.

4. Pelletier G, Roche A, Ink O, Anciaux ML, Derhy S, Rougier P, *et al*: A randomized trial of hepatic arterial chemoembolization in patients with unresectable hepatocellular carcinoma. J Hepatol 11: 181-184, 1990.
5. Madden MV, Krige JE, Bailey S, Beningfield SJ, Geddes C, Werner ID and Terblanche J: Randomised trial of targeted chemotherapy with lipiodol and 5-epidoxorubicin compared with symptomatic treatment for hepatoma. Gut 34: 1598-1600, 1993.
6. No authors listed: A comparison of lipiodol chemoembolization and conservative treatment for unresectable hepatocellular carcinoma. Groupe d'Etude et de Traitement du Carcinome Hépatocellulaire. N Engl J Med 332: 1256-1261, 1995.
7. Llovet JM, Real MI, Montana X, *et al*; Barcelona Liver Cancer Group: Arterial embolisation or chemoembolisation versus symptomatic treatment in patients with unresectable hepatocellular carcinoma: a randomised controlled trial. Lancet 359: 1734-1739, 2002.
8. Lo CM, Ngan H, Tso WK, *et al*: Randomized controlled trial of transarterial lipiodol chemoembolization for unresectable hepatocellular carcinoma. Hepatology 35: 1164-1171, 2002
9. Bruix J and Sherman M: Management of hepatocellular carcinoma: an update. Hepatology 53: 1020-1022, 2011.
10. Bruix J and Llovet JM: Prognostic prediction and treatment strategy in hepatocellular carcinoma. Hepatology 35: 519-524, 2002.
11. Zhu AX: Systemic treatment of hepatocellular carcinoma: dawn of a new era? Ann Surg Oncol 17: 1247-1256, 2010.
12. Trevisani F, De Notariis S, Rossi C and Bernardi M: Randomized control trials on chemoembolization for hepatocellular carcinoma: is there room for new studies? J Clin Gastroenterol 32: 383-389, 2001.
13. Lau WY, Yu SC, Lai EC and Leung TW: Transarterial chemoembolization for hepatocellular carcinoma. J Am Coll Surg 202: 155-168, 2006.
14. Takayasu K, Arii S, Ikai I, *et al*; Liver Cancer Study Group of Japan: Prospective cohort study of transarterial chemoembolization for unresectable hepatocellular carcinoma in 8510 patients. Gastroenterology 131: 461-469, 2006.
15. Simonetti RG, Liberati A, Angiolini C and Pagliaro L: Treatment of hepatocellular carcinoma: a systematic review of randomized controlled trials. Ann Oncol 8: 117-136, 1997.
16. Mathurin P, Rixe O, Carbonell N, *et al*: Review article: overview of medical treatments in unresectable hepatocellular carcinoma - an impossible meta-analysis? Aliment Pharmacol Ther 12: 111-126, 1998.
17. Llovet JM and Bruix J: Systematic review of randomized trials for unresectable hepatocellular carcinoma: chemoembolization improves survival. Hepatology 37: 429-442, 2003.
18. Camma C, Schepis F, Orlando A, *et al*: Transarterial chemoembolization for unresectable hepatocellular carcinoma: meta-analysis of randomized controlled trials. Radiology 224: 47-54, 2002.
19. Chin PL, Chu DZ, Clarke KG, Odom-Maryon T, Yen Y and Wagman LD: Ethnic differences in the behavior of hepatocellular carcinoma. Cancer 85: 1931-1936, 1999.
20. Harrison LE, Reichman T, Koneru B, *et al*: Racial discrepancies in the outcome of patients with hepatocellular carcinoma. Arch Surg 139: 992-996, 2004.
21. Villa E, Moles A, Ferretti I, Buttafoco P, Grottola A, Del Buono M, De Santis M and Manenti F: Natural history of inoperable hepatocellular carcinoma: estrogen receptors' status in the tumor is the strongest prognostic factor for survival. Hepatology 32: 233-238, 2000.
22. Ganne-Carrie N and Trinchet JC: Systemic treatment of hepatocellular carcinoma. Eur J Gastroenterol Hepatol 16: 275-281, 2004.