SPANDIDOS PUBLICATIONS

MOLECULAR AND CLINICAL ONCOLOGY 4: 611-615, 2016

Z skin incision in reduced-port surgery for colorectal cancer

SHIKI FUJINO, NORIKATSU MIYOSHI, MASAYUKI OHUE, SHINGO NOURA, YOSHIYUKI FUJIWARA, MASAHIKO HIGASHIYAMA and MASAHIKO YANO

Department of Surgery, Osaka Medical Center for Cancer and Cardiovascular Diseases, Osaka 537-8511, Japan

Received May 17, 2015; Accepted November 19, 2015

DOI: 10.3892/mco.2016.757

Abstract. Laparoscopic surgery for colorectal cancer (CRC) has recently gained in popularity due to the fewer trocars and shorter incision, leading to reduced wound pain and improved cosmetic outcome. In July, 2013, reduced-port surgery (RPS) was introduced and has been performed thereafter in our hospital. An umbilical incision is used for a main port in RPS, through which the specimen is removed and the anastomosis is performed. In order to make the incision shorter, we introduced the Z skin incision in RPS. In this study, we aimed to discuss this method and evaluate the short-term outcome. Among CRC patients undergoing RPS, Z skin incision (n=14) was compared to conventional skin incision (n=15). The clinical and surgical factors were evaluated and there were no significant differences in terms of gender, age, body mass index, tumor site, procedure, operative time, blood loss or complications between the two groups. The median incision length at the umbilicus was significantly shorter in the Z incision group (P=0.004). Particularly in functional end-to-end anastomosis, the median incision length was 2.5 cm in the Z skin incision group and 4.0 cm in the conventional incision group (P=0.018). In conclusion, Z skin incision is a useful technique for achieving an effective length of skin incision in RPS for CRC.

Introduction

In recent years, laparoscopic surgery has been widely performed for colorectal cancer (CRC) in a number of institutions. It has been reported that the efficacy of laparoscopic surgery is due to the reduced blood loss, shorter hospital stay, decreased postoperative pain, earlier postoperative recovery and improved quality of life, with oncological outcomes comparable to those with open surgery (1-3). Conventional multiport laparoscopic surgery for CRC is mainly performed using five trocars, namely one for the laparoscopist, two for the operator and two for the assistant. Recently, efforts have been made to reduce the number of trocars and perform a shorter skin incision, in order to reduce wound pain and provide a better cosmetic outcome; therefore, single-incision laparoscopic surgery (SILS) and reduced-port surgery (RPS) have been applied in colectomies (3-7). In SILS and RPS, an umbilical incision is used for multi-trocar access, to remove the specimen and perform the anastomosis; thus, the length of the umbilical skin incision depends on these procedures. A shorter umbilical skin incision may reduce postoperative pain and provide a better cosmetic outcome. A Z-shaped skin incision has been used in orthopedics and plastic surgery (8). The Z-shaped skin incision is used for the relaxation of scar contractures and it may provide an incision that is longer compared with a straight line (9). We attempted to perform a shorter umbilical incision using this method and we herein report the usefulness of the Z skin incision in RPS for CRC.

Patients and methods

Patients. A total of 33 patients underwent RPS for CRC at the Osaka Medical Center for Cancer and Cardiovascular Diseases (Osaka, Japan) between July, 2013 and May, 2014. From December, 2013 onwards, we determined that the best method for achieving a shorter umbilical incision was using the Z method. We separated patients into two groups, namely the conventional skin incision group (July, 2013-November, 2013) and the Z skin incision group (December, 2013-May, 2014). A total of 4 patients who had received different types of incisions in November and December, 2013 were excluded. In total, 15 patients underwent RPS with the conventional incision (conventional incision group) and 14 with the Z incision (Z incision group). In all cases, the umbilical incision was used for the first access to the abdominal cavity and as the main port with multiple trocars.

This study was approved by our Institutional Review Board and written informed consent regarding these surgical procedures were obtained from all the participants according to the ethical guidelines of the Osaka Medical Center for Cancer and Cardiovascular Diseases.

Procedure. The Z or midline skin incision was marked in the umbilical region with a sharp knife and the subcutaneous tissue was incised (Fig. 1). A Lap Protector (Hakko Co., Ltd., Nagano, Japan) was folded and the bottom half was inserted into the abdomen through the umbilical incision. EZ Access

Correspondence to: Dr Norikatsu Miyoshi, Department of Surgery, Osaka Medical Center for Cancer and Cardiovascular Diseases, 1-3-3 Nakamichi, Higashinari-ku, Osaka 537-8511, Japan
E-mail: miyosi-no@mc.pref.osaka.jp

Abbreviations: RPS, reduced-port surgery; CRC, colorectal cancer; SILS, single-incision laparoscopic surgery

Key words: reduced-port surgery, colorectal cancer, skin incision

(Hakko Co., Ltd.) was adjusted and two or three devices were introduced through it: A flexible laparoscope (Olympus, Tokyo, Japan) and one or two operating forceps (Fig. 2). Depending on the surgical procedure, one or two ports were added to the lateral abdomen. An operator used two trocars and an assistant used another two trocars, including the laparoscope. The pneumoperitoneum was set at 10 mmHg. In all the cases, laparoscopic intestinal mobilization and lymph node dissection were performed. The intestinal specimen was extracted through the umbilical incision. Functional end-to-end anastomosis (FEEA) or the double-stapling technique (DST).FEEA was performed outside the body after extracting the proximal and distal parts of the intestine through the incision If the specimen could not be extracted, the skin incision was extended along the midline (Fig. 1). Finally, a drainage tube was placed in the pouch of Douglas through the lateral abdominal port site. The fascia was closed with 1 Vicryl sutures (Johnson & Johnson, New Brunswick, NJ, USA) and, after washing with warm saline (500 ml), the skin was closed with 4-0 polydioxanone sutures (Johnson & Johnson). The clinical and operative factors and postoperative outcomes between the conventional and the Z incision groups were analyzed. Clinical stage was determined according to Japanese Clinical Guidelines, Japanese Classification of Colorectal Carcinoma (10).

Statistical analysis. For continuous variables, data are expressed as median (range). The clinical and surgical factors between the conventional and Z incision groups were analyzed using the Wilcoxon rank-sum and Pearson's Chi-square tests. All the data were analyzed using JMP software, version 11.0 (SAS Institute Inc., Cary, NC, USA). Differences with P-values <0.05 were considered statistically significant.

Results

Comparison of patient characteristics between the conventional and Z incision groups. Gender, age, body mass index, clinical stage, tumor site, operative procedure and lymph node dissection did not differ significantly between the two groups (Table I). The surgical and perioperative factors, apart from the length of the skin incision, did not differ significantly between the two groups (Table II). The median length of the skin incision was shorter in the Z incision group [2.5 cm (range, 1.8-4.0 cm)] compared with that in the conventional incision group [3.0 cm (range, 2.0-4.0 cm)] (P=0.004) (Fig. 3). The median operative time was 283 min (range, 175-424 min) and 246 min (range, 169-471 min) in the conventional and Z incision groups, respectively, whereas the blood loss was 25 ml (range, 0-130 ml) and 35 ml (range, 5-300 ml), respectively. In the conventional incision group, 3 patients developed postoperative complications: 1 patient developed surgical site infection in the umbilical wound, 1 suffered from postoperative ileus, and 1 presented with anastomotic bleeding. All the complications were grade I according to the Clavien-Dindo classification (http://www.surgicalcomplication.info/index-2.html).

Comparison of patient characteristics between the conventional and Z incision groups in patients undergoing FEEA. We next examined cases in which FEEA was performed, as this anastomosis procedure generally requires an extended incision.

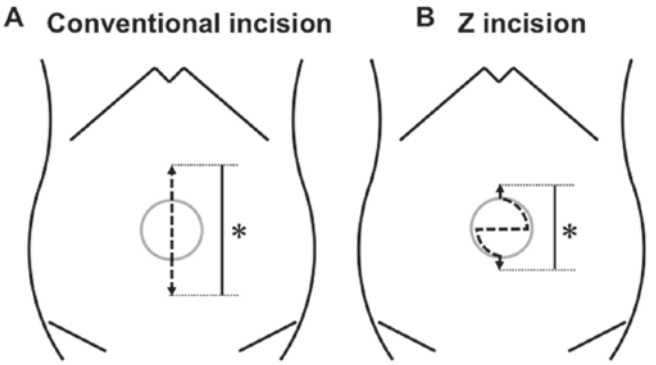

Figure 1. Marking of the conventional and Z incisions. (A) In the conventional incision group, the skin was cut along the midline via the bottom of the umbilicus. (B) In the Z incision group, the skin was cut along a quarter of the circumference of the umbilical circle from 0 to 90 and from 180 to 270 degrees. The two lines are connected via the bottom of the umbilicus. The incisions could be extended along the midline in both groups (arrows). *Length of umbilical incision.

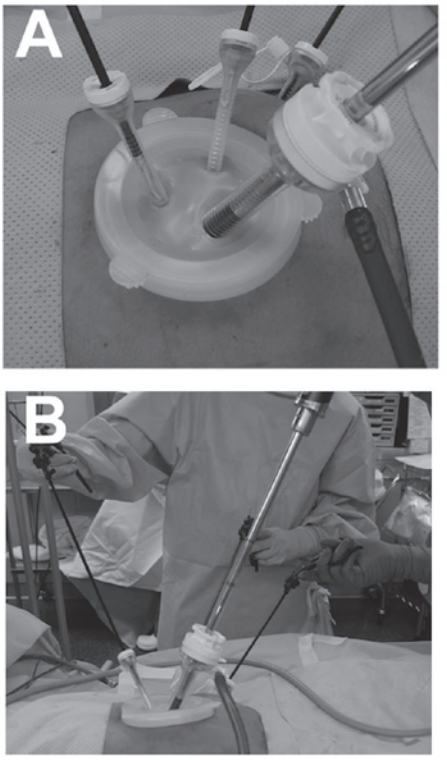

Figure 2. Images of multi-trocar access using EZ Access in an umbilical incision. (A) Three trocars were placed in EZ Access and one port was in the left lateral abdomen in a right colectomy. (B) The operator used two trocars and the assistant used the other two trocars.

The patients' characteristics did not differ significantly between the two groups (Table III). The surgical and perioperative factors, apart from the length of the skin incision, did not differ significantly between the two groups (Table IV). The median length of the skin incision was 4.0 cm (range, 3.0-4.0 cm) in the conventional and 2.5 cm (range, 1.8-4.0 cm) in the Z incision group (P=0.018), suggesting that we may achieve shorter incisions using the Z technique in FEEA. Using the Z technique, we performed RPS with a shorter skin incision, without any effect on surgical or perioperative factors.

Table I. Clinical characteristics of the 29 patients.

Characteristics	Conventional incision (n=15)	Z incision (n=14)	P-value
Age, years (range)	62 (41-85)	63 (38-81)	0.861
Gender (male/female)	10/5	8/6	0.597
Body mass index, kg/m^2 (range)	21 (18-28)	22 (16-24)	0.947
Clinical stage (0/I/II/III/IV)	1/13/1/0/0	1/12/0/1/0	
Tumor site (C/A/T/D/S/RS/Ra/Rb)	2/5/0/1/1/4/1/1	1/2/3/3/1/1/1/2	

C, cecum; A, ascending colon; T, transverse colon; D, descending colon; S, sigmoid colon; RS, rectosigmoid; Ra, rectum above the peritoneal reflection; Rb, rectum below the peritoneal reflection.

Table II. Surgical factors and postoperative outcome of the 29 patients.

Variables	Conventional incision (n=15)	Z incision (n=14)	P-value
Operative procedure (ICR/R/T/L/S/AR/LAR)	3/4/0/2/0/4/2	1/3/2/3/1/1/3	
Lymph node dissection[a] (D1/D2/D3)	15/2/0	12/2/0	
Tumor size, mm (range)	30 (10-90)	20 (10-50)	0.128
Length of umbilical incision, cm (range)	3.0 (2.0-4.0)	2.5 (1.8-4.0)	0.004
Length of umbilical incision (≤2.5 cm/2.5 cm<)	1/14	10/4	<0.001
Number of ports (range)	3 (2-4)	3 (2-4)	1.000
Operative time, min (range)	283 (175-424)	246 (163-471)	0.382
Blood loss, ml (range)	25 (0-130)	35 (5-300)	0.417
Open conversion	0	0	
Anastomosis (FEEA/DST)	9/6	9/5	0.812
SSI of umbilical incision	1	0	
Complications (without SSI)	2	0	
Postoperative hospital stay, days (range)	12 (5-83)	11 (9-19)	0.310
Mortality	0	0	
MFT Reccurence (months)	1 (25)	0 (19)	

[a]Determined by the Japanese Classification of Colorectal Carcinoma. ICR, ileocecal resection; R, right colectomy; T, transverse colectomy; L, left colectomy; S, sigmoid colectomy; AR, anterior resection; LAR, low anterior resection. FEEA, functional end-to-end anastomosis; DST, double-stapling technique. SSI, surgical site infection; MFT, median follow-up time.

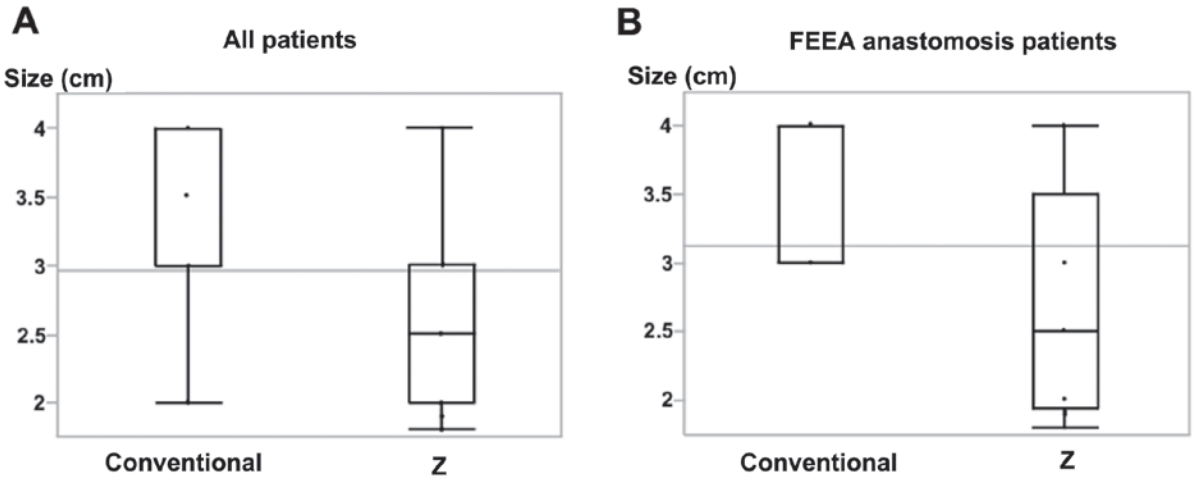

Figure 3. Analysis of the length of the umbilical incision between the conventional and Z incision groups. (A) The length was significantly shorter in the Z incision group compared with that in the conventional incision group (Wilcoxon rank-sum test, P=0.004). (B) In FEEA patients, the length was shorter in the Z incision group compared with that in the conventional incision group (Wilcoxon rank-sum test, P=0.018). FEEA, functional end-to-end anastomosis.

Table III. Clinical characteristics of 18 patients with FEEA.

Characteristics	Conventional incision (n=9)	Z incision (n=9)	P-value
Age, years (range)	62 (41-85)	66 (38-77)	0.894
Gender (male/female)	8/1	6/3	0.256
Body mass index, kg/m^2 (range)	20 (18-24)	21 (16-24)	0.857
Clinical stage (0/I/II/III/IV)	0/8/1/0/0	1/7/0/1/0	
Tumor site (C/A/T/D/S)	2/5/0/1/1	1/2/3/3/0	

FEEA, functional end-to-end anastomosis; C, cecum; A, ascending colon; T, transvers colon; D, descending colon; S, sigmoid colon.

Table IV. Surgical factors and postoperative outcomes of 18 patients with FEEA.

Variables	Conventional incision (n=9)	Z incision (n=9)	P-value
Operative procedure (ICR/R/T/L)	3/4/0/2	1/3/2/3	
Lymph node dissection[a] (D1/D2/D3)	0/7/2	0/8/1	
Tumor size, mm (range)	30 (10-55)	20 (10-50)	0.264
Length of umbilical incision, cm (range)	4.0 (3.0-4.0)	2.5 (1.8-4.0)	0.018
Number of ports (range)	3 (2-4)	3 (2-4)	1.000
Operative time, min (range)	262 (175-370)	231 (163-430)	0.627
Blood loss, ml (range)	40 (0-130)	40 (5-300)	0.929
Open conversion	0	0	
SSI of umbilical incision	1	0	
Complication (without SSI)	2	0	
Postoperative hospital stay, days (range)	13 (5-17)	11 (9-13)	0.052
Mortality	0	0	
MFT Recurrence (months)	1 (25)	0 (19)	

[a]Determined by the Japanese Classification of Colorectal Carcinoma. FEEA, functional end-to-end anastomosis; ICR, ileocecal resection; R, right colectomy; T, transverse colectomy; L, left colectomy; SSI, surgical site infection; MFT, median follow-up time.

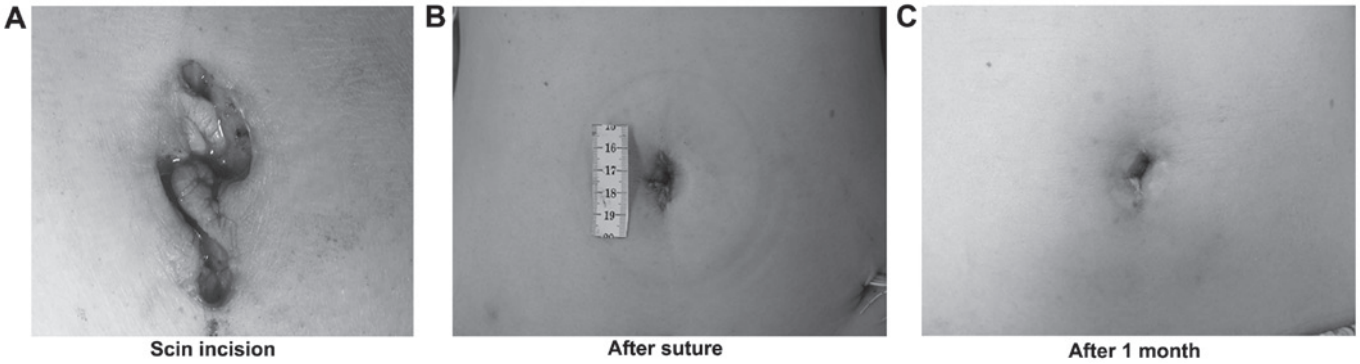

Figure 4. Z skin incision (A) immediately after the skin incision, (B) immediately after suturing and (C) 1 month after the operation.

Discussion

The evolution of laparoscopic surgery has recently led to the introduction of SILS and RPS, despite the limited laparoscopic handling space. Certain studies previously compared single-incision laparoscopic colectomy to conventional multiport laparoscopic colectomy for CRC in terms of operative procedure and outcome (11-13). There were no differences in operative time, open conversion, number of harvested lymph nodes, length of stay, postoperative complications and mortality.

In our study, we also hypothesized that the shorter length of the umbilical incision may present with certain difficulties in the operative technique of RPS for CRC. However, there was no difference in those factors between the conventional and the Z skin incision groups. Therefore, the shorter length of the umbilical incision does not increase the difficulty of RPS

in terms of laparoscopic handling. Fujii *et al* (13) reported that the median length of the skin incision was 3.3 cm in SILS for CRC, and Hachisuka *et al* (14) reported on the zigzag skin incision in RPS for CRC. An incision was required from above to below the umbilical ring. Using the Z skin incision, we were able to shorten the length of the umbilical incision and, in some cases, the incisions were limited within the umbilical ring. With an umbilical incision of <2.5 cm within the umbilical ring, the patient appeared scar-free 1 month after surgery (Fig. 4). The length of the umbilical incision was significantly <2.5 cm in the Z incision group (P=0.0003). Performing and closing the Z incision is somewhat complicated compared with the conventional incision. It generally requires 9 min to open and 15 min to close; however, there were no differences in the total operative time between the conventional and Z skin incision groups. There was no difference in surgical and perioperative factors. Therefore, the Z incision is a useful technique, particularly in SILS and RPS that use the umbilicus for multi-trocar access.

In conclusion, we developed an umbilical Z skin incision technique to perform an abdominal laparoscopic colectomy with an umbilical skin incision of a shorter length. This appears to be a useful technique in RPS for CRC.

Acknowledgements

We would like to thank Dr T. Fukata, Dr T. Umeda, Dr K. Sasaki, Dr Y. Wada, Dr Y. Shishido, Dr T. Hara and Dr K. Hayashi for surgical assistance and fruitful discussion. We would also like to thank Ms. Y. Katayama for technical assistance.

References

1. Yamamoto S, Inomata M, Katayama H, Mizusawa J, Etoh T, Konishi F, Sugihara K, Watanabe M, Moriya Y and Kitano S; Japan Clinical Oncology Group Colorectal Cancer Study Group: Short-term surgical outcomes from a randomized controlled trial to evaluate laparoscopic and open D3 dissection for stage II/III colon cancer: Japan Clinical Oncology Group Study JCOG 0404. Ann Surg 260: 23-30, 2014.
2. Braga M, Frasson M, Zuliani W, Vignali A, Pecorelli N and Di Carlo V: Randomized clinical trial of laparoscopic versus open left colonic resection. Br J Surg 97: 1180-1186, 2010.
3. Yang TX and Chua TC: Single-incision laparoscopic colectomy versus conventional multiport laparoscopic colectomy: A meta-analysis of comparative studies. Int J Colorectal Dis 28: 89-101, 2013.
4. Makino T, Milsom JW and Lee SW: Single-incision laparoscopic surgeries for colorectal diseases: Early experiences of a novel surgical method. Minim Invasive Surg 2012: 783074, 2012.
5. Makino T, Milsom JW and Lee SW: Feasibility and safety of single-incision laparoscopic colectomy: A systematic review. Ann Surg 255: 667-676, 2012.
6. Champagne BJ, Papaconstantinou HT, Parmar SS, Nagle DA, Young-Fadok TM, Lee EC and Delaney CP: Single-incision versus standard multiport laparoscopic colectomy: A multicenter, case-controlled comparison. Ann Surg 255: 66-69, 2012.
7. Vestweber B, Galetin T, Lammerting K, Paul C, Giehl J, Straub E, Kaldowski B, Alfes A and Vestweber KH: Single-incision laparoscopic surgery: Outcomes from 224 colonic resections performed at a single center using SILS. Surg Endosc 27: 434-442, 2013.
8. Davis JS: The relaxation of scar contractures by means of the Z-, or reversed Z-type incision: Stressing the use of scar infiltrated tissues. Ann Surg 94: 871-884, 1931.
9. Tan O, Atik B and Ergen D: A new method in the treatment of postburn scar contractures: Double opposing V-Y-Z plasty. Burns 32: 499-503, 2006.
10. Watanabe T, Itabashi M, Shimada Y, Tanaka S, Ito Y, Ajioka Y, Hamaguchi T, Hyodo I, Igarashi M, Ishida H, *et al*; Japanese Society for Cancer of the Colon and Rectum: Japanese Society for Cancer of the Colon and Rectum (JSCCR) guidelines 2010 for the treatment of colorectal cancer. Int J Clin Oncol 17: 1-29, 2012.
11. Huscher CG, Mingoli A, Sgarzini G, Mereu A, Binda B, Brachini G and Trombetta S: Standard laparoscopic versus single-incision laparoscopic colectomy for cancer: Early results of a randomized prospective study. Am J Surg 204: 115-120, 2012.
12. Kim SJ, Ryu GO, Choi BJ, Kim JG, Lee KJ, Lee SC and Oh ST: The short-term outcomes of conventional and single-port laparoscopic surgery for colorectal cancer. Ann Surg 254: 933-940, 2011.
13. Fujii S, Watanabe K, Ota M, Watanabe J, Ichikawa Y, Yamagishi S, Tatsumi K, Suwa H, Kunisaki C, Taguri M, *et al*: Single-incision laparoscopic surgery using colon-lifting technique for colorectal cancer: A matched case-control comparison with standard multiport laparoscopic surgery in terms of short-term results and access instrument cost. Surg Endosc 26: 1403-1411, 2012.
14. Hachisuka T, Kinoshita T, Yamakawa T, Kurata N, Tsutsuyama M, Umeda S, Tokunaga S, Yarita A, Shibata M, Shimizu D, *et al*: Transumbilical laparoscopic surgery using GelPort through an umbilical zigzag skin incision. Asian J Endosc Surg 5: 50-52, 2012.