

Bilateral primary adrenal diffuse large B cell lymphoma without adrenal insufficiency: A case report and review of the literature

PEIJIE CHEN^{1,2*}, LU JIN^{1,3*}, YU YANG¹, LIANGCHAO NI¹, SHANGQI YANG¹ and YONGQING LAI¹

¹Department of Urology, Peking University Shenzhen Hospital, Shenzhen, Guangdong 518036; ²Shantou University Medical College, Shantou, Guangdong 515041; ³Anhui Medical University, Hefei, Anhui 230032, P.R. China

Received October 7, 2016; Accepted March 24, 2017

DOI: 10.3892/mco.2017.1264

Abstract. Primary adrenal lymphoma (PAL) is an infrequent malignant tumor, occurring in the bilateral adrenal glands as a mass in the majority of cases. The current study presents a case of bilateral primary adrenal diffuse large B cell lymphoma in a 52-year-old female patient, who presented with abdominal pain in the left lumbar region for ~2 weeks. Abdominal ultrasound examination and computed tomography scanning revealed a mass of 132x119x101 mm on the left adrenal gland and a mass of 53x27 mm on the right adrenal gland. A percutaneous biopsy was performed and histopathological examination further confirmed this lesion as diffuse large B cell lymphoma. The present study highlights the importance of early diagnosis of PAL, and performs a literature review of the subject.

Introduction

Although the adrenal glands contain no lymphoid tissue, primary adrenal lymphoma (PAL) is identified in <1% of cases of non-Hodgkin lymphoma (1). As a type of extranodal lymphoma, PAL is rare and constitutes <1% of cases of extranodal lymphomas; PAL is primarily bilateral but secondary involvement of the adrenal gland is typically unilateral (2,3). Diffuse large B cell lymphoma (DLBCL) is the most common subtype of PAL, which represents ~70% of PAL cases (4,5). Characteristically, PAL predominantly affects elderly patients without nodular lesions. Diagnosis of PAL is frequently challenging due to its nonspecific clinical manifestation and imaging results, and pathological examination is the only method of confirming this diagnosis (6). The prognosis of

PAL is typically poor, and the 1-year survival rate is 17.5% (3). The current study reports a case of bilateral primary adrenal diffuse large B cell lymphoma and performs a review of the literature.

Case report

In June 2016, a 52-year-old female patient was admitted to the Department of Urology of Peking University Shenzhen Hospital (Shenzhen, China) due to abdominal pain in the left lumbar region lasting ~2 weeks. The patient had experience anorexia and weight loss of ~15 kg in the previous 0.5 months. The patient's past medical history included grade one hypertension for ~3 years and cerebral infarction ~2 years previously. On admission, physical examination revealed that no enlarged superficial lymph nodes were palpable and there was no hepatosplenomegaly. A full blood count revealed that had a hemoglobin level of 91 g/l (normal range, 115-150 g/l), a white blood cell count of $5.45 \times 10^9/l$ (normal range, $3.5-9.5 \times 10^9/l$), 55.2% neutrophils (normal range, 40-75%), 27.2% lymphocytes (normal range, 20-50%), 13.8% monocytes (normal range, 3-10%), 3.1% eosinophils (normal range, 0.4-8%), 0.7% basophils (normal range, 0-1%), and a platelet count of $449 \times 10^9/l$ (normal range, $125-350 \times 10^9/l$). A biochemical profile revealed a potassium level of 2.8 mmol/l (normal range, 3.5-5.3 mmol/l), a sodium level of 138 mmol/l (normal range, 137-147 mmol/l), an albumin level of 33.7 g/l (normal range, 40-55 g/l), a uric acid level of 558 $\mu\text{mol/l}$ (normal range, 155-357 $\mu\text{mol/l}$), triglyceride levels of 2.13 mmol/l (normal range, 0-1.7 mmol/l), low density lipoprotein levels of 3.79 mmol/l (normal range, 0-3.64 mmol/l) and high density lipoprotein levels of 0.78 mmol/l (normal range, 0.91-1.55 mmol/l). Aldosterone, cortisol, catecholamines and results of other tests were normal. Abdominal ultrasound examination revealed a retroperitoneal tumor, and computed tomography (CT) scanning revealed that a mass of 132x119x101 mm on the left adrenal gland and a mass of 53x27 mm on the right adrenal gland without other structural abnormalities (Fig. 1). Following percutaneous biopsy of the left adrenal gland, histopathological examination revealed the presence of diffuse large B-cell lymphoma (Fig. 2) positive for CD20, CD5, LCA, Mnm1, Bcl-6, C-Myc and Ki-67 staining, with a proliferative index of >98%. Immunostains for cyclin D1, CD3, CD10, CD56, S-100, Cg A, CK, CK-L and Syn

Correspondence to: Professor Yongqing Lai, Department of Urology, Peking University Shenzhen Hospital, 1120 Lianhua Road, Shenzhen, Guangdong 518036, P.R. China
E-mail: yqlord@163.com

*Contributed equally

Key words: primary adrenal lymphoma, adrenal gland neoplasm, non-Hodgkin lymphoma, diffuse large B-cell lymphoma

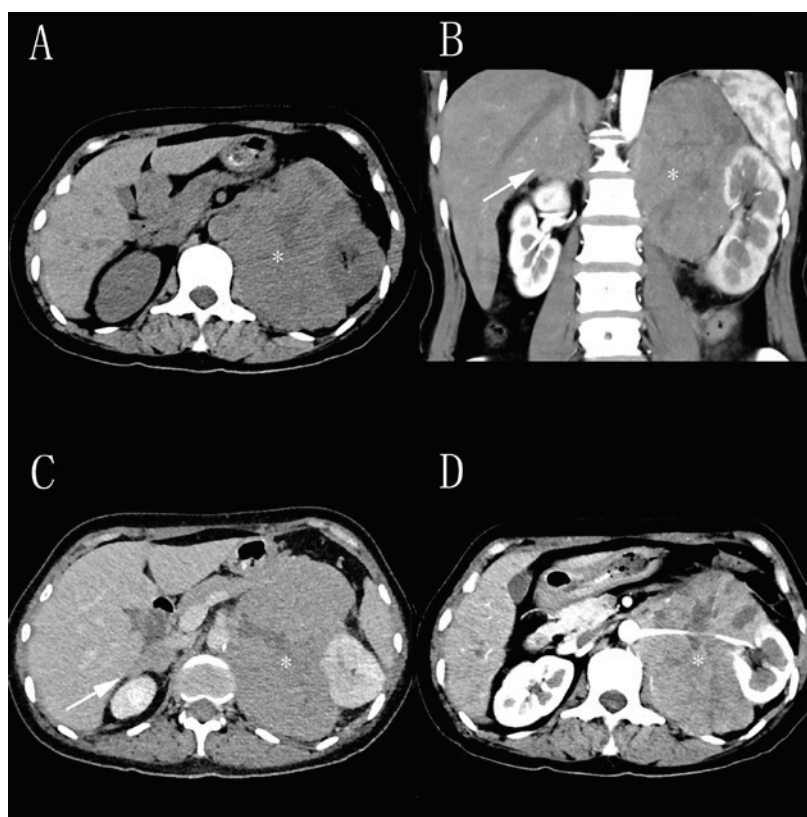


Figure 1. Computed tomography images of adrenal masses prior to (A) and following (B-D) intravenous administration of contrast material. It revealed a mass of 132x119x101 mm on the left adrenal gland (asterisk) and a mass of 53x27 mm on the right adrenal gland (arrow).

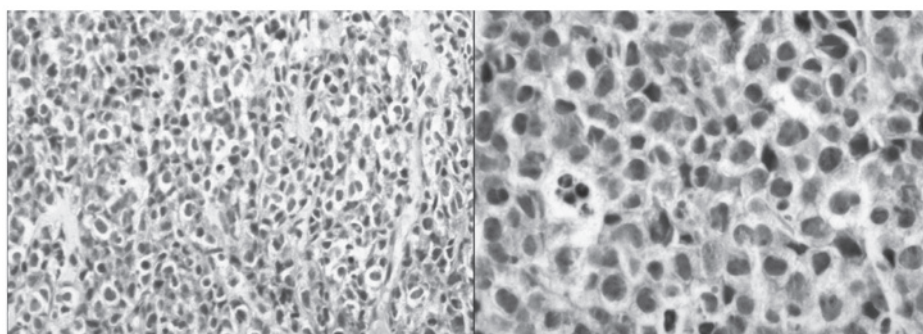


Figure 2. Microscopy revealed diffuse large lymphoid cells following percutaneous biopsy of the left adrenal gland (H&E staining; left panel, magnification x100; right panel, x400).

were negative. The patient requested to leave hospital without surgery, chemotherapy or radiotherapy.

Discussion

PAL without any other extra-adrenal involvement is a rare subtype of extranodal non-Hodgkin lymphoma, with only ~100 cases reported in the previous medical literature (5). PAL typically occurs in elderly and male, and ~70% of cases are bilateral (4,7,8). According to previous studies, the male to female ratio is 7:1 and the average age at diagnosis is 70 years old (9-11). In the present case, CT revealed no other lesions except those detected in the bilateral adrenal glands.

The exact pathogenesis of PAL remains to be established; however, multifactorial associations have been described,

including autoimmune-associated infections, immune dysfunction, originating from hematopoietic tissue resting within adrenal glands, Epstein-Barr virus infection and mutations in the p53 and c-kit genes (3,12,13). For example, Epstein-Barr virus serves a role in lymphoma formation through lymphoid infiltration into the adrenal glands, which lack lymphoid tissue (3).

The diagnosis of PAL is typically challenging to perform due to its nonspecific clinical manifestation and uncommon presentations, which include vague abdominal pain, anemia, weight loss, unexplained fever, hypercalcemia, thrombocytopenia and adrenal insufficiency, some of which were present in the current patient (14). In addition, obvious clinical manifestations tend to appear when >90% of the adrenal gland is damaged (6). Various adrenal gland enlargement sizes have been

reported, ranging from 4-17 cm (15). Nevertheless, there is no correlation between tumor size and adrenal hypofunction (7). DLBCL is the predominant histological subtype, which represents ~70% of PAL cases, whereas the T-immunophenotype makes up ~10% of cases (16-19). Ultrasound-guided biopsy is recommended for the differential diagnosis following the identification of low density of adrenal glands on CT scan images, and immunohistochemical examination further confirms the diagnosis and prognosis. The recommended treatment regimen for PAL is R-CHOP (rituximab, cyclophosphamide, doxorubicin, vincristine and prednisone), a classical chemotherapy regimen (20), with chemotherapy being the typical treatment. It has been reported that surgery is not recommended for treatment (21). This disease appears to have a poor prognosis, and the median survival of patients with PAL is reported to be ~1 year (22). There are certain factors effecting prognosis, such as age, tumor size, lactate dehydrogenase levels and bilateral involvement.

In conclusion, bilateral primary adrenal diffuse large B cell lymphoma is a rare entity. PAL with poor prognosis must be diagnosed at an early stage to potentially improve survival rates.

Acknowledgements

The present study was supported by the National Natural Science Foundation of China (grant no. 81101922), Science and Technology Development Fund Project of Shenzhen (grant nos. JCYJ20130402114702124 and JCYJ20150403091443329) and the fund of Guangdong Key medical subject.

References

- Mozos A, Ye H, Chuang WY, Chu JS, Huang WT, Chen HK, Hsu YH, Bacon CM, Du MQ, Campo E and Chuang SS: Most primary adrenal lymphomas are diffuse large B-cell lymphomas with non-germinal center B-cell phenotype, BCL6 gene rearrangement and poor prognosis. *Mod Pathol* 22: 1210-1217, 2009.
- Hsu CW, Ho CL, Sheu WH, Harn HJ and Chao TY: Adrenal insufficiency caused by primary aggressive non-Hodgkin's lymphoma of bilateral adrenal glands: Report of a case and literature review. *Ann Hematol* 78: 151-154, 1999.
- Grigg AP and Connors JM: Primary adrenal lymphoma. *Clin Lymphoma* 4: 154-160, 2003.
- Erçolak V, Kara O, Günaldı M, Usul Afşar C, Bozkurt Duman B, Açıkalın A, Ergin M and Erdoğan S: Bilateral primary adrenal non-hodgkin lymphoma. *Türk J Haematol* 31: 205-206, 2014.
- De Miguel Sánchez C, Ruiz L, González JL and Hernández JL: Acute adrenal insufficiency secondary to bilateral adrenal B-cell lymphoma: A case report and review of the literature. *Ecancermedicalscience* 10: 634, 2016.
- Ezer A, Parlakgümüş A, Kocer NE, Colakoğlu T, Nursal GN and Yildirim S: Primary adrenal non-Hodgkin's lymphoma: Report of two cases. *Türk J Gastroenterol* 22: 643-647, 2011.
- Wang J, Sun NC, Renslo R, Chuang CC, Tabbarah HJ, Barajas L and French SW: Clinically silent primary adrenal lymphoma: A case report and review of the literature. *Am J Hematol* 58: 130-136, 1998.
- Aziz SA, Laway BA, Rangreze I, Lone MI and Ahmad SN: Primary adrenal lymphoma: Differential involvement with varying adrenal function. *Indian J Endocrinol Metab* 15: 220-223, 2011.
- Lee KS, Chung YS, Park KH, Kim HS and Kim HM: A case of primary bilateral adrenal lymphoma with partial adrenal insufficiency. *Yonsei Med J* 40: 297-300, 1999.
- Dahami Z, Debbagh A, Dakir M, Hafiani M, Joual A, Bennani S, el Mrini M and Benjelloun S: Phenotype B primitive adrenal lymphoma, diagnosed by percutaneous aspiration biopsy. *Ann Urol (Paris)* 35: 22-25, 2001 (In French).
- Wang JP, Sun HR, Li YJ, Bai RJ and Gao S: Imaging features of primary adrenal lymphoma. *Chin Med J (Engl)* 122: 2516-2520, 2009.
- Ohsawa M, Tomita Y, Hashimoto M, Yasunaga Y, Kanno H and Aozasa K: Malignant lymphoma of the adrenal gland: Its possible correlation with the Epstein-Barr virus. *Mod Pathol* 9: 534-543, 1996.
- Padhi S and Sahoo J: Primary adrenal non Hodgkin lymphoma: Changing trends. *Türk J Gastroenterol* 26: 85-86, 2015.
- Ozimek A, Diebold J, Linke R, Heyn J, Hallfeldt K and Mussack T: Bilateral primary adrenal non-Hodgkin's lymphoma and primary adrenocortical carcinoma-review of the literature preoperative differentiation of adrenal tumors. *Endocr J* 55: 625-638, 2008.
- Kacem K, Zriba S, Lakhal RB, Bouteraa W, Aissaoui L, Amor RB, Abdennebi YB, Ali ZB, Abid HB and Meddeb B: Primary adrenal lymphoma. *Türk J Haematol* 31: 188-191, 2014.
- Li Y, Sun H, Gao S and Bai R: Primary bilateral adrenal lymphoma: 2 case reports. *J Comput Assist Tomogr* 30: 791-793, 2006.
- Libé R, Giavoli C, Barbetta L, Dall'Asta C, Passini E, Buffa R, Beck-Peccoz P and Ambrosi B: A primary adrenal non-Hodgkin's lymphoma presenting as an incidental adrenal mass. *Exp Clin Endocrinol Diabetes* 114: 140-144, 2006.
- Mantzios G, Tsigotis P, Veliou F, Boutsikakis I, Petraki L, Kolovos J, Papageorgiou S and Robos Y: Primary adrenal lymphoma presenting as Addison's disease: Case report and review of the literature. *Ann Hematol* 83: 460-463, 2004.
- Rashidi A and Fisher SI: Primary adrenal lymphoma: A systematic review. *Ann Hematol* 92: 1583-1593, 2013.
- Kim YR, Kim JS, Min YH, Hyunyon D, Shin HJ, Mun YC, Park Y, Do YR, Jeong SH, Park JS, *et al*: Prognostic factors in primary diffuse large B-cell lymphoma of adrenal gland treated with rituximab-CHOP chemotherapy from the consortium for improving survival of lymphoma (CISL). *J Hematol Oncol* 5: 49, 2012.
- Bouchikhi AA, Tazi MF, Amiroune D, Mellas S, El Ammari J, Khallouk A, El Fassi MJ and Farih MH: Primary bilateral Non-Hodgkin's lymphoma of the adrenal gland: A case report. *Case Rep Urol* 2012: 325675, 2012.
- Horiguchi K, Hashimoto K, Hashizume M, Masuo T, Suto M, Okajo J, Handa H, Kaneko Y, Yokoo H, Sasaki A, *et al*: Primary bilateral adrenal diffuse large B-cell lymphoma demonstrating adrenal failure. *Intern Med* 49: 2241-2246, 2010.