

Reversible intrahepatic cholestasis in metastatic prostate cancer: An uncommon paraneoplastic syndrome

MUNVEER S. BHANGO¹, BRIAN CHENG², GREGORY P. BOTTA¹,
PHATARAPORN THORSON³ and MICHAEL P. KOSTY¹

¹Division of Hematology-Oncology, Departments of ²Internal Medicine and

³Pathology, Scripps Clinic, La Jolla, CA 92037, USA

Received October 2, 2017; Accepted December 1, 2017

DOI: 10.3892/mco.2018.1564

Abstract. As with other genitourinary malignancies, a variety of paraneoplastic syndromes have been revealed to occur in patients with prostate cancer. Stauffer's Syndrome is a well-described clinical syndrome which manifests via intrahepatic cholestasis in patients with renal cell carcinoma. Less common is intrahepatic cholestasis occurring in association with prostate cancer. The current case report discusses a 67-year-old man presenting with liver failure secondary to intrahepatic cholestasis co-existing with metastatic prostate adenocarcinoma. The patient's liver failure completely resolved with androgen-deprivation therapy suggesting an association between these two entities. The case report evaluates existing literature on this uncommon syndrome including the clinical presentation, natural history, and potential pathophysiology.

Introduction

Cholestatic jaundice associated with malignancy typically occurs as a result of obstruction of the bile ducts or widespread liver metastases. Reversible cholestasis without evidence of biliary obstruction has been reported to occur in association with a variety of malignancies, most notably Stauffer's Syndrome in renal cell carcinoma. Intrahepatic cholestasis occurring in the setting of advanced prostate adenocarcinoma has less commonly been described with the first case reported in 1977 (1). Furthermore, the pathogenesis of this syndrome remains poorly understood. We present a case of patient with newly diagnosed metastatic prostate adenocarcinoma associated with severe liver failure secondary to intrahepatic cholestasis.

Case report

A 67 year old man with no significant past medical history presented to his primary care physician with several weeks of progressive jaundice, pruritus, dark urine, and unintentional weight loss. Laboratory workup revealed AST of 216 U/l (normal, 15-37), ALT 234 U/l (normal, 16-63), Alkaline phosphatase 988 U/l (normal 38-126), and total bilirubin of 26.3 mg/dl (0.1-1.2) with direct bilirubin of 22.5 (0.0-0.3).

Given these abnormalities a magnetic resonance imaging (MRI)-cholangiopancreatography (MRCP) of the abdomen (Fig. 1) was ordered which revealed a normal liver without any evidence biliary obstruction. Several lytic lesions of the bone were incidentally discovered concerning for metastatic disease. Given the unexplained osseous abnormalities, a PSA was ordered which was significantly elevated at 4,130 ng/ml (normal 0-4.5). CT-guided core needle biopsy of one of the bony lesions confirmed metastatic adenocarcinoma strongly positive for PSA and NKX3.1 (Fig. 2). The clinical presentation, laboratory abnormalities, and pathology findings were consistent with metastatic prostate carcinoma. Bone scan (Fig. 3) confirmed the presence of widespread osseous metastatic disease.

The patient was started on combined androgen deprivation therapy with LupronDepot (Leuprolide acetate for depot suspension, AbbVie Inc., North Chicago, IL, USA) 22.5 mg subcutaneously once every three months and Casodex (Bicalutamide, Wilmington, DE, USA) 50 mg orally once daily. The patient clinically responded rapidly soon after initiation of therapy. His PSA declined to 863 ng/ml four weeks after therapy initiation and subsequently 408 ng/ml by eight weeks (Fig. 4). Conjugated bilirubin and liver function abnormalities normalized completely after four weeks of androgen deprivation. The patient is maintained on depo-leuprolide therapy six months after diagnosis and remains asymptomatic from the standpoint of his cancer. Informed consent for this report was obtained from the patient.

Discussion

Cholestasis in the setting of malignancy occurs from a variety of mechanisms including external compression of the biliary system, widespread hepatic infiltration, or metastatic disease.

Correspondence to: Dr Munveer S. Bhangoo, Division of Hematology-Oncology, Scripps Clinic, 10666 N Torrey Pines Road, La Jolla, CA 92037, USA

E-mail: bhangoo.munveer@scrippshealth.org

Key words: prostate cancer, paraneoplastic intrahepatic cholestasis, jaundice

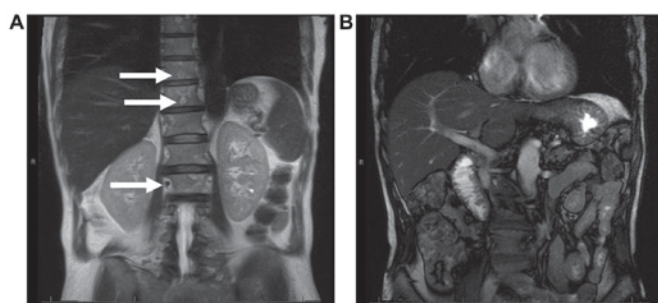


Figure 1. MRI of Abdomen demonstrating (A) diffuse skeletal metastasis, (B) normal liver without evidence of biliary obstruction.

Less commonly, reversible cholestasis in the absence of biliary obstruction has been well-described as a paraneoplastic syndrome. In this case, the possibility of extrinsic compression causing cholestasis was excluded by multiple imaging techniques (ultrasound, CT scan, as well as MRI/MRCP). Furthermore, systemic conditions causing intrahepatic cholestasis such drug toxicity, infections (viral hepatitis, HIV), primary biliary cirrhosis, primary sclerosing cholangitis were entertained. These possibilities were excluded by a careful clinical history and broad laboratory workup. Given the incidental finding of diffuse osseous metastasis that was confirmed to be prostate adenocarcinoma on biopsy, patient was started on anti-androgen therapy and GnRH agonist for treatment. Ultimately, the temporal association between the treatment of prostate cancer and resolution of the patient's liver dysfunction argues strongly for a diagnosis of a paraneoplastic syndrome.

Paraneoplastic syndromes constitute a heterogeneous group of disorders that occur as a result of malignancy independent of mass effect or direct invasion (2). These disorders are felt to occur as a result of humoral factors (e.g., cytokines or hormones) elaborated by tumors. An additional mechanism involves activation of the immune system against tumor antigens (3).

The first report of paraneoplastic liver dysfunction associated with malignancy was described in association with renal cell carcinoma (4). This syndrome is characterized by elevated LFTs in a cholestatic pattern in the absence of external compression or widespread liver metastases. Liver pathology review may range from normal histologic findings to varying degrees of reactive hepatitis (5).

Paraneoplastic intrahepatic cholestasis has been described in several other malignancies including soft tissue sarcoma, medullary thyroid cancer, renal sarcoma, T-cell lymphoma, chronic lymphocytic leukemia, Hodgkin's disease (6-12). Although uncommon, reversible hepatic dysfunction in prostate cancer has been described in nine published cases (Table I) (1,13-20). All reported cases occurred in patients with metastatic disease. Including the patient reported here, 90% of patients experienced improvement in liver dysfunction and jaundice with treatment of the prostate cancer. Patients presenting with intrahepatic cholestasis appear to do as well as other patients diagnosed with metastatic prostate cancer. In fact, 70% of reported cases presenting with intrahepatic cholestasis were alive at one year compared with 71% of patients diagnosed with metastatic prostate adenocarcinoma

Table I. Cases reviewed from literature detailing cholestasis reversal with prostate cancer treatment. Ten cases were analyzed from the literature and compared in terms of patient clinical characteristics, laboratory data, and outcome over a 42 year period of time.

First author	Age	Stage	PSA (ng/ml)	Total bilirubin (mg/dl)	Management	Liver function test outcome	Clinical followup (Mos.)	(Refs.)
Bhangoo, 2017	67	Metastatic	4,130	26.3	Leuprolide, bicalutamide	Improved	Remission (6)	Present study (1)
Reddy, 1977	57	Metastatic		6.2	Radiation, diethylstilbestrol	Transiently improved	Deceased (32)	(13)
Karakolios 2003	72	Metastatic	150	18.1	Flutamide, leuprolide	Resolved	Remission (9)	(14)
Bloch, 1992	69	Metastatic		10.6	ADT, bilateral orchiectomy	Resolved	Deceased (48)	(15)
Cole, 2000	78	Metastatic	9,996	6.56	Leuprolide, bicalutamide	Resolved	Remission (3)	(16)
Nguyen, 2011	51	Metastatic	556	19	Goserelin, bicalutamide	Improved	Remission (6)	(17)
Kuramoto, 2013	75	Metastatic	9,862	17	Leuprolide, bicalutamide	Resolved	Remission (12)	(18)
Ben-Ishay, 1975	58	Metastatic		13	Stilbestrol, bilateral orchiectomy	Resolved	Remission (24)	(19)
Koruk, 2004	77	Metastatic	100	10	Goserelin, bicalutamide	Resolved	Remission (6)	(20)
Shah, 2006	64	Metastatic	956	132	Goserelin, cyproterone	No response	Deceased (6)	

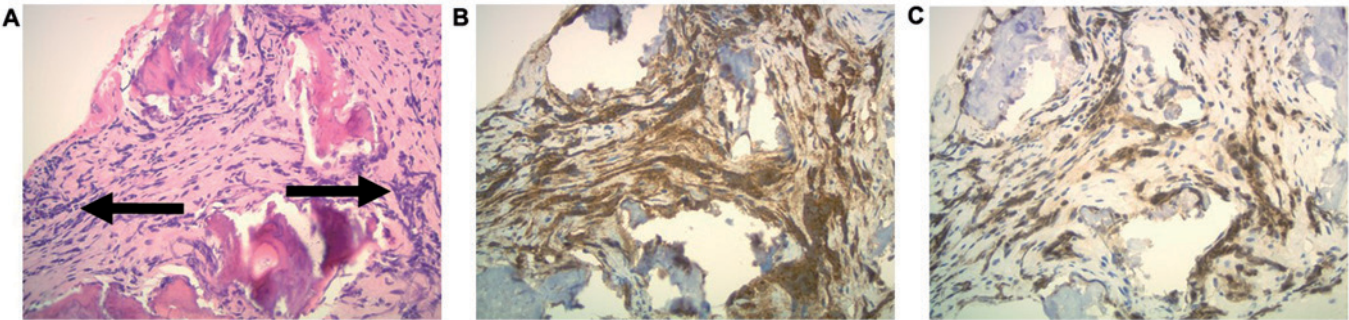


Figure 2. Pathologic findings from bone biopsy. Photomicrograph demonstrating tumor cells within fibrotic medullary space of bone (hematoxylin and eosin stain), x40 magnification (A). Immunohistochemical staining revealing positive expression for PSA (B) and NKX3.1 (C) consistent with prostatic adenocarcinoma.

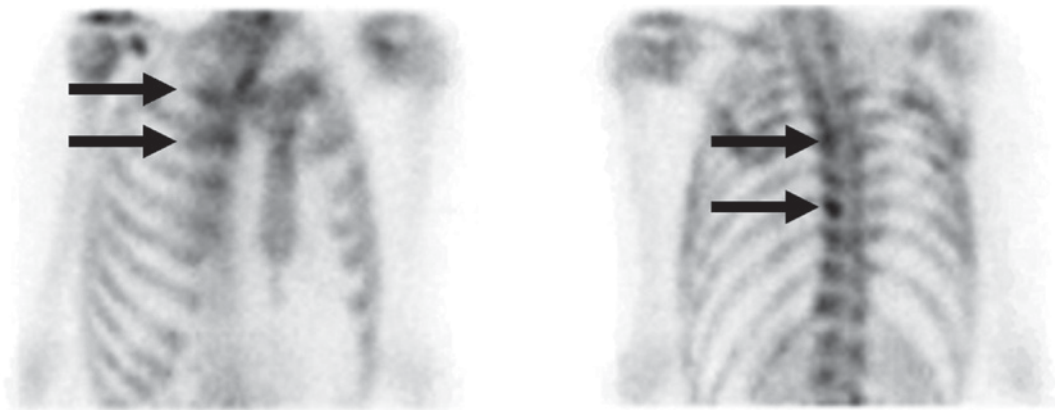


Figure 3. Bone scan consistent with widespread osseous metastatic disease.

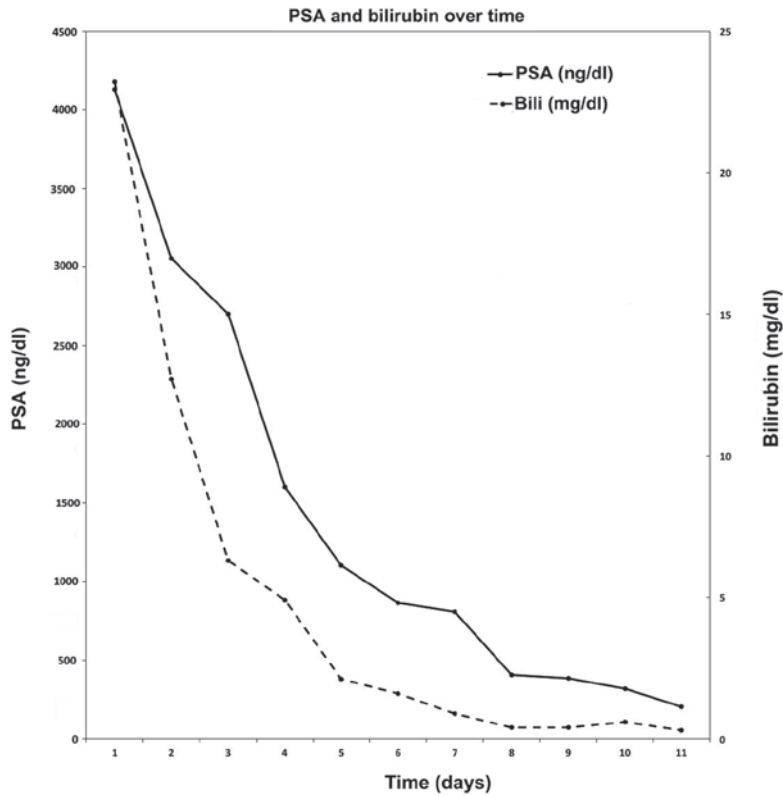


Figure 4. Associated reduction in cholestasis following hormone blockade treatment in metastatic prostate cancer. After initiation of treatment (black arrow), the patient's PSA and Bilirubin were both reduced in a linear fashion after 7 weeks of leuprolide and bicalutamide therapy.

per SEER analysis (21). This suggests that hepatic dysfunction as a presenting sign may not necessarily be a poor prognostic feature.

The precise mechanism of disease is not well understood. One putative explanation involves interleukin 6 (IL-6) which appears to be involved in paraneoplastic cholestasis associated with renal cell carcinoma. In a study of 119 patient with metastatic renal cell carcinoma, patients with intrahepatic cholestasis were found to have significantly elevated IL-6 levels compared with patients without this syndrome (22). The association of IL-6 and cholestasis may be mediated by a systemic inflammation as laboratory markers including C-reactive protein (CRP) and haptoglobin which are commonly elevated (22). Pro-inflammatory cytokines inhibit expression of the hepatobiliary transporter gene expression possibly accounting for impaired biliary outflow (23). The association of this condition with IL-6 remains speculative and other humoral mediators have also been proposed (18). Increased levels of IL-6 have similarly been reported among prostate cancer patients with liver dysfunction suggesting a potential association in this paraneoplastic syndrome (16,17). Future directions to elucidate the molecular mechanisms driving this paraneoplastic syndrome includes cytokine profiling of serum from affected patients. Whether or not increased levels of IL-6 correlate with liver dysfunction in prostate cancer is unknown and warrants further investigation.

The case described above is one of few documented cases where cholestasis occurred as a result of paraneoplastic syndrome from prostate cancer without evidence of hepatic infiltration, metastatic disease, or tumor compression. Our patient's cholestasis resolved with the treatment of his prostate cancer, which is consistent clinical feature of this disease.

References

- Reddy A, Grosberg SJ and Wpanick S: Intermittent cholestatic jaundice and nonmetastatic prostatic carcinoma. *Arch Intern Med* 137: 1616-1618, 1977.
- Darnell RB and Posner JB: Paraneoplastic syndromes. Oxford Uni Press 482, 2011.
- Pelosof LC and Gerber DE: Paraneoplastic syndromes: An approach to diagnosis and treatment. *Mayo Clin Proc* 85: 838-854, 2010.
- Stauffer M: Nephrogenic hepatomegaly. *Gastroenterol* 40: 694, 1961.
- Dancygier H: Clinical hepatology: Principles and practice of hepatobiliary diseases: Volume 2. Springer, 2010.
- Perisic VN, Howard ER, Mihailovic T, Vujanic G, Milovanovic D and Ivanovski P: Cholestasis caused by biliary botryoid sarcoma. *Eur J Pediatr Surg* 1: 242-243, 1991.
- Tiede DJ, Tefferi A, Kochhar R, Thompson GB and Hay ID: Paraneoplastic cholestasis and hypercoagulability associated with medullary thyroid carcinoma. Resolution with tumor debulking. *Cancer* 73: 702-705, 1994.
- Patel KJ, Latif SU and de Calaca WM: An unusual presentation of precursor T cell lymphoblastic leukemia/lymphoma with cholestatic jaundice: Case report. *J Hematol Oncol* 2: 12, 2009.
- Alirhayim Z, Dyal H, Alarhayem A and Donthireddy V: Non-Hodgkin's lymphoma: A cause of paraneoplastic cholestasis. *BMJ Case Rep* 2013: pii: bcr2013009714, 2013.
- Fraisse TC, Damigny A, di Castri A, de Wazières B and Fourcade J: Leiomyosarcoma and Stauffer syndrome. *Rev Med Interne* 22: 1116-1118, 2001 (In French).
- Barta SK, Yahalom J, Shia J and Hamlin PA: Idiopathic cholestasis as a paraneoplastic phenomenon in Hodgkin's lymphoma. *Clin Lymphoma Myeloma* 7: 77-82, 2006.
- Pandey J and Bhowmik KT: Chronic lymphocytic leukemia presenting as jaundice. *Indian J Gastroenterol* 17: 28, 1998.
- Karakolios A, Kasapis C, Kallinikidis T, Kalpidis P and Grigoriadis N: Cholestatic jaundice as a paraneoplastic manifestation of prostate adenocarcinoma. *Clin Gastroenterol Hepatol* 1: 480-483, 2003.
- Bloch WE and Block NL: Metastatic prostate cancer presenting as obstructive jaundice. *Urology* 40: 456-457, 1992.
- Cole A, Mendelblatt D, Aguayo J, Mathew A, Martin E and Vesely DL: Metastatic prostate cancer (with prostate-specific antigen of 9996) presenting as obstructive jaundice. *Am J Med Sci* 319: 118-122, 2000.
- Nguyen V, Gurney H and van der Poorten D: Paraneoplastic hepatic dysfunction in metastatic prostate cancer: The role of cytokine dysregulation. *J Clin Oncol* 29: e21-e23, 2011.
- Kuramoto T, Senzaki H, Koike H, Yamagiwa K, Tamura S, Fujimoto T and Inagaki T: Cholestatic jaundice as a paraneoplastic manifestation of prostate cancer. *Case Rep Urol* 2013: 303727, 2013.
- Ben-Ishay D, Slavin S, Levij IS and Eliakim M: Obstructive jaundice associated with carcinoma of the prostate. *Isr J Med Sci* 11: 838-844, 1975.
- Koruk M, Büyükberber M, Savaş C and Kadayifçi A: Paraneoplastic cholestasis associated with prostate carcinoma. *Turkish J Gastroenterol* 15: 53-55, 2004.
- Shah SH: Paraneoplastic liver dysfunction in prostate cancer. *J Pain Symptom Manage* 32: 511-513, 2006.
- National Cancer Institute: Cancer of the prostate-SEER stat fact sheets, 2016.
- Blay JY, Rossi JF, Wijdenes J, Menetrier-Caux C, Schemann S, Négrier S, Philip T and Favrot M: Role of interleukin-6 in the paraneoplastic inflammatory syndrome associated with renal-cell carcinoma. *Int J Cancer* 72: 424-430, 1997.
- Trauner M, Fickert P and Stauber RE: Inflammation-induced cholestasis. *J Gastroenterol Hepatol* 14: 946-959, 1999.