SPANDIDOS PUBLICATIONS

MOLECULAR AND CLINICAL ONCOLOGY 8: 582-586, 2018

Squamous cell carcinoma of the breast as a clinical diagnostic challenge

KATARZYNA JAKUBOWSKA[1], LUIZA KAŃCZUGA-KODA[1], WOJCIECH KISIELEWSKI[2], MARIUSZ KODA[3] and WALDEMAR FAMULSKI[1,2]

[1]Department of Pathomorphology, Comprehensive Cancer Center, 15-027 Białystok; Departments of [2]Medical Pathomorphology and [3]General Pathomorphology, Medical University of Białystok, 15-269 Białystok, Poland

Received September 17, 2017; Accepted December 14, 2017

DOI: 10.3892/mco.2018.1581

Abstract. Squamous cell carcinoma (SqCC) of the breast should be differentiated between the primary skin keratinizing squamous carcinoma and squamous metaplastic cancer. In the current study, the cases of two patients who were diagnosed with SqCC originated from skin and the breast were discussed. A fine-needle aspiration biopsy confirmed the presence of atypical squamous cells. In both cases, the microscopic examination of the surgical specimen revealed a malignant neoplasm differentiated into SqCC characterized by keratinizing cancer cells with abundant eosiphilic cytoplasm with large, hyperchromatic vesicular nuclei. Immunohistochemical studies showed negative for progesterone and estrogen receptors and human epidermal growth factor receptor 2. Moreover, negative expression of cytokeratin 7 and 20 was confirmed. The diagnosis of the both tumors was established based on the detailed analysis of clinical, macroscopical and microscopical information. SqCC localized in the breast is a great diagnostic challenge in pathomorphology and more attention should be paid for analysis of such lesions in daily practice.

Introduction

Squamous cell carcinoma (SqCC) is a malignant neoplasm of epidermal keratinocytes that arises most commonly on the skin and organs lined with squamous cells. Squamous cell carcinoma is a rare form of metaplastic carcinoma in breast that accounts <0.1% (1). The precursor of pure squamous carcinoma is a benign squamous metaplasia that occurs in the epithelium of cysts, fibroadenomas ana phyllodes tumors. It can be also associated with ductal and lobular hyperplasia or papillomas. Recent studies confirmed that benign squamous metaplasia of ductal and lobular epithelial cells can be linked with fat necrosis and infracted ademonas. Squamous cell carcinoma should be differentiated between lesions of keratinizing squamous carcinoma and squamous metaplasia associated to mammary carcinoma (2). The characteristic features of metaplastic cell carcinoma include: i) primary carcinoma without other neoplastic components such as ductal or mesenchymal elements, ii) the tumor origin is independent of the overlying skin and nipple and iii) absence of primary epidermoid tumors present in other site (oral cavity, bronchus, esophagus, bladder, cervix ect.) (3). However, squamous metaplastic carcinoma should be also differentiated with pure squamous cell carcinoma of skin in the breast. The extensive infiltrate of squamous cancer cells to the skin can make it difficult to confirm the cutaneous origin of tumor and exclude the presence of malignant metaplastic changes as a primary breast. In the present study, cases of cutaneous squamous cell carcinoma and primary metaplastic squamous cell carcinoma of the breast are described. To our knowledge, such cases are great diagnostic challenge in pathomorphology and should be carefully analyzed in daily practice.

The present study was performed in conformity with the Declaration of Helsinki for Human Experimentation and the protocol was approved by the Bioethics Committee of the Medical University of Bialystok. Written informed consent was obtained from both participants.

Case report

Case 1

History. A 72-year-old female was admitted to the Department of Surgical Oncology in Bialystok (Poland) for planned surgery. There was no family history of malignant neoplasms. Patient had used some medication against hypertension. She complained of abdominal pain with normal peristalsis and had normal stools. She was postmenopausal and had given birth to 3 children. Previously, the histological examination of the biopsy material, obtained during a fine-needle aspiration (FNA), confirmed the presence of the cancer cell infiltrate in the left breast (Fig. 1A). The description of preoperative, physical examination demonstrated a large mass with ulceration localized on the left breast. Tumor took the three quarters of the breast and raised several years.

Correspondence to: Dr Katarzyna Jakubowska, Department of Pathomorphology, Comprehensive Cancer Center, 12 Ogrodowa Street, 15-027 Białystok, Poland
E-mail: kathian@wp.pl

Key words: squamous cell carcinoma, metaplastic carcinoma, breast cancer

The skin and the nipple-areola complex were involved. The tumor was attached underlying chest wall. No abnormalities were observed in the opposite breast nor axilla. Local lymph nodes were not enlarged on palpation examination. Chest X-ray was performed preoperatively and demonstrated the heterogenic, rounded area of increased density, 1.3 cm diameter in size, located in the right supraclavival field of the left lung. In addition, diaphragm was normal. The preoperative blood parameters showed the low levels of red blood cells, hemoglobin and hematocrit and the increased levels of CA125 and CA15.3. Following normalization of anemia with the concentrate of red blood cells, patient was qualified for scheduled surgery. Due to large size tumor that infiltrated the chest wall, the left radical mastectomy was performed according to the Halsted's method (1). The surgical procedure included the removal of the breast tumor with a greater pectoral muscle and axilla with local lymph nodes. The left breast was reconstructed with the latissimus dorsi musculocutaneous flap. There was no postoperative morbidity. The clinical staging was T4 N0 MX.

Histopathology. Macroscopically, the postoperative formalin-fixed material of the left breast 17.0x16.5 cm in size, showed a huge, ulcerative tumor with cauliflower-like appearance, 16.8x16.2 cm in size, of gray-brown surface with a narrow margin at the periphery of the skin without the presence of nipple. On cross-sections, tumor was solid, gray-brown color with gray-white foci of necrosis, coming near this deep incision line. Fourteen local lymph nodes were dissected with no evidence of metastases. The biggest lymph node was 3.1x1.8 cm in size. Optimal surgical margins were obtained (Fig. 2A).

The microscopic examination of the surgical specimen revealed a moderately differentiated (G2) squamous cell carcinoma according to WHO Classification of the Skin Tumours (4). Cancer cells have abundant eosiphilic cytoplasm with large vesicular nucleus. The prominent intracellular brigdes, central keratinization and pearl formation were observed. SqCC does not infiltrate along nerve sheaths and lymphovascular vessels. Cancer cells proliferated from the stratified squamous epithelium covering the breast into 2.5 cm deeper layers of the organ. No other primary site and metastatic disease to breast were ruled out (Fig. 3A and B). Immunohistochemical analysis confirmed negative nuclear expression of progesterone and estrogen receptors, and HER2. Moreover, we observed a positive membrane reaction of adhesion protein-E-cadherin. The diagnosis of the tumor was established as triple negative SqCC of breast skin with moderate proliferation index (Ki67 positive in 20% cancer cells).

Follow-up. Patient was discharged home in good general condition and received five courses of chemotherapy with Taxotere + Cisplatin (110 mg i.v.). After 1.5 month following the surgery, patient visited the Surgical Outpatient Clinic and was directed to USG of abdomen and retroperitoneal space, and the FNA of right breast. Imaging studies confirmed the presence of a heterogeneous good well-isolated area with dimensions 27.0x22.0 mm, probably metastatic changes. The material obtained from the FNA cytology of right breast showed the presence of poorly differentiated cancer cells, probably originated from squamous cancer. The change was treated as a distant metastases. One month later, imaging studies of PET-CT confirmed an active metabolic process in the left side of nasopharynx. Patient was qualified for surgery under local anesthesia. Macroscopically, it was visualized a smooth mucosa of the nasopharynx without significant changes. The histopathological study of the nasopharynx did not show a presence of cancer cells but only morphological features of chronic inflammation markers. Another CT scan showed numerous secondary changes within both lungs, the largest diameter of 35.0 mm and a single focus in the segment V of the liver diameter of 24.0 mm. We did not detect secondary changes in the skeletal system. Disease progression of cancer was revealed.

Case 2

History. A 59-years-old woman evaluated in our hospital for recent onset of pain and tenderness in the left breast. Physical examination revealed a palpable well circumscribed mass in the left upper lateral quadrant. The right breast appeared normal. There was no evidence of supraclavicular or axillary lympadenopathy. The overlying skin was unremarkable. An ultrasound examination of the left breast revealed a defined 3.0 cm mass with reduced central echogenicity, consistent with a cystic space. Mammography showed a round, high-density mass (without microcalcifications) with almost regular margins, measuring approximately 3.0 cm, which was classified as BIRADS 4. A fine-needle aspiration biopsy was performed and yielded 0.5 ml of white dense fluid material. Cytological preparations revealed markedly atypical squamous cells arranged in sheets, clusters and as a single cell as well as numerous neutrophils. Several cells were keratinized and some showed degenerative changes (Fig. 1B).

Histopathology. The patient had an ultrasound-guided core biopsy of the left breast mass at the local anesthesia. Patient underwent radical mastectomy with axillary lymph nodes dissection. Gross examination revealed a 6.0 cm tumor with central cystic space containing necrotic material (Fig. 2B). Microscopically, large polygonal cells with keratinizing eosinophilic cytoplasm were presented. Individual cells have abundant eosinophilic cytoplasm and hyperchromatic pleomorphic nuclei with abortive squamous pearl formation (Fig. 3C and D). Histopathological analysis revealed metaplastic carcinoma (a pure primary squamous cell carcinoma of the breast) according to WHO Classification of the Breast (2). The breast tumor profile was negative for estrogen receptors, progesterone receptors and HER2/neu expression.

Follow-up. Patient had adjuvant chemotherapy based on cisplatin and 5-fluorouracil. She had no evidence of recurrence 6 months after surgery.

Discussion

Squamous cell carcinoma is one of the most common skin cancer that was developed in association with prolonged exposure to sunlight. However, not all squamous cell cancers are directly related to UV radiation. They can grow in the shores of chronic ulcers, within the scars burn of skin or as a result

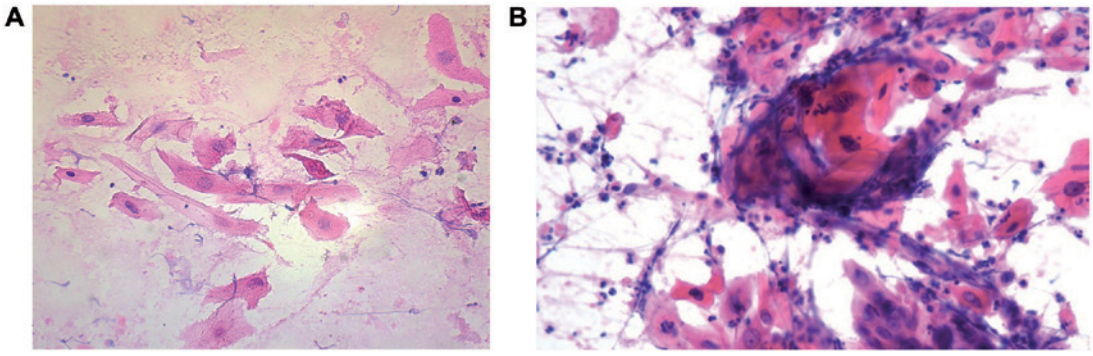

Figure 1. Fine-needle aspiration biopsy (FNA). Case 1: Cluster of atypical squamous cells (A). Case 2: Atypical squamous cells showed abundant dense keratinized cytoplasm (B).

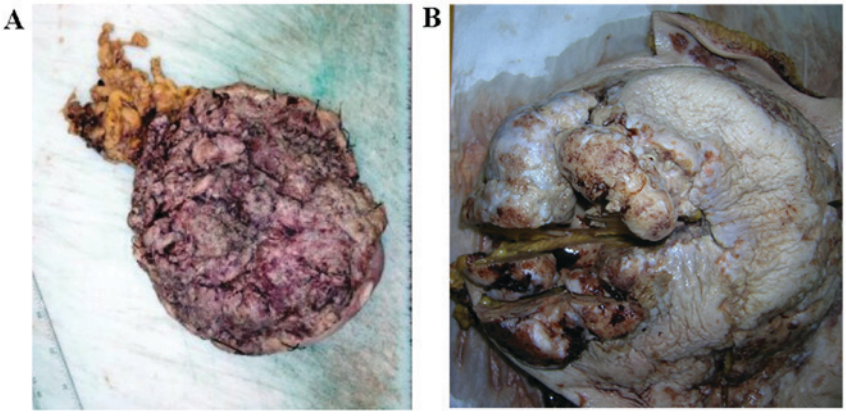

Figure 2. Macroscopy. Case 1: A huge, ulcerative tumor with cauliflower-like appearance, with enrolled nipple, covered the all left breast. On cross-section, there is gray-gray and gray-white tumor with necrotic foci (A). Case 2: Slightly delicate, solid, gray-white tumor, covering the middle part of the breast parenchyma (B).

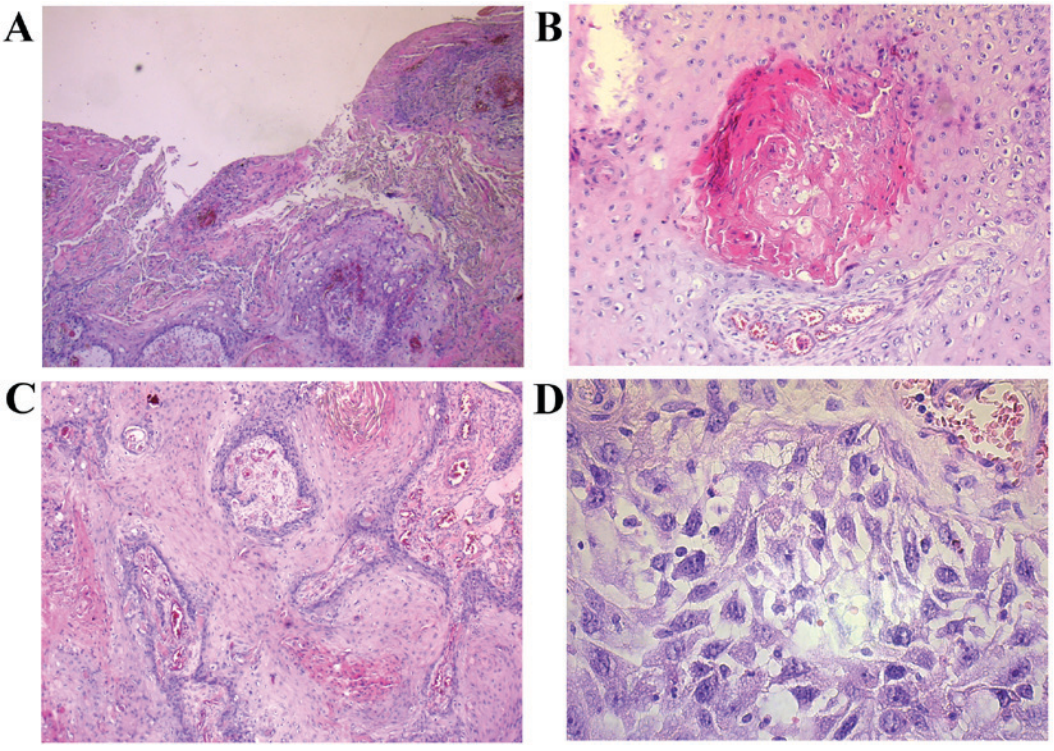

Figure 3. Histopathological findings. Case 1: Squamonus cancer cells have abundant eosiphilic cytoplasm with large vesicular nucleus in the main tumour mass (A). The central keratinization and pearl formation were showed (B). Case 2: Similar to case 1, there were large polygonal cells with keratinizing eosinophilic cytoplasm (C). Higher magnification of tumor shows intercellular bridges, indicative of squamous cell differentiation (D). (H&E stain; magnification x100, x200).

of damage to the epidermis the chemical or radiation therapy. Also patients with immune suppression have an increased risk of squamous cancer (4). We reported a very unusual location-skin overlying the breast in first case. To our knowledge, first patient described in our paper is the one third of cases of breast or axilla reported in the literature. Miranda *et al* (5) confirmed the presence of three small changes of SqCC in the axillary skin. Moreover, we noted histological type of metaplastic cancer of the breast, which probably evolved directly from glandular tubes or is developed in the basis of squamous metaplasia in second case (3). This type of breast carcinoma accounts for ~1% of all malignancies in this location and its presence was described in several reports in the literature (6-11). The incidence of PSqCC falls to 5-6 decade of life compared to SqCC of skin that occurred usually in patients aged above 70 years (12,13).

Squamous cell carcinoma of the skin develops in the form of initially small, hard lumps, often in the middle ulcers, modified necrotic or excessively keratinizing (4). The development of tumor takes years, as observed in our first case. The lesion was large, a diameter of 16,0 cm, and within the ulcerated surface. In evaluated tissue material, it was found a tumor ulcerous and necrotic surface with the presence of inflammatory granulation tissue. Macroscopically, tumor occupied the outer skin surface of the breast and nipple-areola complex. In contrast, metaplastic cancer of the breast formed tumors with rapid growth, involving several months (14,15). These lesions are accompanied by inflamed multicystes or abscesses in 50% of cases (16-18). In the second described case, the gross examination revealed the presence of grayish-white, solid tumor located in the middle part of the breast in size 6 cm. Tumor has a central cystic space containing necrotic material. The overlying skin was unremarkable. In both cases, we ruled out the presence of suspected cancer focuses in other locations.

The large size of the tumor and advanced process of necrosis caused a difficulty of confirmation whether macroscopic tumor derived from the squamous epithelium of the skin or are created in the basis of abnormal glandular epithelium metaplasia. First tumor was built with bands of moderately differentiated squamous cancer cells with large vesicular nucleus. We observed prominent intracellular bridges, central keratinization and pearl formation. SqCC does not infiltrate along nerve sheaths and lymphovascular vessels. Cancer cells proliferated from the stratified squamous epithelium covering the breast into deeper layers of the body. Morphological image of metaplastic breast cancer is very similar. They also may have focal anaplastic component or focal clear cell changes (19). Squamous cell carcinomas showed morphological similarity regardless of location. However, the differentiating feature of our case was the way of cancer spread. In the case of skin, we observed a cancer infiltration that was continuous and formed in 'icicles' from the skin into the tissue of the breast. Therefore, metaplastic cancer had irregular growth of squamous cell that creates cystic-solid tumor confined to the breast parenchyma.

Moreover, because of the similar changes in both histogenesis, we can not use immmunophenotype methods to differentiated cancer cells. Immunohistochemical analysis also does not allow to determine whether it is a primary lesion or metastatic one. In both of our cases, we recorded a positive expression of pancytokeratin which confirms the presence of cells differentiated towards squamous cell carcinoma. In case 1, the characteristics of immunophenotyping were: Cytokreatyna7 (-), cytokeratin 20 (-) and triple negative receptor status suggests that this lesion will probably not derive from the mammary gland. However, in the majority of metaplastic breast cancers also observed a lack of expression of estrogen, progesterone, and HER2 (17). A positive response to these antigens were reported in few percentage of cases (19,20). Only one of case described in literature was confirmed as a SqCC of breast with HER2-basal phenotype (21).

Treatment of squamous cell carcinoma of the skin and metaplastic breast cancer are depends mainly on the stage of the cancer. Typically, the patients are undergoing surgery in the first stage of therapy then adjuvant treatment such as radio- or chemotherapy was used (22-24). In our two cases, the total mastectomy was performed that included removing of breast with local lymph nodes. Chemotherapy was used as a second part of treatment. In SqCC case of skin, we recorded metastases located in the second breast after 1.5 months. In the following months, there was a further progression of the disease manifested by the presence of multiple metastatic lesions in the lungs and a single metastatic focus in the segment V of the liver. In the literature it has been shown that the risk of developing metastatic squamous cell carcinoma of the skin, which is accompanied by changes in sun-damaged (0.5%) is lower than in patients in places not exposed to sunlight (25). Moreover, the ability of squamous cancer cells of the skin metastasize is dependent on the depth of invasion, tumor size, and involvement of vascular and lymphatic vessels (26). In case 2, we did not notice relapse within 6 months after surgery. Time progression-free survival in patients with metaplastic cell carcinoma of the breast is 2-36 months (18,20,24). Overall survival after 2 years was 80%, and after 5 years of 35-67% (19,20,27). It has been shown that tumors with the presence of >10% of spindle cell component have a worse prognosis, however, the focal length of keratinization determines longer overall survival (27). It seems that despite of the similar morphology of cancer cells, the determination of the originality of the tumor may be important in identification of prognostic factors.

In conclusion, cutanous squamous cell carcinoma and metaplastic cell carcinoma of breast are extremely rare lesions that should be differentiated from primary squmanous cell carcinoma in this localization and should be treated with special clinician's and pathomorpgologist's attention. In our opinion, such cases are great diagnostic challenge in pathomorphology and should be more carefully analyzed in daily practice.

References

1. Hennessy BT, Krishnamurthy S, Giordano S, Buchholz TA, Kau SW, Duan Z, Valero V and Hortobagyi GN: Squamous cell carcinoma of the breast. J Clin Oncol 23: 7827-7835, 2005.
2. Tavassoli FA and Devilee P: Metaplastic carcinomas. In: Pathology and Genetics. Tumours of the Breast and Female Genital Organs. World Organization Classification of Tumors. IARC Press, Lyon, pp37-38, 2003.
3. Rosen PR: Chapter 21. Rosen's Breast Pathology. Lippincott-Raven, Philadelphia, New York, pp397-404, 1997.
4. Leboit PE, Burg G, Weedon D and Sarasin A: Squamous Cell Carcinoma. In: Pathology and Genetics. Skin Tumors. World Organization Classification of Tumors. IARC Press, Lyon, pp20-21, 2007.

5. Miranda BH, Malahias M, El-Said TF and Fahmy FS: Axillary skin malignancy: A rare breast cancer presentation. Ann Plast Surg 72: 513-514, 2014.
6. Badge SA, Gangane NM, Shivkumar VB and Sharma SM: Primary squamous cell carcinoma of the breast. Int J Appl Basic Med Res 4: 53-55, 2014.
7. Mitra B, Pal M, Debnath S, Paul B, Saha TN and Maiti A: Primary squamous cell carcinoma of breast with ipsilateral axillary lymph node metastasis: An unusual case. Int J Surg Case Rep 2: 194-197, 2011.
8. Flikweert ER, Hofstee M and Liem MS: Squamous cell carcinoma of the breast: A case report. World J Surg Oncol 6: 135, 2008.
9. Tsung SH: Primary pure squamous cell carcinoma of the breast might be sensitive to Cisplatin-based chemotherapy. Case Rep Oncol 5: 561-565, 2012.
10. Bhosale SJ, Kshirsagar AY, Deshmukh SJ, Jagtap SV and Langade YB: Squamous cell carcinoma of the breast. Am J Case Rep 14: 188-190, 2013.
11. Wang J, Zhang X, He J, Yang M, Tang J, Li X, Tang H and Xie X: Co-expression of EGFR and CK5/6 in primary squamous cell carcinoma of the breast. Med Oncol 31: 172, 2014.
12. Porzio R, Cordini C, Orsi N, Brigati F, Paties CT and Cavanna L: Primary squamous cell carcinoma of the breast after cured bilateral breast cancer. In Vivo 28: 1155-1158, 2014.
13. Mokhtar GA: Squamous cell carcinoma of the breast. Saudi Med J 30: 1346-1349, 2009.
14. Sharma R, Usmani S and Siegel R: Primary squamous cell carcinoma of breast in background of phyllodes tumor-a case report. Conn Med 73: 341-343, 2009.
15. Cichon P, Drucis K and Piotrkowski J: Primary squamous cell carcinoma of the breast-a case report. Pol Merkur Lekarski 38: 140-143, 2015 (In Polish).
16. Samuels TH, Miller NA, Manchul LA, DeFreitas G and Panzarella T: Squamous cell carcinoma of the breast. Can Assoc Radiol J 47: 177-182, 1996.
17. Salemis NS: Breast abscess as the initial manifestation of primary pure squamous cell carcinoma: A rare presentation and literature review. Breast Dis 33: 125-131, 2011.
18. Nair VJ, Kaushal V and Atri R: Pure squamous cell carcinoma of the breast presenting as a pyogenic abscess: A case report. Clin Breast Cancer 7: 713-715, 2007.
19. Liu J, Yu Y, Sun JY, He SS, Wang X, Yin J and Cao XC: Clinicopathologic characteristics and prognosis of primary squamous cell carcinoma of the breast. Breast Cancer Res Treat 149: 133-140, 2015.
20. Behranwala KA, Nasiri N, Abdullah N, Trott PA and Gui GP: Squamous cell carcinoma of the breast: Clinico-pathologic implications and outcome. Eur J Surg Oncol 29: 386-389, 2003.
21. Shui R, Li A, Yang F, Zhou X, Yu B, Xu X and Yang W: Primary squamous cell carcinoma of the breast with unusual basal-HER2 phenotype. Int J Clin Exp Pathol 7: 5203-5209, 2014.
22. Lebbe C, Becker JC, Grob JJ, Malvehy J, Del Marmol V, Pehamberger H, Peris K, Saiag P, Middleton MR, Bastholt L, *et al*: Diagnosis and treatment of merkel cell carcinoma. European consensus-based interdisciplinary guideline. Eur J Cancer 51: 2396-2403, 2015.
23. Kurpad V, Prabhu KC, Ramesh MK and Harindranath HR: Primary denovo squamous cell carcinoma breast masquerading as breast abscess. Indian J Surg Oncol 4: 48-51, 2013.
24. Murialdo R, Boy D, Musizzano Y, Tixi L, Murelli F and Ballestrero A: Squamous cell carcinoma of the breast: A case report. Cases J 2: 7336, 2009.
25. Rowe DE, Carroll RJ and Day CL Jr: Prognostic factors for local recurrence, metastasis, and survival rates in squamous cell carcinoma of the skin, ear, and lip. Implications for treatment modality selection. J Am Acad Dermatol 26: 976-990, 1992.
26. Schmults CD, Karia PS, Carter JB, Han J and Qureshi AA: Factors predictive of recurrence and death from cutaneous squamous cell carcinoma: A 10-year, single-institution cohort study. JAMA Dermatol 149: 541-547, 2013.
27. Nayak A, Wu Y and Gilcrease MZ: Primary squamous cell carcinoma of the breast: Predictors of locoregional recurrence and overall survival. Am J Surg Pathol 37: 867-873, 2013.