SPANDIDOS PUBLICATIONS

MOLECULAR AND CLINICAL ONCOLOGY 10: 397-400, 2019

Pembrolizumab in newly diagnosed EBV-negative extranodal natural killer/T-cell lymphoma: A case report

SAMIA ASIF[1], MADELINE BEGEMANN[1], JOSEPH BENNETT[1], RAWISH FATIMA[1], ASHIQ MASOOD[2] and SHAHZAD RAZA[1]

[1]Department of Hematological Malignancies, Saint-Luke's Cancer Institute/University of Missouri School of Medicine, Kansas City, MO 64111; [2]Rush University Medical Center, Chicago, IL 60612, USA

Received November 8, 2018; Accepted January 14, 2019

DOI: 10.3892/mco.2019.1805

Abstract. Extranodal natural killer (NK)/T-cell lymphoma (ENKTL) is a rare subtype of non-Hodgkin's lymphoma with a dismal prognosis. The pathogenesis almost invariably involves Epstein-Barr virus (EBV) infection, although EBV-negative ENKTLs are frequently reported in the western hemisphere. Treatment of these lymphomas consists of aggressive chemotherapy with dexamethasone, methotrexate, ifosfamide, L-asparaginase and etoposide (SMILE regimen). However, the SMILE regimen is poorly tolerated by elderly patients; therefore, treatment options are limited to palliative radiation and chemotherapy and/or hospice care. Recently, binding of programmed death (PD)-1 with its ligand (PD-L1) expressed on tumor cells was shown to downregulate effector T-cell function and may represent a potent mechanism of immune evasion in classical Hodgkin's lymphoma and aggressive B-cell lymphomas. Thus, targeting PD-L1/PD-1 to inhibit effector T-cell signaling may be a promising therapeutic strategy for these NK/T-cell lymphomas. We herein report the clinical efficacy and feasibility of the anti-PD-1 inhibitor pembrolizumab used concurrently with radiation therapy and as maintenance therapy in an elderly female patient. The findings demonstrated that pembrolizumab may be an effective and well-tolerated treatment for this type of lymphoma.

Introduction

Extranodal natural killer (NK)/T-cell lymphoma (ENKTL) is an uncommon subclass of non-Hodgkin's lymphoma primarily encountered in Asian and South American populations (1). These lymphomas are of putative NK-cell origin, with a minority derived from the T-cell lineage. Pathologically, 80% of ENKTLs occur in the nose and upper aerodigestive tract, and rarely present as widespread metastasis (2). These lymphomas are locally very invasive and may cause perforation of the hard palate, whereas they rarely cause widespread distant metastasis involving the skin, soft tissues, uterus and gastrointestinal tract. The pathogenesis almost invariably involves Epstein-Barr virus (EBV) infection. Nicolae *et al* (3) recently reported a series of 7 cases of EBV-negative aggressive ENKTL. These lymphomas are clinically and pathologically indistinguishable from EBV-positive ENKTLs and they tend to occur in older patients. Gao *et al* (4) also reported a series of 3 patients with EBV-negative ENKTL in the western hemisphere, which shared similar characteristics with EBV-positive ENKTL and exhibited a highly aggressive clinical course. The immune checkpoint protein programmed death ligand 1 (PD-L1) was found to be overexpressed in all 3 patients. Thus, targeting the PD-L1/PD-1 axis may be a potent mechanism of immune evasion by averting effector T-cell signaling and inhibiting anti-lymphoma immunity (5,6). The treatment of these lymphomas is usually aggressive chemotherapy. Unfortunately, the treatment options for elderly patients are limited due to their poor tolerance to chemotherapy. In such cases, physicians tend to recommend hospice care and/or palliative radiation or palliative chemotherapy. In the present case, compassionate use of pembrolizumab was applied. To the best of our knowledge, this case is the first example of pembrolizumab treatment for naïve EBV-negative ENKTL.

Case report

A 90-year-old Hispanic female patient presented in December 2017 to the Saint-Luke's Cancer Institute (Kansas City, USA) with severe inflammation and ulceration of the hard palate for the last 2 months. On physical examination, the patient had scattered erythematous nodular skin lesions (Fig. 1). A biopsy from the hard palate lesions revealed an atypical population of intermediate to large lymphoid cells with a diffuse growth pattern. Immunohistochemical examination revealed positive staining for CD3 (membranous and cytoplasmic), CD43, CD56, multiple myeloma oncogene 1, perforin, granzyme B and T-cell intracellular antigen. The tumor cells were negative for CD4,

Correspondence to: Dr Shahzad Raza, Department of Hematological Malignancies, Saint-Luke's Cancer Institute/University of Missouri School of Medicine, 4321 Washington Street, STE 4000, Kansas City, MO 64111, USA
E-mail: razashahzad2@gmail.com

Key words: immunotherapy, programmed death ligand inhibitor, extranodal natural killer/T-cell lymphoma, pembrolizumab

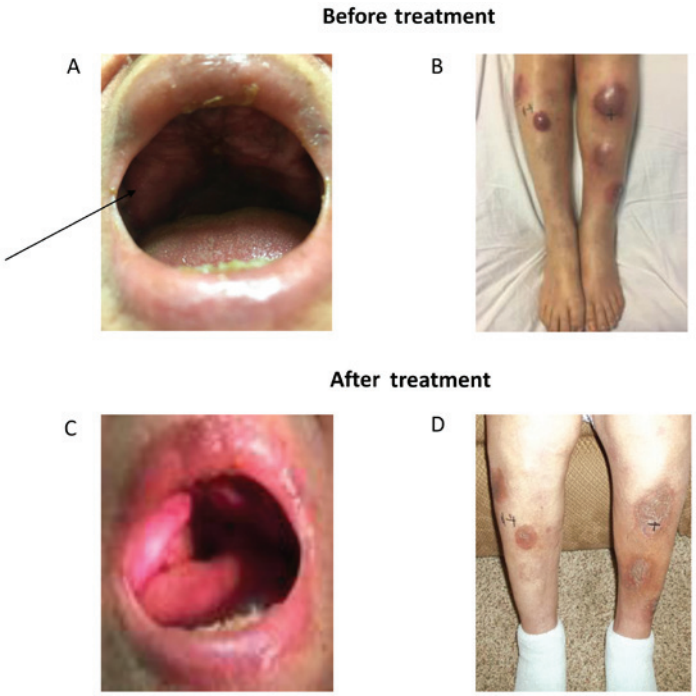

Figure 1. (A and B) EBV-negative ENKTL involving the palate and skin. An ulcerated plaque was observed in the hard palate (black arrow) and tender erythematous nodular skin lesions over both shins. (C and D) Resolution of palatal and skin lesions after treatment with pembrolizumab and radiation. ENKTL, extranodal NK/T-cell lymphoma; NK, natural killer.

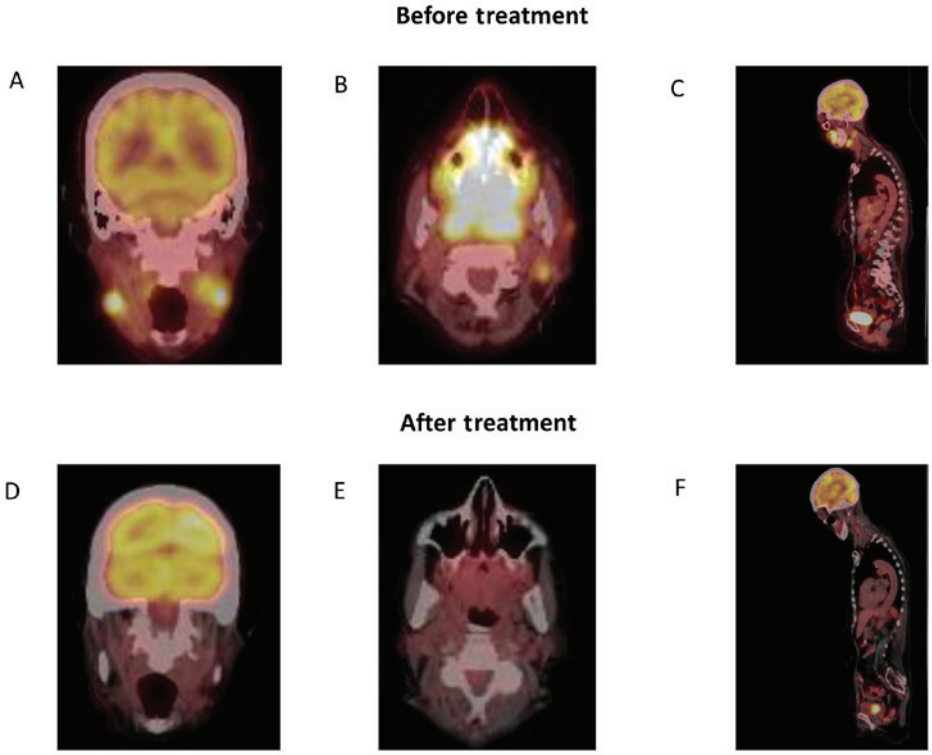

Figure 2. (A-C) Positron emission tomography-computed tomography examination revealed a left submandibular mass measuring 2.6x2.0 cm, with an SUV of 14.4, and a large nasopharyngeal mass, sized 4.5x3.5 cm, with an SUV of 16.3. (D-F) Marked improvement in radiographic response of the retropharyngeal mass. SUV, standardized uptake value.

CD5, CD7, CD8, CD15, CD20, CD30, anaplastic lymphoma kinase-1, B-cell lymphoma (BCL)-2, BCL-6 and EBV-*in situ* hybridization. Ki-67 was positive in 90% of the neoplastic cells. Serum EBV polymerase chain reaction was negative. Based on morphology and immunophenotypic characteristics, the findings were consistent with EBV-negative ENKTL. Position emission tomography-computed tomography (PET-CT) examination demonstrated a nasopharyngeal mass measuring 4.5x3.5 cm,

a left submandibular mass measuring 2.6x2 cm, as well as multiple fluorodeoxyglucose-avid cervical lymph nodes, several bilateral infiltrative breast masses and subcutaneous nodules in the gluteal region of the left leg and right calf; these findings were consistent with disseminated stage IV ENKTL (Fig. 2A). PD-L1 staining was positive in 25% of the tumor cells. Given the patient's advanced age and Eastern Cooperative Oncology Group performance status score of 3, she was not considered a candidate for aggressive chemotherapy. Therefore, treatment was selected based on the published experience of Kwong *et al* (6) on 7 patients with refractory ENKTL treated with pembrolizumab. The patient received 200 mg pembrolizumab every 3 weeks with concurrent radiation to the hard palate and skin nodules over the left leg, followed by maintenance pembrolizumab 200 mg every 3 weeks as compassionate use, and she tolerated the treatment well. The main treatment-related side effect in our patient was hypophosphatemia, which persisted for 3 months and responded to IV phosphate treatment. The lesions of the palate and skin responded to this treatment (Fig. 1B), and a PET scan at 3 months showed a notable response to treatment (Fig. 2B). Unfortunately, at the end of the 6th cycle, the patient experienced worsening of the lower extremity nodules and appearance of new cutaneous masses, and received a modified second-line regimen including pegaspargase, gemcitabine and oxaliplatin (P-GEMOX). After the first cycle, the lactate dehydrogenase level was normalized, and the cutaneous and visceral masses regressed.

However, P-GEMOX was poorly tolerated and patient clinical course was complicated by pseudomonas sepsis. On July 30, 2018, she had no evidence of lymphoma progression but due to poor performance status the patient's family eventually decided to pursue hospice care.

Discussion

The present case report demonstrated that PD-1 blockade concurrently with radiation and as maintenance therapy may be a viable treatment option for aggressive NK-cell lymphomas. Treatment with pembrolizumab appears to be feasible as well as effective in clinically naïve patients.

PD-1, a member of the CD28/CTLA4 family expressed on activated T-cells, is normally involved in immune tolerance and prevention of tissue damage associated with chronic inflammation. Importantly, inhibition of PD-1/PD-L1 has demonstrated high response rates in patients with classical Hodgkin's lymphoma (7). Pembrolizumab is an IgG4 isotype antibody that targets the PD-1 receptor on lymphocytes. Antibody binding to the ligand PD-L1 delivers an inhibitory signal, reducing cytokine production and proliferation. Kwong *et al* (6) recently published their experience on 7 patients with relapsed EBV-positive ENKTL. Of the 7 patients, 6 received 2 mg/kg pembrolizumab every 3 weeks and 1 patient received 2 mg/kg every 2 weeks. All the patients responded to pembrolizumab. In that study, strong PDL1 expression was associated with higher response rates. Li *et al* (8) administered pembrolizumab to 7 patients at 100 mg every 3 weeks and reported a 57% overall response rate, but did not observe a direct correlation between the expression of PD-L1 and clinical response. As our patient had EBV-negative ENKTL, PD-L1 expression on tumor tissue (25% in this case) was used to guide pembrolizumab therapy. Second, pembrolizumab 200 mg every 3 weeks was used concurrently with radiation and then as maintenance treatment, which was well-tolerated in the present case. Interestingly, complete response in the hard palate was sustained right up to the time when the patient transitioned to hospice care. This may be attributed to concurrent radiation and immunotherapy.

In advanced solid tumors, the combination of pembrolizumab and radiation has been proven to be safe and has been shown to enhance T-cell response and augment the abscopal effect on these tumors (9).

This was hypothesized to be the reason for our patient achieving complete response in the hard palate. However, after progression of the lymphoma at other sites, including soft tissue and skin, the treatment was changed to modified P-GEMOX for 1 cycle. There was radiographic response to this treatment, but the patient's course was complicated by pseudomonas pneumonia. Eventually, the patient's family decided to pursue hospice care. Taking into consideration all available treatments, our experience suggests that first-line pembrolizumab may be a feasible option in elderly patients who have limited treatment options, and it may be preferred over palliative chemotherapy.

Acknowledgements

The authors would like to thank Merck & Co., Inc., (Whitehouse Station, NJ, USA) for providing pembrolizumab through their expanded access program.

Funding

No funding was received.

Availability of data and materials

The datasets used/or analyzed during the present study are available from the corresponding author upon request.

Authors' contributions

SA, JB, RF and SR designed the study and drafted the manuscript. SA also retrieved pathology images. JB, RF and SA reviewed the patient's history, clinical and imaging data. SR supervised the entire project. MB and AM reviewed and drafted the manuscript. All the authors have read and approved the final version of this manuscript.

Ethics approval and consent to participate

Not applicable.

Patient consent for publication

The patient provided informed consent in advance via the formal institutional form for the publication of this report and any accompanying images.

Competing interests

SR is a member of advisory board and speaker bureau for Takeda, Novartis, Janssen and Amgen. SR received honoraria,

has a consulting/advisory role and participates in the speaker's bureaus of Takeda, Novartis, Janssen, Amgen and Celgene. SR has no competing interests regarding the preparation of this manuscript and did not receive any financial grants. AM received honoraria, has a consulting/advisory role and participates in the speaker's bureaus of Bristol-Myers Squibb, Boehringer Ingelheim and Biocept. SA, MB, JB and RF declare that they have no competing interests to disclose.

References

1. Sun J, Yang Q, Lu Z, He M, Gao L, Zhu M, Sun L, Wei L, Li M, Liu C, *et al*: Distribution of lymphoid neoplasms in China: Analysis of 4,638 cases according to the World Health Organization classification. Am J Clin Pathol 138: 429-434, 2012.
2. Tse E and Kwong YL: The diagnosis and management of NK/T-cell lymphomas. J Hematol Oncol 10: 85, 2017.
3. Nicolae A, Ganapathi KA, Pham TH, Xi L, Torres-Cabala CA, Nanaji NM, Zha HD, Fan Z, Irwin S, Pittaluga S, *et al*: EBV-negative aggressive NK-cell leukemia/lymphoma: Clinical, pathologic, and genetic features. Am J Surg Pathol 41: 67-74, 2017.
4. Gao J, Behdad A, Ji P, Wolniak KL, Frankfurt O and Chen YH: EBV-negative aggressive NK-cell leukemia/lymphoma: A clinical and pathological study from a single institution. Mod Pathol 30: 1100-1115, 2017.
5. Vari F, Arpon D, Keane C, Hertzberg MS, Talaulikar D, Jain S, Cui Q, Han E, Tobin J, Bird R, *et al*: Immune evasion via PD-1/PD-L1 on NK cells and monocyte/macrophages is more prominent in Hodgkin lymphoma than DLBCL. Blood 131: 1809-1819, 2018.
6. Kwong YL, Chan TSY, Tan D, Kim SJ, Poon LM, Mow B, Khong PL, Loong F, Au-Yeung R, Iqbal J, *et al*: PD1 blockade with pembrolizumab is highly effective in relapsed or refractory NK/T-cell lymphoma failing l-asparaginase. Blood 129: 2437-2442, 2017.
7. Li X, Cui Y, Sun Z, Zhang L, Li L, Wang X, Wu J, Fu X, Ma W, Zhang X, *et al*: DDGP versus SMILE in newly diagnosed advanced natural killer/T-cell lymphoma: A randomized controlled, multicenter, open-label study in China. Clin Cancer Res 22: 5223-5228, 2016.
8. Li X, Cheng Y, Zhang M, Yan J, Li L, Fu X, Zhang X, Chang Y, Sun Z, Yu H, *et al*: Activity of pembrolizumab in relapsed/refractory NK/T-cell lymphoma. J Hematol Oncol 11: 15, 2018.
9. Liu Y, Dong Y, Kong L, Shi F, Zhu H and Yu J: Abscopal effect of radiotherapy combined with immune checkpoint inhibitors. J Hematol Oncol 11: 104, 2018.