Fluorodeoxyglucose positron emission tomography/CT for primary malignant intraosseous neoplasms of the mandible

YIYAN LIU

Nuclear Medicine Service, Department of Radiology, Rutgers New Jersey Medical School, Newark, NJ 07101, USA

Received July 9, 2021; Accepted October 21, 2021

DOI: 10.3892/mco.2021.2451

Abstract. Primary intraosseous malignant neoplasm of the mandible is a very rare entity. There are few publications regarding fluorodeoxyglucose (FDG) positron emission tomography (PET)/CT for primary intraosseous neoplasms of the mandible. FDG PET/CT scans from 10 patients with primary malignant neoplasm of the mandible were retrieved from the Picture Archiving and Communication System database, and image findings were analyzed with correlation to contrast-enhanced diagnostic CT and surgical pathology. Accuracy of the FDG PET/CT findings was evaluated with respect to uptake intensity, lesion extension to adjacent soft tissue, lymph node and distant metastasis. All untreated primary mandible neoplasms demonstrated high FDG avidity on PET imaging. Most mandible lesions extended beyond the bones and involved perimandibular soft tissue. FDG PET/CT imaging showed improved sensitivity and specificity compared with that for CT for lymph node staging in 3 cases, with discordant findings between diagnostic CT and PET/CT. FDG PET/CT identified 4 distant metastases, which were not documented prior to PET/CT. The results suggested that FDG PET/CT was a valuable image modality to demonstrate all primary and metastatic lesions of primary malignant neoplasm of the mandible, to define perimandibular soft tissue involvement, and more accurately stage/restage the disease than diagnostic CT.

Introduction

Mandibular lesions are classified as odontogenic and non-odontogenic based on the cell of origin. A lesion associated with an impacted tooth frequently indicates an odontogenic origin. Non-odontogenic lesions, however, develop from osseous origin and are not tooth related (1,2).

Most malignant neoplasms of the mandible are secondary to tumor invasion from the surrounding mucosa of the oral cavity (3,4). Metastatic disease may involve the mandible. The most common sites of origin include the kidneys, lungs and the breasts (3,4). Primary intraosseous malignant neoplasm of the mandible is a very rare entity and has been hypothesized to originate from the remnants of odontogenic epithelium and has no initial connection with the oral mucosa (3,4). For the diagnosis of primary intraosseous malignant neoplasm of the mandible, tumor invasion or metastasis to the mandible from another oral cavity or distant location must be excluded (2,4).

There have only been a small number of reports on primary mandibular neoplasm in the literature (5-9). There are few publications regarding fluorodeoxyglucose (FDG) positron emission tomography (PET)/CT for primary intraosseous neoplasms of the mandible (10-12), due to the rarity of the disease.

The aim of the present study was to evaluate the value of FDG PET/CT for primary mandibular neoplasm. Therefore, patients with primary malignant neoplasm of the mandible were identified from the Picture Archiving and Communication System database, and FDG PET/CT imaging and all clinical documents were reviewed.

Materials and methods

Ethics and patients. The present retrospective study was approved by the Institutional Review board at New Jersey Medical School, Rutgers University (NJ, USA). Relevant cases were identified by searching a computerized database containing 6,500 patients with cancer who underwent PET/CT imaging at the Advanced Imaging Center, Rutgers New Jersey Medical School (NJ, USA) between January 2010 and June 2020. A total of 10 patients, who had FDG PET/CT for primary mandible lesions or neoplasms, were selected for the study based on the following inclusion criteria: i) Histopathologically confirmed malignant intraosseous neoplasms of the mandible prior to FDG PET/CT; ii) exclusion of other neoplasms, especially in the head and neck by medical history; iii) comprehensive examinations; and iv) laboratory and image evaluations. A total of 6,490 patients with known neoplasm at other locations (such as the tonsils, tongue, larynx, lungs and colorectum), metastatic mandible lesions or

Correspondence to: Professor Yiyan Liu, *Present address:* Nuclear Medicine Section, Department of Radiology, University of Louisville School of Medicine, 530 South Jackson Street, Louisville, KY 40202, USA
E-mail: yiyan.liu@louisville.edu

Key words: primary intraosseous malignant neoplasm of the mandible; mandible, fluorodeoxyglucose positron emission tomography/CT, staging, restaging

radiation-induced mandibular necrosis were excluded from the study.

Prior to FDG PET/CT, 7 patients had diagnostic imaging using contrast-enhanced neck CT. All eligible subjects had available histopathological investigations, clinical and image follow-up data following PET/CT.

FDG PET/CT scan. Combined PET/CT was performed using a PET/CT scanner (Discovery LS; GE Healthcare) and the standard techniques. The patients had fasted for at least 6 h prior to examination and their blood glucose level was <250 mg/dl. The patients received 15 mCi intravenous FDG administration, immediately followed by oral administration of 500 ml diluted Gastrografin. Spiral low-dose CT (80 mA; 140 kV; 4 mm section thickness) was performed with the cranio-caudal direction covering the areas from the vertex to the mid-thigh for the purpose of attenuation correction and anatomic localization, 60 min later. Thereafter, emission scan was conducted in a reverse direction.

Image analysis. Diagnostic CT images were interpreted by the radiologists specialized in head and neck imaging. MIM image software (v6.9.4; MIM Software, Inc.) was used for PET/CT image display and analysis. The whole-body maximum-pixel-intensity projection was used for visual evaluation. Maximum standardized uptake value (SUV_{max}) of the lesions was recorded. All the selected images were re-interpreted by the investigator for accuracy of previous dictation reports.

Histopathological and/or cytopathological diagnosis was inferred from the electronic medical documents, Epic and Logician.

The performance of FDG PET/CT was evaluated based on the association of the image findings with histopathological results, and the sensitivity, specificity and accuracy of FDG PET/CT were calculated for primary mandible and/or distant metastatic lesions.

Results

Patient characteristics. A total of 10 patients and 16 scans were analyzed in the present study (Table I). There were 7 males and 3 females, with a mean age of 69 years (range, 29-82 years). For the first FDG PET/CT scans, 9 patients were for staging and 1 was for restaging following surgery. A total of 6 out of 10 patients had follow-up restaging images after the first scan. The diagnosis of primary intraosseous neoplasms of the mandible was verified using FDG PET/CT, which excluded other primary lesions or tumors in all the patients.

All of the 10 patients had histopathological confirmed primary mandible neoplasms, including 6 squamous cell carcinoma, 1 diffuse large B-cell lymphoma, 1 adenocarcinoma, 1 plasmacytoma and 1 ameloblastic fibrosarcoma. A total of 6 patients had a primary lesion on the right, with 4 on the left.

FDG PET/CT findings. All the untreated primary mandible neoplasms demonstrated high FDG avidity on the PET imaging, with a mean SUV_{max}, 14.8±9.3 (range, 7.0-35). Most mandible lesions extended beyond the bones and involved perimandibular soft tissue, and 2 invaded the ipsilateral floor of the month. The results were suggestive of high FDG avidity and high sensitivity of PET/CT in detection of primary mandible tumors. Contrast-enhanced diagnostic CT imaging of the neck in 7 out of 10 patients showed similar bone lesion as FDG PET; however, PET images could define the involvement of soft tissue compared with that for contrast-enhanced diagnostic CT. In 7 patients with diagnostic CT prior to FDG PET/CT, soft tissue involvement or invasion was well documented on only 1 report (patient 6).

On the integrated CT appearance, all mandible tumors showed lytic/destructive or mixed lytic/sclerotic lesions. There was no pure sclerotic or osteoblastic lesion in any of the patients.

PET/CT for N and M staging. While N staging of the disease is solely based on the size of lymph nodes from anatomic images, defined as positive for those >1 cm (2), FDG PET imaging showed improved sensitivity and specificity compared with that for contrast-enhanced diagnostic CT for N staging. A total of 6 out of 10 patients had ipsilateral lymph node metastases on the initial PET/CT staging scan, and all were verified by surgical pathology. A total of 7 patients had contrast-enhanced diagnostic neck CT prior to PET/CT. While diagnostic CT and FDG PET/CT had similar findings for regional lymphadenopathy in 4 out of 7 patients, there were 3 patients with whom the diagnostic neck CT and FDG PET had discordant findings. For patient 4, the diagnostic neck CT, on the same day as PET/CT, showed right mandibular lesion and two 1.3 cm ipsilateral right level IB lymph nodes, suspicious for metastases based on the size criteria. However, there was no FDG uptake of the lymph nodes on FDG PET/CT (Fig. 1). Surgical pathology from dissection was negative in both lymph nodes. However, for patients 6 and 8, the diagnostic CT did not report lymphadenopathy, but the FDG PET/CT scan revealed a 1.2 cm and 1.1 cm right level II lymph node, with moderate to intense uptake (SUV, 5.0 and 7.1 respectively), consistent with nodal metastases, which were confirmed by surgical histopathological examinations (Fig. 2, for patient 8). Therefore, in these three cases, diagnostic CT was false positive for one case and false negative for 2 cases, but there was no false positives or negatives for FDG PET/CT.

None of the 10 patients had image workups for distant metastasis prior to FDG PET/CT. In 3 out of 10 patients with the first FDG PET/CT scan, distant metastatic disease was detected in the spleen, ilium and lung, respectively. Another patient developed intracranial metastasis on the restaging scan (Fig. 3, patient 7). Overall, the FDG PET/CT scan identified 4 distant metastases from the 10 patients, which were either unknown or not documented prior to PET/CT. From the 4 distant metastatic lesions, 2 (lung and brain) were verified by surgical pathology and another (spleen lesion) was confirmed by biopsy.

PET/CT for restaging. A total of 6 out of 10 patients had a 2nd FDG PET/CT scan for restaging with or without treatment. A total of 3 patients, who had surgical resections (2 mandibulectomy and 1 lung segmentectomy), were negative on the restaging scans, 1 patient had worse disease and new intracranial metastasis after 4-months of chemotherapy, 1 patient had improvement of the disease extent and FDG uptake after

Table I. Characteristics of patients with primary malignant neoplasms of the mandible.

Patient number	Age, years	Sex	Scan number	Pre-PET pathology and indication	Prior contrast-enhanced neck CT	PET/CT findings		Regional lymph nodes	Distant metastasis	Treatment	Final pathology	F/U
						Outcome	SUV					
1	81	M	2	SCC staging	None	R. mandible destruction	8.8	No	No	Mandibulectomy and RT	SCC LN (-)	1 PET/CT in 1 year, neg
2	64	M	2	SCC staging	L. mandible lesion and L. neck nodes	L. mandible destruction	14.7	L. neck	No	Mandibulectomy and RT	SCC LN (+)	1 PET/CT in 1 year, neg
3	84	F	2	SCC staging	R. mandible lesion and R. LN	R. mandible destruction with ST involvement	28	R. neck	No	None	SCC LN (+)	Restaging PET/CT, worse
4	68	F	1	SCC staging	R. mandible lesion and R. neck LN	R. mandibular destruction with ST invasion	11	No (no LN uptake)	No	Segmental mandibulectomy and R. neck dissection	SCC LN (-)	None
5	82	F	2	SCC staging	None	R. mandible destruction with ST invasion	9.4	No	No	Keytruda therapy for 8 m	SCC LN (-)	Restaging PET/CT, decreased extent and uptake. SUV 3.8
6	59	M	1	SCC staging	R. mandible lesion with ST component, small R. LN	R. mandible destruction with ST invasion	15	R. neck. 1.2 cm with SUV 5.0	No	No	SCC LN (+)	None
7	76	M	2	DLBCL staging	None	L. mandible lytic lesion with ST involvement	9.3	L. neck LN	Spleen	Chemo for 4 months	DLBCL LN (+)	Restaging PET/CT, worse with new intracranial lesion
8	77	M	1	Adenocarcinoma staging	R. mandible lesion. No LN	R. mandible lytic lesion	7.0	R. neck LN, 1.1 cm with SUV 7.1	No	Chemo	Adenocarcinoma LN (+)	None
9	68	M	1	Plasmocytoma staging	L mandible lesion and LN	Lytic L. mandible lesion with FOM involvement	35	L. neck LNs	R. ilium	Chemo and RT	Plasmocytoma LN (+)	None
10	29	M	2	Ameloblastic fibrosarcoma restaging	L. mandibulectomy. No LN	RLL lung lesion, 2 cm	9.8	No	R. lung	RLL segmentectomy	Metastatic fibrosarcoma	Repeat PET/CT in 3 months, neg

SCC, squamous cell carcinoma; M, male; F, female; L, left; R, right; LN, lymph node; RLL, right lower lobe; FOM, floor of mouth; chemo, chemotherapy; RT, radiation therapy; neg, negative, SUV, standardized uptake value; DLBCL, diffuse large B-cell lymphoma; PET, positron emission tomography; F/U, follow-up.

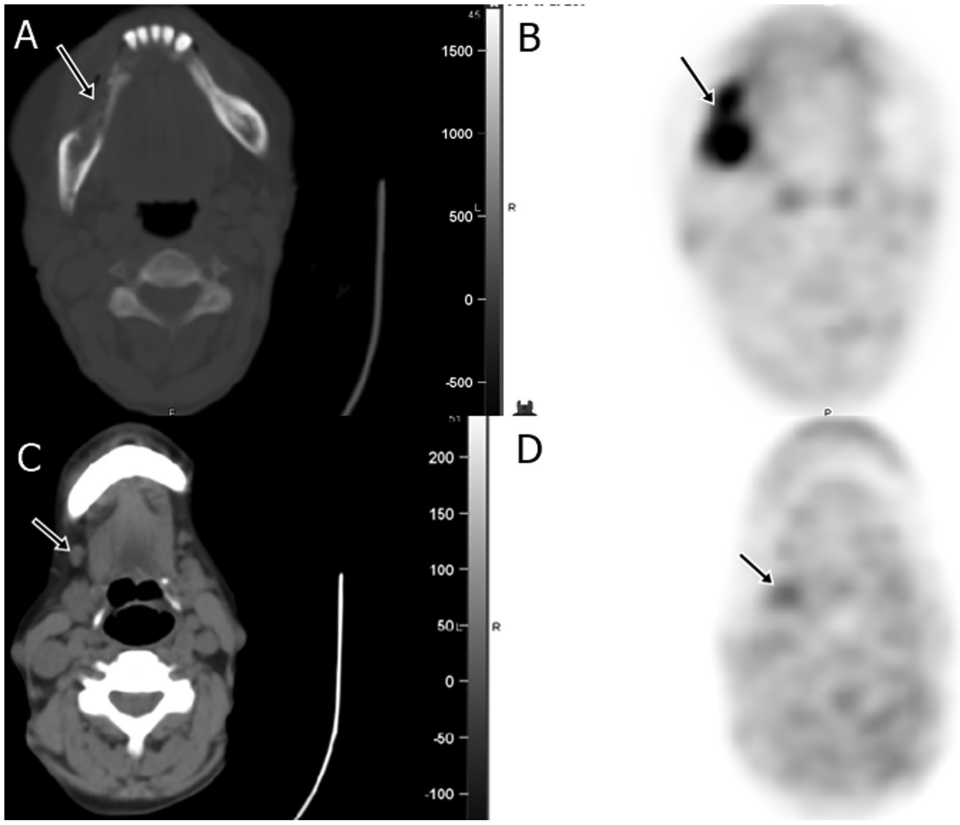

Figure 1. A 68-year-old woman with right mandibular squamous cell carcinoma (patient 4). Staging PET/CT showed (A) bone destruction and the premandibular soft tissue involvement and (B) intense FDG uptake. There was a 1.3 cm right level IB node considered as metastasis on the diagnostic CT report. (C and D) However, there was only minimal uptake of the lymph node on PET (arrows). Surgical pathology of this lymph node was negative for tumor. FDG, fluorodeoxyglucose; PET, positron emission tomography.

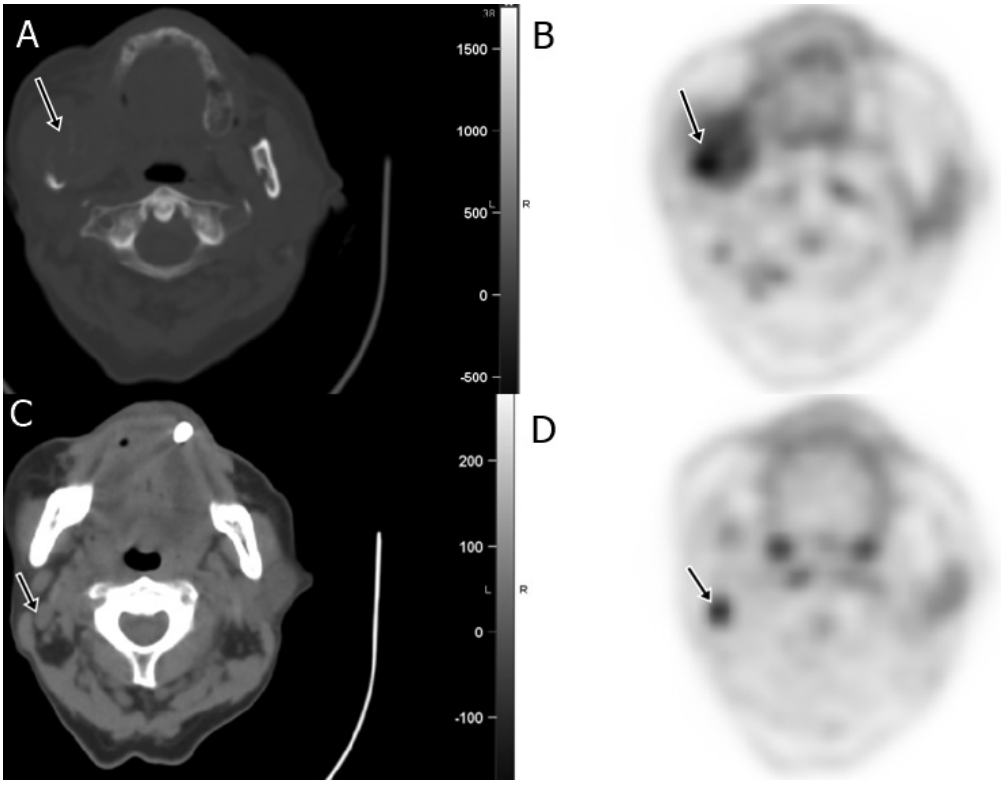

Figure 2. A 77-year-old man with newly diagnosed adenocarcinoma of the right mandible (patient 8). (A and B) Fluorodeoxyglucose PET/CT showed FDG avid destructive bone lesion with adjacent soft tissue invasion (arrows). The diagnostic CT did not report lymphadenopathy; however, (C and D) PET/CT showed a 1.1 cm level IIa lymph node with intense uptake (arrows). The neck dissection confirmed metastatic disease. PET, positron emission tomography.

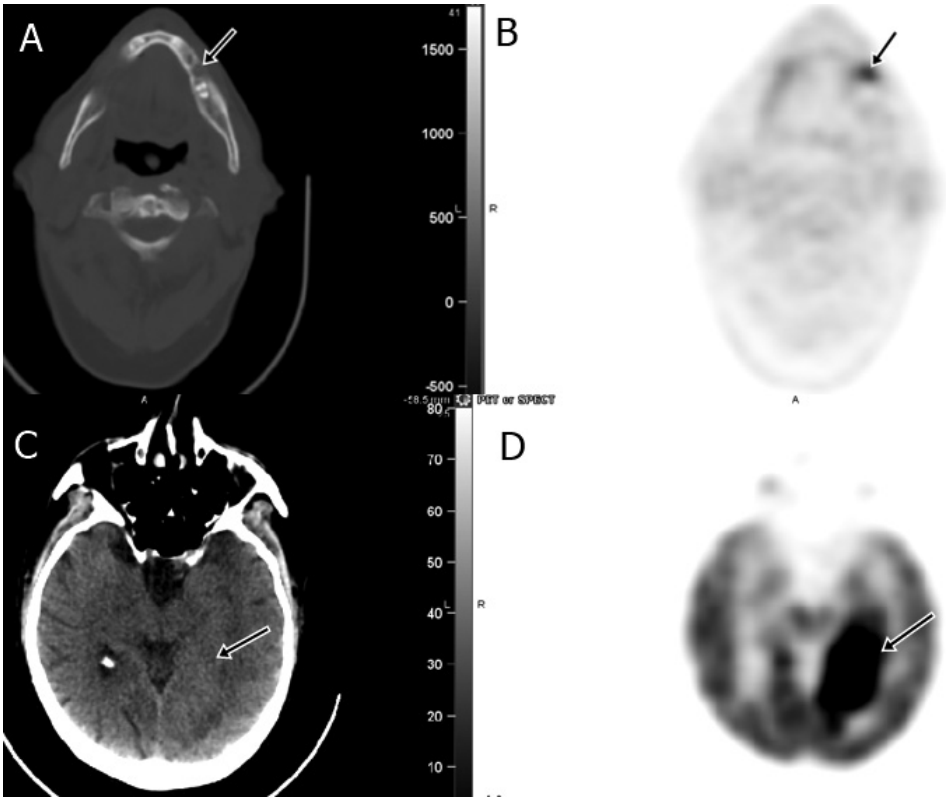

Figure 3. A 76-year-old man four months following chemotherapy for diffuse large B-cell lymphoma of the left mandible (patient 7). (A and B) Restaging FDG PET/CT showed improvement of the primary lesion (arrows), but there was a large (C and D) FDG avid metastatic mass in the left cerebellum (arrows), which was verified by MRI and surgical pathology. FDG, fluorodeoxyglucose; PET, positron emission tomography.

8-months Keytruda treatment, and 1 had worsening primary neoplasm and local nodal disease 6 months later without any treatment.

Overall PET/CT performance. Combining all of the 16 FDG PET/CT scans from the 10 patients, sensitivity, specificity, and accuracy for primary mandible and/or distant metastatic lesions were 100% (13/13), 100% (3/3) and 100% (16/16), respectively.

For N staging of the initial scans, FDG PET/CT sensitivity, specificity and accuracy were 100% (5/5), 100% (4/4) and 100% (9/9), compared with that for diagnostic CT, 75% (3/4), 50% (1/2) and 67% (4/6), respectively.

Discussion

A variety of benign and malignant neoplasms may originate in the mandible. Primary malignant mandibular neoplasm is very rare, with only a few case reports regarding image diagnosis in the literature (1-4). In the present study, the most common malignant tumor of the mandible was squamous cell carcinoma, consistent with previous studies (13-15). Primary intraosseous malignant neoplasms affect men more than women and is more frequent in the 6th and 7th decades of life (16,17). In the present study, 7 out of 10 patients were men and 8 out of 10 were >60 years old, with a mean age of 69 years.

The posterior mandible has been the most common site of tumor occurrence. Image exanimation is often the first evaluation of the suspected mandibular lesion (1,4). A lesion that is surrounded by bone can be regarded as of intraosseous origin. Radiographical lesions usually show a fully enclosed, irregular pattern of bone destruction with ill-defined margin (2). However, image findings are non-specific with similar appearance in a wide range of pathology. The recommended treatment is radical surgery and neck dissection (2-4). In general, prognosis is poor (15).

The patient data analyzed in the present study demonstrated that FDG PET/CT was a valuable image modality for staging and restaging primary mandibular neoplasm. There was high FDG avidity of all primary and metastatic lesions. FDG PET/CT could define perimandibular soft tissue involvement, detect regional lymph node and distant metastases with 100% accuracy. In numerous patients with primary mandibular lesions, there was hyperemia of the adjacent soft tissue and muscles, which might demonstrate contrast enhancement on the diagnostic CT and could not be distinguished from tumor extension. The uptake intensity of the soft tissue/muscles adjacent to the mandibular tumor on the PET image could assist with identifying soft tissue involvement or invasion. Compared to contrast-enhanced diagnostic CT, FDG PET/CT also provided superior N staging. There were three patients with discordant findings between the diagnostic CT and FDG PET/CT images, and surgical pathology verified that FDG uptake in these lymph nodes was more liable than the size criteria for N-staging. It is well-known that FDG PET/CT plays a valuable role in M-staging due to its whole-body acquisition protocol in oncology (2,10). In the present study, none of the 10 patients had image workups for distant metastasis prior to FDG PET/CT, which might be due to scheduled FDG

PET/CT, as it scans the whole body. On the initial staging, three patients were found to have distant metastases in the lung, spleen and ilium respectively, which were all unexpected since there was no prior imaging for distant metastasis. Additional intracranial metastasis was detected from the restaging scan in 1 of these 3 patients. Identification of distant metastases changed the patient's therapeutic strategy. The results might suggest that FDG PET/CT was an effective image modality for surveillance, monitoring therapeutic response and detection of metastatic disease.

The diagnosis of primary intraosseous cancer of the mandible requires exclusion of other oral cavity tumors and different primary neoplasms. The mandibular lesion must be distinguished from the tumors that metastasize to the jaw from distant sites, from gingival carcinomas that have invaded the bone from the surface, and from tumors that originated from maxillary sinus (1,4). For exclusion of another primary tumors, whole-body FDG PET/CT may be the best modality to rule out synchronous lesions or separate primary (18).

Compared to previously published reports regarding FDG PET/CT for primary malignant intraosseous neoplasms of the mandible (10-12), the results from the present study represent the largest number of cases with FDG PET/CT scans in more varied types of tumor pathology. Published cases regarding FDG PET/CT in primary malignant mandibular tumors were all for squamous cell carcinoma. The current study presented FDG PET/CT image findings in additional rare primary neoplasms of the mandible: Diffuse large B-cell lymphoma, adenocarcinoma, plasmacytoma and ameloblastic fibrosarcoma. FDG PET/CT is well-known for its improved sensitivity and accuracy in N and M staging than conventional anatomical image modalities in oncology; however, the current study clearly demonstrated the value of FDG PET/CT in this special group of patients, which is similar to other malignant neoplasms, such as oral cavity cancer, laryngeal cancer, lymphoma and lung cancer (19).

A notable limitation of the present study is the small sample size, due to the rarity of the disease, which made statistical analysis less powerful. In addition, referral and image selection bias should be considered. Another limitation is the lack of color fusion PET/CT images for review of the image examples.

In conclusion, the results of FDG PET/CT images from 10 patients with primary intraosseous malignant neoplasms showed high FDG avidity in all the primary and metastatic lesions, improved definition of perimandibular soft tissue involvement, more accurate regional N-staging and M-staging than the contrast-enhanced diagnostic CT. In addition, whole-body FDG PET/CT is a valuable image modality for exclusion of synchronous lesions or separate primary and verification of diagnosis of primary intraosseous neoplasm of the mandible as well.

Acknowledgements

Not applicable.

Funding

No funding was received.

Availability of data and materials

The datasets used and/or analyzed during the current study are available from the corresponding author on reasonable request.

Author's contributions

YL was a sole author and performed the study including the conception and design, acquisition, analysis and interpretation of data, and preparation of the manuscript. YL also confirms the authenticity of all the raw data.

Ethics approval and consent to participate

This retrospective study was approved by the Institutional Review board at New Jersey Medical School, Rutgers University (approval no, Pro2018001712), and the requirement for written informed consent was waived.

Patient consent for publication

Not applicable.

Competing interests

The author declares that they have no competing interests.

References

1. Looser KG and Kuehn PG: Primary tumors of the mandible. A study of 49 cases. Am J Surg 132: 608-614, 1976.
2. Dunfee BL, Sakai O, Pistey R and Gohel A: Radiologic and pathologic characteristics of benign and malignant lesions of the mandible. Radiographics 26: 1751-1768, 2006.
3. Zachariades N: Neoplasms metastatic to the mouth, jaws and surrounding tissues. J Craniomaxillofac Surg 17: 283-290, 1989.
4. Weber AL, Bui C and Kaneda T: Malignant tumors of the mandible and maxilla. Neuroimaging Clin N Am 13: 509-524, 2003.
5. Lopes Dias J, Borges A and Lima Rego R: Primary intraosseous squamous cell carcinoma of the mandible: A case with atypical imaging features. BJR Case Rep 2: 20150276, 2016.
6. Hu HY, Liu YY, Wang H and Jiang M: Primary Intraosseous Adenoid Cystic Carcinoma of the Mandible: A Comprehensive Review With Analysis of 2 Additional Cases. J Oral Maxillofac Surg 75: 1685-1701, 2017.
7. Kawano K, Ono K, Yada N, Takahashi Y, Kashima K, Yokoyama S and Yanagisawa S: Malignant calcifying epithelial odontogenic tumor of the mandible: Report of a case with pulmonary metastasis showing remarkable response to platinum derivatives. Oral Surg Oral Med Oral Pathol Oral Radiol Endod 104: 76-81, 2007.
8. Schneider LC, Dolinsky HB, Grodjesk JE, Mesa ML and Doyle JL: Malignant spindle cell tumor arising in the mandible of a patient with florid osseous dysplasia. Oral Surg Oral Med Oral Pathol Oral Radiol Endod 88: 69-73, 1999.
9. Mintz GA, Abrams AM, Carlsen GD, Melrose RJ and Fister HW: Primary malignant giant cell tumor of the mandible. Report of a case and review of the literature. Oral Surg Oral Med Oral Pathol 51: 164-171, 1981.
10. Bosch-Barrera J, Arbea L, García-Velloso MJ, Gil-Bazo I, García-Foncillas J and Panizo C: Primary bone lymphoma of the mandible and thyroid incidentaloma identified by FDG PET/CT: A case report. Cases J 2: 6384, 2009.
11. Strobel K, Merwald M, Huellner M, Zenklusen HR and Kuttenberger J: Osteoblastoma of the mandible mimicking osteosarcoma in FDG PET/CT imaging. Clin Nucl Med 38: 143-144, 2013.

12. Takami Y, Aga F, Mitamura K, Norikane T, Okuda H, Yamamoto Y, Miyake M and Nishiyama Y: A Case of Ewing Sarcoma of the Mandible on ^{18}F-FDG PET/CT. Asia Ocean J Nucl Med Biol 8: 84-87, 2020.
13. Woolgar JA, Triantafyllou A, Ferlito A, Devaney KO, Lewis JS Jr, Rinaldo A, Slootweg PJ and Barnes L: Intraosseous carcinoma of the jaws: a clinicopathologic review. Part III: Primary intraosseous squamous cell carcinoma. Head Neck 35: 906-909, 2013.
14. Wenguang X, Hao S, Xiaofeng Q, Zhiyong W, Yufeng W, Qingang H and Wei H: Prognostic Factors of Primary Intraosseous Squamous Cell Carcinoma (PIOSCC): A Retrospective Review. PLoS One 11: e0153646, 2016.
15. Suei Y, Tanimoto K, Taguchi A and Wada T: Primary intraosseous carcinoma: Review of the literature and diagnostic criteria. J Oral Maxillofac Surg 52: 580-583, 1994.
16. De Lathouwer C and Verhest A: Malignant primary intraosseous carcinoma of the mandible. Oral Surg Oral Med Oral Pathol 37: 77-83, 1974.
17. Lo Muzio L, Mangini F, De Falco V, Pennella A and Farronato G: Primary intraosseous carcinoma of the mandible: A case report. Oral Oncol 36: 305-307, 2000.
18. Lugakingira M, Pytynia K, Kolokythas A and Miloro M: Primary intraosseous carcinoma of the mandible: Case report and review of the literature. J Oral Maxillofac Surg 68: 2623-2629, 2010.
19. Kapoor V, McCook BM and Torok FS: An introduction to PET-CT imaging. Radiographics 24: 523-543, 2004.